

Original paper

## T1a renal cancer cryoablation – first experiences in Poland

Grzegorz Rosiak<sup>1,A,B,C,D,E,F</sup>, Jakub Franke<sup>1,B,C,D,E,F</sup>, Dariusz Konecki<sup>1,A,B,D,E</sup>, Krzysztof Milczarek<sup>1,B,D,E,F</sup>,  
Tomasz Ostrowski<sup>2,B,D,E,F</sup>, Robert Nowakowski<sup>3,D,E,F</sup>, Tomasz Demkow<sup>3,D,E,F</sup>, Zbigniew Gałązka<sup>2,D,E,F</sup>

<sup>1</sup>2<sup>nd</sup> Department of Radiology, Medical University of Warsaw, Warsaw, Poland

<sup>2</sup>Department of General, Vascular, Endocrine, and Transplant Surgery, Medical University of Warsaw, Warsaw, Poland

<sup>3</sup>Department of Genitourinary Oncology, Maria Skłodowska-Curie National Research Institute of Oncology, Warsaw, Poland

### Abstract

**Purpose:** Cryoablation is one of the methods of treating patients with renal cancer with curative intent. This procedure is not widely available in Poland due to the lack of reimbursement until April 2023. The purpose of this study is to present the results of the first experiences in cryoablation of renal cell carcinoma in Poland.

**Material and methods:** Patients with renal cell carcinoma in T1a stage (up to 4 cm in diameter) were treated with percutaneous cryoablation between December 2020 and December 2023. All patients were disqualified from surgical treatment due to age, comorbidities, or history of nephrectomy. Diagnosis was confirmed by computed tomography (CT)-guided core needle biopsy that was performed 2-4 weeks before cryoablation.

**Results:** Twenty-five patients underwent CT-guided cryoablation of T1a renal cancer. The mean age of the patients was 77 years (43-91 years). The mean diameter of lesions was 27 mm (15-40 mm). None of the patients presented with local or distant recurrence within the mean 12-months of follow-up period (100% progression-free survival). Urine leak treated with a stent was detected in one patient. Four patients died within the follow-up period, but none of the deaths was directly related to the procedure.

**Conclusions:** Cryoablation is an effective and safe procedure and should be available to more patients in Poland.

**Key words:** cryoablation, ablation, interventional radiology, interventional oncology, renal cell carcinoma, renal cancer.

### Introduction

Renal cell carcinoma (RCC) affects annually 372,000 people worldwide and around 3000 in Poland [1,2]. It is frequently detected in the early stage, usually incidentally in computed tomography (CT), magnetic resonance (MR), or ultrasound studies performed due to other reasons.

Partial nephrectomy is the treatment of choice of stage T1 RCC (< 7 cm and no metastases). However, according to European Association of Urology (EUA), European Society of Medical Oncology (ESMO), and National Comprehensive Cancer Network (NCCN) guidelines, patients with T1a RCC who are poor surgical candidates can be treated with percutaneous ablation [3-5]. According to

the American Urological Association (AUA), clinicians should consider thermal ablation as an alternate approach for the management of T1a solid renal masses < 3 cm in size [6]. Radiofrequency ablation (RFA) and microwave ablation (MWA) are the methods that use high temperature to destroy tumour tissue, while cryoablation is a way of killing cancer cells by freezing the tumour.

Out of these 3 methods, cryoablation is gaining a leading position due to several advantages. Firstly, the ablation zone is very clearly visible during treatment under CT guidance. Also, cryoablation can be safely applied in central kidney tumours and in larger lesions; it is also less painful than heat-based methods (RFA and MWA).

### Correspondence address:

Jakub Franke, 2<sup>nd</sup> Department of Radiology, Medical University of Warsaw, Warsaw, Poland, e-mail: [jakub.t.franke@gmail.com](mailto:jakub.t.franke@gmail.com)

### Authors' contribution:

A Study design · B Data collection · C Statistical analysis · D Data interpretation · E Manuscript preparation · F Literature search · G Funds collection

Unfortunately, cryoablation of kidney tumours is not widely available for patients in Poland due to lack of reimbursement by the National Health Fund until April 2023. The purpose of this study is to present the results of the first experiences in cryoablation of renal cell carcinoma in Poland. The secondary aim of the study is to find out what results of percutaneous renal tumour cryoablation can be achieved when the operators have no experience in renal ablation or any cryoablation but do have experience in other CT-guided procedures.

## Material and methods

The study was accepted by the local bioethical committee (approval number AKBE/84/2024) and was conducted according to Declaration of Helsinki. It involved retrospective analysis of prospectively maintained database of renal tumour cryoablations performed between December 2020 and December 2023.

The patients with RCC in T1a stage (up to 4 cm in diameter) were treated with percutaneous cryoablation. All patients were seen by a urologist and disqualified from surgical treatment due to age, comorbidities, or history of nephrectomy. Exclusion criteria were life expectancy < 1 year, international normalised ratio (INR) > 1.5, and platelet counts (PLT) < 50 k/μl. The stage of the disease was confirmed by baseline CT/MR.

Two patients died within 30 days of the procedure; one in the course of complications of stroke and COVID-19 infection, and one due to a ruptured aortic aneurysm. They were not included in the analysis.

Diagnosis was confirmed by CT-guided core needle biopsy that was performed 2-4 weeks before cryoablation. The biopsies were performed with 18G needles using a coaxial technique (at least 2 tissue samples were taken). In 3 patients no biopsy was done due to history of RCC in the contralateral kidney and enhancement pattern on contrast-enhanced CT typical for RCC.

The cryoablations were done using the IceFX system (Boston Scientific, USA). All procedures were performed under general anaesthesia with CT guidance (320-row CT scanner, Toshiba Aquilion One, Toshiba/Canon, Nasu, Japan). The ablations were performed by 2 of 3 interventional radiologists with at least 10 years of experience in CT-guided ablations. The ablation zone was shaped with multiple needles, so it extended beyond the tumour margin by at least 5 mm.

The following cryoablation protocol was applied: 10 minutes freeze, 1 minute active thaw, 10 minutes freeze, 1 minute passive thaw, and 2-4 minutes active thaw (until needles are removed from the patient). When necessary, hydrodissection was done to separate adjacent organs (e.g. colon, adrenal glands, liver) from the ablation zone and to avoid the danger of thermal injury.

Contrast-enhanced CT was done immediately after each procedure to confirm the size of the ablation zone

and to assess for possible complications. In 16 patients contrast-enhanced CT was also done at the beginning of the procedure to improve visibility of the tumour. The remaining 9 patients did not have preprocedural contrast injection due to poor renal function or excellent visibility of the tumour on non-enhanced CT (exophytic tumours).

The follow-up protocol included CT or MR 6 weeks after ablation, then repeated every 3-6 months for a year, and after that once a year.

The following data were collected: patient demographics, tumour characteristics, and course of the procedure. Complications were noted within 30 days of the procedure and classified according to Clavien-Dindo [7]. Follow-up imaging studies were reviewed for complications, local control (defined as lack of enhancement of the ablated tumour), and the presence of metastases.

## Results

Twenty-five patients underwent CT-guided percutaneous cryoablation for a T1a RCC. There were 10 females and 15 males among the patients included in the study. The mean age of the patients was 77 years (range: 43-91). The mean diameter of lesions was 27 mm (range: 15-40 mm).

All RCCs were in T1a stage (up to 4 cm in diameter). Three patients presented with RCC in the only kidney (after nephrectomy due to RCC in the contralateral kidney).

The mean number of ablation needles was 3 (range: 2-4), and it depended mostly on the size of the tumour. The needle size was 17G. In one patient, embolisation was performed before cryoablation due to high vascularity of the tumour. Hydrodissection with 100-500 ml of normal saline was carried out in 8 procedures (Figure 1).

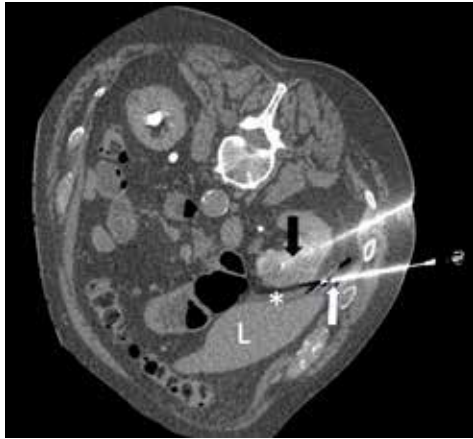
The mean duration of follow-up was 12 months (range: 1-30 months). None of the patients presented with local recurrence or distant progression during the follow-up period (Table 1).

Urine leak was noted in one patient, which required stenting of the ureter and subsided within 2 weeks (Clavien-Dindo grade 3). Otherwise, there were no major post-procedural complications. Minor bleeding was seen in 5 patients, and it subsided in the CT-room within 30 minutes of the procedure, before the patients were transferred to the recovery room (Clavien-Dindo grade 1). None of those patients required intervention or prolonged hospitalisation.

Four out of 25 patients included in the analysis died during the follow-up period. One of them died within 30 days of the cryoablation due to complications after stroke and COVID-19 infection. None of the deaths was directly related to the cryoablation.

## Discussion

Thermal ablation (including cryoablation) is included in major urological and oncological guidelines (AUA, EUA,



**Figure 1.** Cryoablation of renal cell carcinoma. Cryoablation needle – black arrow, hydrodissection needle – white arrow, hydrodissection – asterisk, liver – L

NCCN, ESMO) [3-6] as a method of RCC treatment. It is especially recommended for patients with high surgical risk due to comorbidities, with solitary kidney, compromised kidney function, hereditary RCC, or multiple bilateral tumours [5]. For many years this method has not been available to patients in Poland, mostly due to lack of reimbursement. Our study presents the first experiences of renal cell carcinoma cryoablation in high surgical risk patients in Poland.

One of the major differences between heat-based ablation and cryoablation is the number of needles. There is usually one needle used in RFA/MWA while cryoablation allows the use of multiple needles. This enables to shape the ablation zone to cover the whole tumour at once, even if the lesion is of irregular shape. However, it requires very precise placement of the needles with 1-1.5 cm distance between them; this skill is not necessary in heat-based ablations.

None of the patients presented with local or distant tumour progression (100% progression-free survival). Similar results have been published by Buy *et al.* [8], who reported recurrence-free survival (RFS) at 96.7% after 28 months, Aoun *et al.* [9] reported 96.8% at a mean follow-up of 31.8 months, while Breen *et al.* [10] reported RFS at 97.2% and 93.9% at 3 and 5 years of follow-up, respectively.

One major complication out of 25 procedures (4%) compares favourably with nephron-sparing surgery – 12.6% in the study by Pasticier *et al.* [11] and 9% according to the American Association of Urology meta-analysis [12]. Similar complication rates were reported by Georgiades *et al.* [13] and De Cobelli *et al.* [14].

The results show that a team of interventional radiologists without experience in renal cryoablation but with

**Table 1.** Demographics, procedure data, and results

Number of patients	25
Age	Mean: 77 years, range: 43-91
Sex	10 females and 15 males
Tumour diameter	Mean: 27 mm, range: 15-40 mm
History of prior nephrectomy	3
Pre-procedural contrast injection	18 patients
Number of needles used	Mean: 3, range: 1-4
Hydrodissection	4 procedures
Follow-up duration	Mean: 12 months, range: 1 – 30 months
Minor complications	5 minor bleeds visible on CT, spontaneously subsided
Major complications	1 (urine leak)
Local recurrences	None
Distant recurrences	None

extensive experience in liver ablation and other abdominal CT-guided procedures can still achieve good results. It shows that interventional radiology procedures should be reimbursed and more frequently applied in oncological patients. This applies even more in elderly patients with comorbidities in whom low complication rates are of high importance. Also, in patients with a solitary kidney, an attempt to perform nephron-sparing surgery could lead to radical nephrectomy followed by permanent treatment with dialysis. The good safety profile of percutaneous cryoablation makes such complications highly unlikely. Also, cryoablation can be repeated in cases of local recurrence or a new tumour.

The limitations of the study include the low number of patients and relatively short follow-up period.

Conclusion: The first experiences in percutaneous cryoablation of T1a renal cancer demonstrate similar local control and complication rates to those reported in the literature, showing the high value of interventional radiology procedures in this subgroup of patients.

## Disclosures

1. Institutional review board statement: Approval number AKBE/84/2024.
2. Assistance with the article: None.
3. Financial support and sponsorship: None.
4. Conflicts of interest: None.

## References

1. Global Burden of Disease 2019 Cancer Collaboration; Kocarnik JM, Compton K, Dean FE, Fu W, Gaw BL, Harvey JS, et al. Cancer incidence, mortality, years of life lost, years lived with disability, and disability-adjusted life years for 29 cancer groups from 2010 to 2019: a systematic analysis for the Global Burden of Disease Study 2019. *JAMA Oncol* 2022; 8: 420-444.
2. Wojciechowska U, Barańska K, Miklewska M, Didkowska JA. Cancer incidence and mortality in Poland in 2020. *Nowotwory Journal of Oncology* 2023; 73: 129-145.
3. Motzer RJ, Jonasch E, Agarwal N, Alva A, Baine M, Beckermann K, et al. Kidney cancer, version 3.2022, NCCN clinical practice guidelines in oncology. *J Natl Compr Canc Netw* 2022; 20: 71-90.
4. Ljungberg B, Albiges L, Abu-Ghanem Y, Bedke J, Capitanio U, Dabestani S, et al. European Association of Urology guidelines on renal cell carcinoma: the 2022 update. *Eur Urol* 2022; 82: 399-410.
5. Escudier B, Porta C, Schmidinger M, Rioux-Leclercq N, Bex A, Khoo V, et al. Renal cell carcinoma: ESMO Clinical Practice Guidelines for diagnosis, treatment and follow-up. *Ann Oncol* 2019; 30: 706-720.
6. Campbell SC, Clark PE, Chang SS, Karam JA, Souter L, Uzzo RG. Renal mass and localized renal cancer: evaluation, management, and follow-up: AUA guideline: part I. *J Urol* 2021; 206: 199-208.
7. Dindo D, Demartines N, Clavien PA. Classification of surgical complications: a new proposal with evaluation in a cohort of 6336 patients and results of a survey. *Ann Surg* 2004; 240: 205-213.
8. Buy X, Lang H, Garnon J, Sauleau E, Roy C, Gangi A. Percutaneous renal cryoablation: prospective experience treating 120 consecutive tumors. *AJR Am J Roentgenol* 2013; 201: 1353-1361.
9. Aoun HD, Littrup PJ, Jaber M, Memon F, Adam B, Krycia M, et al. Percutaneous cryoablation of renal tumors: is it time for a new paradigm shift? *J Vasc Interv Radiol* 2017; 28: 1363-1370.
10. Breen DJ, King AJ, Patel N, Lockyer R, Hayesl M. Image-guided cryoablation for sporadic renal cell carcinoma: three- and 5-year outcomes in 220 patients with biopsy-proven renal cell carcinoma. *Radiology* 2018; 289: 554-561.
11. Pasticier G, Timsit MO, Badet L, De La Torre Abril L, Halila M, Fassi Fehri H, et al. Nephron-sparing surgery for renal cell carcinoma: detailed analysis of complications over a 15-year period. *Eur Urol* 2006; 49: 485-490.
12. Campbell SC, Novick AC, Belldgrun A, Blute ML, Chow GK, Derweesh IH, et al. Guideline for management of the clinical T1 renal mass. *J Urol* 2009; 182: 1271-1279.
13. Georgiades CS, Rodriguez R. Efficacy and safety of percutaneous cryoablation for stage 1A/B renal cell carcinoma: results of a prospective, single-arm, 5-year study. *Cardiovasc Intervent Radiol* 2014; 37: 1494-1499.
14. De Cobelli F, Papa M, Panzeri M, Colombo M, Steidler S, Ambrosi A, et al. Percutaneous microwave ablation versus cryoablation in the treatment of T1a renal tumors. *Cardiovasc Intervent Radiol* 2020; 43: 76-83.