

# Experience with Kaposi Sarcoma Herpesvirus Inflammatory Cytokine Syndrome in a Large Urban HIV Clinic in the United States: Case Series and Literature Review

Valeria D. Cantos,<sup>1</sup> Aley G. Kalapila,<sup>1</sup> Minh Ly Nguyen,<sup>1</sup> Marylyn Adamski,<sup>2</sup> and Clifford J. Gunthel<sup>1</sup>

<sup>1</sup>Division of Infectious Diseases, Emory University, Atlanta, Georgia; <sup>2</sup>Grady Health System Ponce de Leon Center, Atlanta, Georgia

In 2010, a new entity, characterized by the classical signs and symptoms of Kaposi sarcoma herpesvirus–associated multicentric Castleman’s disease (KSHV-MCD) in the absence of pathologic evidence of MCD, was described in individuals living with HIV. This syndrome was named KSHV inflammatory cytokine syndrome (KICS). It carries mortality rates of up to 60%. To date, there are no standard therapies. Treatment regimens studied in clinical trials for MCD disease are used in cases of KICS.

**Keywords.** HIV; KSHV inflammatory cytokine syndrome; KICS.

Kaposi sarcoma herpesvirus (KSHV, or human herpesvirus 8) is known to cause multiple malignancies in individuals living with human immunodeficiency virus (HIV) [1], especially in men who have sex with men (MSM) with uncontrolled HIV viremia and CD4 lymphopenia [2]. KSHV-related disorders represent a heterogeneous group of illnesses that includes Kaposi sarcoma (KS), primary effusion lymphoma (PEL), and multicentric Castleman’s disease (KSHV-MCD) [1–3]. In 2010, Uldrick retrospectively described 6 patients who were co-infected with HIV and KSHV, who exhibited classic KSHV-MCD inflammatory signs and symptoms, without pathologic evidence or radiographic findings associated with MCD [4]. This syndrome was named KSHV inflammatory cytokine syndrome (KICS). Since then, 11 more cases that fulfill the working case definition have been described in the literature (Table 1) [5].

Georgia is among the top 5 states in the United States with the highest incidence of HIV infections, and Atlanta is at its epicenter [6]. African American men, who account for 75% of all HIV infections in the state [7], are particularly susceptible to KSHV-related illnesses [8]. The Grady Health System’s Infectious Disease Program at the Ponce de Leon Center (IDP) in Atlanta serves approximately 5800 individuals living with HIV; 82% of them are African American (V. Marconi, oral

communication, 2017). Since 2010, there have been more than 200 cases of KSHV-related diseases diagnosed and treated at IDP. Some of those cases exhibited clinical features suggestive of KICS.

In this series, we describe 2 cases that fulfill the working case definition of KICS and describe their clinical characteristics and outcomes. We compare them with existing reported cases and review the literature on KICS focusing on pathophysiology, diagnosis, and treatment.

## Case 1

A 32-year-old male with HIV/AIDS and KS diagnosed 4 years prior to presentation was admitted to the hospital with fever, fatigue, dry cough, shortness of breath, and anasarca (Supplementary Table 1). He was not linked to care at the time of his initial HIV diagnosis and had never received antiretroviral therapy (ART). There was also a history of untreated chronic hepatitis C and polysubstance abuse of cocaine and methamphetamines. His CD4 cell count on admission was 257 cells/ $\mu$ L (17%), and his serum HIV RNA was 26 650 copies/mL (4.43 log<sub>10</sub>). Other relevant laboratory abnormalities are detailed in Supplementary Table 2. A computed tomography (CT) scan of his chest showed large bilateral pleural effusions along with bilateral axillary and mediastinal lymphadenopathy. A CT scan of the abdomen/pelvis revealed splenomegaly with multiple low-density lesions, lytic lesions in the lumbar spine, diffuse lymphadenopathy, and ascites (Figure 1). A diagnostic and therapeutic thoracentesis was performed. Cytology and flow cytometry of pleural fluid were negative for PEL. An excisional right inguinal lymph node biopsy was consistent with KS, without histologic evidence of KSHV-MCD. A presumptive diagnosis of KICS was made, and chemotherapy with liposomal doxorubicin and rituximab was started. Concomitantly, ART

Received 3 July 2017; editorial decision 7 September 2017; accepted 11 September 2017.

Correspondence: V. D. Cantos, MD, Grady Health System Ponce de Leon Center, 341 Ponce de Leon Ave NE, Atlanta, GA, 30308 (vcantos@emory.edu).

## Open Forum Infectious Diseases®

© The Author 2017. Published by Oxford University Press on behalf of Infectious Diseases Society of America. This is an Open Access article distributed under the terms of the Creative Commons Attribution-NonCommercial-NoDerivs licence (<http://creativecommons.org/licenses/by-nc-nd/4.0/>), which permits non-commercial reproduction and distribution of the work, in any medium, provided the original work is not altered or transformed in any way, and that the work is properly cited. For commercial re-use, please contact [journals.permissions@oup.com](mailto:journals.permissions@oup.com). DOI: 10.1093/ofid/ofx196

**Table 1. Working Case Definition of KSHV Inflammatory Cytokine Syndrome**

1. Clinical Manifestations	
a. Symptoms	b. Laboratory Abnormalities
Fever	Anemia
Fatigue	Thrombocytopenia
Edema	Hypoalbuminemia
Cachexia	Hyponatremia
Respiratory symptoms	c. Radiographic abnormalities
Gastrointestinal disturbances	Lymphadenopathy
Arthralgia and myalgia	Splenomegaly
Altered mental state	Hepatomegaly
Neuropathy with or without pain	Body cavity effusions
2. Evidence of systemic inflammation	
Elevated C-reactive protein ( $\geq 3$ mg/L)	
3. Evidence of KSHV viral activity	
Elevated KSHV viral load ( $\geq 1000$ copies/mL) or peripheral blood mononuclear cells ( $\geq 100$ copies/ $10^6$ cells)	
4. No evidence of KSHV-associated multicenter Castleman's disease	
Exclusion of MCD requires histopathological assessment of lymphadenopathy if present	

The working case definition requires the presence of at least 2 clinical manifestations from at least 2 categories (1a, b, and c), together with each of the criteria in 2, 3, 4. Reproduced with permission from Dr. Yarchoan

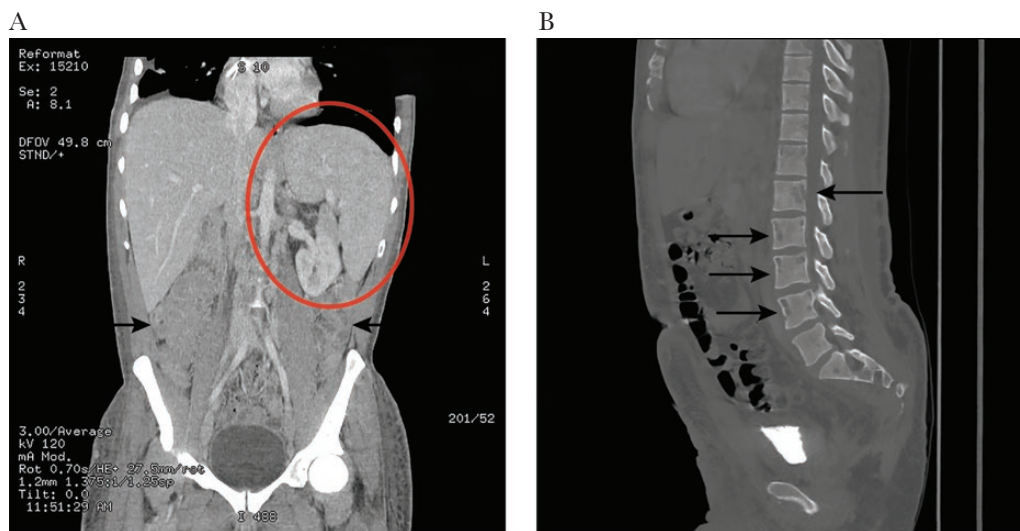Abbreviations: KSHV, Kaposi sarcoma herpesvirus; MCD, multicenter Castleman's disease [5].

was initiated with tenofovir disoproxil fumarate (TDF), emtricitabine (FTC), darunavir, and ritonavir. Despite initial issues with adherence, his HIV RNA became undetectable (more than 4 log<sub>10</sub> reduction from baseline) and his CD4 count increased from 257 cells/ $\mu$ L (17%) to 327 cells/ $\mu$ L (41%) within 4 months of starting ART.

He responded well to chemotherapy, with resolution of fever, improvement of pulmonary symptoms, regression of peripheral lymphadenopathy, and stabilization of cutaneous lesions.

Considering his clinical improvement and a new onset of hyperbilirubinemia on follow-up laboratory tests, chemotherapy was held after 12 cycles (9 months). Hyperbilirubinemia resolved soon after. Three months later, he was admitted to the hospital with recurrent anasarca, severe anemia, thrombocytopenia, and new bilateral lytic lesions in the femoral heads. The work-up for other opportunistic infections, including cytomegalovirus (CMV), mycobacterium avium complex (MAC), and histoplasma capsulatum, was negative. Quantitative levels of serum KSHV polymerase chain reaction (PCR) and human interleukin-6 (hIL-6) were measured: KSHV PCR was 20 815 copies/mL, and hIL-6 level was 6 times higher than the upper normal limit (Supplementary Table 2). Liposomal doxorubicin and rituximab were restarted. Despite 4 cycles of this combination therapy, new KS skin lesions continued to develop. His chemotherapy regimen was then changed to paclitaxel. He completed 4 cycles, and his disease stabilized. Four months later, he again presented with fever, new skin lesions, worsening peripheral neuropathy, anemia, and thrombocytopenia. Liposomal doxorubicin and rituximab were resumed, and there was clinical improvement after 4 cycles of this combination therapy.

Due to chronic lower extremity lymphedema associated with KS, the patient had persistent nonhealing ulcers in his feet, which progressed to chronic osteomyelitis. His clinical course was complicated by recurrent episodes of sepsis, presumably from this site of infection. Cultures of the exudate from these ulcers grew methicillin-resistant *Staphylococcus aureus* (MRSA) and *Escherichia coli*, for which he received multiple rounds of broad-spectrum antibiotics. During his last admission, he completed a course of piperacillin/tazobactam and vancomycin. He was then lost to medical follow-up. A few months later, he received a report of his death. The details and circumstances of



**Figure 1.** Computed tomography of abdomen/pelvis (case 1). (A) Splenomegaly (red circle) and lymphadenopathy (black arrows). (B) Vertebral lytic lesions (black arrows).

**Table 2. Comparison Between KICS, KSHV-MCD, and KS-IRIS**

	KICS	KSHV-MCD	KS-IRIS
Required preexisting diagnoses	KS/PEL HIV	KS/PEL HIV	KS/PEL HIV
Definition	MCD-like systemic inflammation in the absence of pathologic evidence of MCD	Lymphoproliferative disorder characterized by KSHV-infected plasmablasts and by recurrent flares of systemic inflammation and KSHV viremia [26]	Acute progression of preexisting lesions, development of new lesions, involvement of new systems (gastrointestinal, pulmonary, lymphatic) after starting ART
Histopathological findings	Lymph node: KS infiltration or reactive hyperplasia [5] Bone marrow: increased cellularity, reactive plasmacytosis, scattered KSHV-infected plasma cells [5]	Lymph node: hypocellular germinal centers and KSHV-infected, polyclonal plasmacytoid cells in the interfollicular area [10]	Typical KS findings: vascular channels, spindle cells, extravasated RBCs, hemosiderin-containing macrophages [29]
KSHV viremia during symptoms	High [10]	High [10]	Low [22]
Temporal association with ART initiation	No	No	Yes, within 14 wk [21]
Cytokine pattern	High hIL-6, vIL-6, and IL-10 <sup>2</sup>	High hIL-6, vIL-6, and IL-10 <sup>11</sup>	Unknown
HIV viremia	High	Low	Low
CD4 count	<100	>200	Increase >50 cells/μL from pre-ART levels [21]

Abbreviations: ART, antiretroviral therapy; KICS, KSHV inflammatory cytokine syndrome; KS, Kaposi sarcoma; KSHV, Kaposi sarcoma herpesvirus; KS-IRIS: Kaposi sarcoma-immune reconstitution inflammatory syndrome; MCD, multicenter Castleman's disease; PEL, primary effusion lymphoma; RBC, red blood cell.

his demise could not be obtained, despite multiple attempts to contact his family.

### Case 2

A previously healthy 28-year-old male presented to the hospital with intermittent fever, unintentional weight loss, nausea, vomiting, headache, and diffuse lymphadenopathy for 4 months (Supplementary Table 1). A fourth-generation HIV screening test performed in the emergency department was positive. His CD4 cell count was 92 cells/μL (7%), and his serum HIV RNA was 1 044 110 copies/mL (6.02 log<sub>10</sub>). Laboratory abnormalities are detailed in Supplementary Table 2. Given the concern for possible HIV-associated lymphoproliferative disorders, a whole-body positron emission tomography–CT (PET-CT) was obtained. It showed diffuse hypermetabolic lymphadenopathy and splenomegaly. A lumbar puncture and a brain magnetic resonance image (MRI) were noninformative. Inguinal and axillary lymph node excisional biopsies demonstrated prominent follicular involution and were negative for KS or any lymphoproliferative disorders. MCD was excluded based on histological examination, negative KSHV immunostain, and absent clonal B- or atypical T-cell populations on flow cytometry. No infectious agents were identified to explain his clinical presentation. His fevers and headaches resolved spontaneously, and he was discharged home. Ten days later, he was readmitted with fevers up to 40.5°C, fatigue, and a dry cough. Biopsies of suspicious skin and tonsillar lesions both showed KS. A bone marrow biopsy demonstrated hypercellular marrow with granulocytic hyperplasia, without evidence of any infectious or lymphoproliferative processes. Quantitative levels of serum KSHV PCR and hIL-6 were measured: KSHV PCR was 4 347 752

copies/mL, and hIL-6 was 6 times higher than the upper normal limit (Supplementary Table 2). A presumptive diagnosis of KICS was made, and he was started on combination chemotherapy with liposomal doxorubicin and rituximab. ART, with tenofovir disoproxil fumarate, emtricitabine, elvitegravir, and cobicistat, was started prior to his hospital discharge.

He received 4 cycles of combination chemotherapy, with good response. After 5 additional cycles of liposomal doxorubicin, chemotherapy was discontinued. The decision to hold therapy was based on resolution of systemic symptoms, regression of all KS lesions, and a decrease in left ventricular ejection fraction (from 54% to 49%), evidenced in a multigated acquisition (MUGA) scan. Due to inconsistent adherence with ART, HIV viremia persisted for 7 months after initiating therapy. An HIV genotype revealed a new M184I mutation. Darunavir was then added to his regimen. Six months later, his HIV VL was undetectable. Within the first 3 months of ART, his CD4 count increased from 92 cells/μL (7%) to 191 cells/μL (14%) and stabilized in that range. He remains alive and well, and has not had further recurrence of KICS-like symptoms.

### LITERATURE REVIEW

We presented 2 cases that fulfill the working case definition of KICS and reviewed the existing literature. To date, there are 16 reported cases of KICS in HIV patients, all from the National Institutes of Health (NIH). There is an additional case series of 6 pediatric patients in Malawi described as having KICS [9]; however, MCD was excluded by histopathology in only 1 of the cases. As per the working case definition of KICS [5], MCD must be ruled out by histopathological examination.

### Case Definition and Clinical Presentation

In 2005, Dagna et al. reported a case of an HIV-negative woman in Italy who presented with recurrent episodes of MCD-like symptoms including fever, edema, diffuse lymphadenopathy, splenomegaly, arthrosynovitis, rash, and anemia. This case was associated with KSHV viremia and cutaneous KS, without histopathological evidence of MCD [11]. As with our first patient, this case was also characterized by a relapsing and remitting disease course. Improvement in symptoms and laboratory abnormalities followed chemotherapy with liposomal daunorubicin, an anthracycline chemotherapeutic agent similar to doxorubicin. In 2010, Uldrick reported 6 US cases of HIV-infected patients with MCD-like symptoms and laboratory abnormalities consistent with MCD, but without pathologic evidence of MCD on excisional lymph node or bone marrow biopsies [4]. Based on these findings, a working case definition for KICS was created by a group of scientific experts at the NIH (Table 1) [5]. In 2015, Polizzotto prospectively compared 10 HIV-infected patients in the United States who had at least 1 symptom or laboratory derangement included in the KICS definition (KICS group) with 2 other groups of patients: 20 HIV-infected individuals who had evidence of KSHV infection, defined as having positive KSHV serology or positive tissue expression of KSHV viral antigens (KSHV + HIV group) and 20 patients who had HIV with no evidence of KSHV infection (HIV only) [5]. The latter 2 groups were further stratified based on their HIV control (controlled vs uncontrolled). Clinically, KICS patients had a median of 8 concomitant symptoms, which were usually severe and required hospitalization. The majority of them experienced extreme fatigue, gastrointestinal symptoms, and edema. On the contrary, the subjects in the “KSHV + HIV” and the “HIV only” groups were generally asymptomatic. Anemia and hypoalbuminemia were present in all KICS subjects, while only 10% to 40% of the patients in the other groups had such abnormalities. Notably, all the KICS patients had KSHV viremia, unlike the other 2 groups.

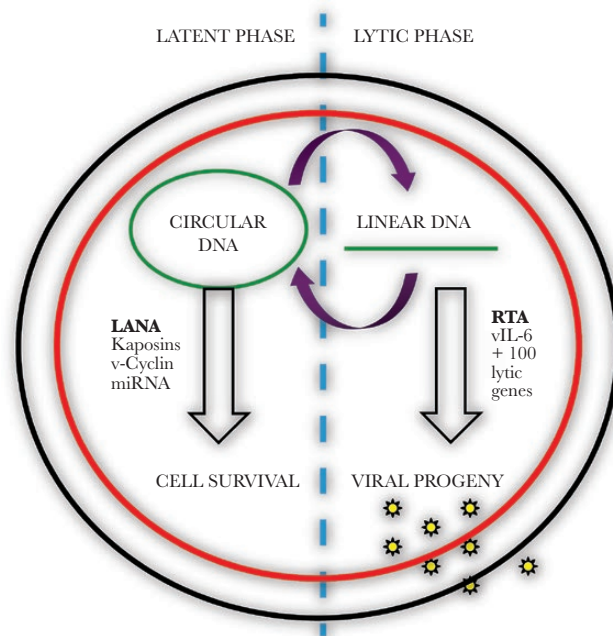
Both of our patients fulfilled the working case definition for KICS. Similar to Uldrick’s and Polizzotto’s cohorts, fatigue, gastrointestinal disturbances, and respiratory symptoms were noted in our cases. Fever, a less common finding in their cohort, was documented in both our cases. Supplemental Table 2 provides a detailed comparison of the clinical findings of our patients compared with Uldrick’s and Polizzotto’s cases [5, 10].

Morbidity and mortality rates are high in patients with KICS. In Uldrick’s retrospective case series, 50% (3 out of 6) of the patients died within a period of 3 to 7.5 months [4]. The causes of death included diffuse alveolar hemorrhage with associated thrombocytopenia, progressive KS despite combination chemotherapy with either liposomal doxorubicin and interleukin-12 (IL-12) or with valgancyclovir and zidovudine, and, as with our first case, progressive KS complicated by infections [4]. In Polizzotto’s prospective case series, 60% (6 out of 10) of

the KICS patients died within the 2-year follow-up period, compared with only 1 death in the other 2 groups (1 out of 40 patients). Four of these deaths were due to progressive tumors, either KS or PEL, while the cause for 2 of the deaths could not be determined [5].

### Pathophysiology

Much of the current knowledge on the pathophysiology of KICS is based on studies of the molecular biology of KSHV (Figure 2) and its relationship with HIV-MCD. KSHV is a gamma-2 herpesvirus. Its genome consists of a linear double-stranded DNA (dsDNA), which “closes up” to become an episome once it reaches the host cell’s nucleus [12]. The life cycle of KSHV involves 2 phases of infection: a reversible sustained latent phase and a transient lytic phase (Figure 2) [13]. The latent phase is characterized by the translation of only a few genes from the episomal DNA that promote cell survival and proliferation, including the latency-associated nuclear antigen (ORF73/LANA), ORF71v-FLIP, ORFK12/Kaposins, and ORF72/v-Cyclin genes [14]. Additionally, microRNAs (miRNAs), which are also expressed during this phase, are involved in the maintenance of KSHV viral latency, optimization of angiogenesis, and dissemination of KSHV-infected cells [15]. The ability of KSHV to persist latently within endothelial cells has been associated with the development of KS [16].



**Figure 2.** Kaposi sarcoma herpesvirus life cycle. Kaposi sarcoma herpesvirus is predominantly in a latent phase, where its genome is found as an episome. Only a few genes are expressed, most of them to optimize cell survival. Intermittently, the episome “opens up” and the virus enters a lytic phase, during which hundreds of lytic genes are expressed in order to produce viral progeny. LANA, latency-associated nuclear antigen; v-Cyclin, viral Cyclin; miRNA, microRNA; RTA, replication and transcription activator; v-IL6, viral interleukin. Figure inspired by Purushothaman et al. [30].



The lytic phase occurs during primary infection or when KSHV reactivates from the latent phase. It is facilitated by the replication and transcription activator protein (RTA) [17]. During this phase, the viral genome “opens up,” activating the expression of more than 100 genes. The resulting proteins are essential for viral DNA replication and for the production of progeny virions, which can go on to infect other host cells [17].

Viral interleukin 6 (vIL-6) is another lytic protein implicated in the pathogenesis of MCD [18]. It is a homologue of the human pro-inflammatory cytokine hIL-6. These IL-6 homologues have similar structural characteristics and biological functions, including suppression of regulatory T (Treg) cell function, recruitment of neutrophils and macrophages, induction of hepatic acute phase response, and tissue damage [19]. vIL-6, although less potent than h-IL6, has the capacity to bind the trans-membrane protein gp-130, which is ubiquitously found in human cells. In this way, it can bypass the IL-6 receptor and still exert its functions [10]. Moreover, v-IL6 can induce the production of h-IL6 by uninfected cells [18].

Interleukin 10 (IL-10) has been found within KS, PEL, and MCD tumors, and its production is thought to be activated by KSHV-associated miRNAs [20]. It is an anti-inflammatory cytokine that prevents the maturation of dendritic cells, inhibits T cell activation, and decreases the cytotoxic activity of macrophages. These immune regulatory effects contribute to the transformation to and persistence of KSHV-related malignancies [20].

In Uldrick's retrospective study, serum levels of vIL-6, hIL-6, IL-10, and levels of KSHV viral load (VL) in peripheral mononuclear cells (PBMCs) were compared in 4 groups of HIV-infected individuals: 6 patients who had KSHV MCD-like signs and symptoms without histopathological evidence of MCD (KICS group), those with confirmed MCD ( $n = 8$ ), 24 patients with severe KS (without signs or symptoms of systemic inflammation), and those with mild KS ( $n = 8$ ). The serum concentration of all the cytokines was 1 to 2  $\log_{10}$  higher in both the KICS group and the MCD group when compared with the mild and severe KS groups. The same pattern was observed with serum KSHV VL; subjects with KICS and with MCD had a KSHV VL that was 2  $\log_{10}$  higher than the subjects with severe KS, and 5  $\log_{10}$  higher than subjects with mild KS. Importantly, there were no statistical differences in HIV VL between the 4 groups [4]. Polizzotto confirmed these findings in his prospective study: levels of hIL-6 and IL-10 were significantly higher in the KICS group compared with HIV-KSHV co-infected patients and HIV-infected individuals with no evidence of KSHV infection [5]. These findings were consistent, irrespective of whether the subjects had HIV viral suppression. This suggests that the clinical symptoms and laboratory abnormalities seen in KICS patients are most likely due to a cytokine-induced pro-inflammatory state caused by KSHV in the lytic phase, and not from

uncontrolled HIV. Similarly, in our first case, we measured KSHV VL and serum hIL-6 at the time of his first recurrence of symptoms, when his HIV VL was suppressed. Both KSHV VL and hIL-6 were elevated, further supporting the findings of the NIH group that KSHV viremia in the setting of active viral replication is likely driving this inflammatory state.

The recurrent episodes of KICS-like symptoms of our first patient raised initial concern for paradoxical Kaposi sarcoma-immune reconstitution inflammatory syndrome (KS-IRIS). The clinical presentation of KICS can resemble the signs and symptoms observed in cases of KS-IRIS. These include progression of preexisting lesions, development of new lesions, involvement of new organ systems, and anasarca due to lymphatic infiltration [21]. Our patient had a rapid decline of his HIV VL after starting ART (more than 4  $\log_{10}$  in 3 months) and a 70-cell increase in his CD4 counts. These numbers are comparable with the findings of Letang et al. in a Mozambique cohort, where the patients who develop KS-IRIS had a median HIV VL reduction of 2.52  $\log_{10}$  and a median CD4 count increase of 95 cells/ $\mu\text{L}$  from pre-ART levels [22]. Furthermore, our patient had at least 3 of the 4 KS-IRIS predictors described by Letang: presence of clinical KS pre-ART, hematocrit of less than 30%, high pre-ART HIV VL, and detectable pre-ART serum KSHV DNA (not available in our patient) [22]. However, there are important aspects of this patient's presentation that distinguish it from KS-IRIS. First, KS-IRIS is characterized by a temporal relationship with ART initiation, usually within the first 14 weeks of starting ART [21]. Our patient had KICS-like symptoms prior to ART initiation. Also, the development of new lesions and recrudescence of symptoms continued long after his HIV VL was undetectable and his CD4 count stabilized, which would be unusual for KS-IRIS. Finally, in cases of KS-IRIS, KSHV VL tends to decrease compared with pre-ART values, while in cases of KICS, KSHV VL is usually high when symptoms arise [5,22]. Although we don't have a KSHV VL level during the initial presentation of our first patient, it was high when he exhibited symptoms at the time of his first recurrence. In summary, we believe that the clinical presentation of our patient was more consistent with KICS than with KS-IRIS. However, as noted by Polizzotto, the distinction between cases of KICS and KS-IRIS may be difficult to determine. The cytokine pattern seen in cases of KS-IRIS warrants further investigation. Similarly, despite the similarities of KSHV-MCD and KICS, there are notable differences. Patients with KICS tend to have low CD4 counts (less than 100 cells/ $\mu\text{L}$ ) and uncontrolled HIV viremia, while KSHV-MCD commonly occurs in patients with HIV viral suppression and higher CD4 counts (above 200 cells/ $\mu\text{L}$ ) [4,5,23]. The immune mechanisms to account for these observed disparities have not yet been elucidated. [Table 2](#) compares the distinguishing features of KICS, KSHV-MCD, and KS-IRIS.

## Treatment

To date, there are no standard therapies for KICS. Given the similarities in pathophysiology between MCD and KICS, researchers have suggested treatment strategies that have been previously studied in clinical trials for MCD [10]. These include rituximab and liposomal doxorubicin [24] or high-dose zidovudine and valganciclovir [25]. In 2007, Gerard et al. evaluated the efficacy of rituximab monotherapy in treating MCD based upon the rationale that rituximab would eliminate the reservoir of CD 20-positive KSHV-infected plasmablasts [26]. In this open-label phase II study of 24 patients, 92% had sustained resolution of symptoms at 60 days. However, more than one-third of the participants developed worsening KS. This phenomenon could be explained by rituximab-induced depletion of CD20+ B lymphocytes, disrupting the interaction between B and T lymphocytes, ultimately causing the dysfunction of T cell-mediated immunity against KS [27, 28]. Uldrick then added liposomal doxorubicin, a firstline chemotherapeutic agent for KS, to rituximab and treated 17 patients with MCD [24]. More than 90% of the subjects had major clinical responses, and 88% had major biochemical responses, namely a reduction in KSHV viremia ( $4 \log_{10}$ ), CRP (3 mg/L), h-IL6 ( $0.5 \log_{10}$ ), and IL-10 ( $1.68 \log_{10}$ ). An improvement of cytopenias and hypoalbuminemia was also observed. Only 1 patient experienced worsening KS. The event-free survival at 1 year was 81.6%, and it was 69% at 2 years and beyond.

A 7-day regimen of high-dose zidovudine (AZT; 600 mg every 6 hours) plus valganciclovir (900 mg every 12 hours) was evaluated as treatment for KSHV-MCD in 14 HIV-positive patients in a pilot study in 2011 [25]. Both these drugs are phosphorylated to cytotoxic compounds by 2 proteins that are translated from KSHV lytic genes, ORF21 and ORF37, expressed in KSHV-infected plasmablasts. Phosphorylated zidovudine and valganciclovir are thought to accumulate within the plasmablast, causing its death. Notably, the dose of AZT used in this trial was 6 times higher than the standard dose used for HIV treatment (300 mg every 12 hours). Three patients had complete overall response in all parameters (clinical, biochemical, and radiographic), 1 patient had partial overall response (at least 50% improvement in all parameters), and 1 patient had progressive disease. The remaining 9 patients did not meet criteria for either complete or partial response or progressive disease and were classified as having stable disease. Levels of hIL-6, IL-10, and KSHV VL had a statistically significant decrease from baseline even though it was only a 2- to 3-fold reduction. Not surprisingly, bone marrow suppression and gastrointestinal side effects were frequently observed and were the major limiting factors of this treatment strategy.

The patients described in this series were treated with liposomal doxorubicin and rituximab, with good initial clinical responses. However, the first patient experienced 2 recurrences of symptoms, leading to re-initiation of chemotherapy. He eventually died from unknown causes. The second patient has not had any relapses of KSHV-associated disease to date.

In conclusion, KICS is a newly described entity that carries significant morbidity and mortality rates of up to 60% [5]. Unlike other opportunistic diseases, it can persist despite good control of HIV viremia and immune reconstitution. Providers who take care of people living with HIV should familiarize themselves with this syndrome. KICS should be included in the differential diagnosis in patients with advanced AIDS presenting with systemic signs and symptoms of inflammation, especially those who have KS and/or PEL. The ongoing NIH study addressing the natural history of KICS as well as different treatment strategies (NCT01419561 and NCT02659930) will shed further light on this newly recognized entity.

## Supplementary Data

Supplementary materials are available at *Open Forum Infectious Diseases* online. Consisting of data provided by the authors to benefit the reader, the posted materials are not copyedited and are the sole responsibility of the authors, so questions or comments should be addressed to the corresponding author.

## Acknowledgement

**Potential conflicts of interest.** All authors: no reported conflicts of interest.

All authors have submitted the ICMJE Form for Disclosure of Potential Conflicts of Interest. Conflicts that the editors consider relevant to the content of the manuscript have been disclosed.

## References

1. Pinzone MR, Berretta M, Cacopardo B, Nunnari G. Epstein-barr virus- and Kaposi sarcoma-associated herpesvirus-related malignancies in the setting of human immunodeficiency virus infection. *Semin Oncol* **2015**; 42:258–71.
2. Bhutani M, Polizzotto MN, Uldrick TS, Yarchoan R. Kaposi sarcoma-associated herpesvirus-associated malignancies: epidemiology, pathogenesis, and advances in treatment. *Semin Oncol* **2015**; 42:223–46.
3. Goncalves PH, Ziegelbauer J, Uldrick TS, Yarchoan R. Kaposi sarcoma herpesvirus-associated cancers and related diseases. *Curr Opin HIV AIDS* **2017**; 12:47–56.
4. Uldrick TS, Wang V, O'Mahony D, et al. An interleukin-6-related systemic inflammatory syndrome in patients co-infected with Kaposi sarcoma-associated herpesvirus and HIV but without Multicentric Castlemans disease. *Clin Infect Dis* **2010**; 51:350–8.
5. Polizzotto MN, Uldrick TS, Wyvill KM, et al. Clinical features and outcomes of patients with symptomatic Kaposi Sarcoma Herpesvirus (KSHV)-associated inflammation: prospective characterization of KSHV inflammatory cytokine syndrome (KICS). *Clin Infect Dis* **2016**; 62:730–8.
6. Georgia Department of Public Health. Adult (Core) HIV/AIDS Surveillance Summary. **2015**. Available at: <https://dph.georgia.gov/adult-core-hivaids-surveillance>. Accessed 1 April 2017.
7. Centers for Disease Control and Prevention. Georgia - 2015 State Health Profile. **2015**. Available at: [https://www.cdc.gov/nchhstp/stateprofiles/pdf/Georgia\\_profile.pdf](https://www.cdc.gov/nchhstp/stateprofiles/pdf/Georgia_profile.pdf). Accessed 5 May 2017.
8. Friedman-Kien AE, Saltzman BR. Clinical manifestations of classical, endemic African, and epidemic AIDS-associated Kaposi's sarcoma. *J Am Acad Dermatol* **1990**; 22:1237–50.
9. Kamiyango W, Dittmer D, Kovarik C, et al. Kaposi sarcoma inflammatory cytokine syndrome (KICS) in HIV-infected children in Malawi, a distinct clinical presentation characterized by interleukin-6 related viral pathophysiology. *Br J Haematol* **2015**; 171:79.
10. Polizzotto MN, Uldrick TS, Hu D, Yarchoan R. Clinical manifestations of Kaposi sarcoma herpesvirus lytic activation: multicentric Castlemans disease (KSHV-MCD) and the KSHV inflammatory cytokine syndrome. *Front Microbiol* **2012**; 3:73.
11. Dagna L, Broccolo F, Paties CT, et al. A relapsing inflammatory syndrome and active human herpesvirus 8 infection. *N Engl J Med* **2005**; 353:156–63.
12. Purushothaman P, Dabral P, Gupta N, et al. KSHV genome replication and maintenance. *Front Microbiol* **2016**; 7:54.
13. Kaye KM. 143 - Kaposi's Sarcoma-associated herpesvirus (human herpesvirus 8) A2 - Bennett, John E. In: Dolin R, Blaser MJ, eds. *Mandell, Douglas, and Bennett's Principles and Practice of Infectious Diseases*. 8th ed. Philadelphia: Content Repository Only; **2015**:1777–1782.e1772.

14. Juillard F, Tan M, Li S, Kaye KM. Kaposi's sarcoma herpesvirus genome persistence. *Front Microbiol* **2016**; 7:1149.
15. Qin J, Li W, Gao SJ, Lu C. KSHV microRNAs: tricks of the devil. *Trends Microbiol*. **2017**; 25(8):648–61.
16. Chen L, Lagunoff M. Establishment and maintenance of Kaposi's sarcoma-associated herpesvirus latency in B cells. *J Virol* **2005**; 79:14383–91.
17. Purushothaman P, Uppal T, Verma SC. Molecular biology of KSHV lytic reactivation. *Viruses* **2015**; 7:116–53.
18. Polizzotto MN, Uldrick TS, Wang V, et al. Human and viral interleukin-6 and other cytokines in Kaposi sarcoma herpesvirus-associated multicentric Castleman disease. *Blood* **2013**; 122:4189–98.
19. Rincon M. Interleukin-6: from an inflammatory marker to a target for inflammatory diseases. *Trends Immunol* **2012**; 33:571–7.
20. Qin Z, Kearney P, Plaisance K, Parsons CH. Pivotal advance: Kaposi's sarcoma-associated herpesvirus (KSHV)-encoded microRNA specifically induce IL-6 and IL-10 secretion by macrophages and monocytes. *J Leukoc Biol* **2010**; 87:25–34.
21. Letang E, Lewis JJ, Bower M, et al. Immune reconstitution inflammatory syndrome associated with Kaposi sarcoma: higher incidence and mortality in Africa than in the UK. *AIDS* **2013**; 27:1603–13.
22. Letang E, Almeida JM, Miró JM, et al. Predictors of immune reconstitution inflammatory syndrome-associated with Kaposi sarcoma in Mozambique: a prospective study. *J Acquir Immune Defic Syndr* **2010**; 53:589–97.
23. Bower M, Newsom-Davis T, Naresh K, et al. Clinical features and outcome in HIV-associated multicentric Castleman's disease. *J Clin Oncol* **2011**; 29:2481–6.
24. Uldrick TS, Polizzotto MN, Aleman K, et al. Rituximab plus liposomal doxorubicin in HIV-infected patients with KSHV-associated multicentric Castleman disease. *Blood* **2014**; 124:3544–52.
25. Uldrick TS, Polizzotto MN, Aleman K, et al. High-dose zidovudine plus valganciclovir for Kaposi sarcoma herpesvirus-associated multicentric Castleman disease: a pilot study of virus-activated cytotoxic therapy. *Blood* **2011**; 117:6977–86.
26. Gérard L, Bérezné A, Galicier L, et al. Prospective study of rituximab in chemotherapy-dependent human immunodeficiency virus associated multicentric Castleman's disease: ANRS 117 CastlemaB Trial. *J Clin Oncol* **2007**; 25:3350–6.
27. Clifford KS, Demierre MF. Progression of classic Kaposi's sarcoma with rituximab. *J Am Acad Dermatol* **2005**; 53:155–7.
28. Pantanowitz L, Früh K, Marconi S, et al. Pathology of rituximab-induced Kaposi sarcoma flare. *BMC Clin Pathol* **2008**; 8:7.
29. Johnson R, Horwitz SN, Frost P. Disseminated Kaposi's sarcoma in a homosexual man. *JAMA* **1982**; 247:1739–41.
30. Purushothaman P, Dabral P, Gupta N, et al. KSHV genome replication and maintenance. *Front Microbiol* **2016**; 7:54.