

## Isolated Orbital Roof Fracture: Can It Be Catastrophic?

### Abstract

Orbital encephalocele is a rare catastrophic complication of orbital roof fractures. Early diagnosis of this posttraumatic orbital encephalocele is very crucial because this condition if untreated leads to rapid loss of vision. Whenever displaced orbital roof fracture is identified in a head injury patient, an orbital encephalocele should be suspected. Although magnetic resonance imaging is the investigation of choice, computed tomography of orbit with thin axial and coronal sequences often gives the diagnosis. Frontobasal approach is the most commonly used surgical approach. Supra-transorbital approach is a minimally invasive alternative. Good results with regard to the orbital symptoms can be expected.

**Keywords:** Frontobasal approach, intraocular pressure, orbital encephalocele, supra-transorbital approach

### Introduction

Isolated orbital roof fractures are rare. These fractures are usually seen in motor vehicle accidents with blunt injury to the forehead or sides of the orbit. Most of these fractures heal without any complications.<sup>[1,2]</sup>

Orbital encephalocele is one of the rare but catastrophic complications of orbital roof fractures. Only a limited number of cases have been reported with a study published in 2016 stating number of such cases to be 25.<sup>[3]</sup> Early diagnosis of orbital encephalocele is very crucial because this condition if untreated leads to rapid loss of vision. Here, we report a case of orbital “blow-in” fracture with orbital encephalocele.

### Methods

The clinical and radiological features and surgical findings of a case of orbital encephalocele treated in our hospital have been reviewed. Published cases in the literature have been analyzed and reported here.

### Clinical presentation

A 7-year-old boy was admitted in our emergency department following road traffic accident. He fell down from a bicycle. On admission, his Glasgow Coma Scale was 15/15. On examination, he had

periorbital hematoma with edematous lids closing the right eye. Pupils were equal in size, reacting to light, and extraocular movements were normal on both sides. His vision was normal and able to count fingers at 5 feet.

Computed tomography (CT) scan of the head revealed fracture in the roof of the right orbit and a small hematoma in extraconal space [Figure 1]. It also revealed contusions in the basifrontal lobe. On the 4<sup>th</sup> day of admission, we noticed right eyeball protruding through the closed lids [Figure 2]. Extraocular movements were restricted. Visual acuity in the right eye was 3/60 and in left 6/6. CT orbit with thin sagittal and coronal sections was done. Axial section showed enlargement of the extraconal lesion medially, and it was pushing the orbit anteriorly and laterally. The coronal section showed the brain matter herniating through the defect in the roof [Figure 2].

Frontobasal approach with small frontal craniotomy was used. On lifting the frontal lobe, tear in the basal dura was seen adherent to the fracture margin. After releasing the dura, herniated, lacerated brain along with pia-arachnoid covering was evacuated. The displaced bone fragment was retrieved. Duroplasty was done with pericranium. Orbital roof was reconstructed with titanium mesh with screws. In the immediate postoperative period, the proptosis has resolved [Figure 3]. In the next couple of days, his vision improved to normal.

**How to cite this article:** Sadashivam S. Isolated orbital roof fracture: Can it be catastrophic?. *Asian J Neurosurg* 2018;13:935-7.

### Saravanan Sadashivam

Department of Neurosurgery,  
Kerala Institute of Medical  
Science, Trivandrum, Kerala,  
India

#### Address for correspondence:

Dr Saravanan Sadashivam,  
T C No 1/13/56, Thejas,  
Rose Garden, Poonthi  
Road, Kumarapuram,  
Trivandrum - 695 011,  
Kerala, India.  
E-mail: drsaravns@gmail.com

#### Access this article online

Website: [www.asianjns.org](http://www.asianjns.org)

DOI: 10.4103/ajns.AJNS\_101\_18

#### Quick Response Code:



This is an open access journal, and articles are distributed under the terms of the Creative Commons Attribution-NonCommercial-ShareAlike 4.0 License, which allows others to remix, tweak, and build upon the work non-commercially, as long as appropriate credit is given and the new creations are licensed under the identical terms.

For reprints contact: [reprints@medknow.com](mailto:reprints@medknow.com)

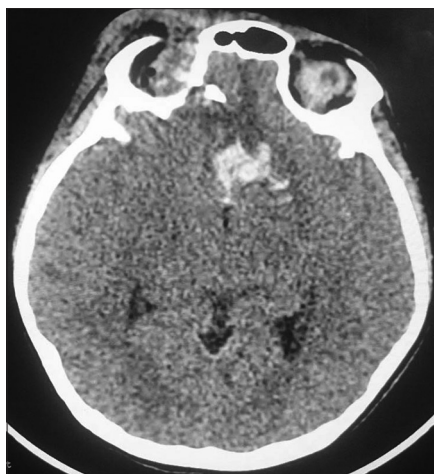


Figure 1: Computed tomography scan of the head done on admission showed suspected extraconal hematoma. Note the periorbital soft-tissue swelling

## Discussion

Orbital roof fractures most often result from blunt injury. These fractures are relatively common in pediatric age group. Proportionally larger cranium and incomplete pneumatization of the frontal sinus in young children make them susceptible to the fracture because the impact force is directly transmitted to orbital roof.<sup>[4]</sup> These fractures may be simple undisplaced or complex. The complex fractures can be blow out or blow in fractures. “Blowout” fractures usually present with entrapment syndrome. “Blow-in” fractures present with features of raised intraorbital pressure or impingement syndrome. Inferiorly displaced fractures and fractures with surface area over 2 cm<sup>2</sup> represent higher risk fractures. They should be followed closely for any complications.<sup>[5]</sup>

Orbital encephalocele is a rare complication of orbital roof fractures. It is characterized by herniation of the part of the brain and meninges through the fracture line into the orbit. Traumatic orbital encephalocele can be classified as acute and chronic. Acute orbital encephalocele occurs within days after the injury. It leads to rapid loss of vision. Hence, early diagnosis is crucial. It is commonly reported in children between 2 and 12 years of age. Few cases in adults have also been reported.<sup>[2,6]</sup>

The most common symptoms are rapidly progressive proptosis, decreased vision, eyelid swelling, and restricted eyeball movements. The periorbital edema resulting from the injury often makes the early diagnosis difficult.

Three factors play an important role in the pathogenesis of acute orbital encephalocele. They are raised intracranial pressure, injury to the basal dura, and bony defect due to the fracture.<sup>[2,7]</sup> Herniated brain and bone fragments cause venous outflow obstruction which results in edema of the retro-orbital soft tissues and increased intraorbital pressure. This, in turn, obliterates the draining veins. This vicious

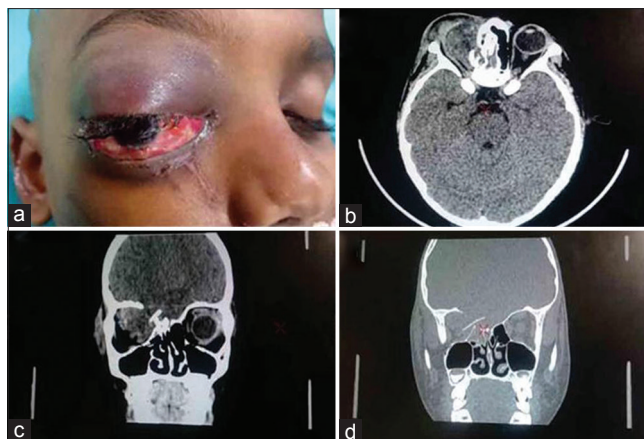


Figure 2: (a) Note the proptosis of the right eye. (b) Axial computed tomography head shows extra-axial mass displacing the eyeball. (c) Coronal section of computed tomography orbit shows brain parenchyma herniating into the orbit. (d) Coronal bone window shows the displaced orbital roof fracture

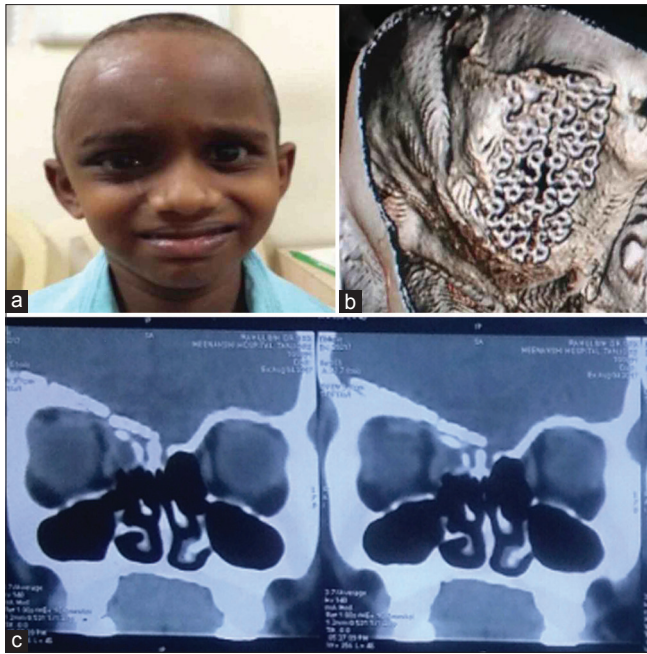
cycle ultimately results in retinal artery occlusion and permanent visual loss.<sup>[3]</sup>

Early diagnosis is vital to preserve the vision. Encephalocele may be misinterpreted as extraconal hematoma in the cranial CT scan.<sup>[8]</sup> Many authors advised magnetic resonance imaging (MRI) of the orbit as the investigation of choice.<sup>[2,6,8,9]</sup> It may not be always easy to perform MRI in emergency situation. CT of the orbit with thin axial and coronal sections is very useful in the evaluation of the orbital contents.<sup>[10]</sup> Often, this is useful in establishing the diagnosis.

Chronic orbital encephalocele or growing fracture of orbital roof occurs usually months or years after the initial injury. Like growing fracture of the skull, orbital roof-growing fractures are commonly seen in infants and children.<sup>[11,12]</sup> Cerebral pulsation and normal growth of the brain and cranium of the children are responsible for the growth of the fracture.<sup>[13]</sup>

The goals of the surgical treatment of orbital encephalocele are (1) orbital decompression by removing herniated brain, (2) duroplasty, and (3) orbital roof reconstruction.<sup>[2,9]</sup> Orbital roof reconstruction is the key step and should be done in all cases. The most common surgical approach described in the literature is frontobasal approach.<sup>[11,12]</sup> Recently, di Somma *et al.* described a minimally invasive combined supra-transorbital keyhole approach for the reconstruction of delayed orbital encephalocele.<sup>[14]</sup> Through superior blepharoplasty incision, the authors made orbital osteotomy with supraorbital minicraniotomy.

Various materials have been described in the literature for the reconstruction of the orbital roof. Autologous bone graft, temporalis fascia, alloplastic grafts such as titanium mesh and miniscrews, polypropylene, porous polyethylene, methyl methacrylate, and polyamide mesh have been used



**Figure 3:** (a) Postoperative picture shows the complete resolution of proptosis. (b) Three-dimensional reconstruction of computed tomography skull shows orbital roof reconstruct. (c) Coronal computed tomography orbit shows the titanium mesh covering the orbital roof defect

for the reconstruction.<sup>[3,10,15]</sup> Irrespective of the material used the cosmetic outcome is very good in all cases. Recurrence has not been reported in the literature.

### Conclusion

Acute traumatic orbital encephalocele is a rare complication of orbital roof fractures. Early diagnosis is vital as untreated cases could result in devastating complications. CT orbit with thin axial and coronal sections can be reliable in making the diagnosis. Traditional approach such as frontal craniotomy and frontobasal approach or minimally invasive supra-transorbital approach can be used for the repair of the orbital roof. Reconstruction of the orbital roof using autologous or alloplastic graft is the key step in the surgery.

### Declaration of patient consent

The authors certify that they have obtained all appropriate patient consent forms. In the form, the legal guardian has given his consent for images and other clinical information to be reported in the journal. The guardian understands that name and initials will not be published and due efforts will be made to conceal patient identity, but anonymity cannot be guaranteed.

### Financial support and sponsorship

Nil.

### Conflicts of interest

There are no conflicts of interest.

### References

1. Antonelli V, Cremonini AM, Campobassi A, Pascarella R, Zofrea G, Servadei F, *et al.* Traumatic encephalocele related to orbital roof fractures: Report of six cases and literature review. *Surg Neurol* 2002;57:117-25.
2. Losee JE, Afifi A, Jiang S, Smith D, Chao MT, Vecchione L, *et al.* Pediatric orbital fractures: Classification, management, and early follow-up. *Plast Reconstr Surg* 2008;122:886-97.
3. Aggarwal A, Gupta AK, Aggarwal AK. Acute post traumatic encephalocele in a child: CT and MRI features. *BJR Case Rep* 2016;2:20150170.
4. Koltai PJ, Amjad I, Meyer D, Feustel PJ. Orbital fractures in children. *Arch Otolaryngol Head Neck Surg* 1995;121:1375-9.
5. Coon D, Yuan N, Jones D, Howell LK, Grant MP, Redett RJ, *et al.* Defining pediatric orbital roof fractures: Patterns, sequelae, and indications for operation. *Plast Reconstr Surg* 2014;134:442e-8e.
6. Duhem-Tonnelle V, Duhem R, Mora AR, Allaoui M, Assaker R. Traumatic orbital encephalocele in an adult: Report of one case. *Neurochirurgie* 2008;54:28-31.
7. Menkü A, Koç RK, Tucer B, Kurtsoy A, Akdemir H. Growing skull fracture of the orbital roof: Report of two cases and review of the literature. *Neurosurg Rev* 2004;27:133-6.
8. Wei LA, Kennedy TA, Paul S, Wells TS, Griepentrog GJ, Lucarelli MJ, *et al.* Traumatic orbital encephalocele: Presentation and imaging. *Orbit* 2016;35:72-7.
9. Cayli SR, Kocak A, Alkan A, Kutlu R, Tekiner A, Ates O, *et al.* Intraorbital encephalocele: An important complication of orbital roof fractures in pediatric patients. *Pediatr Neurosurg* 2003;39:240-5.
10. Gazioglu N, Ulu MO, Ozlen F, Uzan M, Ciplak N. Acute traumatic orbital encephalocele related to orbital roof fracture: Reconstruction by using porous polyethylene. *Ulus Travma Acil Cerrahi Derg* 2008;14:247-52.
11. Suri A, Mahapatra AK. Growing fractures of the orbital roof. A report of two cases and a review. *Pediatr Neurosurg* 2002;36:96-100.
12. Amirjamshidi A, Abbassioun K, Sadeghi Tary A. Growing traumatic leptomeningeal cyst of the roof of the orbit presenting with unilateral exophthalmos. *Surg Neurol* 2000;54:178-81.
13. Taveras JM, Ransohoff J. Leptomeningeal cysts of the brain following trauma with erosion of the skull; a study of seven cases treated by surgery. *J Neurosurg* 1953;10:233-41.
14. di Somma L, Iacoangeli M, Nasi D, Balercia P, Lupi E, Giroto R, *et al.* Combined supra-transorbital keyhole approach for treatment of delayed intraorbital encephalocele: A minimally invasive approach for an unusual complication of decompressive craniectomy. *Surg Neurol Int* 2016;7:S12-6.
15. Mokla NJ, Desai MF. Titanium mesh reconstruction of orbital roof fracture with traumatic encephalocele: A case report and review of literature. *Craniofac Trauma Reconstr* 2012;5:11-8.