

CASE REPORT

Open Access

A novel *GLI3* mutation affecting the zinc finger domain leads to preaxial-postaxial polydactyly-syndactyly complex

Michael Volodarsky^{1†}, Yshaia Langer^{1,2†} and Ohad S Birk^{1,3*}

Abstract

Background: Polydactyly is a highly common congenital limb defect. Extra digits may appear as an isolated anomaly or as a part of a syndrome. Mutations in *GLI3* have been shown to cause Greig cephalopolysyndactyly, Pallister-Hall syndrome and non-syndromic polydactyly. Genotype-phenotype correlation studies of *GLI3* mutations suggest a model by which mutations in the zinc-finger domain (ZFD) of *GLI3* likely lead to syndromic polydactyly. Here we describe a rare case of autosomal dominant heterozygous missense mutation in the ZFD of *GLI3* leading to a variable polydactyly-syndactyly complex.

Case presentation: A large Jewish Moroccan family presented with apparently autosomal dominant heredity of bilateral thumb polydactyly in hands and feet combined with post-axial polydactyly type B or type A. Syndactyly was evident in most patients' hands and feet. Apart from head circumference beyond 90th percentile in some of the affected individuals, none had craniofacial dysmorphism. A novel *GLI3* c.1802A > G (p.His601Arg) mutation was found in all affected individuals.

Conclusion: We demonstrate that a mutation in the ZFD domain of *GLI3* leads to phenotypic variability, including an isolated limb phenotype. Thus, the variability in phenotypes caused by mutations in this master developmental regulator is more profound than has been previously suggested.

Keywords: Polydactyly, Syndactyly, GCPS, *GLI3*, Mutation, C2H2, Zinc finger

Background

Polydactyly, one of the most common congenital hand/foot malformations encountered in clinical genetics [1,2], can occur as an isolated entity or as part of pleiotropic developmental anomaly syndromes [3]. Post-axial polydactyly is far more common than pre-axial and central polydactyly; occasionally, concomitant syndactyly is seen with some forms of polydactyly [2]. The *GLI3* protein is a zinc finger transcription factor expressed early in development [4]. It is required for the specification of dorsal cell types and for suppression of ventral cell types in the forebrain [5]. *GLI3* expression in the anterior half of the limb

buds appears to play an important role in suppressing digit formation [5]. These observations, together with the diverse phenotypes resulting from molecular defects in *GLI3*, serve as a classical example of pleiotropy: *GLI3* mutations are known to cause different clinical entities: Greig Cephalopolysyndactyly Syndrome (GCPS) (MIM ID #175700), Pallister-Hall Syndrome (MIM ID #146510), Acrocallosal Syndrome (MIM ID #200990), Pre-axial Polydactyly type IV (MIM ID #174700) and Post-axial Polydactyly type A (MIM ID #174200). The great majority of known *GLI3* mutations cause loss of function [4]. Some reports describe *GLI3* mutations as a cause of isolated polydactyly [6], while others consider all *GLI3* mutations as causing polydactyly within the GCPS spectrum [7]. It has been suggested that mutations in different domains of the gene underlie the different evolving phenotypes, and that mutations 5' to or within the zinc finger domain (ZFD) of *GLI3* specifically cause GCPS [6,8]. The classic clinical presentation of GCPS is a triad of polysyndactyly,

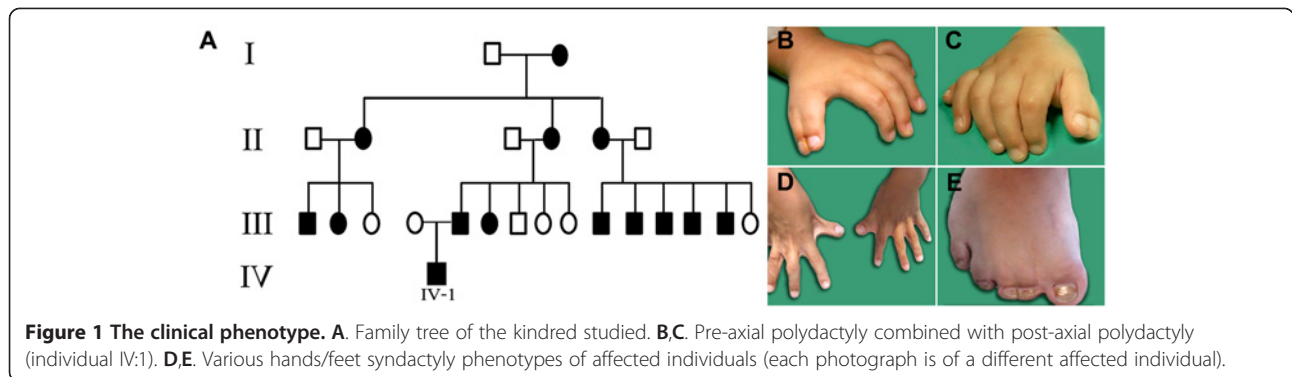
* Correspondence: obirk@bgu.ac.il

[†]Equal contributors

¹The Morris Kahn Laboratory of Human Genetics, National Institute for Biotechnology in the Negev and Faculty of Health Sciences, Ben Gurion University, Beer-Sheva 84105, Israel

³Genetics Institute, Soroka Medical Center, Beer-Sheva 84101, Israel

Full list of author information is available at the end of the article



macrocephaly and hypertelorism [9]. Here we report a new heterozygous missense mutation in the zinc finger domain of *GLI3* leading to a variable phenotype presenting in some cases as an isolated polydactyly-syndactyly complex.

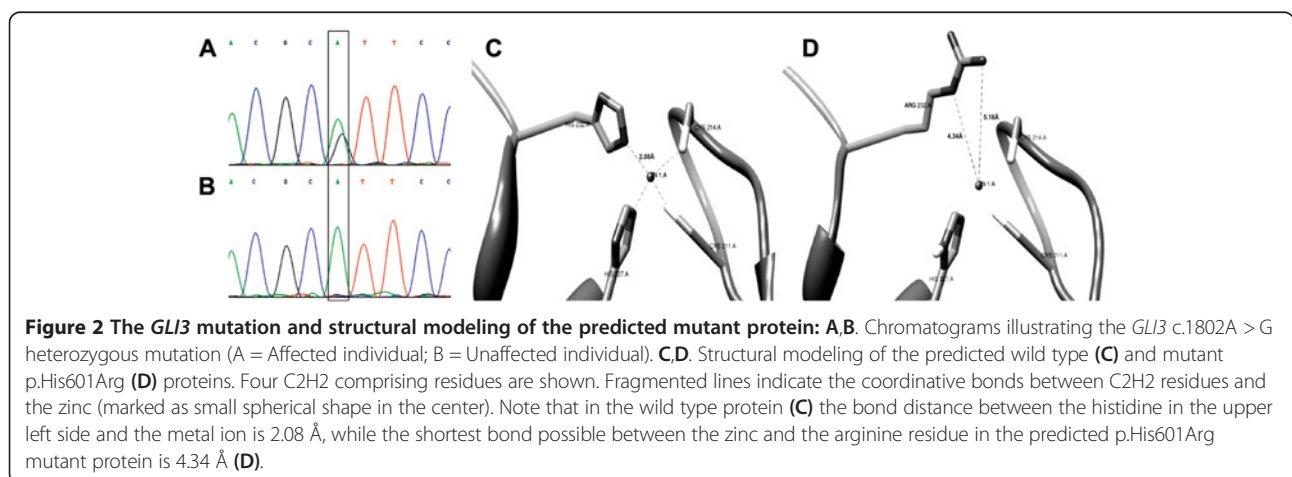
Case presentation

A large Jewish Moroccan kindred presented with apparently autosomal dominant heredity of polydactyly (Figure 1A). Affected and unaffected family members underwent thorough clinical and molecular evaluation following Soroka Medical Center IRB approval and informed consent. Phenotypic variability among the 14 affected individuals was evident: most had hands and feet bilateral thumb polydactyly and post-axial polydactyly type B. Syndactyly was found in the feet of all affected individuals and in the hands of most (Figure 1D,E). A single case of thumb polydactyly combined with post-axial polydactyly type A (well developed separated digit) was evident (Figure 1A, IV:1; Figure 1B,C). None of the affected individuals had apparent craniofacial dysmorphism. Occipitofrontal head circumference (OFC) and interpupillary distance (IPD) were measured in 13 (8 affected and 5 unaffected) family members. The measurements were most variable (see Additional file 1). Five

patients had an OFC at or above the 90th percentile, while all the healthy individuals showed OFC beneath 90th percentile. As to IPD measurements, 5 of 8 affected as well as 4 of 5 unaffected individuals were above 97th percentile.

Methods and results

Blood samples were obtained from 13 affected and 6 unaffected family members and genomic DNA was extracted by routine techniques. Linkage to genes known to be associated with non-syndromic polydactyly was tested using 2 polymorphic markers flanking each candidate gene. Association of the phenotype with *HOXD13*, ZPA regulatory sequence (ZRS) and *FBLN1* was ruled out (data not shown). Polymorphic markers D7S1526 and D7S691 flanking *GLI3* identified a heterozygous haplotype shared by all affected family members (data not shown). Sanger sequencing of all *GLI3* exons and their flanking exon-intron boundaries and comparison (NCBI BLAST) to the published *GLI3* sequence (GenBank reference number NM_000168.5), identified a single heterozygous missense mutation in exon 12: c.1802A > G, p.His601Arg (Figure 2A,B). This novel mutation was found to segregate within the kindred as expected, demonstrating full penetrance of the phenotype.



The *GLI3* ZFD consists of 5 C2H2 type zinc fingers. The histidine to arginine substitution caused by the mutation is of the second histidine within one of the C2H2 zinc fingers comprising this domain. In zinc finger domains, a zinc ion forms four coordinate bonds generating a stable fold [10]. Since the *GLI3* 601His is one of the four residues directly interacting with the Zn^{2+} ion in a C2H2 zinc finger motif, the p.His601Arg substitution is likely to have functional consequences. Using crystallographic structure of the consensus motif of C2H2 type zinc finger (PDB:3IUF), we used UCSF Chimera software [11] to construct a simplified model illustrating the change in interactions with the Zinc cation. As shown in Figure 2, the mutation is predicted to cause destabilization of the Zn^{2+} ion, as the stable coordinative bond of histidine 232 (comparable to *GLI3* histidine 601) with the metal ion (Figure 2C) is replaced in the mutated protein by a much longer unrealized bond with an arginine residue (Figure 2D). We speculate that the p.His601Arg mutation might alter the ability of *GLI3* to bind its downstream targets within the SHH pathway, such as the posterior *Hoxd* genes [12].

Conclusions

In the kindred we describe, the OFC and IPD findings possibly stem from intrafamilial variability. The craniofacial manifestations of GCPS are highly variable and not all patients with GCPS have obvious macrocephaly [9] as observed in the family described here. In fact, the mild end of the GCPS spectrum is a continuum with isolated polydactyly [7]. Thus, in some cases there is unclear clinical delineation of GCPS versus non-syndromic polydactyly. The effects of truncating mutations (leading to loss of functional regions) on digit number and identity were largely discussed in the context of *GLI3*'s role as mediator of the hedgehog pathway, whereas connection between defect in the DNA binding domain (DBD) and the phenotype of our pedigree is more elusive. Besides the posterior *Hoxd* genes, other factors known to be downstream of *GLI3* are *FGF8*, *FGF4*, *GREM1*, *HAND2* and *JAG1* [12]. It is plausible that changes in expression patterns of these *GLI3* targets (as a result of an obstructed DBD) can contribute to the polydactyly phenotype. Both the precise mechanism through which the specific mutation leads to the disease phenotype, and the molecular mechanisms underlying the familial phenotypic variability are yet to be elucidated.

In summary, we describe a large kindred with a novel heterozygous *GLI3* ZFD domain missense mutation leading to polydactyly-syndactyly complex. The phenotype described is within the wide range of phenotypic spectrum of GCPS established by Biesecker [13]. With recent emerging evidence of *GLI3* mutations causing non-syndromic limb defects [14,15], our data highlight the

fact that a *GLI3* mutation within the ZFD domain can cause a mild form of GCPS with no prominent facial dysmorphism. This report strengthens the need to screen for *GLI3* mutations in patients with polydactyly-syndactyly phenotype, even when syndromic features are not evident.

Consent

Written informed consent was obtained from the patients for publication of this Case report and any accompanying images.

Additional file

Additional file 1: Clinical data. Gender, affected (+/-), age, OFC, IPD and malformations data of family members.

Competing interests

The authors declare that they have no competing interests.

Authors' contributions

MV carried out the molecular genetic studies and drafted the manuscript. YL was involved in acquisition and analysis of clinical data and helped drafting the manuscript. OSB conceived and coordinated the study and took part in writing the manuscript. All authors read and approved the final manuscript.

Acknowledgements

This research was supported by the Israel Science Foundation (grant No. 1689/12). We deeply thank the Morris Kahn family foundation for the generous support of this study, and the patients and their families for kind participation. We would also like to acknowledge Dotan Amar for his assistance in drawing some of the figures. Molecular graphics images were produced using the UCSF Chimera package from the Resource for Biocomputing, Visualization, and Informatics at the University of California, San Francisco (supported by NIH P41 RR001081).

Author details

¹The Morris Kahn Laboratory of Human Genetics, National Institute for Biotechnology in the Negev and Faculty of Health Sciences, Ben Gurion University, Beer-Sheva 84105, Israel. ²Department of Pediatrics, Shaare-Zedek Medical Center, Jerusalem, Israel. ³Genetics Institute, Soroka Medical Center, Beer-Sheva 84101, Israel.

Received: 13 April 2014 Accepted: 24 September 2014

Published online: 30 September 2014

References

1. Shubha RP, Sankar VH: Polydactyly and genes. *Indian J Pediatr* 2010, **77**(3):277–281.
2. Chong AK: Common congenital hand conditions. *Singapore Med J* 2010, **51**(12):965–971.
3. Biesecker LG: Polydactyly: how many disorders and how many genes? *Am J Med Genet* 2002, **112**(3):279–283.
4. Biesecker LG: What you can learn from one gene: *GLI3*. *J Med Genet* 2006, **43**:465–469.
5. Motoyoma J: Essential roles of *Gli3* and sonic hedgehog in pattern formation and developmental anomalies caused by their dysfunction. *Congenit Anom (Kyoto)* 2006, **46**:123–128.
6. Johnston JJ, Sapp JC, Turner JT, Amor D, Aftimos S, Aleck KA, Bocian M, Bodurtha JN, Cox GF, Curry CJ, Day R, Donnai D, Field M, Fujiwara I, Gabbett M, Gal M, Graham JM, Hedera P, Hennekam RC, Hersh JH, Hopkin RJ, Kayserili H, Kidd AM, Kimonis V, Lin AE, Lynch SA, Maisenbacher M, Mansour S, McGaughan J, Mehta L, et al: Molecular analysis expands the spectrum of phenotypes associated with *GLI3* mutations. *Hum Mutat* 2010, **31**:1142–1154.

7. Balk K, Biesecker LG: **The clinical atlas of Greig cephalopolysyndactyly syndrome.** *Am J Med Genet A* 2008, **1;146A**(5):548–557.
8. De'murger F, Ichkou A, Mougou-Zerelli S, Le Merrer M, Goudefroye G, Delezoide AL, Que'lin C, Manouvrier S, Baujat G, Fradin M, Pasquier L, Megarbane' A, Faivre L, Baumann C, Nampoothiri S, Roume J, Isidor B, Lacombe D, Delrue MA, Mercier S, Philip N, Schaefer E, Holder M, Krause A, Laffargue F, Sinico M, Amram D, Andre' G, Liquier A, Rossi M: **New insights into genotype-phenotype correlation for GLI3 mutations.** *Eur J Hum Genet* 2014. 10.1038/ejhg.2014.62.
9. Biesecker LG: **The Greig cephalopolysyndactyly syndrome.** *Orphanet J Rare Dis* 2008, **24**(3):10.
10. Takafumi N, Makiko S, Kiyoshi A: **Correlated mutation analysis of C2H2 zinc finger domains.** *Genome Inform* 2003, **14**:565–566.
11. Pettersen EF, Goddard TD, Huang CC, Couch GS, Greenblatt DM, Meng EC, Ferrin TE: **UCSF Chimera—a visualization system for exploratory research and analysis.** *J Comput Chem* 2004, **25**(13):1605–1612.
12. Sheth R, Bastida MF, Ros M: **Hoxd and Gli3 interactions modulate digit number in the amniote limb.** *Dev Biol* 2007, **310**(2):430–441.
13. Biesecker LG: **Greig Cephalopolysyndactyly Syndrome.** In *GeneReviews™ (Internet)*. ; 2001. updated 2009.
14. Wang Z, Wang J, Li Y, Geng J, Fu Q, Xu, Shen Y: **Novel frame-shift mutations of GLI3 gene in non-syndromic postaxial polydactyly patients.** *Clin Chim Acta* 2014, **10**(433):195–199.
15. Sethi SK, Goyal D, Khalil S, Yadav DK: **Two Indian families with Greig cephalosyndactyly with non-syndromic phenotype.** *Eur J Pediatr* 2013, **172**(8):1131–1135.

doi:10.1186/s12881-014-0110-9

Cite this article as: Volodarsky et al.: A novel *GLI3* mutation affecting the zinc finger domain leads to preaxial-postaxial polydactyly-syndactyly complex. *BMC Medical Genetics* 2014 **15**:110.

Submit your next manuscript to BioMed Central and take full advantage of:

- Convenient online submission
- Thorough peer review
- No space constraints or color figure charges
- Immediate publication on acceptance
- Inclusion in PubMed, CAS, Scopus and Google Scholar
- Research which is freely available for redistribution

Submit your manuscript at
www.biomedcentral.com/submit

