

Normal adrenal gland thickness on computerized tomography in an Asian Indian adult population

Reetu John, Tharani Putta, Betty Simon, Anu Eapen, Felix Jebasingh¹, Nihal Thomas¹, Simon Rajaratnam¹

Departments of Radiodiagnosis and ¹Endocrinology, Christian Medical College, Vellore, Tamil Nadu, India

Correspondence: Dr. Tharani Putta, Department of Radiodiagnosis, Christian Medical College, Vellore - 632 004, Tamil Nadu, India.
E-mail: tharaniputta@gmail.com

Abstract

Context: The size and morphology of the adrenal glands are affected by several physiological and pathological conditions. Radiologists need to be aware of the normal thickness of adrenal gland to accurately assess patients with suspected adrenal pathology. However, there is limited data on the normal size of the adrenal glands. Moreover, this has not been studied in our population. **Aims:** To study the normal thickness of adrenal gland on computerized tomography (CT) in Indian adult population. **Settings and Design:** Retrospective study in a tertiary care hospital in Southern India. **Subjects and Methods:** Our study included 586 adults who underwent a CT abdominal angiogram over 15 months, and excluding patients with clinical or imaging evidence of adrenal disease. The measurements made included: the maximum thickness of the body, medial and lateral limbs, measured perpendicular to the long axis. **Results:** The median age was 51 (range: 18–85) years. The mean maximum thickness of the adrenal body, medial, and lateral limbs were 7.2 ± 1.8 , 4.1 ± 1.1 , and 4.3 ± 1.1 mm on the right side and 8.8 ± 1.9 , 4.7 ± 1.1 , and 4.9 ± 1.3 mm on the left. The cumulative thickness of the body and the limbs were 15.6 ± 3.7 mm and 18.4 ± 3.8 mm on the right and left sides, respectively. There was a statistically significant difference in all the measurements between the right and left adrenal glands (all *P* values = 0.000) and between men and women, being larger in men (*P* value <0.05). Among our patients 27% had at least one adrenal gland body measuring ≥ 10 mm in thickness. **Conclusions:** Our study has defined the normal range of adrenal gland thickness in an Asian Indian adult population, which may be used as a baseline reference for future research and as a reference for radiological reporting.

Key words: Adrenal atrophy; adrenal gland size; adrenal gland thickness; bulky adrenal; multidetector computed tomography

Introduction

The size and morphology of the adrenal glands may be affected by a variety of physiological states and pathological conditions, including neoplasms (primary or metastatic), tuberculosis and other infections, noninfectious granulomatous diseases, hemorrhage, and various endocrine disorders. A diffusely enlarged adrenal gland is

a subjective observation that is fairly commonly made by the radiologists during routine computed tomography (CT) reporting. There is, however, no recent literature that states the normal adrenal gland thickness on multidetector CT images in a large population. Through this retrospective study, we have established a baseline reference range for normal adrenal gland thickness in an Asian Indian adult

This is an open access journal, and articles are distributed under the terms of the Creative Commons Attribution-NonCommercial-ShareAlike 4.0 License, which allows others to remix, tweak, and build upon the work non-commercially, as long as appropriate credit is given and the new creations are licensed under the identical terms.

For reprints contact: reprints@medknow.com

Cite this article as: John R, Putta T, Simon B, Eapen A, Jebasingh F, Thomas N, *et al.* Normal adrenal gland thickness on computerized tomography in an Asian Indian adult population. *Indian J Radiol Imaging* 2018;28:465-9.

Access this article online

Quick Response Code:



Website:
www.ijri.org

DOI:
10.4103/ijri.IJRI_129_18

population which can be used for clinical care and future research.

Subjects and Methods

In this retrospective observational study, we included all adult patients who underwent CT angiogram of the upper abdomen over a period of 15 months at the Christian Medical College, Vellore located in Southern India. These patients underwent CT for unrelated clinical indications. CT angiograms were used in order to ensure uniformity in slice thickness, image quality, and data across all the study cases. All patients with clinical, biochemical, or radiological evidence of adrenal disease (including those with nodular thickening) and those with history of chronic steroid use were excluded from the study. The CT studies included thin-slice axial images (≤ 2.5 mm slice thickness). The following measurements were made in each late arterial or early portal venous phase CT on the axial image in an abdominal soft tissue window setting (window level 40–60, window width 400) using a standard described method^[1]: the maximum thickness of the body, the medial and the lateral limbs were measured perpendicular to their long axis, in both adrenal glands [Figure 1]. The measurements were recorded in millimeters (mm) to the nearest single decimal point. The mean and standard deviation for each of the measurements were calculated. Spearman's correlation coefficient was used to measure correlation between age and each variable. Levene's test for equality of variances was used to measure statistically significant differences between genders and between the two sides. Statistical Package for the Social Sciences (SPSS, IBM Corp., Armonk, NY) software version 23 was used for statistical analysis.

Results

The median age was 51 years (range = 18–85 years, $n = 586$, male 385, female 201). The mean and standard deviation

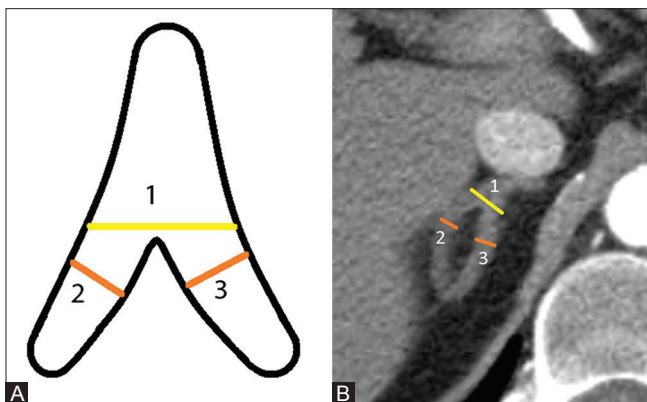


Figure 1 (A and B): Schematic diagram (A) and axial CT image (B) of the adrenal gland demonstrating the measurement technique: 1 shows the maximum thickness of the body of the adrenal gland, and 2 and 3 show the maximum thickness of the lateral and medial limbs, respectively

for various measurements are summarized in Table 1. The mean maximum thickness (in mm) of the right adrenal gland body, medial limb, and lateral limb were 7.2 ± 1.8 , 4.1 ± 1.1 , and 4.3 ± 1.1 , respectively, and the mean maximum thickness (in mm) of the left adrenal gland body, medial limb, and lateral limb were 8.8 ± 1.9 , 4.7 ± 1.1 , and 4.9 ± 1.3 , respectively. The cumulative thickness of the body and both limbs of the adrenal glands were 15.6 ± 3.7 mm on the right side and 18.4 ± 3.8 mm on the left.

There was statistically significant difference in all the measurements between the right and left sides, left being larger than the right (P values < 0.001). On average, the left adrenal body was larger than the right adrenal body by 1.6 mm (95% confidence interval (CI) [1.45, 1.73]) and the cumulative left adrenal size was larger than the right side by 2.8 mm (95% CI [2.58, 3.03]).

There was a statistically significant difference in all the measurements of adrenal gland size between males and females, larger in males [Table 1 and Figure 2]. The mean cumulative right adrenal gland size in males and females were 16.6 ± 3.6 and 13.8 ± 3.1 mm, respectively, and the mean cumulative left adrenal gland size in males and females were 19.4 ± 3.8 and 16.6 ± 3.0 mm, respectively. The cumulative adrenal gland thickness is 2.8 mm more in males when compared to females on both sides (95% CI [2.17, 3.35]) and P value = 0.005 on the right; 95% CI [2.16, 3.38] and P value = 0.022 on the left).

There was medium positive correlation (Spearman's correlation coefficient (r) ranging from 0.329 to 0.436) between the patient age and all the adrenal gland measurements with the exception of left medial limb thickness, which showed a weak positive correlation ($r = 0.247$) [Figure 3]. Thickness of adrenal body ≥ 10 mm was seen in 27% of the cases at least on one side and bilaterally in 5.4% of the cases.

Discussion

The term "bulky adrenals" is an ambiguous but commonly used phrase in the CT reports and many a times, the referring physician and the radiologist are uncertain of what this finding means for the patient. Moreover, there is no objectivity in using this term.

When a patient has unilateral or bilateral smooth adrenal enlargement, it is important to rule out a hypo or hyper-functioning adrenal gland.^[2] In such cases, the baseline investigations include serum 8 AM cortisol, serum electrolytes, 24-h urine-free cortisol, and 24-h urinary catecholamine levels. In addition to the above biochemical parameters, a subset of patients may need to undergo an overnight 1 mg dexamethasone suppressed serum cortisol or renin and aldosterone ratio, for further characterization. Although not often necessary, a smaller subset of these

Table 1: The mean values, standard deviation, and 95% CI of various adrenal gland measurements on CT (mm)

Adrenal gland thickness	Right adrenal			Left adrenal			P*
	Mean thickness (mm)	SD	95% CI (mm)	Mean thickness (mm)	SD	95% CI (mm)	
Total population (n=586)							
Body	7.2	1.85	3.5-10.9	8.8	1.95	4.9-12.7	0.000
Medial limb	4.1	1.12	1.8-6.3	4.7	1.13	2.4-6.9	0.000
Lateral limb	4.3	1.15	2.0-6.6	4.9	1.33	2.2-7.5	0.000
Cumulative	15.6	3.69	8.2-23.0	18.4	3.79	10.8-26.0	0.000
Males (n=385)							
Body	7.6	1.79	4.0-11.2	9.2	1.93	5.3-13.0	0.000
Medial limb	4.4	1.12	2.1-6.6	5.0	1.14	2.7-7.3	0.000
Lateral limb	4.6	1.15	2.3-6.9	5.2	1.34	2.5-7.9	0.000
Cumulative	16.6	3.60	9.4-23.8	19.4	3.79	11.8-27.0	0.000
Females (n=201)							
Body	6.4	1.65	3.1-9.7	8.0	1.73	4.5-11.5	0.000
Medial limb	3.6	0.92	1.8-5.4	4.4	1.02	2.3-6.4	0.000
Lateral limb	3.9	1.01	1.9-5.9	4.2	0.98	2.2-6.2	0.000
Cumulative	13.8	3.15	7.5-20.1	16.6	3.06	10.5-22.7	0.000

*P<0.05 indicates statistically significant difference. CI: Confidence interval, SD: Standard deviation

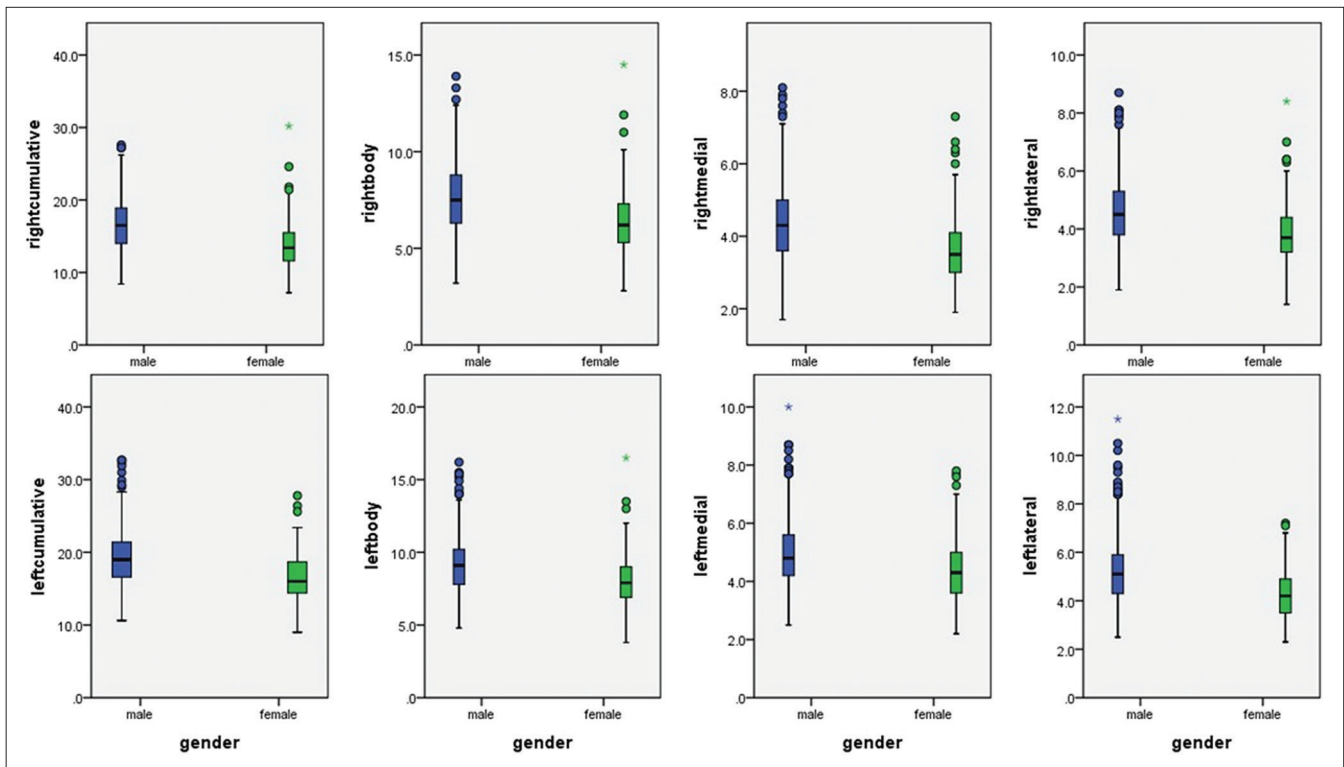


Figure 2: Box plot diagram showing a significant difference in all the measurements between the right and left adrenal glands

patients with bilateral diffuse adrenal gland enlargement may require biopsy to determine the cause for enlargement. It is also interesting to note that there is no universally accepted cut-off size for labeling an adrenal gland as atrophic either. Bilateral atrophic adrenal glands are usually seen in patients with Addison’s disease or those with history of chronic steroid abuse. These patients require serum 8 AM cortisol and electrolyte levels, and additionally plasma

adrenocorticotrophic hormone level in suspected Addison’s disease. The knowledge of normal thickness of the adrenal glands is essential for radiologists in their daily practice, in order to objectively and accurately assess patients with suspected adrenal pathology. Hence, we believe that a study of this kind will be of great impact in order to objectively determine a patient as having enlarged or atrophic adrenal glands.

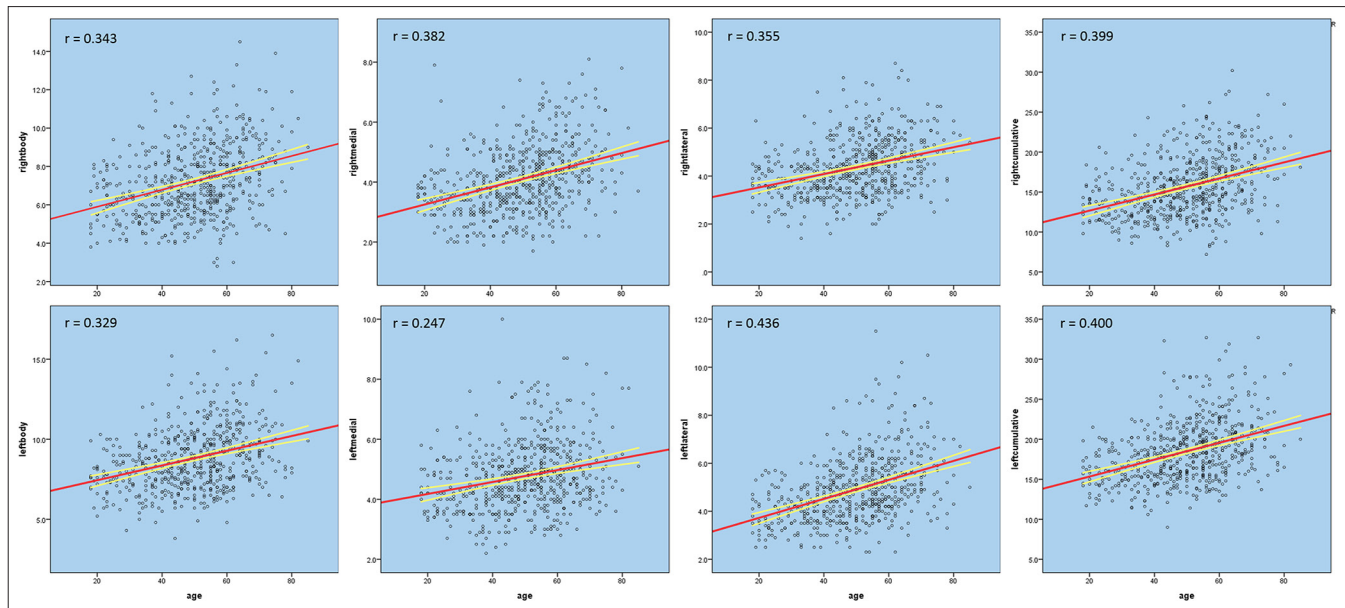


Figure 3: Scatter diagram showing weak to moderate positive correlation between the patient age and various adrenal gland measurements

Montagne *et al.* and Vincent *et al.* determined the normal range of adrenal gland thickness on CT in 60 and 55 patients, respectively, more than two decades ago.^[1,3] The drawback of their studies was the lack of multislice CT technology, optimal CT slice thickness, and the small number of study subjects. Many radiologists till date continue to use the cut-off value of 10 mm as the maximum thickness of adrenal gland beyond which it is considered as abnormal,^[4,5] this was based on the study by Vincent *et al.*^[6] With the advent of multidetector CT technology, it is now possible to acquire very thin-slice CT images with very good spatial resolution. More recently, Wang *et al.* and Schneller *et al.* separately assessed the volume of normal adrenal glands on multidetector CT using computer-assisted technology.^[7,8] However, assessment of adrenal gland volumes as a part of routine CT reporting is not practical, even in a high volume imaging center, where there is undue pressure on the system due to time and resource constraints. Measuring adrenal gland thickness is a simple alternative way of estimating the adrenal gland size, which can be done on axial CT images during routine practice and does not require expensive software. Maximum adrenal gland width also correlates well with the overall adrenal gland volume.^[8] The data on normal volume and thickness of the adrenal gland are very limited^[4] and to our knowledge, this has not been studied in the Asian Indian population. Through this study, we have identified the normal adrenal gland size in Indian adult population and shown a statistically significant difference in size between the right and left glands and between males and females. In our study, we have found that adrenal glands were larger in men compared to women. This finding is in agreement with what was reported by Schneller *et al.*^[8] and is contrary to the findings of Akin and Yilmaz,^[4] who reported that women had larger adrenal glands when

compared to men. It is important to note that very limited literature is available on this particular aspect. We also found that there is only low to medium positive correlation between adrenal gland size and age. The mean lateral limb thickness is slightly more than that of medial limb on both sides. This is consistent with all the previous studies that have studied this variable.^[1,3,8] Contrary to what has been reported in the literature,^[3,9,10] we also found a remarkably large number (27%) of our study subjects with adrenal body thickness ≥ 10 mm. Instead of using 10 mm as the cut-off for upper limit of normal adrenal body thickness, we propose the use of 95% CIs as reference range for normal adrenal gland thickness in our population [Table 1]: 4.0–11.2 mm for right adrenal body and 5.3–13 mm for left adrenal body in men; 3.1–9.7 mm for right adrenal body and 4.5–11.5 mm for left adrenal body in women.

In view of this being a retrospective study, biochemical screening tests were not available for many patients and we acknowledge this limitation. In an attempt to assess the functional status of the incidentally enlarged adrenal glands, Li *et al.*^[11] found that 35 out of 39 patients with smoothly enlarged adrenal glands showed normal biochemical functional status and only 3 out of the 39 patients had subclinical biochemical abnormality. This shows the relatively low incidence of subclinical biochemical abnormality in patients with incidental finding of smoothly enlarged adrenal glands. Whether we can attribute the high incidence of incidentally enlarged adrenal glands to ethnicity is debatable. At the very least, it may be necessary to use different reference standards for different population groups. We propose the use of our data as a useful baseline reference range for the Asian Indian adult population, and a guide for radiologists who can use this in their routine

cross-sectional reporting practice when they encounter a doubtful “bulky” or “diffuse smoothly enlarged” adrenal gland. In view of the retrospective nature of this study, there was no data available on patient height and body weight and hence, we could not compare the adrenal size to these parameters. We further acknowledge the need for large multiethnic population-based studies to establish an internationally acceptable reference standard.

Financial support and sponsorship

Nil.

Conflicts of interest

There are no conflicts of interest.

References

- Vincent JM, Morrison ID, Armstrong P, Reznick RH. The size of normal adrenal glands on computed tomography. *Clin Radiol* 1994;49:453-5.
- Fassnacht M, Arlt W, Bancos I, Dralle H, Newell-Price J, Sahdev A, *et al.* Management of adrenal incidentalomas: European society of endocrinology clinical practice guideline in collaboration with the European network for the study of adrenal tumors. *Eur J Endocrinol* 2016;175:G1-34.
- Montagne J, Kressel H, Korobkin M, Moss A. Computed tomography of the normal adrenal glands. *Am J Roentgenol* 1978;130:963-6.
- Akin D, Yilmaz M. Morphometric analysis of suprarenal glands (adrenal glands) with multislice computerized tomography. *Int J Morphol* 2017;35:120-7.
- Tang YZ, Bharwani N, Micco M, Akker S, Rockall AG, Sahdev A, *et al.* The prevalence of incidentally detected adrenal enlargement on CT. *Clin Radiol* 2014;69:e37-42.
- Vincent JM, Morrison ID, Armstrong P, Reznick RH. Computed tomography of diffuse, non-metastatic enlargement of the adrenal glands in patients with malignant disease. *Clin Radiol* 1994;49:456-60.
- Wang X, Jin ZY, Xue HD, Liu W, Sun H, Chen Y, *et al.* Evaluation of normal adrenal gland volume by 64-slice CT. *Chin Med Sci J* 2013;27:220-4.
- Schneller J, Reiser M, Beuschlein F, Osswald A, Pallauf A, Riestler A, *et al.* Linear and volumetric evaluation of the adrenal gland – MDCT-based measurements of the adrenals. *Acad Radiol* 2014;21:1465-74.
- Hamidi C. Evaluation of adrenal gland thickness by multi-detector computerized tomography. *J Clin Exp Investig* 2012;3:392-4.
- Karstaedt N, Sagel SS, Stanley RJ, Melson GL, Levitt RG. Computed tomography of the adrenal gland. *Radiology* 1978;129:723-30.
- Li LL, Gu WJ, Dou JT, Yang GQ, Lv ZH, Mu YM, *et al.* Incidental adrenal enlargement: An overview from a retrospective study in a Chinese population. *Int J Endocrinol* 2015;2015:192874.