



Published in final edited form as:

*Prostate Cancer Prostatic Dis.* 2021 September ; 24(3): 623–637. doi:10.1038/s41391-021-00332-5.

## Clinical Considerations for the Management of Androgen Indifferent Prostate Cancer

Jacob E. Berchuck<sup>1,3</sup>, Paul V. Viscuse<sup>2,3</sup>, Himisha Beltran<sup>1,4</sup>, Ana Aparicio<sup>2,4</sup>

<sup>1</sup>Department of Medical Oncology, Dana-Farber Cancer Institute, Harvard Medical School, Boston, MA

<sup>2</sup>Department of Genitourinary Medical Oncology, The University of Texas MD Anderson Cancer Center, Houston, TX

<sup>3</sup>These authors contributed equally

<sup>4</sup>These authors contributed equally

### Abstract

**Background:** Many systemic therapies for advanced prostate cancer work by disrupting androgen receptor signaling. Androgen indifferent prostate cancer (AIPC) variants, including aggressive variant prostate cancer (AVPC), neuroendocrine prostate cancer (NEPC), and double negative prostate cancer (DNPC), are increasingly common and often overlapping resistance phenotypes following treatment with androgen receptor signaling inhibitors in men with metastatic castration-resistant prostate cancer and are associated with poor outcomes. Understanding the underlying biology and identifying effective therapies for AIPC is paramount for improving survival for men with prostate cancer.

**Methods:** In this review, we summarize the current knowledge on AIPC variants, including our current understanding of the clinical, morphologic, and molecular features as well as current therapeutic approaches. We also explore emerging therapies and biomarkers aimed at improving outcomes for men with AIPC.

**Results and Conclusions:** Establishing consensus definitions, developing novel biomarkers for early and accurate detection, further characterization of molecular drivers of each phenotype, and developing effective therapies will be critical to improving outcomes for men with AIPC. Significant progress has been made towards defining the clinical and molecular characteristics of AVPC, NEPC, and DNPC. Novel diagnostic approaches, including cell-free DNA, circulating tumor cells, and molecular imaging are promising tools for detecting AIPC in clinical practice. Building on previous treatment advances, several clinical trials are underway evaluating novel therapeutic approaches in patients with AIPC informed by an understanding of variant-specific biology. In this review, we discuss how these recent and ongoing studies will help to improve diagnosis, prognosis, and therapy for men with AIPC.

---

Users may view, print, copy, and download text and data-mine the content in such documents, for the purposes of academic research, subject always to the full Conditions of use:[http://www.nature.com/authors/editorial\\_policies/license.html#terms](http://www.nature.com/authors/editorial_policies/license.html#terms)

**Corresponding Authors:** Himisha Beltran, MD, [himisha\\_beltran@dfci.harvard.edu](mailto:himisha_beltran@dfci.harvard.edu), Ana Aparicio, MD, [aaparicio@mdanderson.org](mailto:aaparicio@mdanderson.org).

## INTRODUCTION

Prostate cancer is characterized by significant clinical and biological heterogeneity. Many men experience an indolent disease course with long-term survival following prolonged responses to treatment, while others quickly develop aggressive resistant disease. As prostate cancer is primarily driven by androgen receptor (AR) signaling, several FDA-approved systemic therapies for advanced disease disrupt this pathway through a variety of mechanisms including ligand depletion with androgen deprivation therapy (ADT) or CYP-17 inhibitors, or direct inhibition of the AR ligand binding domain with second-generation anti-androgens. However, resistance invariably emerges with a growing subset exhibiting androgen indifferent biology, which displays a particularly aggressive and lethal disease course that progresses rapidly despite treatment with potent androgen signaling inhibitors (ASIs). Effective treatments are lacking for patients who develop androgen indifferent prostate cancer (AIPC).

This review of androgen indifferent variants of metastatic castrate-resistant prostate cancer (mCRPC) summarizes our current understanding of the clinical, morphologic, and molecular features as well as current therapeutic approaches. We also explore emerging therapies and biomarkers aimed at improving outcomes for patients with AIPC.

## DEFINING CHARACTERISTICS OF AIPC VARIANTS

### Histological Variants of Prostate Cancer

Histologic variants of AIPC defined by tumor morphology include poorly differentiated neuroendocrine prostate carcinomas (encompassing both small cell prostate carcinoma [SCPC] and large cell neuroendocrine carcinoma [LCNEC]), sarcomatoid carcinomas, and squamous cell carcinomas. Histologic features of SCPC include scant cytoplasm, ill-defined borders, darkly stained nuclei with fine chromatin, absent nucleoli, nuclear molding, tumor necrosis, and frequent mitotic figures (1–4). LCNEC comprise large nesting patterns with peripheral palisading, abundant cytoplasm, prominent nucleoli, and tumor necrosis (1). Sarcomatoid carcinomas display undifferentiated spindled appearance with or without atypia, and squamous cell carcinomas demonstrate keratinization or eosinophilic cytoplasm with variable atypia (5, 6). Each of these variants may arise *de novo* or following treatment and may be pure or admixed with adenocarcinoma or other components (1–9).

### Neuroendocrine Prostate Cancer

The term neuroendocrine prostate cancer (NEPC), based on Epstein criteria (1), encompasses tumors with neuroendocrine morphology and includes SCPC, LNEC, and tumors with mixed adenocarcinoma and neuroendocrine histology (1). Immunohistochemistry (IHC) is not required to meet these criteria. Other studies have included prostate adenocarcinoma with immunohistochemical staining of classical NE markers such as chromogranin A, synaptophysin, CD56, neuron specific enolase (NSE), and bombesin into the definition of NEPC (2). These morphology- and IHC-based definitions often overlap, but in some cases would result in differential classification of a tumor (Table 1). NEPC can present *de novo*, typically as SCPC, or as an emergent phenotype in men

with existing prostate adenocarcinoma (PRAD). NEPC that develops in men with mCRPC after treatment with ASI therapy has been termed treatment-emergent NEPC (t-NEPC) or castration-resistant NEPC (CRPC-NE or CR-NEPC) to be distinguished from castration-resistant prostate adenocarcinoma (CRPC-Adeno or CR-PRAD).

### **Aggressive Variant Prostate Cancer**

The observation that some patients present with atypical, virulent clinical features and androgen indifference without the characteristic SCPC morphology led to the definition of *aggressive variant prostate cancers* (AVPC). This refers to a group of tumors of heterogeneous morphologies (including SCPC but also conventional PRAD and poorly differentiated carcinomas with or without NE differentiation) that meet at least one of the following clinicopathological features: 1) exclusive visceral metastases; 2) radiographically evident lytic bone metastases; 3) bulky lymphadenopathy ( $> 5$  cm) or bulky high-grade mass ( $> 5$  cm, Gleason  $\geq 8$ ) in the prostate or pelvis; 4) low PSA ( $< 10$  ng/mL) at initial presentation (before ADT) or at the time of symptomatic progression of castrate resistant disease plus high volume ( $> 20$ ) bone metastases; 5) serum CEA and/or LDH twice the upper limit of normal; 6) short interval ( $< 6$  months) to castration-resistant progression following initiation of hormonal therapy; 7) SCPC morphology. The number of criteria met is significantly associated with shorter survival independent of neuroendocrine marker expression (10). The purpose of the AVPC definition was to provide a framework for developing effective therapies for AIPCs extending beyond those with NEPC histology. The term “*anaplastic*” was previously used to describe this group of tumors; however, it is now reserved for describing pleomorphic histologic features, not clinical features.

### **Double Negative Prostate Cancer**

Evaluation of clinical samples has identified a subset of CR-PRAD tumors that lack expression of both AR and NE markers termed double negative prostate cancer (DNPC). Both clinically and in pre-clinical studies, these tumors demonstrate androgen indifference and are thought to represent resistant tumor clones following initial response to ASIs. It has been hypothesized that DNPC may represent an intermediate stage between androgen responsive prostate cancer and NEPC (11).

### **Prevalence and Clinical Relevance**

Significant heterogeneity exists not only within the defining characteristics of AIPC variants, but also their prevalence and clinical relevance. There is a growing consensus in the field that the prevalence of AIPC is increasing, potentially due to greater awareness as well as the increased use of potent ASIs, such as abiraterone, enzalutamide, and other next-generation AR antagonists. This is highlighted by an autopsy study of patients dying with mCRPC spanning two decades (11). Markers of AR signaling (AR and PSA) and NE differentiation (chromogranin and synaptophysin) were analyzed using IHC in 300 tumors from 84 patients. The proportion of patients with AR-negative tumors was 11.6% in the pre-ASI era (1998–2011) and 36.7% in the modern era (2012–2106). Both the prevalence of NEPC (6.3% to 13.3%) and DNPC (5.4% to 23.3%) increased during this time. Two contemporary studies of men with mCRPC found that 11–17% of metastatic tumor biopsies harbored morphologic features of NEPC and that NEPC was present at higher rates after

treatment with an ASI (7, 12). *De novo* SCPC is rare with most of the literature comprising small series, so the prevalence is not known. It is estimated that approximately 30% of men with metastatic prostate cancer meet AVPC clinical criteria(13).

Expression of NE markers in the absence of SCPC morphology is associated with poor prognosis and castration resistance, but not clearly linked with the virulent clinical course, androgen indifference or sensitivity to platinum-based chemotherapy that characterize tumors with SCPC morphology (14–19). Generally, however, most AIPC variants are clinically virulent with rapid progression despite treatment with ASIs and are thus termed “androgen indifferent” (1–6). Whether they are truly indifferent to androgens or to canonical AR signaling is not established. SEER data indicates that 60% of patients with SCPC present with metastatic disease with overall 1-, 2-, and 5-year survival of 48%, 28%, and 14% (20). A retrospective analysis found that median overall survival (OS) was significantly shorter in patients with pure SCPC (22.0 months) (whether *de novo* or treatment-related) compared to mixed histology tumors with neuroendocrine features (71.6 months). Additionally, patients with *de novo* SCPC had significantly shorter OS compared to those with CR-NEPC (16.8 versus 53.5 months) (21). Another study found that men with CR-NEPC had significantly shorter OS (hazard ratio of 2.02; 95% confidence interval [CI] 1.07–3.82) compared to those with CR-PRAD following treatment with potent ASIs (7). Features portending a poorer outcome in CR-NEPC include SCPC histology, lack of progressive PSA rise, elevated LDH, and liver metastases (7–9, 21). The AVPC criteria were created to identify patients predicted to have aggressive disease that is unlikely to respond to ASI therapy, thus by definition is clinically relevant. The subsequent section discusses the published data on clinical management of NEPC and AVPC. The clinical relevance of DNPC from a prognostic and therapeutic standpoint is not known.

## CURRENT THERAPIES

The optimal therapeutic approach for patients with AIPC is not clearly defined. Localized *de novo* SCPC is rare and there is no high-quality data to guide management. The NCCN Prostate Cancer guidelines refer clinicians to guidelines for small cell lung cancer (SCLC), which recommends radiation with etoposide plus cisplatin chemotherapy. More commonly, histologic or morphologic NE features are admixed with PRAD in a primary localized tumor. No data exists to suggest that this entity should be treated differently than localized PRAD, thus standard guidelines for local management should be followed.

Given its characteristic androgen indifference, metastatic pure SCPC is typically unresponsive to ADT, rendering conventional therapeutic approaches ineffective. Due to potential heterogeneity within these tumors, however, it is advisable to continue ADT. Treatment recommendations are extrapolated from data in SCLC where multiple studies have demonstrated efficacy of etoposide plus cisplatin or carboplatin (22–28). As a result, NCCN guidelines suggest etoposide plus platinum-based chemotherapy as first-line therapy for metastatic pure SCPC (29). The IMpower133 study showed a modest survival benefit with the addition of atezolizumab to first-line cisplatin and etoposide in SCLC and may be considered for off-label use in SCPC (30). Additionally, pembrolizumab is approved for

metastatic SCLC following platinum-based chemotherapy and at least one additional line of prior therapy (31).

More commonly, CR-NEPC presents as a morphologically mixed tumor in the mCRPC setting when a biopsy is obtained following progression on ASI therapy. The NCCN Prostate Cancer guidelines (Version 2.2020 – May 21, 2020) state that if histologic evidence of both PRAD and NEPC is present, selection of subsequent treatment to target either the PRAD or NEPC component can be prioritized based on the clinical context. Optimal sequencing of therapies targeting the CR-PRAD versus CR-NEPC tumor clone is not established. Clinical features such as significantly discordant PSA and burden of disease or morphologic features of NEPC (as opposed to IHC expression of NE markers alone) may suggest benefit to prioritizing therapy targeting the androgen indifferent disease with platinum-based chemotherapy.

Several clinical studies support the use of platinum-based chemotherapy in NEPC. A retrospective analysis of mCRPC patients treated with platinum chemotherapy found that patients with *de novo* or treatment-emergent NEPC had a significantly higher response rate (63%) than those with PRAD (14%) (32). In a Phase 2 study of 36 patients with SCPC, the combination of doxorubicin, etoposide, and cisplatin resulted in an objective response rate of 61% with median progression-free survival (PFS) of 5.8 months and median OS of 10.5 months (17). In a small Phase 2 study of 13 patients with NEPC (including 11 with pure or mixed SCPC) cisplatin-based chemotherapy resulted in an objective response rate of 66.6% with one complete response (33). In a Phase 2 study of 41 patients with AIPC and supranormal serum NE markers, combination chemotherapy with docetaxel and cisplatin resulted in an objective response rate of 41%, a PSA response of 48%, and median PFS and OS of 4 and 12 months, respectively (16). In contrast, the Phase 2 GETUG P01 trial reported an objective response rate of only 8.7% with etoposide plus carboplatin in mCRPC patients with visceral metastases or CR-NEPC defined by high serum levels of chromogranin A and neuron-specific enolase (34).

Two prospective clinical trials support that patients meeting criteria for AVPC are likely to benefit from platinum-based combination chemotherapy, regardless of morphology and neuroendocrine marker expression. In a single arm Phase II study, 113 men meeting AVPC criteria were treated with frontline carboplatin plus docetaxel followed by salvage cisplatin plus etoposide upon progression. The median PFS following carboplatin plus docetaxel was 5.1 months, and the median OS was 16.0 months (95% CI 13.6–19.0) (10). In a follow-up randomized Phase II study, 160 men with mCRPC were stratified by the presence of AVPC clinicopathological criteria and randomized to cabazitaxel with or without carboplatin. The PFS hazard ratio (HR) for men meeting AVPC criteria treated with the combination versus single agent cabazitaxel was 0.58 (95% CI 0.37–0.89), while only 0.74 (95% CI 0.46–1.21) in men that did not meet AVPC criteria (35).

## MOLECULAR FEATURES

Androgen indifferent tumors represent a heterogeneous subset of prostate cancer. Molecular characterization of AIPC has identified recurrent molecular features and alterations in several pathways as described below (Table 1; Figure 1).

### Androgen Receptor Signaling

As some cases of androgen indifferent tumors arise through divergent clonal evolution from CR-PRAD, these tumors may exhibit overlapping molecular alterations with PRAD (36). For example, approximately 50% of NEPC tumors harbor *ERG* rearrangements, a defining feature observed at a similar frequency in PRAD (37). This molecular alteration is a useful clinical biomarker in neuroendocrine tumors of unknown origin as *ERG* rearrangements are characteristically absent in high-grade neuroendocrine cancers arising from other tissues, such as lung and bladder (38).

Compared to CR-PRAD tumors, CR-NEPC tumors harbor a low frequency of *AR* mutations and amplifications with evidence of low AR expression and attenuated *AR* signaling. As a result, there is decreased expression of AR target genes including *KLK3*, which encodes PSA (1, 7, 11, 36). The paucity of *AR* alterations in CR-NEPC tumors is thought to be due to clonal selection of CR-PRAD cells that are androgen indifferent under the selective pressure of potent ASI therapy. However, in another series of treatment-emergent CR-NEPC tumors, the majority retained strong nuclear AR staining. Attenuated signaling through traditional AR target genes despite persistent AR expression suggests that the AR cistrome may be epigenetically reprogrammed as tumors transform from PRAD to NEPC. Loss of AR expression may be a later stage event.

### Proneural Transcription Factors

Cellular states are often characterized by the expression of lineage-specific transcription factors. Accordingly, NEPC tumors express a distinct set of proneural transcription factors including *BRN2*, *BRN4*, *MYCN*, *FOXA2*, *ASCL1*, and *INSM1* (39–43). While suppressed by AR in PRAD, *BRN2* is expressed at high levels in NEPC tumors. A pre-clinical *in vitro* model demonstrated that *BRN2* is not only upregulated, but also necessary and sufficient for induction of NE markers in AIPC cells (40). A subsequent patient-derived xenograft model showed that *BRN4* is overexpressed in NEPC samples and drives neuroendocrine differentiation via direct interaction with *BRN2* (39). Likewise, integration of a genetically-engineered mouse model and human prostate cancer transcriptome data demonstrated that overexpression of N-Myc (*MYCN*) leads to attenuation of AR signaling, induction of the Polycomb Repressive Complex 2 (*PRC2*), and development of poorly differentiated prostate cancer that is molecularly similar to human NEPC (41). *FOXA2* is a pioneer transcription factor that is specifically expressed in SCPC and may serve as a sensitive and specific diagnostic biomarker of NEPC (42).

### Epigenetic Alterations

*EZH2*, the functional enzymatic component of *PRC2* responsible for histone methylation, leading to repression of gene transcription, has long been associated with aggressive



prostate cancer (44, 45). More recently, EZH2 expression was found to be significantly higher in CR-NEPC compared to CR-PRAD tumors (36). Consistent with its repressive role, EZH2 target genes, including *WNT*, *DKK1*, *NDK1*, and HOX-encoding genes are also significantly downregulated in CR-NEPC. Pre-clinical studies demonstrate that EZH2 promotes neuroendocrine trans-differentiation and works in concert with N-Myc to drive tumor aggressiveness (41, 46). In addition to NEPC, epigenetic alterations are present in other AIPC variants. Polycomb Repressive Complex 1 (PRC1) recognizes the H3K27me3 mark created by PRC2 and monoubiquitinates histone H2A, resulting in chromatin compaction and transcriptional repression. PRC1 is active in DNPC, driving tumor progression by promoting self-renewal and angiogenesis (47).

In addition to, and likely in part as a result of alterations in *PRC1/2*, AIPC is defined by global epigenetic differences. Beltran et al performed DNA methylation profiling of 10 CR-NEPC and 18 CR-PRAD tumors (36). Unsupervised clustering based on DNA methylation resulted in clean partitioning of CR-NEPC and CR-PRAD tumors. The three CR-PRAD tumors (by histology) that clustered with the CR-NEPC tumors all displayed clinical features of androgen indifference. This data highlights that methylation profiling provides instructive information about tumor biology, such as androgen indifference, not captured by traditional histology-based tumor assessment.

### Epithelial-Mesenchymal Transition (EMT) and Stem Cell Markers

Epigenetic and transcriptomic analysis of CR-NEPC and CR-PRAD tumors identified cell-cell adhesion, EMT, and stem cell programs as highly dysregulated in NEPC relative to PRAD. For example, *SPDEF*, a transcription factor reported to suppress tumor metastasis through inhibition of EMT in prostate cancer, is amongst the most hypermethylated genes in NEPC relative to PRAD (36, 48). Accordingly, *SPDEF* expression is lower in NEPC, suggesting that de-repression of EMT pathways is a hallmark of CR-NEPC. The transcription factor *SOX2*, is essential for maintenance of embryonic and neural stem cells. In both pre-clinical models and patient samples, *SOX2* is upregulated in NEPC relative to PRAD tumors (7, 49). The tumor suppressor genes *TP53* and *RBI*, which are both involved in suppression of *SOX2*, are frequently altered in NEPC (50, 51). Loss of *TP53* and *RBI* is thought to result in de-repression of epigenetic reprogramming factors, such as *SOX2*, creating a stem cell-like environment permissive of trans-differentiation from PRAD to NEPC as a mechanism of resistance to potent ASI therapy (49, 52, 53).

### Tumor Suppressor Genes

AIPC tumors display a high frequency of *TP53*, *RBI*, and *PTEN* loss (54). Integration of IHC, copy number, and patient-derived xenograft data obtained from a Phase 2 study of men with tumors meeting AVPC clinicopathological criteria identified combined deleterious alterations in *RBI* (copy number loss or negative IHC), *TP53* (copy number loss, mutations), and *PTEN* (copy number loss) as a distinctive molecular profile (55). Pre-clinical studies reveal that concurrent alterations in these tumor suppressor genes result in aggressive, resistant neoplasms and is associated with lineage plasticity, androgen indifference, and DNA damage response signaling (49, 52, 56–60). The AVPC molecular signature (AVPC-ms), defined as two or more alterations (by IHC and/or genomic alteration) involving *RBI*,

*TP53*, and *PTEN*, was studied as a potential predictive biomarker of response to platinum-based chemotherapy in a Phase 1/2 study comparing cabazitaxel plus carboplatin to cabazitaxel monotherapy in mCRPC. A post-hoc analysis found that patients with AVPC-ms experienced significantly longer median PFS (7.5 versus 1.7 months) and median OS (20.2 versus 8.5 months) when treated with cabazitaxel plus carboplatin compared to cabazitaxel alone. AVPC-ms negative patients did not benefit from the addition of carboplatin to cabazitaxel (35). Further validation of the AVPC-ms as a predictive biomarker is planned as part of a Phase 3 study of cabazitaxel plus carboplatin. The ability of the AVPC-ms to predict for poor response to potent ASIs (ADT, abiraterone, and apalutamide) is being assessed as a part of the ongoing Phase 2 DynAMo study in CRPC ([NCT02703623](https://clinicaltrials.gov/ct2/show/study/NCT02703623)).

### Mitotic Genes

Androgen indifferent prostate tumors demonstrate upregulation of mitotic genes. Aurora kinase A (*AURKA*) is a cell cycle kinase that functions in mitotic spindle formation and chromosome segregation (61). *AURKA* is overexpressed in AIPC and has been shown to stabilize N-Myc to induce neuroendocrine differentiation with observed reversal of the neuroendocrine phenotype after treatment with an Aurora kinase inhibitor (62). Expression of *AURKA* has also been linked mechanistically to *TP53* mutation through increased expression of *miR-25* leading to reduced levels of *FBXW7* which encodes an E3 ubiquitin ligase that regulates *AURKA* (63). Upregulation of the mitotic gene *UBE2C*, along with a lack of cyclin D1 and *RBI* expression, was reported in *AR*-null SCPC and LCNEC xenografts compared to conventional PRAD. This signature was confirmed in clinical CRPC samples with SCPC/LCNEC morphology (64).

### DNA Damage Repair Alterations

Defects in DNA damage repair (DDR) genes have been observed in a variety of malignancies with a reliance on compensatory mechanisms and represent an opportunity for cancer treatment. This is particularly important in tumor-suppressor deficient, highly proliferative, platinum-sensitive, androgen indifferent tumors. A subset of DDR-associated genes have been shown to be co-regulated by AR and the transcription factor c-Myb in mCRPC as a compensatory response to deficiencies in DNA repair processes. In AR-negative prostate cancer, c-Myb is de-repressed and may substitute as the dominant regulator of common DDR target genes which have been correlated with aggressive clinical features (63). Upregulation of DDR genes in NEPC and a subset of CR-PRAD has also been associated with activation of PARP1/2 by N-Myc (46). Further, co-deletion of *RBI* and *BRCA2* has been shown to induce EMT and is associated with an aggressive phenotype that is attenuated by PARP inhibitor use (65). Lastly, recent data suggests that expression of DNA/RNA helicase Schlafen Family Member 11 (*SLFN11*), an inhibitor of checkpoint maintenance and homologous recombination repair, may predict sensitivity to platinum chemotherapy in mCRPC tumors. Transcriptomic profiling of mCRPC tumors, and IHC analysis of CTCs from men with mCRPC, identified *SLFN11* to be independently predictive of response to platinum chemotherapy. Further, *SLFN11* knockout in patient-derived organoids significantly attenuated response to platinum chemotherapy. (66).



## Fibroblast Growth Factor (FGF) & Mitogen-Activated Protein Kinase (MAPK) Pathways

Pre-clinical studies have identified the FGF and MAPK pathways as mechanisms of sustained growth in experimentally-derived androgen indifferent LNCaP cells. This finding was validated with clinical data as gene sets reflecting FGF and MAPK activity were enriched in DNPC metastases relative to PRAD tumors. Further, in an independent set of CR-PRAD tumors, FGF and MAPK activity were found to be inversely correlated with AR signaling. FGF activity can be driven through both autocrine and paracrine signaling (11).

## Immune Profiles

RNA expression analysis of CRPC tumors identified *PRCI* upregulation in DNPC samples. Subsequent pre-clinical studies demonstrated that *PRCI* upregulation governs recruitment of M2-like tumor-associated macrophages and regulatory T cells, thus suppressing both the innate and adaptive immune system and creating a profoundly immunosuppressive and proangiogenic microenvironment in metastatic sites (47).

PD-1/PD-L1 expression and tumor mutational burden are predictive biomarkers for response to immune checkpoint inhibitors in some, but not all, malignancies. Immunohistochemical analysis revealed that PD-L1 staining is more common in CR-NEPC (41%) compared with CR-PRAD (10%) tumors (67). An independent analysis of RNA-sequencing and whole-exome sequencing data supported these findings, reporting that PD-L1 expression in CR-NEPC tumors is higher than CR-PRAD tumors (68). In contrast, PD-1 expression is significantly lower in CR-NEPC than CR-PRAD tumors. Median TMB was comparable in CR-NEPC and CR-PRAD tumors (38.0 vs 37.0,  $p=0.44$ ), but CR-NEPC tumors showed significantly lower expression of immune cytokines. By comparison, median TMB of NEPC was significantly lower than SCLC (38.0 vs 142.5,  $p<0.001$ ). Understanding the prevalence of high TMB and/or microsatellite instability and their predictive value in AIPC remains an area of unmet need.

## EMERGING THERAPIES

Informed by an evolving understanding of the underlying biology of androgen indifferent tumors, multiple molecularly targeted therapies are under active clinical investigation (Table 2). In addition to the traditional goal of cancer regression, some therapies targeting AIPC seek to reprogram and restore androgen sensitivity.

## Cancer Regression

Delta-like protein 3 (DLL3) is a transmembrane inhibitory ligand of the Notch receptor pathway with aberrant overexpression on the surface of NEPC as well as small cell lung cancer (SCLC) tumors. In prostate cancer, DLL3 expression is enriched in CR-NEPC tumors (76.6%) compared to CR-PRAD tumors (12.5%), and is notably absent in benign prostate tissue (69). Rovalpituzumab tesirine (Rova-T) is a DLL3-targeted antibody-drug conjugate that first demonstrated antitumor activity in pre-clinical models and early-phase clinical trials of SCLC (70, 71). Subsequent *in vitro* and patient-derived xenograft studies confirmed pre-clinical efficacy of Rova-T in DLL3-positive NEPC (69). A case report of a patient with biopsy-proven NEPC who progressed on platinum-based chemotherapy, but

had marked radiographic shrinkage in metastatic disease burden after one cycle of Rova-T further strengthened the rationale for clinical development of this therapeutic approach in patients with DLL3-positive mCRPC (69). A press release in August 2019, however, reported that Rova-T failed to meet its primary endpoint of improving OS in the Phase 3 MERU clinical trial in SCLC (NCT03033511) resulting in termination of its development. In spite of this setback, DLL3-directed therapy remains a promising therapeutic approach in patients with NEPC. The anti-DLL3 x CD3 Bi-specific T cell Engager (BiTE) AMG757 (Amgen) and the DLL3-targeted Tri-specific T cell Activating Construct (Tri-Tac) HPN328 (Harpoon) are now entering clinical trials for patients with NEPC and other small cell /NE cancers.

Notably, tumor mutation burden, a genomic biomarker predictive of response to immune checkpoint inhibitors, was significantly lower in CR-NEPC than SCLC tumors (67). How these findings will translate to clinical efficacy will be answered by three ongoing clinical trials investigating immunotherapy in NEPC: 1) Phase 1b/2 study of pembrolizumab plus BXCL701, an oral innate immunity activator (NCT03910660); 2) Phase 2 study of avelumab (NCT03179410); 3) Phase 1 study of pembrolizumab in combination with platinum-based chemotherapy (NCT03582475) (Table 2).

CR-AVPC and SCLC share similar molecular profiles with frequent deleterious alterations in the tumor suppressor genes *TP53*, *RBI*, and *PTEN* (55, 64). These similarities likely underlie their shared sensitivity to platinum-based chemotherapy (10, 35). In other solid tumors, platinum-sensitivity is a surrogate predictive biomarker for response to PARP inhibitors as both therapies have greater efficacy in patients with homologous recombination (HR) deficient tumors. Approximately 20% of mCRPC tumors harbor deleterious alterations in HR genes (72). Maintenance PARP inhibitor therapy in patients who respond to platinum-based chemotherapy has been demonstrated to significantly improve PFS in patients with ovarian and pancreatic cancer (73–75). This approach is now being assessed in an ongoing Phase 2 study of induction chemotherapy with carboplatin plus cabazitaxel followed by PARP inhibitor maintenance therapy with olaparib in men with CR-AVPC (NCT03263650). A planned study (NCT pending) will assess the efficacy and toxicity of adding PD-1 blockade to induction chemotherapy and maintenance PARP inhibition.

Molecular studies have identified aberrant FGF signaling as a potential driver of DNPC. Multiple efforts are underway to evaluate the efficacy of FGF-targeted therapy in mCRPC. TKI258 is an oral multi-kinase inhibitor with activity against FGF receptors (FGFR). A Phase 2 study of TKI258 in men with mCRPC has completed accrual, though results have not yet been reported (NCT00831792). Another ongoing Phase 2 clinical trial, specifically in men with CR-DNPC, is evaluating the efficacy of the FGFR-selective kinase inhibitor erdafitinib in combination with either enzalutamide or abiraterone (NCT03999515). Pre-clinical studies of DNPC demonstrated that PRC1 upregulation results in CCL2-mediated suppression of the innate and adaptive immune system (47). Although theoretical at this time, the investigators hypothesize that blocking this immunosuppressive pathway may sensitize CR-DNPC tumors and other immunologically “cold” mCRPC tumors to immunotherapy.

## Reprogramming and restoring androgen dependence

The oncogenic transcription factor N-Myc is over-expressed in NEPC and has been demonstrated in pre-clinical models to suppress AR signaling and drive aggressive prostate cancer (36, 41). Although pharmacologic inhibition of transcription factors is notoriously challenging, numerous therapeutic approaches to inhibit MYC by targeting transcriptional and post-translational regulation are under investigation (76). Aurora kinase A (AURKA) binds to and stabilizes N-Myc, resulting in a potentially targetable dependency in NEPC (77). Pre-clinical studies confirmed that pharmacologic inhibition of AURKA results in decreased N-Myc protein levels, decreased N-Myc target gene expression, and decreased cell viability (41). Unfortunately, a Phase 2 clinical trial of the selective AURKA inhibitor alisertib in men with metastatic prostate cancer enriched for NEPC failed to meet its primary endpoint, though exceptional responses were observed. One patient who developed innumerable lung and liver metastases and biopsy-proven NEPC after 12 months of primary ADT had complete resolution of visceral metastases after 12 weeks of alisertib monotherapy that was maintained for 14 months (78). This exceptional responder highlights the need for predictive biomarkers to identify patients who will benefit from AURKA-directed therapy.

N-Myc forms a complex with EZH2 to induce EZH2-mediated transcriptional changes that drive transformation towards the NEPC phenotype (41). *EZH2* is one of the highest expressed genes in CR-NEPC relative to CR-PRAD and is a promising therapeutic target for NEPC with numerous EZH2 inhibitors already evaluated in Phase 1 clinical trials (36). EZH2 inhibition restores AR signaling and may re-sensitize NEPC cells to ASI therapy in pre-clinical studies (41, 49). The Phase 1b/2 ProSTAR Study ([NCT03480646](#)) is investigating the EZH2 inhibitor CPI-1205 in combination with either enzalutamide or abiraterone plus prednisone in men with mCRPC who have progressed on the other potent ASIs. Preliminary data suggests that the combinations are well-tolerated with clinical responses (PSA decrease by 80%, CTC reduction by 30%, and radiographic responses by RECIST criteria) reported, though the efficacy and applicability based on clinical or molecular subgroups is not yet known (79). Other EZH2 inhibitors in early clinical development for prostate cancer include PF-06821497 ([NCT03460977](#)) and tazemostat ([NCT04179864](#)).

## NOVEL BIOMARKERS

Disease activity in men with prostate cancer is typically monitored with PSA. However, AIPCs typically have downregulated AR signaling, often resulting in lower PSA expression that is discordant from disease burden (1). Some subsets, such as DNPC, are exclusively diagnosed by pathologic analysis of tumor tissue (11). One shortcoming of this approach is the lack of consensus pathologic features to identify AIPC variants. For example, neuroendocrine marker expression (i.e. chromogranin A, synaptophysin, CD56, neuron specific enolase (NSE), and bombesin) by IHC has not been shown to demonstrate prognostic or predictive significance (80–82). Additionally, tumor biopsy samples may not capture the overall disease due to intra-patient tumor heterogeneity (36, 83, 84). These limitations of the current diagnostic approach highlight the need for novel non-invasive and radiographic biomarkers to identify men with AIPC variants who may benefit from non-AR

targeted therapies. While the diagnostics discussed below demonstrate great promise for earlier and more accurate detection and classification of AIPC variants in the future, these biomarkers are still in the investigational stage. The standard of care diagnostic approach for men with CRPC progressing after treatment with potent ASIs is metastatic tumor biopsy for pathologic and genomic analysis.

### RNA Expression-Based Analysis

Given the challenges of identifying NEPC based on current diagnostics, Beltran et al developed an RNA expression-based NEPC classifier (36). Using transcriptomic data from CR-NEPC and CR-PRAD tumors, 70 differentially expressed genes were used to build an NEPC classifier, which demonstrated >99% precision in an initial discovery cohort. Evaluation of transcriptomic data in an external cohort of 683 prostate cancer tumors identified an elevated NEPC classifier score in 8% of metastatic tumors and none of the treatment-naive PRAD or benign prostate samples. More than 80% of the tumors with an elevated NEPC classifier score had pathologic features of NEPC. Further, the NEPC classifier demonstrated superior precision compared to conventional neuroendocrine markers, PSA, AR expression, and AR signaling. In an independent analysis of RNA expression data of 119 mCRPC tumors, unsupervised clustering of the transcriptomic data identified a cluster enriched for CR-NEPC tumors (7). A gene expression signature of NEPC was developed that demonstrated 91% accuracy on internal cross validation. When applied to an external cohort of mCRPC tumors, the NEPC signature demonstrated high accuracy. All TCGA primary prostate cancer tumors were accurately classified as PRAD. Subsequent studies have suggested that low PSA, high grade localized tumors and mCRPC may share NEPC characteristics based on transcriptome analysis (85, 86). Significant limitations of this transcriptome-based diagnostic approach include the need to obtain tissue and the potential for sampling error as a single metastatic foci may not be representative a patient's overall disease.

### Cell-free DNA

Profiling of cell-free DNA (cfDNA) is a promising approach for non-invasive detection of tumor-specific genetic and epigenetic features. Tumor-derived DNA is detectable in the majority of patients with mCRPC (87, 88). Advantages of cfDNA as a diagnostic tool in mCRPC include 1) facilitating tumor analysis when tissue is challenging to obtain, 2) being less subject to the sampling error introduced by a single tissue biopsy of a heterogeneous tumor, and 3) feasibility of serial samples to temporally assess tumor evolution. Although a rapidly evolving field, data on the clinical feasibility of cfDNA for detection of AIPC is limited. A tissue-based classifier has been published that integrates RNA-sequencing and DNA methylation data to determine with high precision if CRPC tumors are NEPC (36, 89). A recent study extended this analysis to cfDNA, leading to several important observations (83). First, genomic and epigenomic features (i.e., DNA methylation) of CR-NEPC are identifiable through plasma cfDNA analysis. This finding has important clinical implications as non-invasive diagnosis of CR-NEPC could identify patients who may benefit from platinum-based chemotherapy or other non-AR targeted therapies (10, 55). This study also reported the biological observation that cfDNA from patients with CR-NEPC were less heterogeneous than from those with CR-PRAD. This data suggests that during the transition

towards CR-NEPC, a dominant androgen indifferent clone (often harboring combined loss of *RBI* and *TP53*) is selected and persists due to the selective pressures of potent ASI therapy. Further studies are ongoing to determine the clinical utility of cfDNA to identify patients with AIPC who may benefit from non-ASI therapy. Recently, use of unbiased genome sequencing allowing for simultaneous detection of copy number alterations and exome mutations in cfDNA of CRPC patients distinguished those with platinum-sensitive tumors with plans for additional study (90).

### Circulating Tumor Cells

Circulating tumor cells (CTCs) provide the potential for real-time, non-invasive, molecular characterization to determine prognosis and individualize treatment decisions in men with mCRPC. An early study established the prognostic value of enumerating CTCs prior to initiating therapy in men with mCRPC, reporting unfavorable PFS and OS for men with 5 CTCs per 7.5 ml of blood (91). A subsequent study sought to identify molecular features that could be used to identify men with CR-NEPC (92). The investigators observed that low or absent AR expression, low cytokeratin expression, smaller morphology, and cell clusters were observed more frequently in CTCs from men with CR-NEPC compared to those with CR-PRAD. A classifier based on these characteristics was able to identify most cases of CR-NEPC, highlighting the potential of this diagnostic approach. The investigators then applied this classifier to a small cohort of “atypical CRPC” CTCs that were histologically adenocarcinoma but displayed evidence of androgen indifference, such as radiographic progression in the setting of low PSA. Compared to CR-PRAD samples, atypical CRPC was associated with greater CTC heterogeneity and a higher burden of NEPC-like cells. In another study of 47 patients with AVPC, CTCs were identified in 42.6% of patients (93). Copy number alterations in at least 2 tumor suppressor genes was associated with poor survival and increased genomic instability. Genomic instability, as measured by large scale transitions on CTC copy number analysis, was also independently associated with aggressive disease. Similarly, shorter PFS and OS were observed in patients with mCRPC whose CTCs were classified by the Epic CTC Platform as having a NE phenotype or chromosomal instability (94). Although further clinical validation is needed, these findings highlight the utility of CTCs for the detection of patients harboring AIPC and insights into disease biology.

### Imaging

Molecular imaging has demonstrated the ability for early and accurate detection of metastatic prostate cancer and providing novel insights into tumor biology, aggressiveness, and response to treatment. These imaging modalities consist of a radionuclide conjugated to a receptor-targeting agent or metabolic compound. The most widely-studied molecular imaging targets in prostate cancer include prostate specific membrane antigen (PSMA), a transmembrane glycoprotein overexpressed in prostate cancer cells, and dihydrotestosterone (DHT), the primary ligand for the AR (95). While PSMA and DHT are relatively specific for prostate cancer, compounds such as fluoro-2-D-deoxyglucose (FDG), choline, acetate, and fluciclovine more broadly detect metabolic activity. The different characteristics of these molecular imaging modalities present an exciting opportunity to correlate radiographic findings with tumor biology.

FDG PET imaging has been studied specifically in prostate cancer with positive expression of serum NE markers. A case series of 23 patients and 592 unique lesions compared PET, CT, and bone scan. Only 22.2% of bone lesions were detected by PET compared to 92.7% and 77.6% for CT and bone scan respectively. 95.1% soft tissue lesions were detected by PET compared to 97.5% with CT, with a possible association between PET avidity and patient survival less than 2.2 years. However, this study selected for tumors solely based on neuroendocrine marker expression and did not account for the presence or absence of clinically virulent features making it difficult to extrapolate to androgen indifferent tumors (96).

Transcriptomic analysis of mCRPC tumors demonstrated that PSMA expression is significantly lower in CR-NEPC than CR-PRAD tumors (97). This suggests that lesions, which display evidence of metabolic activity, but are PSMA negative may be more likely to be AIPC. A subset analysis of patients with mCRPC who underwent FDG and PSMA PET supports this hypothesis. The 16 patients whose imaging showed discordant FDG-positive PSMA-low or -negative lesions had a dismal prognosis with median overall survival of 2.5 months (98). Although this study did not perform biopsies to correlate radiographic features with tumor pathology, this clinical association suggests that patients with FDG-positive PSMA-negative lesions display an aggressive disease course, often associated with AIPC.

The potential benefit of more specific targeting towards prostate cancer is highlighted in a study of 133 patients with mCRPC who underwent imaging with both DHT and choline positron emission tomography (PET) (99). The majority of lesions (71.2%) were positive for both DHT and choline (AR<sub>1</sub>Glyc<sub>1</sub>), however a subset (12.7%) were DHT negative and choline positive (AR<sub>0</sub>Glyc<sub>1</sub>). In total 49% of patients had an AR<sub>0</sub>Glyc<sub>1</sub> lesion, which on multi-variate analysis was associated with a significant increase in the hazard of death. To better understand the association between radiographic findings and tumor biology, the investigators obtained 57 biopsies, 12 of which were consistent with poorly differentiated prostate cancer. Of the 8 lesions that were PSA positive by IHC, 7 were AR<sub>1</sub>. All 4 lesions that were PSA negative were AR<sub>0</sub>. This suggests a strong association between DHT PET negativity and androgen indifferent biology on a lesion-by-lesion basis. A similar trend has been reported for PSMA, whereby a large transcriptome-based analysis of mCRPC tumors demonstrated an inverse correlation of PSMA levels with expression of neuroendocrine markers (100). This pattern is borne out clinically, as highlighted in a case report of a patient with a peritoneal metastasis with moderate radiotracer uptake and a liver metastasis with no uptake on PSMA PET. Tissue obtained from the two lesions demonstrated moderate and absent PSMA expression, respectively. Further, the liver lesion stained negative for AR, was strongly positive for synaptophysin, and harbored alterations in *TP53* and *RB1* (101). In contrast, efforts to exploit the somatostatin receptors with Ga-68-DOTATOC PET/CT in prostate cancer with neuroendocrine marker expression have been disappointing to date with weak expression of DOTATOC-affine somatostatin receptors compared to gastrointestinal and pancreatic neuroendocrine tumors (102). Ongoing studies to understand the correlation between molecular imaging and tumor biology will enhance our understanding of AIPC variants.



## CONCLUSION

AIPC is an increasingly recognized disease variant in men with mCRPC that generally emerges as a resistance phenotype following treatment with potent therapy to suppress androgen signaling. While there is significant clinical and biological heterogeneity within AIPC, significant progress has been made to understand the molecular underpinnings of NEPC, AVPC, and DNPC. However, the ability to detect AIPC in clinical practice and effectively treat it remain significant barriers. At this time, we therefore recommend performing metastatic tumor biopsies in men progressing following treatment with potent ASI therapy for pathologic and genomic analysis. This approach can identify potentially clinically actionable tumor features including 1) AIPC variants, 2) biomarkers predictive of response to FDA approved targeted therapies (e.g. DDR alterations for PARP inhibitors and microsatellite instability for pembrolizumab), and 3) tumor alterations under investigation in clinical trials. Plasma genotyping is another options when tissue is unobtainable.

A panel of experts recently published a list of critical unanswered scientific questions regarding the role of lineage plasticity in androgen receptor independent prostate cancer (103). Building upon this, we believe that the following issues must be addressed to improve outcomes for patients diagnosed with androgen indifferent prostate cancer: agreeing upon a consensus definition for the distinct AIPC variants, developing diagnostics for early and accurate detection of clinically actionable variants, further characterizing the molecular drivers of each AIPC phenotype, and developing effective variant-specific targeted therapies. Given the adverse outcomes associated with AIPC, efforts are underway to overcome these barriers. CTCs, cfDNA, and molecular imaging appear poised to provide objective tools non-invasive and radiographic detection of AIPC. Further, several clinical trials are underway evaluating novel therapeutic approaches in patients with androgen independent prostate cancer informed by an understanding of variant-specific biology. Finally, correlative translational research studying patient samples from clinical trials in AIPC will be critical to furthering our understanding of this challenging disease.

## ACKNOWLEDGMENTS

J.E.B is supported by the Department of Defense (W81XWH-20-1-0118). H.B. is supported by the Prostate Cancer Foundation, National Cancer Institute (1R37 CA241486-01A1, P50 CA211024) and Department of Defense (W81XWH-17-1-0653). A.A. is supported by the MD Anderson Moonshot Program, the Prostate Cancer Foundation, the Emerson Collective, National Cancer Institute (P50 CA140388-08A1, U01 CA224044) and Department of Defense (PC190353 and PC200135).

### CONFLICT OF INTEREST

H.B. has received research funding from Janssen, AbbVie Stemcentrx, Astellas, Eli Lilly, and Millennium, and has served as advisor/consultant for Janssen, Astellas, Amgen, Astra Zeneca, Pfizer, Blue Earth Diagnostics, and Sanofi Genzyme.

A.A. has received research funding from Janssen, Bristol Myers Squibb, Sanofi Genzyme, Glaxo Smith Kline, Daiichi Sankyo and Astra Zeneca, and has served as advisor/consultant for Janssen, Sanofi Genzyme, Glaxo Smith Kline, Astellas, Amgen and Astra Zeneca.

## REFERENCES

1. Epstein JI, Amin MB, Beltran H, Lotan TL, Mosquera JM, Reuter VE, et al. Proposed morphologic classification of prostate cancer with neuroendocrine differentiation. *The American journal of surgical pathology*. 2014;38(6):756–67. [PubMed: 24705311]
2. Parimi V, Goyal R, Poropatich K, Yang XJ. Neuroendocrine differentiation of prostate cancer: a review. *American journal of clinical and experimental urology*. 2014;2(4):273–85. [PubMed: 25606573]
3. Wang W, Epstein JI. Small cell carcinoma of the prostate. A morphologic and immunohistochemical study of 95 cases. *The American journal of surgical pathology*. 2008;32(1):65–71. [PubMed: 18162772]
4. Yao JL, Madeb R, Bourne P, Lei J, Yang X, Tickoo S, et al. Small Cell Carcinoma of the Prostate: An Immunohistochemical Study. *The American journal of surgical pathology*. 2006;30(6):705–12. [PubMed: 16723847]
5. Manucha V, Henegan J. Clinicopathologic Diagnostic Approach to Aggressive Variant Prostate Cancer. *Archives of pathology & laboratory medicine*. 2020;144(1):18–23. [PubMed: 31403335]
6. Palmgren JS, Karavadia SS, Wakefield MR. Unusual and underappreciated: small cell carcinoma of the prostate. *Seminars in oncology*. 2007;34(1):22–9. [PubMed: 17270662]
7. Aggarwal R, Huang J, Alumkal JJ, Zhang L, Feng FY, Thomas GV, et al. Clinical and Genomic Characterization of Treatment-Emergent Small-Cell Neuroendocrine Prostate Cancer: A Multi-institutional Prospective Study. *Journal of clinical oncology : official journal of the American Society of Clinical Oncology*. 2018;36(24):2492–503. [PubMed: 29985747]
8. Nadal R, Schweizer M, Kryvenko ON, Epstein JI, Eisenberger MA. Small cell carcinoma of the prostate. *Nature Reviews Urology*. 2014;11(4):213–9. [PubMed: 24535589]
9. Spiess PE, Pettaway CA, Vakar-Lopez F, Kassouf W, Wang X, Busby JE, et al. Treatment outcomes of small cell carcinoma of the prostate: a single-center study. *Cancer*. 2007;110(8):1729–37. [PubMed: 17786954]
10. Aparicio AM, Harzstark AL, Corn PG, Wen S, Araujo JC, Tu SM, et al. Platinum-based chemotherapy for variant castrate-resistant prostate cancer. *Clinical cancer research : an official journal of the American Association for Cancer Research*. 2013;19(13):3621–30. [PubMed: 23649003]
11. Bluemn EG, Coleman IM, Lucas JM, Coleman RT, Hernandez-Lopez S, Tharakan R, et al. Androgen Receptor Pathway-Independent Prostate Cancer Is Sustained through FGF Signaling. *Cancer cell*. 2017;32(4):474–89.e6. [PubMed: 29017058]
12. Abida W, Cyrta J, Heller G, Prandi D, Armenia J, Coleman I, et al. Genomic correlates of clinical outcome in advanced prostate cancer. *Proc Natl Acad Sci U S A*. 2019;116(23):11428–11436. [PubMed: 31061129]
13. Aparicio A, Zhang M, Ramesh N, Wang X, Corn PG, Zurita AJ, et al. Aggressive variant prostate cancer (AVPC) molecular signature in castration-sensitive, de novo metastatic prostate cancer (MIPCa). *Journal of Clinical Oncology*. 2019;37(15\_suppl):5052-.
14. Amato RJ, Logothetis CJ, Hallinan R, Ro JY, Sella A, Dexeus FH. Chemotherapy for small cell carcinoma of prostatic origin. *J Urol*. 1992;147(3 Pt 2):935–7. [PubMed: 1311396]
15. Berruti A, Mosca A, Tucci M, Terrone C, Torta M, Tarabuzzi R, et al. Independent prognostic role of circulating chromogranin A in prostate cancer patients with hormone-refractory disease. *Endocrine-related cancer*. 2005;12(1):109–17. [PubMed: 15788643]
16. Culine S, El Demery M, Lamy PJ, Iborra F, Avances C, Pinguet F. Docetaxel and cisplatin in patients with metastatic androgen independent prostate cancer and circulating neuroendocrine markers. *J Urol*. 2007;178(3 Pt 1):844–8; discussion 8. [PubMed: 17631339]
17. Papandreou CN, Daliani DD, Thall PF, Tu SM, Wang X, Reyes A, et al. Results of a phase II study with doxorubicin, etoposide, and cisplatin in patients with fully characterized small-cell carcinoma of the prostate. *Journal of clinical oncology : official journal of the American Society of Clinical Oncology*. 2002;20(14):3072–80. [PubMed: 12118020]

18. Steineck G, Reuter V, Kelly WK, Frank R, Schwartz L, Scher HI. Cytotoxic treatment of aggressive prostate tumors with or without neuroendocrine elements. *Acta Oncol.* 2002;41(7–8):668–74. [PubMed: 14651212]
19. Taplin ME, George DJ, Halabi S, Sanford B, Febbo PG, Hennessy KT, et al. Prognostic significance of plasma chromogranin a levels in patients with hormone-refractory prostate cancer treated in Cancer and Leukemia Group B 9480 study. *Urology.* 2005;66(2):386–91. [PubMed: 16098367]
20. Deorah S, Rao MB, Raman R, Gaitonde K, Donovan JF. Survival of patients with small cell carcinoma of the prostate during 1973–2003: a population-based study. *BJU international.* 2012;109(6):824–30. [PubMed: 21883857]
21. Conteduca V, Oromendia C, Eng KW, Bareja R, Sigouros M, Molina A, et al. Clinical features of neuroendocrine prostate cancer. *European journal of cancer (Oxford, England : 1990).* 2019;121:7–18.
22. Fukuoka M, Furuse K, Saijo N, Nishiwaki Y, Ikegami H, Tamura T, et al. Randomized Trial of Cyclophosphamide, Doxorubicin, and Vincristine Versus Cisplatin and Etoposide Versus Alternation of These Regimens in Small-Cell Lung Cancer. *JNCI: Journal of the National Cancer Institute.* 1991;83(12):855–61. [PubMed: 1648142]
23. Joss RA, Alberto P, Hürny C, Bacchi M, Leyvraz S, Thürlimann B, et al. Quality versus quantity of life in the treatment of patients with advanced small-cell lung cancer? A randomized phase III comparison of weekly carboplatin and teniposide versus cisplatin, adriamycin, etoposide alternating with cyclophosphamide, methotrexate, vincristine and lomustine. *Swiss Group for Clinical Cancer Research (SAKK). Annals of oncology : official journal of the European Society for Medical Oncology.* 1995;6(1):41–8.
24. Lee SM, James L, Qian W, Spiro S, Eisen T, Gower N, et al. Comparison of gemcitabine and carboplatin versus cisplatin and etoposide for patients with poor-prognosis small cell lung cancer. *Thorax.* 2009;64(1):75–80. [PubMed: 18786981]
25. Okamoto H, Watanabe K, Kunikane H, Yokoyama A, Kudoh S, Asakawa T, et al. Randomised phase III trial of carboplatin plus etoposide vs split doses of cisplatin plus etoposide in elderly or poor-risk patients with extensive disease small-cell lung cancer: JCOG 9702. *British journal of cancer.* 2007;97(2):162–9. [PubMed: 17579629]
26. Roth BJ, Johnson DH, Einhorn LH, Schacter LP, Cherng NC, Cohen HJ, et al. Randomized study of cyclophosphamide, doxorubicin, and vincristine versus etoposide and cisplatin versus alternation of these two regimens in extensive small-cell lung cancer: a phase III trial of the Southeastern Cancer Study Group. *Journal of clinical oncology : official journal of the American Society of Clinical Oncology.* 1992;10(2):282–91. [PubMed: 1310103]
27. Skarlos DV, Samantas E, Kosmidis P, Fountzilas G, Angelidou M, Palamidas P, et al. Randomized comparison of etoposide-cisplatin vs. etoposide-carboplatin and irradiation in small-cell lung cancer. A Hellenic Co-operative Oncology Group study. *Annals of oncology : official journal of the European Society for Medical Oncology.* 1994;5(7):601–7. [PubMed: 7993835]
28. Sundstrøm S, Bremnes RM, Kaasa S, Aasebø U, Hatlevoll R, Dahle R, et al. Cisplatin and etoposide regimen is superior to cyclophosphamide, epirubicin, and vincristine regimen in small-cell lung cancer: results from a randomized phase III trial with 5 years' follow-up. *Journal of clinical oncology : official journal of the American Society of Clinical Oncology.* 2002;20(24):4665–72. [PubMed: 12488411]
29. Mohler JL, Antonarakis ES. NCCN Guidelines Updates: Management of Prostate Cancer. *Journal of the National Comprehensive Cancer Network : JNCCN.* 2019;17(5.5):583–6. [PubMed: 31117038]
30. Horn L, Mansfield AS, Szczesna A, Havel L, Krzakowski M, Hochmair MJ, et al. First-Line Atezolizumab plus Chemotherapy in Extensive-Stage Small-Cell Lung Cancer. *The New England journal of medicine.* 2018;379(23):2220–9. [PubMed: 30280641]
31. Chung HC, Piha-Paul SA, Lopez-Martin J, Schellens JHM, Kao S, Miller WH Jr., et al. Pembrolizumab After Two or More Lines of Previous Therapy in Patients With Recurrent or Metastatic SCLC: Results From the KEYNOTE-028 and KEYNOTE-158 Studies. *J Thorac Oncol.* 2020;15(4):618–27. [PubMed: 31870883]

32. Humeniuk MS, Gupta RT, Healy P, McNamara M, Ramalingam S, Harrison M, et al. Platinum sensitivity in metastatic prostate cancer: does histology matter? *Prostate cancer and prostatic diseases*. 2018;21(1):92–9. [PubMed: 29230006]
33. Sella A, Konichezky M, Flex D, Sulkes A, Baniel J. Low PSA metastatic androgen- independent prostate cancer. *European urology*. 2000;38(3):250–4. [PubMed: 10940696]
34. Flechon A, Pouessel D, Ferlay C, Perol D, Beuzebec P, Gravis G, et al. Phase II study of carboplatin and etoposide in patients with anaplastic progressive metastatic castration-resistant prostate cancer (mCRPC) with or without neuroendocrine differentiation: results of the French Genito-Urinary Tumor Group (GETUG) P01 trial. *Annals of oncology*. 2011;22(11):2476–81. [PubMed: 21436186]
35. Corn PG, Heath EI, Zurita A, Ramesh N, Xiao L, Sei E, et al. Cabazitaxel plus carboplatin for the treatment of men with metastatic castration-resistant prostate cancers: a randomised, open-label, phase 1–2 trial. *The Lancet Oncology*. 2019;20(10):1432–43. [PubMed: 31515154]
36. Beltran H, Prandi D, Mosquera JM, Benelli M, Puca L, Cyrta J, et al. Divergent clonal evolution of castration-resistant neuroendocrine prostate cancer. *Nature medicine*. 2016;22(3):298–305.
37. Scheble VJ, Braun M, Wilbertz T, Stiedl AC, Petersen K, Schilling D, et al. ERG rearrangement in small cell prostatic and lung cancer. *Histopathology*. 2010;56(7):937–43. [PubMed: 20636794]
38. Lotan TL, Gupta NS, Wang W, Toubaji A, Haffner MC, Chau A, et al. ERG gene rearrangements are common in prostatic small cell carcinomas. *Modern pathology : an official journal of the United States and Canadian Academy of Pathology, Inc*. 2011;24(6):820–8.
39. Bhagirath D, Yang TL, Tabatabai ZL, Majid S, Dahiya R, Tanaka Y, et al. BRN4 Is a Novel Driver of Neuroendocrine Differentiation in Castration-Resistant Prostate Cancer and Is Selectively Released in Extracellular Vesicles with BRN2. *Clinical cancer research : an official journal of the American Association for Cancer Research*. 2019;25(21):6532–45. [PubMed: 31371344]
40. Bishop JL, Thaper D, Vahid S, Davies A, Ketola K, Kuruma H, et al. The Master Neural Transcription Factor BRN2 Is an Androgen Receptor-Suppressed Driver of Neuroendocrine Differentiation in Prostate Cancer. *Cancer discovery*. 2017;7(1):54–71. [PubMed: 27784708]
41. Dardenne E, Beltran H, Benelli M, Gayvert K, Berger A, Puca L, et al. N-Myc Induces an EZH2-Mediated Transcriptional Program Driving Neuroendocrine Prostate Cancer. *Cancer cell*. 2016;30(4):563–77. [PubMed: 27728805]
42. Park JW, Lee JK, Witte ON, Huang J. FOXA2 is a sensitive and specific marker for small cell neuroendocrine carcinoma of the prostate. *Modern pathology : an official journal of the United States and Canadian Academy of Pathology, Inc*. 2017;30(9):1262–72.
43. Tsai HK, Lehrer J, Alshalalfa M, Erho N, Davicioni E, Lotan TL. Gene expression signatures of neuroendocrine prostate cancer and primary small cell prostatic carcinoma. *BMC Cancer*. 2017;17(1):759. [PubMed: 29132337]
44. Karanikolas BD, Figueiredo ML, Wu L. Comprehensive evaluation of the role of EZH2 in the growth, invasion, and aggression of a panel of prostate cancer cell lines. *The Prostate*. 2010;70(6):675–88. [PubMed: 20087897]
45. Yu J, Yu J, Rhodes DR, Tomlins SA, Cao X, Chen G, et al. A polycomb repression signature in metastatic prostate cancer predicts cancer outcome. *Cancer research*. 2007;67(22):10657–63. [PubMed: 18006806]
46. Zhang Y, Zheng D, Zhou T, Song H, Hulsurkar M, Su N, et al. Androgen deprivation promotes neuroendocrine differentiation and angiogenesis through CREB-EZH2-TSP1 pathway in prostate cancers. *Nat Commun*. 2018;9(1):4080. [PubMed: 30287808]
47. Su W, Han HH, Wang Y, Zhang B, Zhou B, Cheng Y, et al. The Polycomb Repressor Complex 1 Drives Double-Negative Prostate Cancer Metastasis by Coordinating Stemness and Immune Suppression. *Cancer cell*. 2019;36(2):139–55.e10. [PubMed: 31327655]
48. Steffan JJ, Koul S, Meacham RB, Koul HK. The transcription factor SPDEF suppresses prostate tumor metastasis. *J Biol Chem*. 2016;291(39):20826. [PubMed: 27664067]
49. Ku SY, Rosario S, Wang Y, Mu P, Seshadri M, Goodrich ZW, et al. Rb1 and Trp53 cooperate to suppress prostate cancer lineage plasticity, metastasis, and antiandrogen resistance. *Science (New York, NY)*. 2017;355(6320):78–83.

50. Choi YJ, Lin CP, Ho JJ, He X, Okada N, Bu P, et al. miR-34 miRNAs provide a barrier for somatic cell reprogramming. *Nat Cell Biol.* 2011;13(11):1353–60. [PubMed: 22020437]
51. Kareta MS, Gorges LL, Hafeez S, Benayoun BA, Marro S, Zmoos AF, et al. Inhibition of pluripotency networks by the Rb tumor suppressor restricts reprogramming and tumorigenesis. *Cell Stem Cell.* 2015;16(1):39–50. [PubMed: 25467916]
52. Mu P, Zhang Z, Benelli M, Karthaus WR, Hoover E, Chen CC, et al. SOX2 promotes lineage plasticity and antiandrogen resistance in TP53- and RB1-deficient prostate cancer. *Science (New York, NY).* 2017;355(6320):84–8.
53. Park JW, Lee JK, Sheu KM, Wang L, Balanis NG, Nguyen K, et al. Reprogramming normal human epithelial tissues to a common, lethal neuroendocrine cancer lineage. *Science (New York, NY).* 2018;362(6410):91–5.
54. Cancer Genome Atlas Research N. The Molecular Taxonomy of Primary Prostate Cancer. *Cell.* 2015;163(4):1011–25. [PubMed: 26544944]
55. Aparicio AM, Shen L, Tapia EL, Lu JF, Chen HC, Zhang J, et al. Combined Tumor Suppressor Defects Characterize Clinically Defined Aggressive Variant Prostate Cancers. *Clinical cancer research : an official journal of the American Association for Cancer Research.* 2016;22(6):1520–30. [PubMed: 26546618]
56. Gingrich JR, Barrios RJ, Foster BA, Greenberg NM. Pathologic progression of autochthonous prostate cancer in the TRAMP model. *Prostate cancer and prostatic diseases.* 1999;2(2):70–5. [PubMed: 12496841]
57. Karanika S, Karantanos T, Li L, Corn PG, Thompson TC. DNA damage response and prostate cancer: defects, regulation and therapeutic implications. *Oncogene.* 2015;34(22):2815–22. [PubMed: 25132269]
58. Kwabi-Addo B, Giri D, Schmidt K, Podsypanina K, Parsons R, Greenberg N, et al. Haploinsufficiency of the Pten tumor suppressor gene promotes prostate cancer progression. *Proceedings of the National Academy of Sciences of the United States of America.* 2001;98(20):11563–8. [PubMed: 11553783]
59. Zhou Z, Flesken-Nikitin A, Corney DC, Wang W, Goodrich DW, Roy-Burman P, et al. Synergy of p53 and Rb deficiency in a conditional mouse model for metastatic prostate cancer. *Cancer research.* 2006;66(16):7889–98. [PubMed: 16912162]
60. Zou M, Toivanen R, Mitrofanova A, Floch N, Hayati S, Sun Y, et al. Transdifferentiation as a Mechanism of Treatment Resistance in a Mouse Model of Castration-Resistant Prostate Cancer. *Cancer discovery.* 2017;7(7):736–49. [PubMed: 28411207]
61. Kivinummi K, Urbanucci A, Leinonen K, Tammela TLJ, Annala M, Isaacs WB, et al. The expression of AURKA is androgen regulated in castration-resistant prostate cancer. *Sci Rep.* 2017;7(1):17978. [PubMed: 29269934]
62. Beltran H, Rickman DS, Park K, Chae SS, Sboner A, MacDonald TY, et al. Molecular characterization of neuroendocrine prostate cancer and identification of new drug targets. *Cancer discovery.* 2011;1(6):487–95. [PubMed: 22389870]
63. Li L, Chang W, Yang G, Ren C, Park S, Karantanos T, et al. Targeting poly(ADP-ribose) polymerase and the c-Myb-regulated DNA damage response pathway in castration-resistant prostate cancer. *Sci Signal.* 2014;7(326):ra47. [PubMed: 24847116]
64. Tzelepi V, Zhang J, Lu JF, Kleb B, Wu G, Wan X, et al. Modeling a lethal prostate cancer variant with small-cell carcinoma features. *Clinical cancer research : an official journal of the American Association for Cancer Research.* 2012;18(3):666–77. [PubMed: 22156612]
65. Chakraborty G, Armenia J, Mazzu YZ, Nandakumar S, Stopsack KH, Atiq MO, et al. Significance of BRCA2 and RB1 Co-loss in Aggressive Prostate Cancer Progression. *Clinical Cancer Research.* 2020;26(8):2047–64. [PubMed: 31796516]
66. Conteduca V, Ku S-Y, Puca L, Slade M, Fernandez L, Hess J, et al. SLFN11 Expression in Advanced Prostate Cancer and Response to Platinum-based Chemotherapy. *Molecular Cancer Therapeutics.* 2020;19(5):1157–64. [PubMed: 32127465]
67. Nappi L, Kesch C, Vahid S, Fazli L, Eigl BJ, Kollmannsberger CK, et al. Immunogenomic landscape of neuroendocrine small cell prostate cancer. *Journal of Clinical Oncology.* 2019;37(7\_suppl):217-.

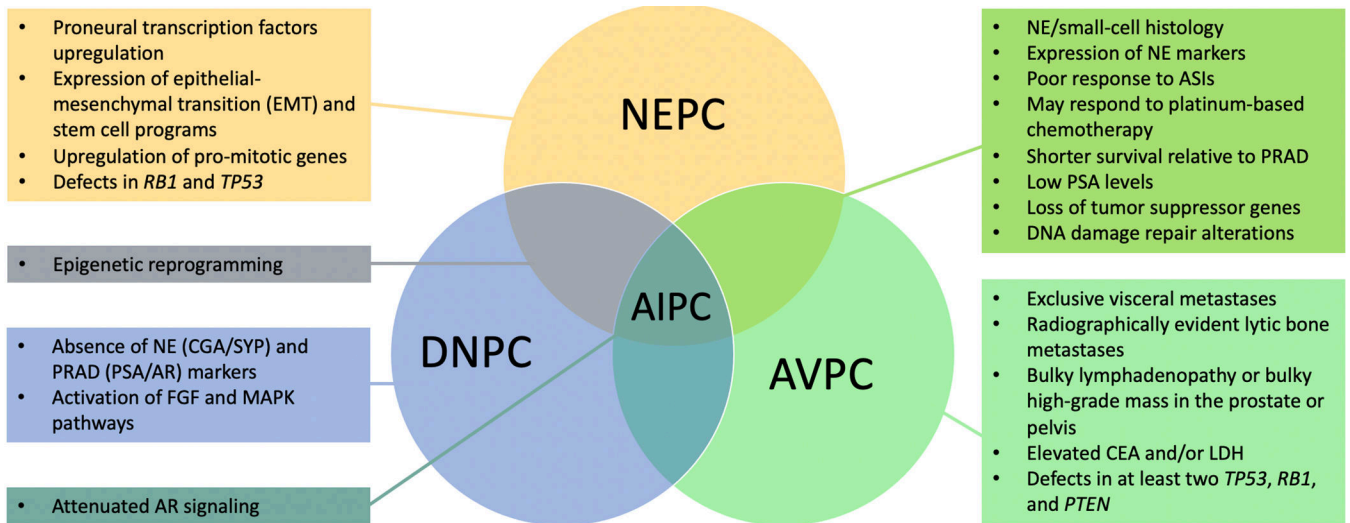


68. Ferguson AM, Bhinder B, Conteduca V, Sigouros M, Sboner A, Nanus D, et al. Abstract 134: Immunogenomic landscape of neuroendocrine prostate cancer (NEPC). *Cancer research*. 2019;79(13 Supplement):134-.
69. Puca L, Gavyert K, Sailer V, Conteduca V, Dardenne E, Sigouros M, et al. Delta-like protein 3 expression and therapeutic targeting in neuroendocrine prostate cancer. *Science translational medicine*. 2019;11(484).
70. Rudin CM, Pietanza MC, Bauer TM, Ready N, Morgensztern D, Glisson BS, et al. Rovalpituzumab tesirine, a DLL3-targeted antibody-drug conjugate, in recurrent small-cell lung cancer: a first-in-human, first-in-class, open-label, phase 1 study. *The Lancet Oncology*. 2017;18(1):42–51. [PubMed: 27932068]
71. Saunders LR, Bankovich AJ, Anderson WC, Aujay MA, Bheddah S, Black K, et al. A DLL3-targeted antibody-drug conjugate eradicates high-grade pulmonary neuroendocrine tumor-initiating cells in vivo. *Science translational medicine*. 2015;7(302):302ra136.
72. Robinson D, Van Allen EM, Wu YM, Schultz N, Lonigro RJ, Mosquera JM, et al. Integrative clinical genomics of advanced prostate cancer. *Cell*. 2015;161(5):1215–28. [PubMed: 26000489]
73. Coleman RL, Fleming GF, Brady MF, Swisher EM, Steffensen KD, Friedlander M, et al. Veliparib with First-Line Chemotherapy and as Maintenance Therapy in Ovarian Cancer. *The New England journal of medicine*. 2019;381(25):2403–15. [PubMed: 31562800]
74. Golan T, Hammel P, Reni M, Van Cutsem E, Macarulla T, Hall MJ, et al. Maintenance Olaparib for Germline BRCA-Mutated Metastatic Pancreatic Cancer. *The New England journal of medicine*. 2019;381(4):317–27. [PubMed: 31157963]
75. González-Martín A, Pothuri B, Vergote I, DePont Christensen R, Graybill W, Mirza MR, et al. Niraparib in Patients with Newly Diagnosed Advanced Ovarian Cancer. *The New England journal of medicine*. 2019;381(25):2391–402. [PubMed: 31562799]
76. Allen-Petersen BL, Sears RC. Mission Possible: Advances in MYC Therapeutic Targeting in Cancer. *BioDrugs : clinical immunotherapeutics, biopharmaceuticals and gene therapy*. 2019;33(5):539–53.
77. Otto T, Horn S, Brockmann M, Eilers U, Schüttrumpf L, Popov N, et al. Stabilization of N-Myc is a critical function of Aurora A in human neuroblastoma. *Cancer cell*. 2009;15(1):67–78. [PubMed: 19111882]
78. Beltran H, Oromendia C, Danila DC, Montgomery B, Hoimes C, Szmulewitz RZ, et al. A Phase II Trial of the Aurora Kinase A Inhibitor Alisertib for Patients with Castration-resistant and Neuroendocrine Prostate Cancer: Efficacy and Biomarkers. *Clinical cancer research : an official journal of the American Association for Cancer Research*. 2019;25(1):43–51. [PubMed: 30232224]
79. Taplin M-E, Hussain A, Shah S, Shore ND, Edenfield WJ, Sartor OA, et al. Abstract CT094: Phase Ib results of ProSTAR: CPI-1205, EZH2 inhibitor, combined with enzalutamide (E) or abiraterone/prednisone (A/P) in patients with metastatic castration-resistant prostate cancer (mCRPC). *Cancer research*. 2019;79(13 Supplement):CT094–CT.
80. Casella R, Bubendorf L, Sauter G, Moch H, Mihatsch MJ, Gasser TC. Focal neuroendocrine differentiation lacks prognostic significance in prostate core needle biopsies. *J Urol*. 1998;160(2):406–10. [PubMed: 9679888]
81. Cohen MK, Arber DA, Coffield KS, Keegan GT, McClintock J, Speights VO Jr. Neuroendocrine differentiation in prostatic adenocarcinoma and its relationship to tumor progression. *Cancer*. 1994;74(7):1899–903. [PubMed: 8082095]
82. Ishida E, Nakamura M, Shimada K, Tasaki M, Konishi N. Immunohistochemical analysis of neuroendocrine differentiation in prostate cancer. *Pathobiology*. 2009;76(1):30–8. [PubMed: 19188748]
83. Beltran H, Romanel A, Conteduca V, Casiraghi N, Sigouros M, Franceschini GM, et al. Circulating tumor DNA profile recognizes transformation to castration-resistant neuroendocrine prostate cancer. *The Journal of clinical investigation*. 2020;130(4):1653–68. [PubMed: 32091413]
84. Gundem G, Van Loo P, Kremeyer B, Alexandrov LB, Tubio JMC, Papaemmanuil E, et al. The evolutionary history of lethal metastatic prostate cancer. *Nature*. 2015;520(7547):353–7. [PubMed: 25830880]



85. Alumkal JJ, Sun D, Lu E, Beer TM, Thomas GV, Latour E, et al. Transcriptional profiling identifies an androgen receptor activity-low, stemness program associated with enzalutamide resistance. *Proceedings of the National Academy of Sciences of the United States of America*. 2020;117(22):12315–23. [PubMed: 32424106]
86. Mahal BA, Yang DD, Wang NQ, Alshalalfa M, Davicioni E, Choeurng V, et al. Clinical and Genomic Characterization of Low-Prostate-specific Antigen, High-grade Prostate Cancer. *European urology*. 2018;74(2):146–54. [PubMed: 29478736]
87. De Mattos-Arruda L, Weigelt B, Cortes J, Won HH, Ng CK, Nuciforo P, et al. Capturing intra-tumor genetic heterogeneity by de novo mutation profiling of circulating cell-free tumor DNA: a proof-of-principle. *Annals of oncology : official journal of the European Society for Medical Oncology*. 2014;25(9):1729–35. [PubMed: 25009010]
88. Mayrhofer M, De Laere B, Whittington T, Van Oyen P, Ghysel C, Ampe J, et al. Cell-free DNA profiling of metastatic prostate cancer reveals microsatellite instability, structural rearrangements and clonal hematopoiesis. *Genome medicine*. 2018;10(1):85. [PubMed: 30458854]
89. Abida W, Cyrta J, Heller G, Prandi D, Armenia J, Coleman I, et al. Genomic correlates of clinical outcome in advanced prostate cancer. *Proceedings of the National Academy of Sciences of the United States of America*. 2019;116(23):11428–36. [PubMed: 31061129]
90. Ramesh N, Sei E, Tsai PC, Logothetis C, Corn P, Aparicio A, et al. Abstract 446: Plasma genome sequencing identifies prostate cancer patients that are sensitive to platinum-based therapy. *Cancer research*. 2019;79(13 Supplement):446-.
91. de Bono JS, Scher HI, Montgomery RB, Parker C, Miller MC, Tissing H, et al. Circulating tumor cells predict survival benefit from treatment in metastatic castration-resistant prostate cancer. *Clinical cancer research : an official journal of the American Association for Cancer Research*. 2008;14(19):6302–9. [PubMed: 18829513]
92. Beltran H, Jendrisak A, Landers M, Mosquera JM, Kossai M, Louw J, et al. The Initial Detection and Partial Characterization of Circulating Tumor Cells in Neuroendocrine Prostate Cancer. *Clinical cancer research : an official journal of the American Association for Cancer Research*. 2016;22(6):1510–9. [PubMed: 26671992]
93. Malihi PD, Graf RP, Rodriguez A, Ramesh N, Lee J, Sutton R, et al. Single-Cell Circulating Tumor Cell Analysis Reveals Genomic Instability as a Distinctive Feature of Aggressive Prostate Cancer. *Clinical cancer research : an official journal of the American Association for Cancer Research*. 2020.
94. Brown LC, Halabi S, Schonhoft J, Luo J, Nanus DM, Giannakakou P, et al. Association of circulating tumor cell chromosomal instability with worse outcomes in men with mCRPC treated with abiraterone or enzalutamide. *Journal of Clinical Oncology*. 2020;38(6\_suppl):183-. [PubMed: 31794325]
95. Boustani AM, Pucar D, Saperstein L. Molecular imaging of prostate cancer. *The British journal of radiology*. 2018;91(1084):20170736. [PubMed: 29243485]
96. Spratt DE, Gavane S, Tarlinton L, Fareedy SB, Doran MG, Zelefsky MJ, et al. Utility of FDG-PET in clinical neuroendocrine prostate cancer. *The Prostate*. 2014;74(11):1153–9. [PubMed: 24913988]
97. Chu C, Alshalalfa M, Sjöström M, Zhao S, Herlemann A, Chou J, et al. Differential expression of PSMA and 18F-fluciclovine transporter genes in metastatic castrate-resistant and treatment-emergent small cell/neuroendocrine prostate cancer. *Journal of Clinical Oncology*. 2020;38(6\_suppl):24-.
98. Thang SP, Violet J, Sandhu S, Iravani A, Akhurst T, Kong G, et al. Poor Outcomes for Patients with Metastatic Castration-resistant Prostate Cancer with Low Prostate-specific Membrane Antigen (PSMA) Expression Deemed Ineligible for (177)Lu-labelled PSMA Radioligand Therapy. *Eur Urol Oncol*. 2019;2(6):670–6. [PubMed: 31412006]
99. Fox JJ, Gavane SC, Blanc-Autran E, Nehmeh S, Gönen M, Beattie B, et al. Positron Emission Tomography/Computed Tomography-Based Assessments of Androgen Receptor Expression and Glycolytic Activity as a Prognostic Biomarker for Metastatic Castration-Resistant Prostate Cancer. *JAMA oncology*. 2018;4(2):217–24. [PubMed: 29121144]

100. Bakht MK, Derecichei I, Li Y, Ferraiuolo RM, Dunning M, Oh SW, et al. Neuroendocrine differentiation of prostate cancer leads to PSMA suppression. *Endocrine-related cancer*. 2018;26(2):131–46. [PubMed: 30400059]
101. Tosoian JJ, Gorin MA, Rowe SP, Andreas D, Szabo Z, Pienta KJ, et al. Correlation of PSMA-Targeted (18)F-DCFPyL PET/CT Findings With Immunohistochemical and Genomic Data in a Patient With Metastatic Neuroendocrine Prostate Cancer. *Clinical genitourinary cancer*. 2017;15(1):e65–e8. [PubMed: 27751686]
102. Luboldt W, Zophel K, Wunderlich G, Abramyuk A, Luboldt HJ, Kotzerke J. Visualization of somatostatin receptors in prostate cancer and its bone metastases with Ga-68-DOTATOC PET/CT. *Mol Imaging Biol*. 2010;12(1):78–84. [PubMed: 19421819]
103. Beltran H, Hruszkewycz A, Scher HI, Hildesheim J, Isaacs J, Yu EY, et al. The Role of Lineage Plasticity in Prostate Cancer Therapy Resistance. *Clinical cancer research : an official journal of the American Association for Cancer Research*. 2019;25(23):6916–24. [PubMed: 31363002]
104. Têtu B, Ro JY, Ayala AG, Johnson DE, Logothetis CJ, Ordonez NG. Small cell carcinoma of the prostate. Part I. A clinicopathologic study of 20 cases. *Cancer*. 1987;59(10):1803–9. [PubMed: 3030528]
105. Labrecque MP, Coleman IM, Brown LG, True LD, Kollath L, Lakely B, et al. Molecular profiling stratifies diverse phenotypes of treatment-refractory metastatic castration-resistant prostate cancer. *The Journal of clinical investigation*. 2019;130(10):4492–505.



**Figure 1: Proposed characteristics of androgen indifferent prostate cancer.**

This figure highlights unique and overlapping clinical, histologic, and molecular characteristics of androgen indifferent prostate cancer variants. Abbreviations: NEPC, neuroendocrine prostate cancer; AVPC, aggressive variant prostate cancer; DNPC, double negative prostate cancer; AIPC, androgen indifferent prostate cancer; PRAD, prostate adenocarcinoma; ASI, androgen signaling inhibitor; CGA, chromogranin A; SYP, synaptophysin; AR, androgen receptor; PSA, prostate specific antigen.

**Table 1:**

Clinical and molecular features of androgen independent prostate cancer variants.

	<b>Small Cell Prostate Cancer</b>	<b>Castration-Resistant/Treatment-Emergent NEPC</b>	<b>PRAD with NE Differentiation</b>	<b>Aggressive Variant Prostate Cancer</b>	<b>Double Negative Prostate Cancer</b>
<b>Clinical context</b>	Localized (40%) or metastatic (60%) (20)	Metastatic	Localized or metastatic	Locally advanced or metastatic	Metastatic
<b>Typical Presentation</b>	De novo or following treatment with ADT and/or ARSI	Following treatment with ADT and/or ARSI	De novo or following treatment with ADT and/or ARSI	De novo or following treatment with ADT and/or ARSI	Following treatment with ADT and/or ARSI
<b>Method of Diagnosis</b>	Histology	Histology and IHC	Histology and IHC	Histology, IHC, imaging, and clinical data	IHC
<b>Clinical features</b>	Exclusive visceral metastases; Radiographically evident lytic bone metastases; Bulky lymphadenopathy ( 5 cm) or bulky high-grade mass ( 5 cm, Gleason 8) in the prostate or pelvis; Short interval ( 6 months) to castration (104), (17), (14)	No differences compared to non-small cell tumors (7)	No differences compared to PRAD	Exclusive visceral metastases; Radiographically evident lytic bone metastases; Bulky lymphadenopathy ( 5 cm) or bulky high-grade mass ( 5 cm, Gleason 8) in the prostate or pelvis; Short interval ( 6 months) to castration (10)	
<b>Histology</b>	Small cell	Small cell; adenocarcinoma plus >= 50% IHC staining for NE markers (36)	Adenocarcinoma with NE differentiation	Small cell; Poorly differentiated carcinoma with or without NE markers; PRAD with or without NE markers	Adenocarcinoma; squamous differentiation (rare) (105)
<b>IHC</b>	Expresses CGA, SYP, CD56, NSE; Absence of AR, PSA, PSAP, PSMA	Expresses CGA, SYP, NSE; Absence of AR, PSA, PSAP, PSMA (not required)	Expresses CGA, SYP, NSE	Combined defects in at least two of the following: TP53, RB1, PTEN (55)	Absence of AR, PSA, and SPC markers
<b>Median PSA (range)</b>	0.14 (0.05–0.96) (21)	0.38 (0–29.9) (36); 64.8 (0.4–1500) (7)		8.7 (0–924.7) (10)	
<b>Serum markers</b>	Elevated CGA, CEA, LDH (21), (17)	Elevated NSE and CGA (36), (7)		Low PSA ( 10 ng/mL) at initial presentation or at the time of symptomatic progression of castrate resistant disease; Elevated CEA and/or LDH (10)	
<b>Molecular features</b>	Likely similar to CR-NEPC	Loss of TP53 and RB1 (49), (89), (7); Expression of proneural TFs (eg MYCN, FOXA2, ASCL1, INSM1); Upregulation of EZH2 (36); Global DNA methylation reprogramming (36); Upregulation of stem cell and EMT markers (eg SOX2) (49)	Upregulation proneural TFs (eg INSM1, ASCL1, POU3F2, NKX2-1); Low expression of AR and AR regulated genes; Loss of REST; Upregulation of EMT genes (105)	Combined defects in at least two of the following: TP53, RB1, and PTEN (55)	Increased PRCl activity (47); Increased FGF and MAPK activity (11); Immunosuppressive and proangiogenic microenvironment (47); Upregulation of EMT genes (105)
<b>Reported % of advanced</b>	7% (89)	8% (36); 17% (7)	10% (11)		21% (11)

	Small Cell Prostate Cancer	Castration-Resistant/Treatment-Emergent NEPC	PRAD with NE Differentiation	Aggressive Variant Prostate Cancer	Double Negative Prostate Cancer
prostate cancer*					
<b>Prognosis</b>	Median survival 13–17 months (20), (21)	Median survival 37 months (7)	Little to no difference compared to PRAD (1)	Median survival 16 months (10)	

\* There is overlap between these variants, so proportions may not be cumulative.

Abbreviations: NEPC, neuroendocrine prostate cancer; PRAD, prostate adenocarcinoma; AR, androgen receptor; NE, neuroendocrine; ADT, androgen deprivation therapy; ARSI, androgen receptor signaling inhibitor; IHC, immunohistochemistry; PSA, prostate specific antigen; CGA, chromogranin A; SYP, synaptophysin; NSE, neuron specific enolase; LDH, lactate dehydrogenase; TF, transcription factor; EMT, epithelial-mesenchymal transition

**Table 2:**  
**List of ongoing clinical trials in androgen indifferent prostate cancer.**

Clinical trials enrolling patients with androgen indifferent prostate cancer. This includes clinical trials enrolling patients with “neuroendocrine prostate cancer,” “small cell prostate cancer,” “aggressive variant prostate carcinoma,” “double-negative prostate cancer,” or “extrapulmonary small cell carcinoma” whose status was listed as “Not yet recruiting,” “Recruiting,” or “Active, not recruiting” on [clinicaltrials.gov](http://clinicaltrials.gov) as of 10/27/20.

NCT#	Title	Phase	AIPC Variant Included	Status
NCT03179410	PD-L1 Inhibition as CheckPoint Immunotherapy for NeuroEndocrine Phenotype Prostate Cancer (PICK-NEPC)	Phase 2	NEPC	Active, not recruiting
NCT03263650	Study of Olaparib Maintenance Following Cabazitaxel-Carbo in Men With AVPC (C-COLA)	Phase 2	AVPC	Active, not recruiting
NCT033333616	Nivolumab Combined With Ipilimumab for Patients With Advanced Rare Genitourinary Tumors	Phase 2	NEPC	Recruiting
NCT03582475	Pembrolizumab With Combination Chemotherapy in Treating Participants With Locally Advanced or Metastatic Small Cell/Neuroendocrine Cancers of Urothelium or Prostate	Phase 1	NEPC	Recruiting
NCT03896503	Randomized Trial of Topotecan With M6620, an ATR Kinase Inhibitor, in Small Cell Lung Cancers and Small Cell Cancers Outside of the Lungs	Phase 2	Extrapulmonary SCC	Recruiting
NCT03910660	A Trial of BXCL701 and Pembrolizumab in Patients With mCRPC	Phase 1/2	NEPC	Recruiting
NCT03999515	Erdafitinib and Abiraterone Acetate or Enzalutamide in Treating Patients With Double Negative Prostate Cancer	Phase 2	DNPC	Recruiting
NCT04388852	DS3201 and Ipilimumab for the Treatment of Metastatic Prostate, Urothelial and Renal Cell Cancers	Phase 1	AVPC/NEPC	Recruiting
NCT04592237	Cabazitaxel, Carboplatin, and Cetrelimab Followed by Niraparib With or Without Cetrelimab for the Treatment of Aggressive Variant Metastatic Prostate Cancer	Phase 2	AVPC	Not yet recruiting
NCT02893917	Olaparib With or Without Cediramb in Treating Patients With Metastatic Castration-Resistant Prostate Cancer	Phase 2	NEPC	Active, not recruiting
NCT03866382	Testing the Effectiveness of Two Immunotherapy Drugs (Nivolumab and Ipilimumab) With One Anti-cancer Targeted Drug (Cabozantinib) for Rare Genitourinary Tumors	Phase 2	NEPC	Recruiting
NCT04471974	ZEN-3694, Enzalutamide, and Pembrolizumab for the Treatment of Metastatic Castration-Resistant Prostate Cancer	Phase 2	NEPC	Recruiting
NCT04209595	PLX038 (PEGylated SN38) and Rucaparib in Solid Tumors and Small Cell Cancers	Phase 1/2	Extrapulmonary SCC	Recruiting
NCT02487095	Trial of Topotecan With VX-970 (M6620), an ATR Kinase Inhibitor, in Small Cell Cancers and Extrapulmonary Small Cell Cancers	Phase 1/2	Extrapulmonary SCC	Recruiting
NCT03837977	Second-line Therapy for Patients With Progressive Poorly Differentiated Extra-pulmonary Neuroendocrine Carcinoma (NET02)	Phase 2	Extrapulmonary Poorly Differentiated Neuroendocrine Carcinoma	Recruiting

Abbreviations: AIPC, androgen indifferent prostate cancer; NEPC, neuroendocrine prostate cancer; AVPC, aggressive variant prostate cancer; mCRPC, metastatic castrate resistant prostate cancer; SCC, small cell carcinoma; DNPC, double negative prostate cancer