

# A new endoscopic scoring system corresponding to histological healing using linked color imaging in ulcerative colitis: the SOUL study



## Authors

Daisuke Saito<sup>1</sup>, Fumihito Hirai<sup>2</sup>, Kazuhiko Uchiyama<sup>3</sup>, Tomohisa Takagi<sup>3</sup>, Yuji Naito<sup>4</sup>, Noritaka Takatsu<sup>5</sup>, Hiroshi Tanabe<sup>6</sup>, Mitsuo Kishimoto<sup>7</sup>, Minoru Matsuura<sup>1</sup>, Jun Miyoshi<sup>1</sup>, Kenji Watanabe<sup>8</sup>, Motohiro Esaki<sup>9</sup>, Makoto Naganuma<sup>10</sup>, Tadakazu Hisamatsu<sup>1</sup>

## Institutions

- 1 Department of Gastroenterology and Hepatology, Kyorin University School of Medicine, Tokyo, Japan
- 2 Department of Gastroenterology and Medicine, Fukuoka University Faculty of Medicine, Fukuoka, Japan
- 3 Department of Gastroenterology and Hepatology, Molecular Gastroenterology and Hepatology, Kyoto Prefectural University of Medicine, Kyoto, Japan
- 4 Department of Human Immunology and Nutrition Science, Kyoto Prefectural University of Medicine, Kyoto, Japan
- 5 Inflammatory bowel disease center, Fukuoka University Chikushi Hospital, Fukuoka, Japan
- 6 Department of Pathology, Fukuoka University Chikushi Hospital, Fukuoka, Japan
- 7 Department of Surgical Pathology, Kyoto City Hospital, Kyoto, Japan
- 8 Center for Inflammatory Bowel Disease, Division of Gastroenterology and Hepatology, Department of Internal Medicine, Hyogo Medical University, Hyogo, Japan
- 9 Department of Gastroenterology and Hepatology, Saga University, Saga, Japan
- 10 Department of Gastroenterology and Hepatology, Kansai Medical University, Osaka, Japan

## Corresponding author

Tadakazu Hisamatsu, MD, PhD, AGAF, FACC, Department of Gastroenterology and Hepatology, Kyorin University School of Medicine, 6-20-2 Shinkawa, Mitaka-shi, Tokyo 181-8611, Japan  
 Fax: +81-422-71-5381  
 thisamatsu@ks.kyorin-u.ac.jp

## ABSTRACT

**Background and study aims** An important therapeutic aim in ulcerative colitis (UC) is endoscopic remission. Although an endoscopic score with white light imaging (WLI) is mainly used to evaluate endoscopic findings, the usefulness of linked color imaging (LCI) has been reported. We evaluated the relationship between LCI and histopathological findings and attempted to establish a new LCI endoscopic evaluation index for UC.

**Patients and methods** This study was conducted at Kyorin University, Kyoto Prefectural University, and Fukuoka University Chikushi Hospital. Ninety-two patients with a Mayo endoscopic subscore (MES)  $\leq 1$  who underwent colonoscopy for UC in clinical remission were included. LCI index was defined as redness (R) (Grade 0–2), area of inflammation (A) (Grade 0–3), and lymphoid follicles (L) (Grade 0–3). Histological healing was defined as Geboes score  $< 2B.1$ . Endoscopic and histopathological scores were determined by central judgment.

**Results** In 92 patients, 85 biopsies from the sigmoid colon and 84 biopsies from the rectum (total 169 biopsies) were evaluated. There were 22, 117, and 30 cases of Grades 0, 1, and 2, respectively in LCI index-R; 113, 34, 17, and five cases of Grades 0, 1, 2, and 3, respectively, in LCI index-A; and 124, 27, 14, and four cases of Grades 0, 1, 2, and 3, respectively, in LCI index-L. Histological healing was achieved in 84.0% of the cases (142 of 169), and there were significant associations with histological healing or non-healing in LCI index-R ( $P = 0.013$ ) and A ( $P = 0.0014$ ).

**Conclusions** A new LCI index is useful for predicting histological healing in UC patients with MES  $\leq 1$  and clinical remission.

submitted 5.10.2022

accepted after revision 29.3.2023

accepted manuscript online 3.4.2023

## Bibliography

Endosc Int Open 2023; 11: E504–E512

DOI 10.1055/a-2067-8943

ISSN 2364-3722

© 2023. The Author(s).

This is an open access article published by Thieme under the terms of the Creative Commons Attribution-NonDerivative-NonCommercial License, permitting copying and reproduction so long as the original work is given appropriate credit. Contents may not be used for commercial purposes, or adapted, remixed, transformed or built upon. (<https://creativecommons.org/licenses/by-nc-nd/4.0/>)

Georg Thieme Verlag KG, Rüdigerstraße 14,  
70469 Stuttgart, Germany

## Introduction

Ulcerative colitis (UC) is a chronic inflammatory disease of the colon that causes clinical symptoms such as bloody stools, diarrhea, and abdominal pain [1, 2]. Currently, one of the most important therapeutic targets for UC is endoscopic remission [3, 4], but the clinical symptoms do not always reflect the endoscopic findings [5]. Some patients in clinical remission still have colonic mucosal inflammation [6]. Several studies demonstrated that endoscopic remission is associated with better long-term prognosis, namely a reduction in disease relapse, hospitalization, and surgery [7–10]. Histological healing has drawn more attention for achieving better long-term outcomes beyond endoscopic remission [11–14]. Previous studies have demonstrated that histological indices can assess active colonic inflammation more precisely than endoscopic indices even in patients with clinically mild UC [15, 16]. These findings suggest that endoscopic evaluation is not enough to assess microscopic inflammation, which is detected as endoscopically invisible lesions, and histological healing can lead to better clinical outcomes. The recent Selecting Therapeutic Targets in Inflammatory Bowel Disease (STRIDE II) program [17] stated that a therapeutic target should be set to improve long-term outcomes in inflammatory bowel disease treatment. In STRIDE II, histological healing was proposed as a considerable target. However, there are some concerns about assessing histological healing. Biopsy can result in complications such as bleeding. In addition, histopathological evaluation is a burden for endoscopists and pathologists.

The LASEREO endoscopic system (Fujifilm Medical Co., Tokyo, Japan) uses a semi-conductor laser as the light source and has linked color imaging (LCI) [18]. LCI is an image-enhanced technology that can enhance slight color differences in the red region of the mucosa. Because it can emphasize redness, LCI is expected to effectively diagnose disease conditions that cause mucosal redness, such as inflammation.

Some reports have evaluated endoscopic inflammation of UC using LCI. Uchiyama et al. showed that LCI can subdivide the Mayo endoscopic subscore (MES), a widely used endoscopic score, with WLI [19]. They evaluated 193 areas in 52 patients with UC by LCI. LCI patterns were classified from A to C (A, no redness; B, redness with visible vessels; and C, redness without visible vessels). In the results, even MES 0 was sub-classified by LCI, and LCI classification was well correlated with the histopathological Matts score. Takagi et al. examined 26 UC patients with MES 0 and demonstrated that the non-relapse rate was significantly higher in patients with no redness by LCI observation [20].

However, a large multicenter study is still needed to confirm the usefulness of LCI in clinical practice for UC. In addition, the correlation of LCI findings with histopathology has not yet been fully investigated. Here, we conducted a multicenter study to assess LCI and histological findings to establish a new LCI endoscopic evaluation index for UC.

## Patients and methods

### Patient enrollment

This study (score evaluation for observation of patients with UC using LCI: The SOUL study) was conducted at three tertiary institutions (Kyorin University Hospital, Kyoto Prefectural University of Medicine, and Fukuoka University Chikushi Hospital) between November 2016 and February 2019 (UMIN000030412). Patients who were in clinical and endoscopic remission were enrolled in this study. UC diagnosis was determined based on clinical, endoscopic, radiological, and histological criteria according to the clinical practice guidelines for inflammatory bowel disease by the Japanese Society of Gastroenterology [21]. Patient characteristics, treatments, and blood examination results were obtained from the medical records at each institution.


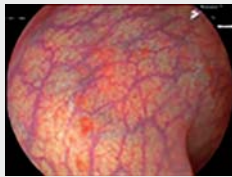

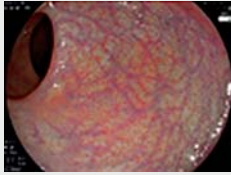

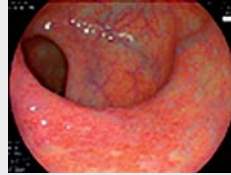

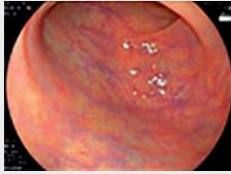
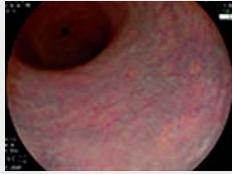
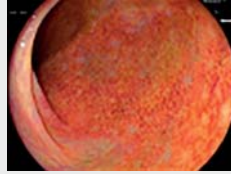
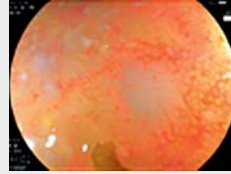
### Clinical disease activity

Clinical disease activity was evaluated using the partial Mayo score, which was previously used in several clinical trials [22–24]. Clinical remission was defined as a rectal bleeding subscore of 0 (no rectal bleeding) and a stool frequency subscore of either 0 (normal stool frequency for the patient) or 1 (1 or 2 more daily stools than normal).

### Endoscopic evaluation

Endoscopic activity with WLI was assessed using MES [25]. Endoscopic remission was defined as  $MES \leq 1$ . All examinations were performed with a high-definition EG-L590WR endoscope as part of the LASEREO endoscopic system (Fujifilm Medical Co., Tokyo, Japan). Colonoscopy was performed on the enrolled patients, and the rectum and sigmoid colon were observed.

First, observation was performed with WLI, and MES was evaluated. Patients with  $MES \geq 2$  were excluded. Next, observation was performed with LCI. Referring to the previous LCI classification based on the report by Uchiyama et al. [19], we evaluated the degree of redness. We also evaluated the area of inflammation and lymphoid follicles, which have not been analyzed as an item by conventional endoscopic observation with WLI. Briefly, endoscopic findings with LCI were classified as LCI index-R (redness), LCI index-A (area of inflammation), and LCI index-L (lymphoid follicular) (► **Fig. 1**). In addition, each LCI index was classified as Grade 0–2 or 0–3. LCI index-R was defined as: Grade 0, no redness; Grade 1, redness with visible vessels; and Grade 2, redness without visible vessels. LCI index-A was defined as: Grade 0, up to 1 of 4 screen; Grade 1, up to 2 of 4 screen; Grade 2, up to 3 of 4 screen; and Grade 3, over Grade 2. LCI index-L was defined as: Grade 0, no lymphoid follicular; Grade 1, slightly visible lymphoid follicles; Grade 2, clearly visible lymphoid follicles; and Grade 3, lymphatic follicles with angiogenesis. These evaluations were made by three central endoscopic judgment committee members who are experts in colonoscopy for UC. Discussions were held among the three members, and when two or more of them had the same judgment this was adopted as the final evaluation.

LCI index	Grade 0	Grade 1	Grade 2	Grade 3
Redness (R)	 No redness	 Redness with visible vessels	 Redness without visible vessels	
Area of inflammation (A)	 Up to 25% of screen	 Up to 50% of screen	 Up to 75% of screen	 Over grade 2
Lymphoid follicular (L)	 No lymphoid follicular	 Slightly visible lymphoid follicles	 Clearly visible lymphoid follicles	 Lymphatic follicles with angiogenesis

► **Fig. 1** Definition and representative images of each component of the LCI index. The LCI index consist of three components: LCI index-R (Redness), LCI index-A (Area of inflammation), and LCI index L (Lymphoid follicular). LCI index-R was classified into Grade 0 to 2 according to the degree of redness with/without visible vessels. LCI index-A was classified into Grade 0 to 4 according to the extent of redness on the screen. LCI index-L was categorized into Grade 0 to 3 according to the visibility of lymphoid follicles. LCI; linked color imaging.

## Histopathological evaluation

Biopsy specimens were obtained from areas with inflammation and lymphoid follicles observed by LCI. Biopsy of areas with inflammation was performed at the sites at which the endoscopist judged that the inflammation was most severe and mild. One or more samples were collected from each site. When inflammation was not endoscopically observed, a biopsy of the normal mucosa was performed. The histopathological findings were evaluated by Geboes histopathological score (GHS) [26, 27]. Histological healing was defined as GHS < 2B.1 (neutrophil infiltration in < 5% of crypts, no crypt destruction, and no erosions, ulcerations, or granulation tissue) with reference to definition of histologic improvement in the phase 3 clinical trial of ustekinumab for moderate to severe UC [28].

Blinded histopathological evaluations were performed two central expert pathologists, and the final results were decided through a discussion and consensus by the two pathologists.

## Ethics statement

This study was conducted in accordance with the guidelines of the Declaration of Helsinki and with the approval of each institution's ethics committee (as core facilities, Kyorin University School of Medicine, approval number 707). All patients provided written informed consent.

## Statistical analysis

The data for LCI index, MES, and GHS were used for the analyses in the present study. The proportion and score of each component of the LCI index were compared between MES 0 vs. 1 and GHS < 2B.1 vs. ≥ 2B.1 using Fisher's exact test and Mann-Whitney U test, respectively. We set the threshold of the LCI index as the 75th percentile, and evaluated the sensitivity, specificity, positive predictive value, and negative predictive value according to histological healing. The concordance rate of the pathologist's judgment was evaluated using the Cohen's  $\kappa$  coefficient [29].  $\kappa$ -values were classified as follows: < 0, poor agreement; 0–0.2, slight agreement; 0.2–0.4, fair agreement; 0.4–0.6, moderate agreement; 0.6–0.8, substantial agreement; and 0.8–1.0 almost perfect agreement.

Statistical analysis was performed using SPSS software, version 25 (IBM Corp., Armonk, New York, United States) and R version 4.0.3 (The R Foundation for Statistical Computing, Vienna, Austria).  $P < 0.05$  was considered statistically significant.

## Results

### Patient characteristics

We enrolled 98 UC patients with clinical remission and performed colonoscopies. Four patients with MES ≥ 2 and one pa-

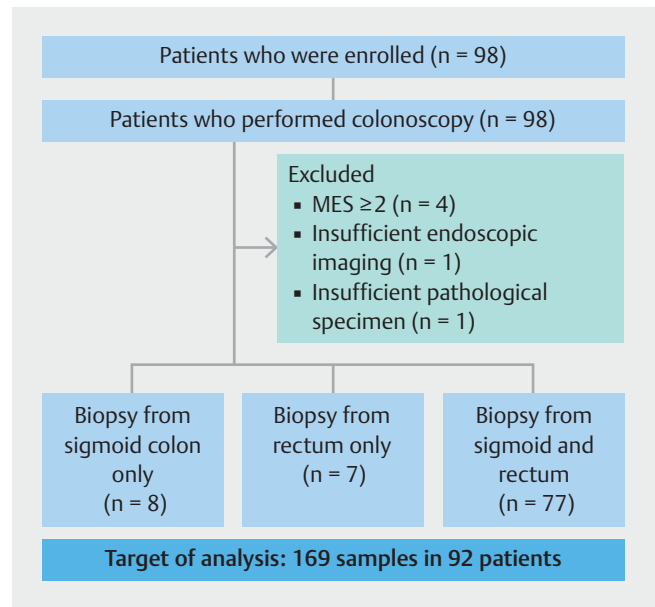
tient with insufficient endoscopic images were excluded. In addition, one patient was excluded because of insufficient mucosal biopsy sample (► Fig. 2). The clinical characteristics of 92 patients are shown in ► Table 1. The most common extent of colitis was pancolitis (60 patients, 65.2%). As concomitant medications, 5-aminosalicylic acid, azathioprine, prednisolone, anti-tumor necrosis factor- $\alpha$  treatment, and tacrolimus were used in 80 (86.9%), 23 (25.0%), 1 (1.1%), 10 (10.9%), and two patients (2.2%), respectively.

### Proportion of MES and LCI index

In 92 patients, the endoscopic findings of 85 samples of sigmoid colon and 84 samples of rectum were evaluated (► Table 2). Among the 169 samples, MES was confirmed and finalized as MES 0 for 117 of 169 cases (69.2%) and MES 1 for 52 of 169 cases (30.8%). In LCI index, the proportion of cases in which the diagnosis of three central endoscopic judgment committee members was consistent in two or more members were 164 of 169 cases (97.0%) in LCI-index R, 154 of 169 cases (91.1%) in LCI-index A, and 151 of 169 cases (89.3%) in LCI-index L. In LCI index-R, there were 22 of 169 cases (12.4%) of Grade 0, 117 of 169 cases (69.8%) of Grade 1, and 30 of 169 cases (17.8%) of Grade 2. In LCI index-A, there were 113 of 169 cases (66.9%) of Grade 0, 34 of 169 cases (20.2%) of Grade 1, 17 of 169 cases (10.0%) of Grade 2, and five of 169 cases (2.9%) of Grade 3. In LCI index-L, there were 124 of 169 cases (73.8%) of Grade 0, 27 of 169 cases (16.0%) of Grade 1, 14 of 169 cases (8.4%) of Grade 2, and four of 169 cases (2.4%) of Grade 3.

### Proportion of each LCI index component in patients with MES 0 and 1

The proportion of each LCI index in MES 0 and 1 is shown in ► Fig. 3. Regarding LCI index-R in MES 0, there were 20 of 117 cases (17.1%) of Grade 0, 92 of 117 cases (78.6%) of Grade 1, and five of 117 cases (4.3%) of Grade 2. For MES 1, there were one of 52 cases (1.9%) of Grade 0, 26 of 52 cases (50.0%) of Grade 1, and 25 of 52 cases (48.0%) of Grade 2. The proportion of LCI index-R (0 of 1 of 2) was associated with MES (0 of 1) ( $P < 0.0001$ ). Regarding LCI index-A in MES 0, there were 98 of 117 cases (83.8%) of Grade 0, 13 of 117 cases (11.1%) of Grade 1, 4 of 117 cases (3.4%) of Grade 2, and two of 117 cases (1.7%) of Grade 3. In MES 1, there were 15 of 52 cases (28.8%) of Grade 0, 21 of 52 cases (40.4%) of Grade 1, 13 of 52 cases (25.0%) of Grade 2, and three of 52 cases (5.8%) of Grade 3. The proportion of LCI index-A (0 of 1 of 2 of 3) was associated with MES (0 of 1) ( $P < 0.0001$ ). Regarding LCI index-L in MES 0, there were 92 of 117 cases (78.6%) of Grade 0, 16 of 117 cases (13.7%) of Grade 1, five of 117 cases (4.3%) of Grade 2, and four of 117 cases (3.4%) of Grade 3. In MES 1, there were 32 of 52 cases (61.5%) of Grade 0, 11 of 52 cases (21.2%) of Grade 1, and nine of 52 cases (17.3%) of Grade 2. The proportion of LCI index-L (0 of 1 of 2 of 3) was associated with MES (0 of 1) ( $P = 0.009$ ).



► Fig. 2 Flow chart of this study. Of the enrolled 98 patients with UC, 169 samples in 92 patients were analyzed in this study.

► Table 1 Patient characteristics at baseline (n = 92).

Characteristics	Total (n = 92)
Median age, y (IQR)	46 (36–60)
Male sex, n (%)	48 (53.3)
Median body mass index, kg/m <sup>2</sup> (IQR)	20.5 (17.8–21.9)
Median disease duration, y (IQR)	8.0 (4.3–13.0)
Extent of colitis, n (%)	
Pancolitis	60 (65.2)
Left-sided colitis	29 (31.5)
Proctitis	3 (3.3)
Concomitant drug, n (%)	
5-aminosalicylic acid	80 (86.9)
Azathioprine	23 (25.0)
Prednisolone	1 (1.1)
TNF inhibitors	10 (10.9)
Oral tacrolimus	2 (2.2)
Total Mayo score, mean $\pm$ SD	0.76 $\pm$ 0.82
Median C-reactive protein level, mg/dL (IQR)	0.04 (0.02–0.10)
Median albumin, g/dL (IQR)	4.3 (4.2–4.5)
Median hemoglobin, g/dL (IQR)	14.0 (13.1–15.1)

IQR, interquartile range; SD, standard deviation; TNF, tumor necrosis factor.

► **Table 2** Proportion of MES and LCI index.

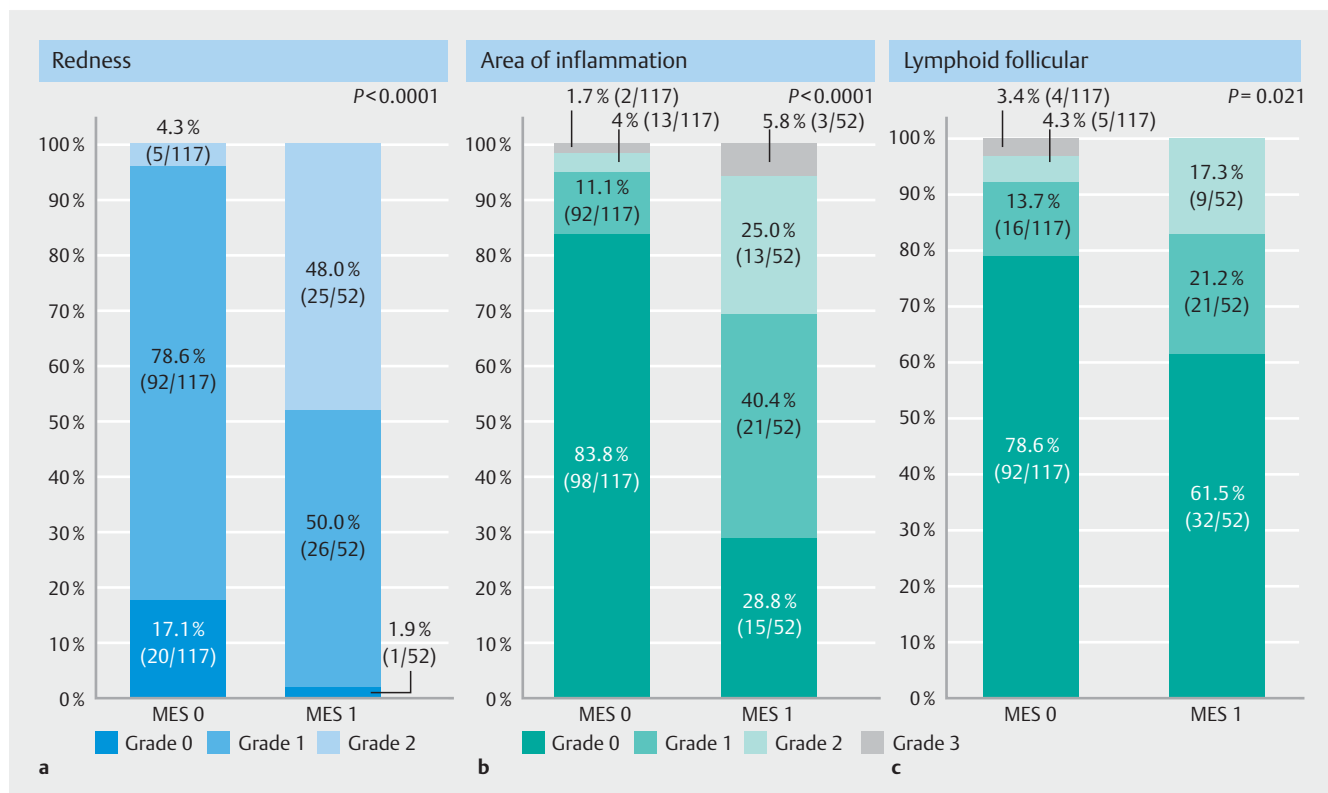
Endoscopic findings	Total (n = 169)
MES (0/1)	117/52
LCI Index	
Redness (0/1/2)	22/117/30
Area of inflammation (0/1/2/3)	113/34/17/5
Lymphoid follicular (0/1/2/3)	124/27/14/4

LCI, linked color imaging; MES, Mayo endoscopic subscore; WLI, white light imaging.

### Proportion of each LCI index in patients with and without histological healing

Regarding the diagnoses made by the two pathologists, the concordance rate using the  $\kappa$ -score is shown in ► **Table 3**. "Chronic inflammatory infiltrate," "crypt destruction," and "crypt destruction" had a moderate agreement, and "structural changes," "eosinophils in lamina propria," "neutrophils in lamina propria," and "neutrophils in epithelium" had a stationary agreement. The overall histological healing rate was 84.0% (142 of 169). The proportions of each LCI index in histological

healing and non-healing are shown in ► **Fig. 4**. Regarding the LCI index-R in histological healing, there were 21 of 142 cases (14.8%) of Grade 0, 101 of 142 cases (71.1%) of Grade 1, and 20 of 142 cases (14.1%) of Grade 2. In histological non-healing, there were one of 27 (3.7%) of Grade 0, 16 of 27 cases (59.3%) of Grade 1, and 10 of 27 cases (37.0%) of Grade 2. The proportion of LCI index-R (0 of 1 of 2) was associated with histological healing or non-healing ( $P=0.013$ ). Regarding LCI index-A in histological healing, there were 103 of 142 cases (72.5%) of Grade 0, 27 of 142 cases (19.0%) of Grade 1, nine of 142 cases (6.3%) of Grade 2, and three of 142 cases (2.1%) of Grade 3. In histological non-healing, there were 11 of 27 cases (40.7%) of Grade 0, seven of 27 cases (25.9%) of Grade 1, eight of 27 cases (29.6%) of Grade 2, and one of 27 cases (3.7%) of Grade 3. The proportion of LCI index-A (0 of 1 of 2 of 3) was associated with histological healing or non-healing ( $P=0.0014$ ). Regarding LCI index-L in histological healing, there were 106 of 142 cases (74.6%) of Grade 0, 23 of 142 cases (16.2%) of Grade 1, 11 of 142 cases (7.7%) of Grade 2, and two of 142 cases (1.4%) of Grade 3. In histological non-healing, there were 18 of 27 cases (66.7%) of Grade 0, four of 27 cases (14.8%) of Grade 1, four of 27 cases (14.8%) of Grade 2, and one of 27 cases (3.7%) of Grade 3. The proportion of LCI index-L (0 of 1 of 2 of 3) was not associated with histological healing or non-healing ( $P=0.382$ ).



► **Fig. 3** Proportion of each LCI index in MES 0 and 1. **a** Proportion of LCI index-R. The proportion of LCI index-R (0/1/2) was associated with MES (0/1) ( $P < 0.0001$ ). **b** Proportion of LCI index-A. The proportion of LCI index-A (0/1/2/3) was associated with MES (0/1) ( $P < 0.0001$ ). **c** Proportion of LCI index-L. The proportion of LCI index-L (0/1/2/3) was associated with MES (0/1) ( $P = 0.009$ ). The proportion of each component of the LCI index and MES was compared using Fisher's exact test. LCI, Linked color imaging; MES, Mayo endoscopic subscore.



► **Table 3** Concordance rate of pathological judgment using  $\kappa$  score.

Geboes histopathological score	$\kappa$ score
Structural changes	0.702 (0.650–0.754)
Chronic inflammatory infiltrate	0.453 (0.395–0.511)
Eosinophils in lamina propria	0.670 (0.616–0.724)
Neutrophils in lamina propria	0.784 (0.719–0.849)
Neutrophils in epithelium	0.729 (0.651–0.807)
Crypt destruction	0.491 (0.275–0.707)
Erosion/ulceration	0.551 (0.431–0.671)

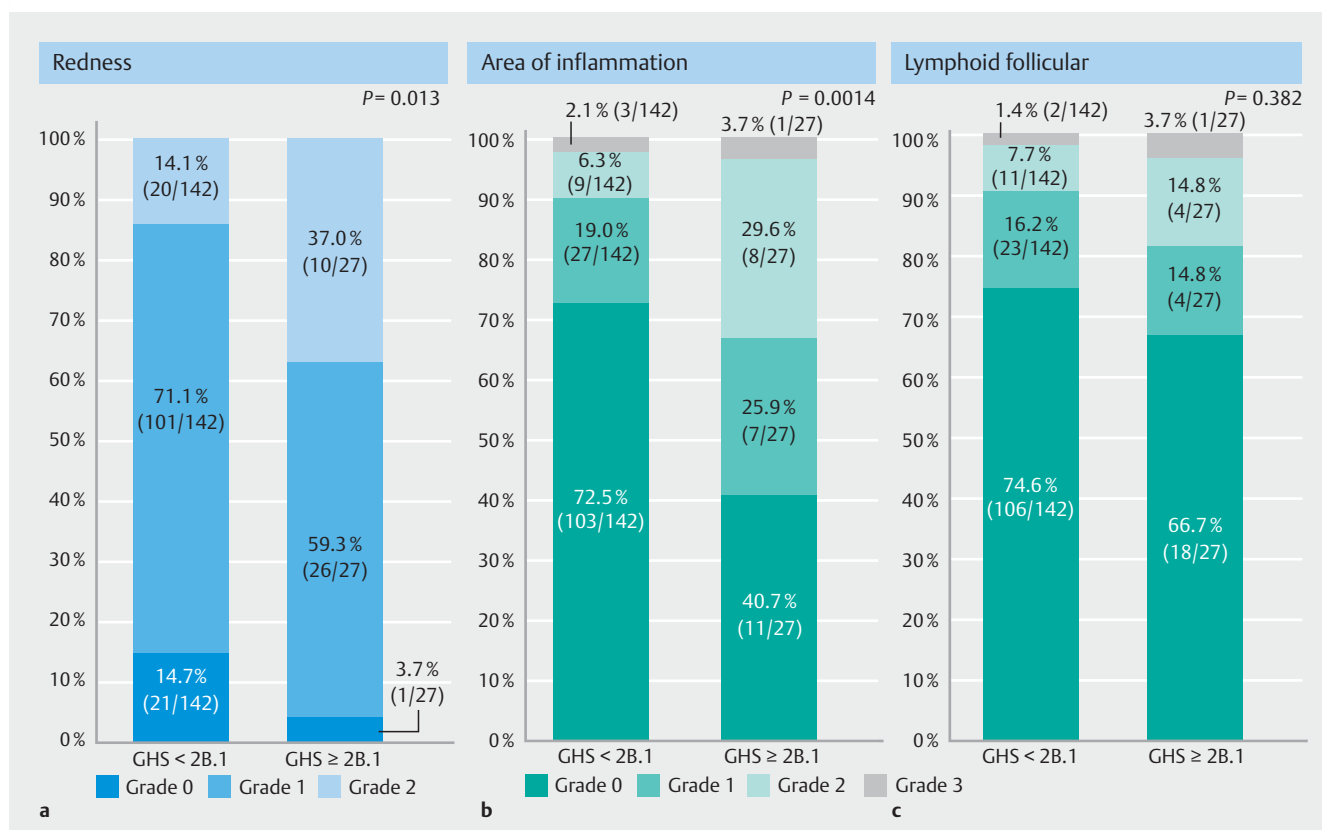
Next, we performed an additional analysis to examine if there was a difference in each component of the LCI index between the subjects with and without histological healing (► **Table 4**). LCI index-R ( $P=0.0036$ ) and A ( $P=0.0004$ ) were significantly lower in the subjects with histological healing compared with those without histological healing. No significant difference in LCI index-L score was found between the subjects with or without histological healing ( $P=0.322$ ).

## Relationship between LCI index and histological healing in patients with endoscopic remission

In LCI index-R and A, which had significant differences compared with histological healing, we aimed to set a threshold of these components considering their convenience in daily practice. Because the 75th percentile of LCI index-R score in the subjects with histological healing was Grade 1, we set the threshold of LCI index-R to predict histological healing at Grade 1. Grade  $\leq 1$  vs. 2 of LCI index-R was significantly associated with histological healing vs. non-healing ( $P=0.007$ ). The 75th percentile of LCI index-A score in the subjects with histological healing was also Grade 1. Grade  $\leq 1$  vs.  $\geq 2$  of LCI index-A was significantly associated with histological healing vs. non-healing ( $P=0.001$ ) (► **Table 5**).

## Discussion

Previously, Uchiyama et al. reported that MES subdivision was obtained from redness evaluated by LCI. They demonstrated that mucosal redness without visible vessels was diagnosed in 4.6% and 34.6% of patients with MES 0 and MES1, respectively [19]. In our study, LCI index-R Grade 2, representing redness without visible vessels, was observed in 4.3% and 48.0% of pa-



► **Fig. 4** Proportion of each LCI index in histological healing/non-healing. **a** Proportion of LCI index-R. The proportion of LCI index-R (0/1/2) was associated with histological healing/non-healing ( $P=0.013$ ). **b** Proportion of LCI index-A. The proportion of LCI index-A (0/1/2/3) was associated with histological healing/non-healing ( $P=0.0014$ ). **c** Proportion of LCI index-L. The proportion of LCI index-L (0/1/2/3) was not associated with histological healing/non-healing ( $P=0.382$ ). The proportion of each component of the LCI index was compared using Fisher's exact test. Histological healing was defined as  $GHS < 2B.1$ . GHS, Geboes histopathological score; LCI, linked color imaging.

► **Table 4** Relationship between each LCI index and histological healing (GHS < 2B.1).

LCI index	Histological healing		P value <sup>1</sup>
	(+)	(-)	
Redness (0/1/2)	21/101/20	1/16/10	0.003
Area of inflammation (0/1/2/3)	103/27/9/3	11/7/8/1	0.0004
Lymphoid follicular (0/1/2/3)	106/23/11/2	18/4/4/1	0.322

GHS, Geboes histological score; LCI, linked color imaging.

<sup>1</sup> Mann-Whitney U test.► **Table 5** Diagnostic capability of LCI index for histological healing (GHS < 2B.1).

LCI index	Histological healing		Sensitivity	Specificity	PPV	NPV	P value
	(+)	(-)					
Redness							
Grade ≤ 1 <sup>1</sup>	122	17	0.859	0.370	0.877	0.333	0.007
Grade 2	20	10					
Area of inflammation							
Grade ≤ 1 <sup>2</sup>	129	18	0.908	0.333	0.878	0.409	0.001
Grade ≥ 2	13	9					

LCI, linked color imaging; NPV, negative predictive value; PPV, positive predictive value.

<sup>1</sup> The 75th percentile of LCI index-R score in the subjects with histological healing.<sup>2</sup> The 75th percentile of LCI index-A score in the subjects with histological healing.

tients with MES 0 and MES1, respectively, consistent with the previous report by Uchiyama et al. LCI index may be able to subdivide MES 0 and 1, defined as endoscopic remission in WLI.

In the present study, LCI index-A was significantly correlated with histological healing in patients with UC in clinical remission. This finding provides the insight that LCI index-A – an index evaluating the area of inflammation from the viewpoint of redness as well as decreased visibility of vessels – could be a novel marker in endoscopic monitoring for UC.

The weakness of the previous endoscopic score is that it is evaluated by point (strongest point of inflammation). However, in clinical practice, inflammation has a certain regionality. We believe that the advantage of this study is that it incorporates regionality (LCI-index A) into the endoscopic score and emphasizes redness by LCI (LCI-index R). In colonoscopy with LCI, the boundary of areas with redness and loss of vascular pattern is easily determined. It is an advantage of LCI.

Histological healing is generally considered to be in a higher hierarchy than endoscopic remission [14]. Various studies showed that histologically active inflammation can exist even in mucosa with endoscopic remission [30]. However, there is insufficient evidence that histological healing is a superior predictor to endoscopic remission in predicting a preferable long-term prognosis. Furthermore, attention should be paid to the cutoff value defined for histological healing. In a Phase 3 clinical trial of ustekinumab for moderate to severe UC, the proportion of patients who achieved histologic improvement (defined as

neutrophil infiltration in < 5% of crypts, no crypt destruction, and no erosions, ulcerations, or granulation tissue) was numerically greater than that of patients who achieved endoscopic improvements [28]. Thus, the hierarchy between endoscopic and histological findings may change depending on the cutoff value for histological healing.

Histological findings are limited as a point evaluation, while endoscopic findings can be an area evaluation. However, for UC characterized by continuous lesions, no endoscopic scoring system is currently available that considers areas of inflammation. Yoon et al. reported that UC patients who achieved MES 0 had a lower risk of relapse within 12 months than who achieved MES 1. Furthermore, they reported that patients who achieved MES 0 with histological healing had a lower risk of relapse [31]. However, these were analyses in MES that did not include evaluation of area. Although the long-term prognosis was not evaluated in our study, the LCI index, which includes the evaluation of area, may be involved in predicting relapse. In addition, in LCI index, lymphoid follicles were included in an evaluation item as LCI index-L. In this study, the relationship between LCI index and histological healing was evaluated for each index, and only LCI index-L was not associated with histological healing. In UC, lymphoid follicles may precede or accompany typical mucosal lesions, and these are considered to be an early lesion in UC [32]. In our study, all patients had a certain disease duration, and lymphoid follicles observed were unlikely to be early lesions in UC. Lymphoid follicles have not been analyzed by conven-

tional endoscopic observation with WLI. Although LCI index-L was not correlated with histopathological findings, there is still a possibility that lymphoid follicles may affect the subsequent clinical course.

In addition, in our study, we evaluated only the association between each LCI index and histological healing, not the total score. The reason for this is that it was difficult to compare the importance of each index and grade. It also included that only the LCI index L was not associated with histologic cure. Adding the LCI index-L to the total score is considered difficult.

Our study had several limitations. First, there might be a selection bias because the subjects were selected by the attending physicians. Second, inflammation was evaluated only in the sigmoid colon and the rectum, and not in the entire colon. Although this study included many patients with total colitis, all patients in clinical remission were selected; thus, the evaluation was limited to the sigmoid colon. Third, because the target patients were limited to  $MES \leq 1$ , much of the actual biopsy tissue showed mild inflammation in GHS. This might affect LCI-index evaluation, especially specificity. However, we believe that there is no point in assessing histopathological inflammatory activity by biopsy for assessment of disease activity, which is invasive, in cases with  $MES \geq 2$  with apparent endoscopic inflammation. Of course, a biopsy is necessary for evaluation such as infection or cancer. Finally, this study examined the correlation between LCI findings and histopathology, and a further prospective analysis is needed to determine if LCI index can predict long-term prognosis in UC patients with clinical remission.

## Conclusions

We developed an LCI index that is useful for predicting histological healing in UC patients with clinical remission and  $MES \leq 1$ . Additional studies are required to investigate the usefulness of the LCI index in predicting long-term prognosis.

## Acknowledgments

The authors thank H. Nikki March, PhD, from Edanz (<https://jp.edanz.com>) for editing a draft of this manuscript.

## Competing interests

Dr. Hirai has received research grants from Eli Lilly, AbbVie, EA Pharma, JIMRO, Ayumi, Kissei, Mochida, Eisai, and Asahi Kasei Medical, consulting fees from Kissei, and speaker's fees from AbbVie, EA Pharma, Janssen, Mochida, Mitsubishi Tanabe, and Takeda. Dr. Uchiyama has received grant support from AbbVie GK and lecture fees from Mitsubishi Tanabe Pharma Corporation. Dr. has received collaborative research funds from Fujifilm Medical Co., Ltd. and lecture fees from Mochida Pharma. Co. Ltd. and Janssen Pharmaceutical K.K. Dr. Naito received scholarship funds from Taiyo Kagaku Co., Ltd. and from EA Pharma. Co. Ltd., a collaboration research fund from Taiyo Kagaku Co., Ltd., and lecture fees from Mylan EPD Co., Takeda Pharma. Co. Ltd., Mochida Pharma. Co. Ltd., EA Pharma. Co. Ltd., Otsuka Pharma. Co. Ltd., and Miyarisan Pharma. Co. Ltd. Dr. Matsuura has received research grants from AbbVie GK, Mitsubishi Tanabe Pharma Corporation, EA Pharma Co., Ltd., Kyorin Pharmaceutical Co., Ltd., Mochida Pharmaceutical Co., Ltd., Janssen Pharmaceutical K.K., Nippon Kaya-

ku Co., Ltd., and Kissei Pharmaceutical Co., Ltd., and commercial research funding from AbbVie GK, Mitsubishi Tanabe Pharma Corporation, EA Pharma Co., Ltd., Mochida Pharmaceutical Co., Ltd., Nippon Kayaku Co., Ltd., and JIMRO Co. Dr. Miyoshi has received lecture fees from AbbVie GK, Miyarisan Pharma. Co. Ltd., Takeda Pharmaceutical Co. Ltd., and Janssen Pharmaceutical K.K. Dr. Watanabe has received grant support from Helmsley Charitable Trust, EA Pharma Co., Ltd., Takeda Pharmaceutical Co., Ltd., EP CRSU Co., Ltd., AbbVie Japan Co., Ltd., Mitsubishi Tanabe Pharma Corporation, JIMRO Co., Ltd., Nippon Kayaku Co., Ltd., and Mochida Pharmaceutical Co., Ltd.; and consulting and lecture fees from EA Pharma Co., Ltd., AbbVie Japan Co., Ltd., Takeda Pharmaceutical Co., Ltd., Janssen Pharmaceutical K.K., Pfizer Japan Inc., Kissei Pharmaceutical Co., Ltd., GlaxoSmithKline K.K., Mitsubishi Tanabe Pharma Corporation, JIMRO Co., Ltd., Mochida Pharmaceutical Co., Ltd., Zeria Pharmaceutical Co., Ltd., Nippon Kayaku Co., Ltd., Kissei Pharmaceutical Co., Ltd., Sandoz Pharma K.K., and Olympus Corporation. Dr. Esaki has performed joint research with Alfresa Pharma Co., Ltd., received grant support from Mitsubishi Tanabe Pharma Corporation, EA Pharma Co., Ltd., AbbVie GK, JIMRO Co., Ltd., Kyorin Pharmaceutical Co., Ltd., Nippon Kayaku Co., Ltd., Takeda Pharmaceutical Co., Ltd., Pfizer Inc., Fujifilm Co., Ltd., and Mochida Pharmaceutical Co., Ltd., and received consulting and lecture fees from Mitsubishi Tanabe Pharma Corporation, AbbVie GK, EA Pharma Co., Ltd., Pfizer Inc., Kyorin Pharmaceutical Co. Ltd., JIMRO Co., Janssen Pharmaceutical K.K., Mochida Pharmaceutical Co., Ltd., Takeda Pharmaceutical Co., Ltd., Nippon Kayaku Co., Ltd., Fujifilm Co., Ltd., and Covidien Japan. Inc. Dr. Naganuma has received research grants from EA Pharma Co., Ltd. and Mochida Pharmaceutical Co., Ltd. and lecture fees from Takeda Pharmaceutical Co., Ltd., Mitsubishi Tanabe Pharmaceutical Co., Ltd., and Pfizer Co. Dr. has performed joint research with Alfresa Pharma Co., Ltd. and EA Pharma Co., Ltd., received grant support from Mitsubishi Tanabe Pharma Corporation, EA Pharma Co., Ltd., AbbVie GK, JIMRO Co., Ltd., Zeria Pharmaceutical Co., Ltd., Daiichi-Sankyo, Kyorin Pharmaceutical Co., Ltd., Nippon Kayaku Co., Ltd., Takeda Pharmaceutical Co., Ltd., Pfizer Inc., and Mochida Pharmaceutical Co., Ltd., and received consulting and lecture fees from Mitsubishi Tanabe Pharma Corporation, AbbVie GK, Celgene K.K., EA Pharma Co., Ltd., Kyorin Pharmaceutical Co. Ltd., JIMRO Co., Janssen Pharmaceutical K.K., Mochida Pharmaceutical Co., Ltd., Takeda Pharmaceutical Co., Ltd., and Pfizer Inc.

## Clinical trial

UMIN Japan (<http://www.umin.ac.jp/english/>)

UMIN000030412

**TRIAL REGISTRATION:** Prospective, Multi-Center Study  
UMIN000030412 at UMIN Japan

## References

- [1] Danese S, Fiocchi C. Ulcerative colitis. *N Engl J Med* 2011; 365: 1713–1725
- [2] Ungaro R, Mehandru S, Allen PB et al. Ulcerative colitis. *Lancet* 2017; 389: 1756–1770
- [3] Dulai PS, Jairath V. How do we treat inflammatory bowel diseases to aim for endoscopic remission? *Clin Gastroenterol Hepatol* 2020; 18: 1300–1308
- [4] Annese V, Daperno M, Rutter MD et al. European evidence based consensus for endoscopy in inflammatory bowel disease. *J Crohns Colitis* 2013; 7: 982–1018
- [5] Baars JE, Nuij VJ, Oldenburg B et al. Majority of patients with inflammatory bowel disease in clinical remission have mucosal inflammation. *Inflamm Bowel Dis* 2012; 18: 1634–1640



- [6] Rosenberg L, Lawlor GO, Zenlea T et al. Predictors of endoscopic inflammation in patients with ulcerative colitis in clinical remission. *Inflamm Bowel Dis* 2013; 19: 779–784
- [7] Colombel JF, Rutgeerts P, Reinisch W et al. Early mucosal healing with infliximab is associated with improved long-term clinical outcomes in ulcerative colitis. *Gastroenterology* 2011; 141: 1194–1201
- [8] Meucci G, Fasoli R, Saibeni S et al. Prognostic significance of endoscopic remission in patients with active ulcerative colitis treated with oral and topical mesalazine: a prospective, multicenter study. *Inflamm Bowel Dis* 2012; 18: 1006–1010
- [9] Frosliè KF, Jahnsen J, Moum BA et al. Mucosal healing in inflammatory bowel disease: results from a Norwegian population-based cohort. *Gastroenterology* 2007; 133: 412–422
- [10] Dulai PS, Levesque BG, Feagan BG et al. Assessment of mucosal healing in inflammatory bowel disease: review. *Gastrointest Endosc* 2015; 82: 246–255
- [11] Lemmens B, Arijis I, Van Assche G et al. Correlation between the endoscopic and histologic score in assessing the activity of ulcerative colitis. *Inflamm Bowel Dis* 2013; 19: 1194–1201
- [12] Zenlea T, Yee EU, Rosenberg L et al. Histology grade is independently associated with relapse risk in patients with ulcerative colitis in clinical remission: a prospective study. *Am J Gastroenterol* 2016; 111: 685–690
- [13] Rosenberg L, Nanda KS, Zenlea T et al. Histologic markers of inflammation in patients with ulcerative colitis in clinical remission. *Clin Gastroenterol Hepatol* 2013; 11: 991–996
- [14] Korelitz BI, Sultan K, Kothari M et al. Histological healing favors lower risk of colon carcinoma in extensive ulcerative colitis. *World J Gastroenterol* 2014; 20: 4980–4986
- [15] Bitton A, Peppercorn MA, Antonioli DA et al. Clinical, biological, and histologic parameters as predictors of relapse in ulcerative colitis. *Gastroenterology* 2001; 120: 13–20
- [16] Ozaki R, Kobayashi T, Okabayashi S et al. Histological risk factors to predict clinical relapse in ulcerative colitis with endoscopically normal mucosa. *J Crohns Colitis* 2018; 12: 1288–1294
- [17] Turner D, Ricciuto A, Lewis A et al. STRIDE-II: An update on the Selecting Therapeutic Targets in Inflammatory Bowel Disease (STRIDE) initiative of the International Organization for the Study of IBD (IOIBD): Determining therapeutic goals for treat-to-target strategies in IBD. *Gastroenterology* 2021; 160: 1570–1583
- [18] Fukuda H, Miura Y, Hayashi Y et al. Linked color imaging technology facilitates early detection of flat gastric cancers. *Clin J Gastroenterol* 2015; 8: 385–389
- [19] Uchiyama K, Takagi T, Kashiwagi S et al. Assessment of endoscopic mucosal healing of ulcerative colitis using linked colour imaging, a novel endoscopic enhancement system. *J Crohns Colitis* 2017; 11: 963–969
- [20] Takagi T, Uchiyama K, Kajiwara-Kubota M et al. The efficacy of linked color imaging for the endoscopic diagnosis of mucosal healing in quiescent ulcerative colitis. *J Gastroenterol Hepatol* 2021; 36: 2448–2454
- [21] Nakase H, Uchino M, Shinzaki S et al. Evidence-based clinical practice guidelines for inflammatory bowel disease 2020. *J Gastroenterol* 2021; 56: 489–526
- [22] Rutgeerts P, Sandborn WJ, Feagan BG et al. Infliximab for induction and maintenance therapy for ulcerative colitis. *N Engl J Med* 2005; 353: 2462–2476
- [23] Lewis JD, Chuai S, Nessel L et al. Use of the noninvasive components of the Mayo score to assess clinical response in ulcerative colitis. *Inflamm Bowel Dis* 2008; 14: 1660–1666
- [24] Nakarai A, Kato J, Hiraoka S et al. Prognosis of ulcerative colitis differs between patients with complete and partial mucosal healing, which can be predicted from the platelet count. *World J Gastroenterol* 2014; 20: 18367–18374
- [25] Rutgeerts P, Sandborn WJ, Feagan BG et al. Infliximab for induction and maintenance therapy for ulcerative colitis. *N Engl J Med* 2005; 353: 2462–2476
- [26] Jauregui-Amezaga A, Geerits A, Das Y et al. A simplified Geboes Score for ulcerative colitis. *J Crohns Colitis* 2017; 11: 305–313
- [27] Mosli MH, Feagan BG, Zou G et al. Development and validation of a histological index for UC. *Gut* 2017; 66: 50–58
- [28] Sands BE, Sandborn WJ, Panaccione R et al. Ustekinumab as induction and maintenance therapy for ulcerative colitis. *N Engl J Med* 2019; 381: 1201–1214
- [29] Cohen J. A coefficient of agreement for nominal scales. *Educ Psychol Measurement* 1960; 20: 37–46
- [30] Bryant RV, Winer S, Travis SPL et al. Systematic review: Histological remission in inflammatory bowel disease. Is 'complete' remission the new treatment paradigm? An IOIBD initiative *J Crohns Colitis* 2014; 8: 1582–1597
- [31] Yoon H, Jangi S, Dulai PS et al. Incremental benefit of achieving endoscopic and histologic remission in patients with ulcerative colitis: a systematic review and meta-analysis. *Gastroenterology* 2020; 159: 1262–1275
- [32] Hayashi R, Ueno Y, Tanaka S et al. Rectal lymphoid follicle aphthous lesions frequently progress to ulcerative colitis with proximal extension. *Intern Med* 2019; 58: 625–631