

## Suspected macular light damage caused by excessive use of smartphone

Xu-Dong Huang, Xiang Gao, Lei Gao, Gang Ma, Jie Zhang

Weifang Eye Hospital, Qingdao University, Weifang, Shandong 261000, China.

*To the Editor:* Smartphones have also changed the exposure of human eyes to light. As all the spectral peaks for smartphones are very similar to short-wavelength blue visible light,<sup>[1]</sup> it is not surprising that eye damage with smartphones has raised public concerns. In this article, we describe one patient with suspected macular light damage caused by the excessive use of a smartphone.

A 29-year-old male barber visited Weifang Eye Hospital on September 4, 2018 because of worsening blurred binocular vision for 3 days, claiming that he was unable to work properly. He had no other eye discomfort, and his best corrected visual acuity was 20/50 OU. Slit lamp biomicroscopy revealed a normal anterior and posterior segment with no alteration of the foveal reflex. There were no cells in the vitreous. Fluorescein angiography, indocyanine green angiography, and fundus autofluorescence were unremarkable. Multifocal electroretinogram, visual evoked potentials, and the 10-degree central visual field were normal. Moreover, capillary network of macular appeared unremarkable with optical coherence tomography angiography. Only high-definition optical coherence tomography (OCT) revealed foveolar disturbance, which resembled some cases of traditional photic retinopathy [Figure 1A, B].

On the basis of preliminary exclusion of common macular lesions, and in view of the difficulty in diagnosis, we decided to start with a history survey. The patient was found to have no history of any systemic illness, abuse of tobacco and liquor or systemic or ocular medication, nor did he have history of any eye disease in the family. Further history survey elicited no experience of sun gazing or electrowelding. However, detailed history taking revealed that he had been addicted to using smartphone for 3 years. Apart from normal daytime use, he was accustomed to spending 6 to 8 hours every night on his phone, especially viewing screen in bed with lights turned off during the night, without enabling “Night Shift” with protection mode even in the dark.

The patient was advised to limit his time focusing on the phone except for normal social intercourse and stop viewing

his phone in the dark, turn on “Night Shift” with protection mode and go to sleep before 10:30 PM. Following our advice strictly, he showed improvement of his eyesight after about 2 weeks. In the follow-up visits of 3 months, his best corrected visual acuity improved to 20/25 OU. The OCT findings were similar but subtler and less uneven [Figure 1C, D]. Six months after his first visit, the OCT scan showed that the sub-foveal outer layer of the macula in both eyes almost returned to normal [Figure 1E, F]. There were no abnormalities in other aspects of ocular examinations [Supplementary Figures 1–10, <http://links.lww.com/CM9/A73>].

Damage to the retina caused by light, especially blue light is a well-established phenomenon either in the laboratory or in real life.<sup>[1-7]</sup> It is widely believed that compared with natural exposures with the reasonably foreseeable exposure to optical radiation from mobile phones, the actual spectrally weighted irradiance is lower than the natural exposures.<sup>[3]</sup> Despite the fact that International Commission on Non-ionizing Radiation Protection Guide has successfully dispelled the concerns, the spectral peaks for smartphones are very similar to short-wavelength blue visible light.<sup>[1]</sup> Most reviews have deemed the risk to be low, but there is no knowledge of when or if a damage threshold is reached. On the contrary, nowadays there are millions of users depending more and more on the mobile phone. People today might spend more time viewing the phone than seeing the natural light; moreover, reading on the phone pulls people’s eyes very close to the phone screen.

With few such case reports of light-induced retinopathy due to smartphones addiction issued in the world, the diagnosis we gave to the patient was cautious and well-thought-out. After the exclusion of known macular diseases and a total 6 months of follow-up, we believe our preliminary diagnosis was reasonable. Firstly, we excluded all known macular diseases in the process of our 6-month follow-up visits. Secondly, rigorous detailed history taking and the 6-month follow-up visits revealed his addiction to his smartphone in the last 3 years. Finally,

### Access this article online

Quick Response Code:



Website:  
[www.cmj.org](http://www.cmj.org)

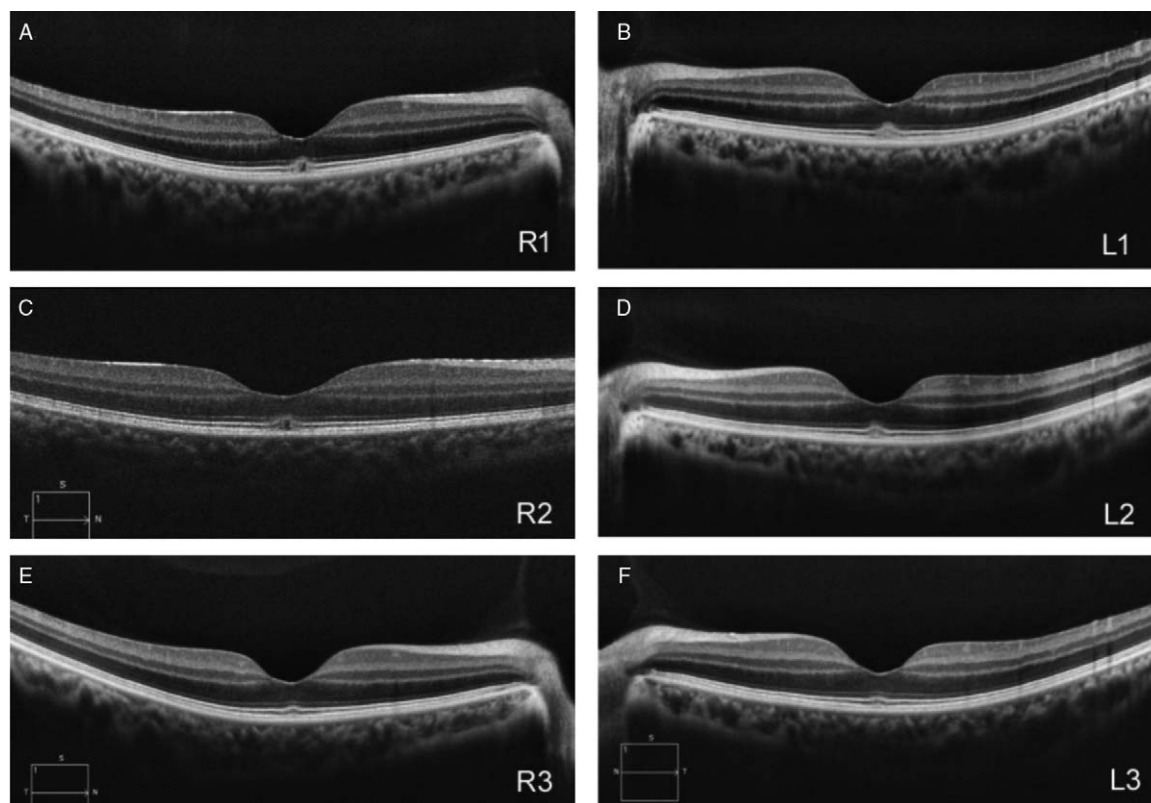
DOI:  
10.1097/CM9.0000000000000379

**Correspondence to:** Prof. Lei Gao, Weifang Eye Hospital, Qingdao University, Weifang, Shandong 261000, China  
E-Mail: [gl6365@163.com](mailto:gl6365@163.com)

Copyright © 2019 The Chinese Medical Association, produced by Wolters Kluwer, Inc. under the CC-BY-NC-ND license. This is an open access article distributed under the terms of the Creative Commons Attribution-Non Commercial-No Derivatives License 4.0 (CCBY-NC-ND), where it is permissible to download and share the work provided it is properly cited. The work cannot be changed in any way or used commercially without permission from the journal.

Chinese Medical Journal 2019;132(16)

Received: 21-05-2019 Edited by: Yuan-Yuan Ji



**Figure 1:** High-definition OCT of right (R) and left (L) eye at different stage. (A, B) R1, L1: OCT images at initial presentation display a mild irregularity and hyper-reflective area at the level of the outer segment through macular fovea for both eyes. A blurring of EZ and IZ lines in a protuberance above the sub-foveolar RPE was noted and a small low reflection cyst was formed in the right eye. The retinal inner layer and RPE/Bruch complex profile seems normal. (C, D) R2, L2: OCT images at 3-month follow-up. The corresponding OCT images still show a slight alteration in the out segment, but more subtle and less uneven after 3-month follow-up. (E, F) R3, L3: OCT images at 6-month follow-up showed that the sub-foveal outer layer of the macula in both eyes almost returned to normal. OCT: Optical coherence tomography; RPE: Retinal pigment epithelium; EZ: Ellipsoid zone; IZ: Interdigitation zone.

binocular lesion occurs simultaneously in the fovea maculae, which is in line with people's viewing habits. The outer segment changes found by OCT coincide with the pathologic changes of chronic light injury.<sup>[4]</sup> More importantly, after a 6-month behavioral intervention, the visual acuity was significantly improved to normal and confirmed with revised OCT images.

To the best of our knowledge, this is a rare case of light-induced retinopathy due to smartphones addiction in the real world. Literature retrieval related to smartphones affecting human visual acuity is currently limited to transient smartphone "blindness."<sup>[5]</sup> Apart from causing confusion in diagnosis, it might not lead to people's concern. If the symptoms of our case are proved to be related to recurrent, prolonged exposures to smartphone screen, it will surely have a profound impact on both the manufacturers and the consumers, especially when we are one step into the era of virtual reality.

#### Declaration of patient consent

Written consent was obtained from the patient for publication of this case report and any accompanying images.

#### Conflicts of interest

None.

#### References

- Clark AJ, Yang P, Khaderi KR, Moshfeghi AA. Ocular tolerance of contemporary electronic display devices. *Ophthalmic Surg Lasers Imaging Retina* 2018;49:346–354. doi: 10.3928/23258160-20180501-08.
- Lin CH, Wu MR, Li CH, Cheng HW, Huang SH, Tsai CH, *et al.* Editor's highlight: Periodic exposure to smartphone-mimic low-luminance blue light induces retina damage through Bcl-2/BAX-dependent apoptosis. *Toxicol Sci* 2017;157:196–210. doi: 10.1093/toxsci/kfx030.
- O'Hagan JB, Khazova M, Price LL. Low-energy light bulbs, computers, tablets and the blue light hazard. *Eye (Lond)* 2016;30:230–233. doi: 10.1038/eye.2015.261.
- Shukla D. Optical coherence tomography and autofluorescence findings in chronic phototoxic maculopathy secondary to snow-reflected solar radiation. *Indian J Ophthalmol* 2015;63:455–457. doi: 10.4103/0301-4738.159889.
- Alim-Marvasti A, Bi W, Mahroo OA, Barbur JL, Plant GT. Transient smartphone "blindness." *N Engl J Med* 2016;374:2502–2504. doi: 10.1056/NEJMc1514294.
- Polosa A, Bessaklia H, Lachapelle P. Light-induced retinopathy: young age protects more than ocular pigmentation. *Curr Eye Res* 2017;42:924–935. doi: 10.1080/02713683.2016.1255336.
- Begaj T, Schaal S. Sunlight and ultraviolet radiation-pertinent retinal implications and current management. *Surv Ophthalmol* 2018;63:174–192. doi: 10.1016/j.survophthal.2017.09.002.

**How to cite this article:** Huang XD, Gao X, Gao L, Ma G, Zhang J. Suspected macular light damage caused by excessive use of smartphone. *Chin Med J* 2019;132:2013–2014. doi: 10.1097/CM9.0000000000000379