

Case Report

Open Access

Unusual metastasis of papillary thyroid carcinoma to larynx and hypopharynx a case report

Bipin T Varghese*¹, Anitha Mathews³, Manoj Pandey¹ and VM Pradeep²

Address: ¹Department of Surgical Oncology, Regional Cancer Centre, Trivandrum, India, ²Department of Nuclear Medicine, Regional Cancer Centre, Trivandrum, India and ³Department of Pathology, Regional Cancer Centre, Trivandrum, India

Email: Bipin T Varghese* - bipin@rcctvm.org; Anitha Mathews - cytology@rcctvm.org; Manoj Pandey - manojpandey@rcctvm.org; VM Pradeep - surgicaloncology@rcctvm.org

* Corresponding author

Published: 22 June 2003

Received: 09 April 2003

World Journal of Surgical Oncology 2003, 1:7

Accepted: 22 June 2003

This article is available from: <http://www.wjso.com/content/1/1/7>

© 2003 Varghese et al; licensee BioMed Central Ltd. This is an Open Access article: verbatim copying and redistribution of this article are permitted in all media for any purpose, provided this notice is preserved along with the article's original URL.

Abstract

Background: Although direct infiltration of papillary carcinoma of thyroid to larynx, trachea and esophagus is well recognized, lymphatic and vascular metastases to larynx and hypopharynx have rarely been reported.

Case report: A case of loco-regionally advanced papillary carcinoma of thyroid metastasizing to the hypopharynx and aryepiglottic fold is presented

Conclusions: Papillary thyroid carcinoma (PCT) is known for their indolent nature and erratic behavior. PCT commonly spreads through lymphatics and vascular spread is rare. However, when occurs it is usually to bone, brain, lungs and soft tissue. Therapeutic decisions in advanced thyroid malignancies are usually difficult especially when there is extra-nodal spread of the tumor. A judicious combination of surgical clearance combined with radioablation is the key to the management of such tumors

Introduction

Primary mode of spread in papillary carcinoma thyroid (PCT) is lymphatic [1]. Blood borne metastasis to distant sites is rare. Known sites of distant spread in PCT are bone, lung, skin and brain while involvement of recurrent laryngeal nerve, larynx, pharynx, trachea and esophagus occurs due to direct infiltration [2]. Distant metastases to kidney [3], cerebellum [4], skin [5] and esophagus [6] have also been reported.

Although there are several reports of synchronous association between squamous cell carcinoma of the upper aero digestive tract and lymph node metastasis from occult

PCT [7,8], extra nodal metastasis to the larynx and hypopharynx is not reported. We believe this to be the first report of extra nodal metastasis of papillary carcinoma thyroid to larynx and hypopharynx.

Case Report

A 41-year-old man underwent exploration of the neck for fine needle aspiration cytology (FNAC) proven papillary carcinoma thyroid. The attempt at thyroidectomy failed due to extensive extra thyroidal infiltration of the tumor and the patient was referred to cancer centre.

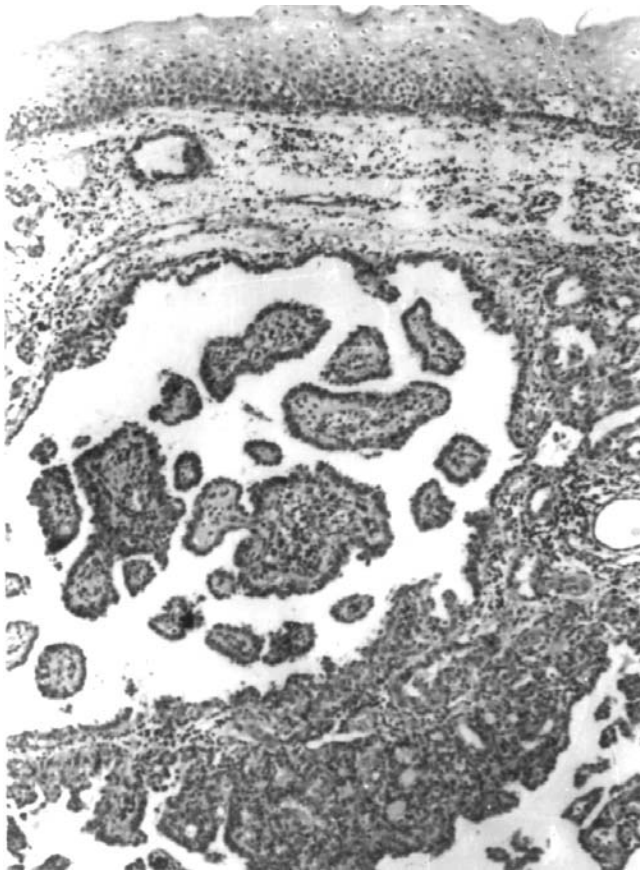


Figure 1
Biopsy from the right aryepiglottic fold showing intact squamous epithelium with underlying papillary carcinoma with papillary and follicular patterns. (H&E \times 250)

On examination horizontal scar of Kocher's incision was present in front of the neck and fullness was seen over the thyroid bed. Due to postoperative edema, the thyroid could not be assessed.

Bilateral neck nodes were present in levels II, III and IV. Indirect Laryngoscopy (IDL) revealed, mobile vocal cords and multiple mucosal nodules on the posterior pharyngeal wall and the right aryepiglottic fold. The trachea and esophagus were free of disease. A flexible endoscopy of the upper-aero digestive tract confirmed the findings of indirect laryngoscopy and punch biopsies were taken from posterior pharyngeal wall and aryepiglottic fold lesions. Histopathological examination of the biopsy specimen revealed tissue lined by stratified squamous epithelium with metastatic papillary carcinoma in the sub epithelial region (Figure 1). A detailed metastatic workup was carried out which did not reveal metastatic disease elsewhere.

A revision (completion) thyroidectomy and bilateral modified neck dissection, with adjuvant postoperative radioablation of the extra nodal metastasis was planned. Peroperatively he was found to have an 8 \times 6 cm firm to hard multinodular lesion in the right lobe and a similar 4 \times 3 cm sized lesion in the left lobe of thyroid gland. Multiple lymph nodes were encountered on the right side from level II to V, largest measuring 3 cm. About 4 cm segment of right internal jugular vein was absent. On the left side too, nodes were present from level II to V, with the largest measuring 3 cm. In view of the extensive local regional nodal disease and the high risk of injury to both the recurrent laryngeal nerves an option of laryngopharyngectomy with permanent tracheostomy was given but patient did not consent for it, hence, a debulking surgery including excision of the entire right lobe and the isthmus along with right radical neck dissection, left functional neck dissection and central compartment clearance, was carried out. The right recurrent laryngeal nerve (RLN) could not be identified separately during the procedure.

The histopathology of the resected specimen showed papillary carcinoma thyroid (Figure 2) extending to the medial margin of excision. All the lymph nodes in the neck dissection specimen showed metastatic papillary carcinoma. Postoperative scintigraphy carried out after 4 weeks with 100 mc of I^{131} administered orally showed 37% neck uptake after 24 hours with a nearly intact left lobe.

In view of the gross residual disease and sub epithelial deposition of the tumor in the posterior pharyngeal wall and right aryepiglottic fold it was decided to subject the patient for postoperative external radiotherapy (RT). The patient however, did not report for any further treatment.

Discussion

Papillary thyroid carcinoma is known for their indolent nature and erratic behavior. Histologically, tall cell [1] and diffuse sclerosis [9] variants of PCT carries a bad prognosis. Other bad prognostic indicators are extra capsular invasion / extra nodal spread, anaplasia of the tumor, age of the patient (>45 yrs) and presence of distant metastasis [1,2]. A direct association between presence of extranodal spread and occurrence of distant metastasis has also been reported [10].

PCT commonly spreads through lymphatics and vascular spread is rare. However, when occurs it is usually to bone, brain, lungs and soft tissue. Involvement of other structures in neck like larynx, trachea and esophagus is mainly due to direct infiltration of tumor into these structures.

Unlike the cases of direct laryngeal invasion [2] by the tumor that presents with symptoms of stridor/dysphagia

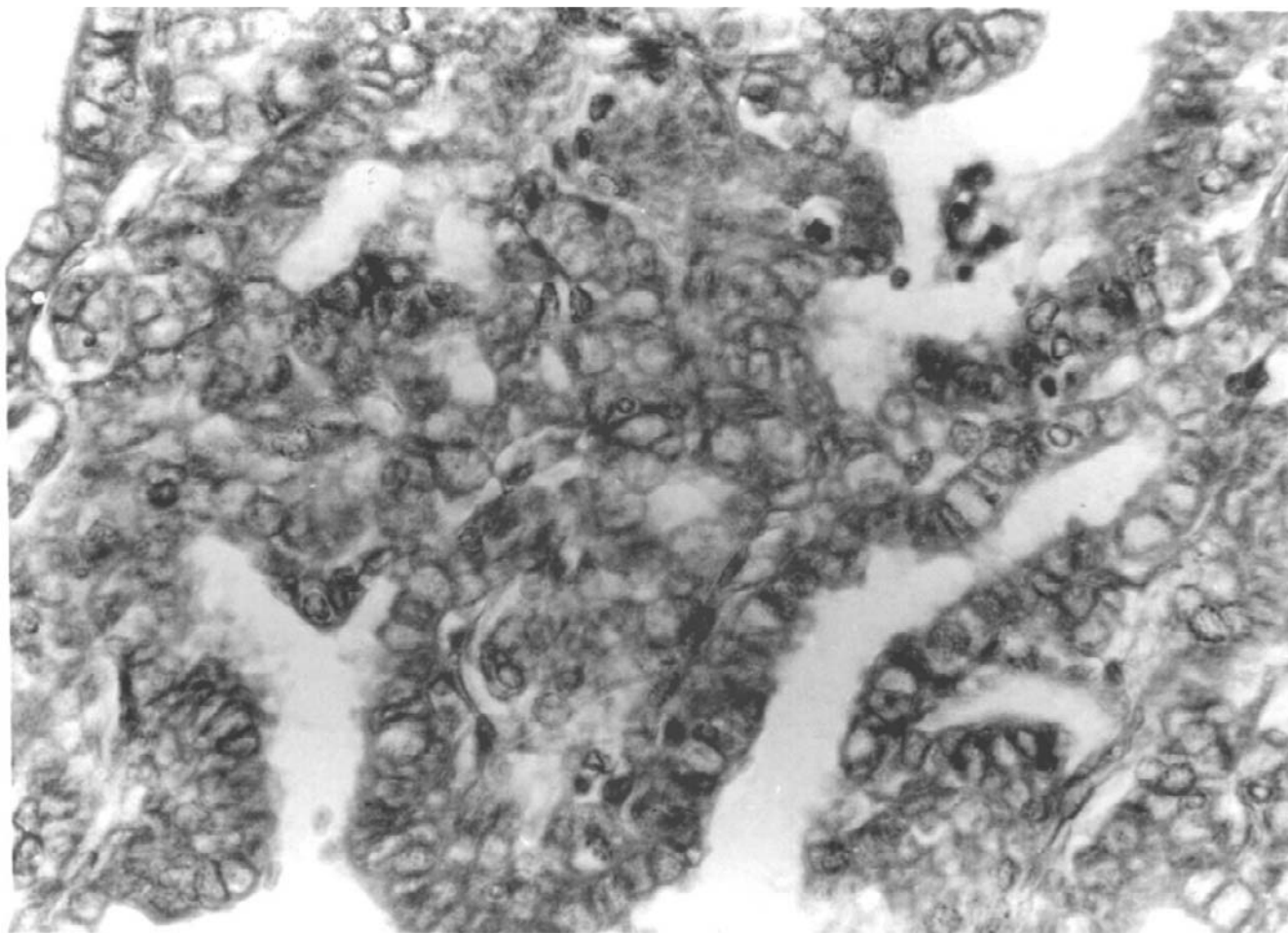


Figure 2
Primary thyroid carcinoma showing papillary and follicular pattern (H & E \times 400)

or hoarseness, the present case did not have any symptom and on routine indirect laryngoscopic examination was found to have discrete laryngeal and hypopharyngeal nodules covered with normal squamous epithelium, which were not in continuity with the thyroid tumor. Direct laryngoscopic findings and its subsequent operative and histological confirmation prompt us to reason that these discrete nodules would have been a consequence of either a retrograde lymphatic [11] or vascular spread. Retrograde or aberrant lymphatic spread to retropharyngeal nodes or the pharynx per se is very unlikely because of the absence of lymphoid component in the laryngeal and pharyngeal specimen and in parapharyngeal or retropharyngeal spaces, however a retrograde subepithelial spread to larynx and hypopharynx can not be ruled out. Absence of central compartment and retropharyngeal lymphadenopathy and predominant nodal spread to lateral compartment (level II, III, IV) is also an

argument against this. A computerized tomogram (CT) or magnetic resonance image (MRI) would have helped in differentiating the direct invasion or metastasis. However due to financial constraints it was not carried out in the present patient. Radioiodine scan is not of help in such situations as in presence of thyroid tissue, majority of the metastasis do not take up radioiodine.

Advanced thyroid malignancies generally presents difficult therapeutic decisions especially when there is extra nodal and extra capsular spread of the tumor. A judicious combination of surgical clearance combined with radio ablation is the key to the management of such tumors [12]. However, when gross residual thyroid tissue is left behind a post operative external beam RT is preferable to radioablation because of the need for a high dose of radioiodine to get optimum results in a disease which is already destined to have a bad outcome [13,14].

This case is being reported for its extreme rarity and to highlight the role of combined modality approach in the management of such (extra nodal) diseases. A radical approach to the present disease would entail total thyroidectomy and partial laryngo-pharyngectomy. Pharynx would have required reconstruction with a myocutaneous flap if more than 50% of it was resected. However this is most often unacceptable to the patient because of the inherent morbidity and to the surgeon because of the alternative option of debulking surgery and adjuvant postoperative radiotherapy/radioablation [12].

References

1. Cotran RD, Kumar V, Collins T and eds: **Robbins Pathological Basis of Disease** WB Saunders Company, Philadelphia 61999:1143-1144.
2. Mcaffrey TV, Bergstrahl EJ and Hay ID: **Locally invasive papillary thyroid carcinoma** *Head Neck* 1994, **16**:165-172.
3. Graham LD and Roe SM: **Metastatic papillary thyroid carcinoma presenting as a primary renal neoplasm** *Am Surg* 1995, **61**:732-734.
4. Pacak K, Sweeney DC, Wartofsky L, Mark AS, Punja U, Azzam CJ and Burman KD: **Solitary cerebellar metastasis from papillary thyroid carcinoma: A case report** *Thyroid* 1998, **8**:327-335.
5. Lissak B, Vannetzel JM, Gallouedec N, Berrod JL and Rieu M: **Solitary skin metastasis as the presenting feature of differentiated thyroid microcarcinoma: Report of two cases** *J Endocrinol Invest* 1995, **18**:813-16.
6. Cooney BS, Levine MS and Schnall MD: **Metastatic thyroid carcinoma presenting as an expansile intraluminal esophageal mass** *Abdom Imaging* 1995, **20**:20-22.
7. Mattavelli F, Guzzo M, Di Palma S and Molinari R: **Synchronous association of carcinoma of the superior aerodigestive ways and lymph node metastasis of papillary adenocarcinoma of the thyroid: Presentation of 6 cases** *Acta Otorhinolaryngol Ital* 1991, **11**:179-184.
8. Lopez-Escamez JA, Lopez-Nevot A, Moreno-Garcia MI, Gamiz MJ and Salinero J: **Cervical metastasis of occult papillary thyroid carcinoma associated with epidermoid carcinoma of the larynx** *ORL J Otorhinolaryngol Relat Spec* 1999, **61**:224-226.
9. Mizukami Y, Nonomura A, Michigishi T, Hashimoto T, Noguchi M, Nakamura S, Matasubara F and Kurumaya H: **Diffuse sclerosing variant of papillary carcinoma of the thyroid: report of three cases** *Acta Pathol Jpn* 1990, **40**:676-682.
10. Yamashita H, Noguchi S, Murakami N, Kawamoto H and Watanabe S: **Extracapsular invasion of lymph node metastasis is an indicator of distant metastasis and poor prognosis in patients with thyroid papillary carcinoma** *Cancer* 1997, **80**:2268-2272.
11. Tobias MJ: **Anatomy of the Human Lymphatic System: A compendium translated from the original 'Anatomie des Lymphatiques de l'Homme' by H. Rouviere rearranged for the use of students and practitioners** *Ann Arbor, Edward Bros* 1938.
12. Mazzaferrri EL: **Thyroid remnant I¹³¹ ablation for papillary and follicular thyroid carcinoma** *Thyroid* 1997, **7**:265-271.
13. O'Doherty MJ, Nunan TO and Croft DN: **Radionuclide and therapy of thyroid cancer** *Nucl Med Commun* 1993, **14**:736-755.
14. Harmer CL: **Radiotherapy in the management of thyroid cancer** *Ann Acad Med Singapore* 1996, **25**:413-419.

Publish with **BioMed Central** and every scientist can read your work free of charge

"BioMed Central will be the most significant development for disseminating the results of biomedical research in our lifetime."

Sir Paul Nurse, Cancer Research UK

Your research papers will be:

- available free of charge to the entire biomedical community
- peer reviewed and published immediately upon acceptance
- cited in PubMed and archived on PubMed Central
- yours — you keep the copyright

Submit your manuscript here:
http://www.biomedcentral.com/info/publishing_adv.asp

