

## Traumatic axillary artery pseudoaneurysm treated with intravascular balloon occlusion and percutaneous thrombin injection

Maria Carratola, BS; Priti Parikh, PhD; Kathryn Tchorz, MD; and Shannon Kauffman, MD

Axillary artery pseudoaneurysms are relatively rare, with few reported cases found in the literature. Furthermore, treatment with percutaneous thrombin injection has not yet been reported. We report the case of a 59-year-old man with a large (10 cm) post-traumatic pseudoaneurysm of the left axillary artery found five weeks after a motorcycle crash. The patient sustained multiple injuries, including fractures of the left scapula and clavicle. Edema was observed at the time of diagnosis. Arteriography with successful ultrasound-guided percutaneous thrombin injection was undertaken. The patient experienced no complications after the procedure.

### Introduction

A pseudoaneurysm (PSA) is simply a contained hematoma, a collection of blood and connective tissue, outside the wall of a blood vessel and contained by the surrounding tissues. PSAs are instigated through various mechanisms. The two major etiologies are iatrogenic and traumatic. Most iatrogenic PSAs are formed in the femoral artery and are secondary to endovascular catheterization procedures. Conversely, traumatic PSAs may be found in the axillary region, or elsewhere, and are of the blunt or penetrating variety. Blunt trauma induces an organized thrombus and hematoma to slowly form over the course of a few weeks. Examples include anterior shoulder dislocation and proximal humeral fractures (1-3). There have also been reported cases of penetrating trauma, such as stab-

bing wounds, which have incited the formation of a PSA, though these are rare (4, 5).

Treatment options fall into a spectrum of invasive and noninvasive modalities. Open surgical repair is the traditional and most invasive option. Minimally invasive techniques include endovascular coil embolization, covered stent placement, and percutaneous thrombin injection. Noninvasive techniques include ultrasound-guided compression therapy and simple observation. Only small, asymptomatic PSAs are likely to undergo spontaneous thrombosis and resolution, and therefore they are the only candidates for observation (6). Minimally invasive techniques have a lower rate of complications than open surgery, with percutaneous thrombin injection success rates approaching 97% (7).

Because the femoral artery is the access site of choice for many diagnostic and therapeutic endovascular procedures, there is a larger proportion of femoral PSAs than any other location. Therefore, there has been significant investigation into the treatment of femoral PSAs with thrombin injection, all of which has shown promising results (7-9). However, less literature is available on this modality of treatment for axillary artery PSAs, and the true incidence of PSAs in this location is unknown. Upper-extremity PSAs, both iatrogenic and traumatic, have been reported to compose less than 2% of all PSAs. Additionally, those arising due to trauma are likely a very small percentage of this number (10). To our knowledge, this is the only reported

---

**Citation:** Carratola M, Parikh P, Tchorz K, Kauffman S. Traumatic axillary artery pseudoaneurysm treated with intravascular balloon occlusion and percutaneous thrombin injection. *Radiology Case Reports*. (Online) 2014;1:871.

**Copyright:** © 2013 The Authors. This is an open-access article distributed under the terms of the Creative Commons Attribution-NonCommercial-NoDerivs 2.5 License, which permits reproduction and distribution, provided the original work is properly cited. Commercial use and derivative works are not permitted.

Ms. Carratola is a student, Dr. Parikh is Assistant Professor, and Dr. Tchorz is an Associate Professor in the Department of Surgery, all at Wright State University, Dayton OH. Dr. Kauffman is in Interventional Radiology at Radiology Physicians, Inc., Dayton OH. Contact Dr. Parikh at [priti.parikh@wright.edu](mailto:priti.parikh@wright.edu).

**Competing Interests:** The authors have declared that no competing interests exist.

DOI: 10.2484/rcr.v9i1.871

# Traumatic axillary artery pseudoaneurysm: intravascular balloon occlusion & percutaneous thrombin

case of a traumatic axillary artery pseudoaneurysm treated with ultrasound-guided percutaneous thrombin injection.

## Case report 1

### History and presentation

A 59-year-old man involved in an unhelmeted motorcycle crash presented to the Emergency Department after being found minimally responsive in a ditch. An initial Glasgow Coma Scale (GCS) of 7 necessitated intubation on the scene. He was hypotensive, with a GCS of 3T on arrival at the hospital. He had multiple injuries, including a scalp laceration, subdural hematoma, and fractures of the skull, left clavicle, left scapula, left radius, left hand (fifth phalanx), and left zygomatic arch. He also had multiple rib fractures, multiple cervical spine fractures, and a dislocation of the first metacarpophalangeal joint.

He required intervention from the neurological, maxillofacial, and orthopedic surgery teams. On post-trauma day 33, CT angiography of the left upper extremity was obtained to rule out vascular injury, due to the patient's history of scapular and clavicular fractures and the presence of left shoulder and arm swelling (Figs. 1A-C). On physical exam, there was no palpable pulsatile axillary mass, radial pulses were palpable and equal bilaterally, and the patient showed no neurologic symptoms; however, he was not fully responsive due to traumatic brain injury. Imaging results showed a 10-cm PSA arising from the left axillary artery, with the majority of the lumen thrombosed. Approximately 2 cm of the lesion showed continued active contrast enhancement. The PSA demonstrated a narrow neck and appeared to be amenable to minimally invasive intervention. Left-upper-extremity angiography with possible thrombin injection, stent placement, or coil embolization was planned.

### Procedure

Access was obtained via the right common femoral artery, using a 21-gauge micropuncture needle with placement of a 5 French vascular sheath. Flush aortography demonstrated a three-vessel aortic arch without atherosclerosis and a widely patent left subclavian artery without injury. Redemonstration of the axillary artery PSA, originating from the proximal portion of the artery and projecting in a cephalad direction, was noted (Fig. 2). An angled, tapered catheter was used to cannulate the subclavian and axillary arteries, and dedicated imaging of the lesion was obtained.

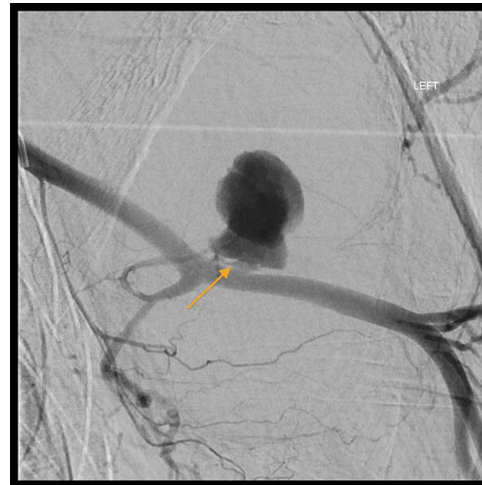

Figure 2. Digital subtraction angiography, before thrombin injection. A narrow neck (arrow) can be seen, decreasing the risk of downstream embolization.

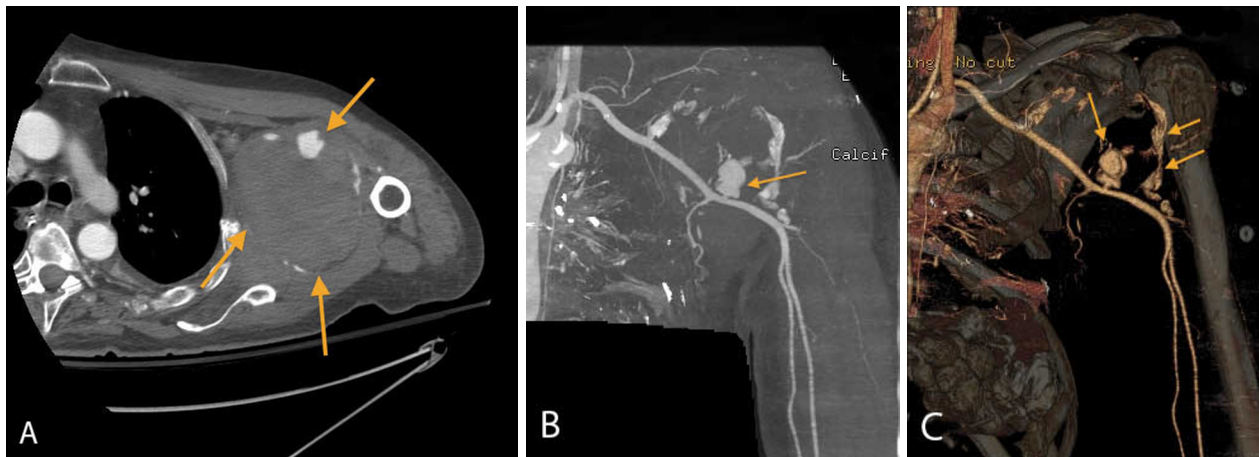


Figure 1. A. Left-upper-extremity CT-angiography with contrast, axial view. The PSA as seen on initial diagnostic imaging, demonstrating a narrow neck with approximately 10 cm total diameter. The active PSA lumen (upper arrow) can be seen as a relatively small portion of the overall hematoma formation (lower arrows). B. Left-upper-extremity CT-angiography with contrast, coronal view. Initial diagnostic imaging, showing a coronal view of the PSA lumen. C. Left-upper-extremity CT-angiography, 3D with color. This digitally recreated 3D image demonstrates the active PSA lumen (left arrow) and the distal edge of the hematoma formation, as evidenced by a small amount of contrast enhancement (right arrows).

## Traumatic axillary artery pseudoaneurysm: intravascular balloon occlusion & percutaneous thrombin

A 6-mm x 4-cm angioplasty balloon was positioned along the area of injury (Fig. 3). Using ultrasound guidance, a 21-gauge micropuncture needle was inserted percutaneously into the medial and cephalad portion of the PSA. The an-

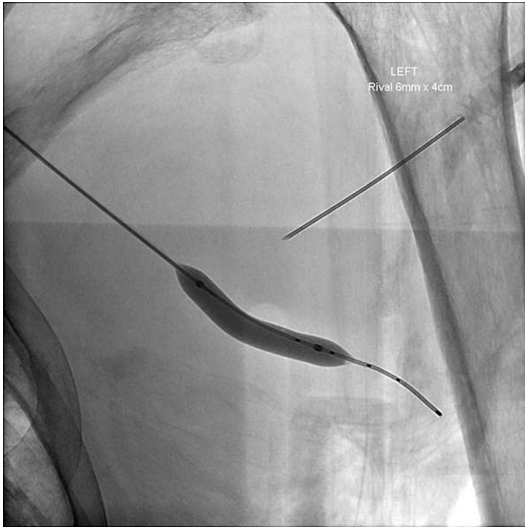

Figure 3. Axial fluoroscopy. Demonstration of balloon occlusion and percutaneous placement of the 21-gauge micropuncture needle into the medial and cephalad portion of the PSA.

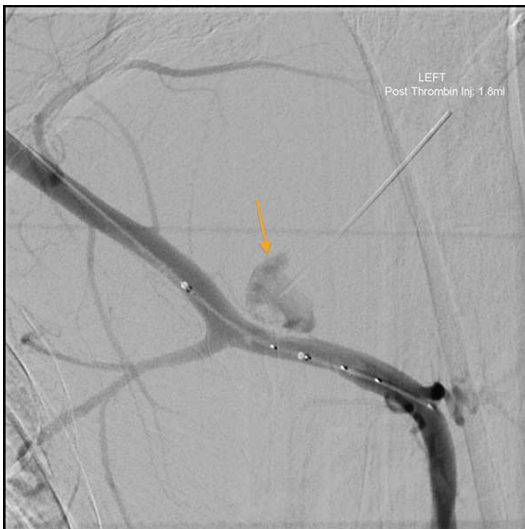

Figure 4. Digital subtraction angiography. Partially occluded PSA, as seen between cycles of thrombin injection, as evidenced by the decreasing lumen size (arrow).

gioplasty balloon was inflated, and lack of flow within the PSA was confirmed by color Doppler imaging. Reconstituted bovine thrombin (500 U/mL) was directly injected into the PSA, and the balloon was left inflated for one minute. This was repeated several times, with progressive thrombosis of the body of the PSA from distal to proximal

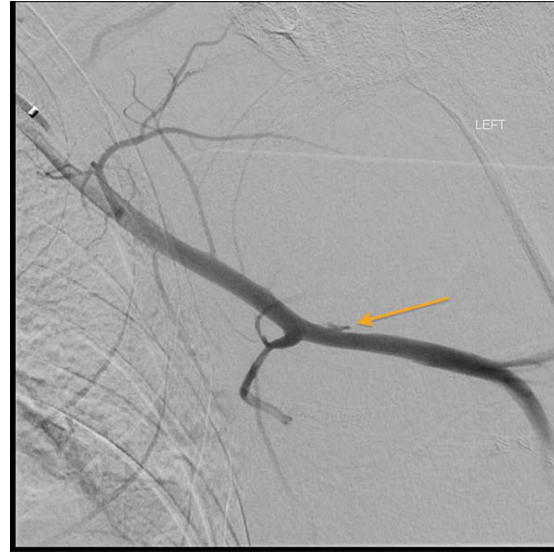

Figure 5. Digital subtraction angiography, after thrombin injection. A very small remnant of PSA appears (arrow).

(Figs. 4, 5). A total of 1.8 mL (900 U) of thrombin was used.

Distal circulation to the hand remained intact, good Doppler waveform was noted, and pulse oximetry reading remained stable. The sheath was removed and hemostasis achieved. The patient tolerated the procedure well without immediate complications.

### Postprocedure course

The patient experienced no significant complications related to the procedure in the following weeks. A followup arterial duplex ultrasound was performed on post-procedure day 1; it showed thrombosis of the aneurysm sac, with a small residual lumen measuring 1.2 x 0.8 cm.

A venous Doppler ultrasound was obtained on post-procedure day 6. Results showed a residual hematoma that was 14.4 cm x 7.9 cm. The patient continued to show good capillary refill and warm extremities, and had no impairment of muscle strength or changes in sensation.

A second arterial duplex ultrasound, performed on post-procedure day 17, showed complete resolution of the small residual PSA lumen, with an adjacent soft-tissue hematoma measuring 9.8 x 7.3 cm. The subclavian, axillary, brachial, radial, and ulnar arteries demonstrated normal flow velocities without evidence of stenosis, thrombosis, or dissection.

The patient was discharged on post-trauma day 55 (post-procedure day 21) to an extended care facility. He was instructed to maintain his left upper extremity in a nonweight-bearing sling, with close followup with his orthopedic and neurologic surgeons.

### Discussion

Pseudoaneurysms are potentially life-threatening conditions. They may begin as a silent lesion, but are certainly not guaranteed to remain so. Potential sequelae include

## Traumatic axillary artery pseudoaneurysm: intravascular balloon occlusion & percutaneous thrombin

hemorrhage, distal embolization, and ischemia (8). Depending on location, local mass effect may result in neural, vascular, or airway compression (9). In the axilla, the brachial plexus is especially susceptible to such injury. It is therefore imperative to expediently identify and treat PSAs that are at risk for such complications.

Our patient's PSA was in a unique location, making it difficult to access by more traditional methods, such as open surgery or ultrasound-guided compression therapy. In addition, surgery is more invasive and associated with higher morbidity. Compression therapy, though it has largely replaced the open surgical technique in cases where the artery is easily accessible, is still limited by patient discomfort (11). In addition, the arteries in the axillary region provide a challenge for compression due to the nearby clavicle, which may overlie the PSA neck or body (12). Therefore, our first line of treatment was a minimally invasive technique.

Among the minimally invasive options, percutaneous thrombin injection was chosen over embolization and stent placement because of the many flexion points and essential efferent vessels in the vicinity of the subclavian and axillary arteries. A highly tortuous vessel, and one with nearby arterial branches, provides a significant challenge for precise placement of both embolization coils and stent grafts (6). Complex arterial anatomy can even cause delayed complications. Lee et al have described an interesting case of stent failure due to collateral arterial supply to a PSA. In this case, after initial stent placement in the subclavian artery to exclude the PSA, a reversal of blood flow from the nearby vertebral artery fed into the lesion. In addition to continuous backflow of blood from the vertebral artery, patency was preserved by outflow from the PSA to the internal mammary artery (13).

Though this complication is unlikely, endovascular repair with a stent graft would require long-term monitoring for restenosis. While possible, coil embolization was not favored, as the patient would be left with a permanent coil mass in the axillary soft tissues. Conversely, thrombin is completely reabsorbed along with the thrombus and requires no inconvenient long-term imaging followup. However, even now, thrombin injection into axillary PSAs is not well characterized (14). The closest reported cases have been of the subclavian artery PSAs (5, 9, 15).

When considering this vascular area, care should be taken to avoid distal embolization and arterial thrombosis (16). Wide-necked PSAs are especially worrisome for embolization, and they may benefit from a combination of reparative techniques. To our knowledge, there is no defined threshold for the size of the neck relative to the PSA, but a "narrow" neck is favored to decrease the risk of downstream embolization. Balloon occlusion of the PSA neck during thrombin injection can help block the potential channel of distal embolization. If it is anatomically possible, ultrasound-guided compression can be used in conjunction with balloon occlusion. Endovascular remodeling is another possible treatment modality for wide-necked PSAs, whereby coil embolization is accomplished within the

PSA, while the parent vessel is protected with balloon occlusion (8). In our case, although the PSA neck was considered narrow, extra care was taken, and balloon occlusion was used to prevent complications.

It has been previously described that iatrogenic PSAs smaller than or equal to 2 cm in diameter can be observed and may not require treatment due to spontaneous thrombosis. Little is known regarding traumatic PSAs (17). Additionally, continued enlargement of our patient's PSA may have resulted in compression of the adjacent nerve and vein as well overlying skin, so definitive management was felt best for this patient.

Overall, percutaneous thrombin injection is not limited to superficial vessels and is ideal in small, tortuous arteries, especially those that are not amenable to endovascular repair. It is a promising modality for routine therapeutic resolution of axillary PSAs, and its use will continue to gain popularity in the future. This case is one such example of traumatic PSA formation in the axillary artery that was resolved by ultrasound-guided percutaneous thrombin injection.

### References

1. Stahnke M, Duddy M. Endovascular repair of a traumatic axillary pseudoaneurysm following anterior shoulder dislocation. *Cardiovascular Intervent Radiol* 2006; 29: 298-301. [[PubMed](#)]
2. Emadian S, Lee W. Axillary artery pseudoaneurysm and axillary nerve palsy: delayed sequella of anterior shoulder dislocation. *Am J Emerg Med*. 1996 Jan;14(1): 108-9. [[PubMed](#)]
3. Palcau L, Gouicem D, Dufranc J, Mackowiak E, Berger L. Delayed axillary artery pseudoaneurysm as an isolated consequence to anterior dislocation of the shoulder. *Ann Vasc Surg*. 2012 Feb;26(2):279. e9-12. [[PubMed](#)]
4. Fokou M, Evenga V, Mefire A, Guifo M, Pagbe J, Sandman W. Giant pseudoaneurysm of the left axillary artery following a stab wound. *Cardiovasc J Afr*. 2012 Oct 23;23(9):e4-6. [[PubMed](#)]
5. Mehta K, England E, Apgar J, Moulton J, Javadi A, Wissman R. Post-traumatic pseudoaneurysm of the thyrocervical trunk. *Skeletal Radiol*. 2013 Apr 16. [[PubMed](#)]
6. Saad N, Saad W, Davies M, Waldman D, Fultz P, Rubens D. Pseudoaneurysms and the role of minimally invasive techniques in their management. *Radiographics*. 2005;25 [Suppl 1]:S173-89. [[PubMed](#)]
7. Shah K, Halaharvi D, Franz R, Jenkins J. Treatment of iatrogenic pseudoaneurysms using ultrasound-guided thrombin injection over a 5-year period. *Int J Angiol*. 2011;20(4):235-42. [[PubMed](#)]
8. Keeling A, McGrath F, Lee M. Interventional radiology in the diagnosis, management, and follow-up of pseudoaneurysms. *Cardiovasc Intervent Radiol*. 2009 Jan;32(1):2-18. [[PubMed](#)]

## Traumatic axillary artery pseudoaneurysm: intravascular balloon occlusion & percutaneous thrombin

9. Jeganathan R, Harkin D, Lowry P, Lee B. Iatrogenic subclavian artery pseudoaneurysm causing airway compromise: treatment with percutaneous thrombin injection. *J Vasc Surg.* 2004 Aug;40(2):371-4. [[PubMed](#)]
10. Szendro G, Golcman L, Klimov A, Yefim C, Johnatan B, Avrahami E, Yechieli B, Yurfest S. Arterial false aneurysms and their modern management. *Isr Med Assoc J.* 2001;3:5-8.
11. Morgan R, Belli A. Current treatment methods for postcatheterization pseudoaneurysms. *J Vasc Intervent Radiol.* 2003;14(6):697-710. [[PubMed](#)]
12. McConnell P, Rehm J, Oltman D, Lynch T, Baxter B. Thrombin injection for treating a subclavian artery pseudoaneurysm. *Surg.* 2000;127(6):716-8. [[PubMed](#)]
13. Lee G, Brawley J, Hung R. Complex subclavian artery pseudoaneurysm causing failure of endovascular stent repair with salvage by percutaneous thrombin injection. *J Vasc Surg.* 2010 Oct;52(4):1058-60. [[PubMed](#)]
14. Mazzaccaro D, Malacrida G, Occhiuto M, Stegher S, Tealdi D, Nano G. Endovascular treatment of iatrogenic axillary artery pseudoaneurysm under echographic control: A case report. *Cardiothorac Surg.* 2011; 6: 78. [[PubMed](#)]
15. Kemmerer S, Piampiano P, Smith D. Treatment of subclavian artery pseudoaneurysm with use of US-guided percutaneous thrombin injection. *J Vasc Interv Radiol.* 2000 Sep;11(8):1039-42. [[PubMed](#)]
16. Holder R, Hilton D, Martin J, Harris PL, Rowlands PC, McWilliams RG. Percutaneous thrombin injection of carotid artery pseudoaneurysm. *J Endovasc Ther.* 2002;9:25-8. [[PubMed](#)]
17. Toursarkissian B, et al. Spontaneous closure of selected iatrogenic pseudoaneurysms and arteriovenous fistulae. *J Vasc Interv Radiol.* 1997 May;25(5):803-8. [[PubMed](#)]