



Review

Standards and Definitions in Neck Dissections of Differentiated Thyroid Cancer

Mehmet Uludağ,¹ Mert Tanal,¹ Adnan İşgör,^{2,3}

¹Department of General Surgery, Istanbul Sisli Hamidiye Etfal Training and Research Hospital, Health Sciences University, Istanbul, Turkey

²Department of General Surgery, Bahcesehir University Faculty of Medicine, Istanbul, Turkey

³Department of General Surgery, Sisli Memorial Hospital, Istanbul, Turkey

Abstract

Papillary and follicular thyroid carcinomas arising from the follicular epithelial cells and forming differentiated thyroid cancer (DTC) consist of >95% of thyroid cancers. Lymph node metastasis to the neck is common in DTC, especially in papillary thyroid cancer. The removal of only the metastatic lymph nodes (berry picking) does not help to achieve a potential positive contribution to the survival and recurrence of lymph node dissection in the DTC. Thus, systematic dissection of the cervical lymph nodes is needed. Today, according to the widely accepted and commonly used definitions and lymph node staging, the deep lymph nodes of the lateral side of the neck are divided into five regions. Based on the fact that some groups have biologically independent regions, Groups I, II, and V are divided into the A and B subgroups. The central region lymph nodes contain VI and VII region lymph nodes, which consist of the prelaryngeal, pretracheal, and right and left paratracheal lymph node groups.

Radical neck dissection (RND) is accepted as the standard basic procedure in defining neck dissections. In this method, in addition to all the regions of the Groups I–V lymph nodes at one side, the ipsilateral spinal accessory nerve, internal jugular vein, and sternocleidomastoid muscle are removed. Sparing of one or more of the routinely removed non-lymphatic structures in the RND is called modified RND (MRND), whereas the preservation of one or more of the routinely removed lymph node groups in the RND is termed as selective neck dissection (SND). In difference, the procedure with an addition of a lymph node and/or non-lymphatic structures to routinely removed neck structures in RND is called extended RND. Generally, involving one or more regions of SND are applied for DTC.

The removal of the paratracheal, prelaryngeal, and pretracheal lymph node groups at one side is termed as ipsilateral central dissection, whereas the removal of the bilateral paratracheal lymph node groups, in other words, the excision of four lymph node groups in the central region (Groups VI and VII), is defined as bilateral central dissection. In conclusion, bilateral central neck dissection (CND) is the SND in which the regions of VI and VII are removed.

In the DTC, CND is prophylactically and therapeutically applied, whereas lateral neck dissection is performed only therapeutically in the presence of clinical metastasis (N1b) in the lateral neck region. Debates on the extent of SNDs to be made in the central and lateral neck regions are still ongoing. Central dissection should be made at least unilaterally. In the lateral side of the neck, SNDs can be applied in different combinations in which at least one region from Groups I to V is removed. The main variables that determine the extent of SND in the central and lateral regions in DTC are the complication rates, the effect of the procedure, and its effect on prognosis and recurrence.

Keywords: Cancer; cervical; differentiated; dissection; lymphatic; thyroid.

Please cite this article as "Uludağ M, Tanal M, İşgör A. Standards and Definitions in Neck Dissections of Differentiated Thyroid Cancer. Med Bull Sisli Etfal Hosp 2018;52(3):149–163".

Address for correspondence: Mert Tanal, MD. Department of General Surgery, Bahcesehir University Faculty of Medicine, Istanbul, Turkey

Phone: +90 533 721 50 62 **E-mail:** merttanal@yahoo.com

Submitted Date: September 10, 2018 **Accepted Date:** September 11, 2018 **Available Online Date:** October 01, 2018

©Copyright 2018 by The Medical Bulletin of Sisli Etfal Hospital - Available online at www.sislietfaltip.org

This is an open access article under the CC BY-NC-ND license (<http://creativecommons.org/licenses/by-nc/4.0/>).



Though the classification of thyroid cancer, the most common endocrine malignancy, is still controversial, it is generally subgrouped into three main groups: differentiated thyroid cancer (DTC), medullary thyroid cancer, and anaplastic thyroid cancer. DTC originating from the follicular epithelial cells is divided into two distinct subgroups as well-differentiated DTC (WDTC) and poorly or non-DTC in terms of pathological evaluation, clinical course, and prognosis. The incidence of thyroid cancer, especially WDTC, has been determined to increase worldwide, especially within the last 30 years due to improvements in diagnostic and monitoring methods.^[1,2] Papillary thyroid cancer (PTC) and follicular thyroid cancer (FTC) occur in the WDTC group and consist of approximately >95% of thyroid cancers. PTC, which accounts for 80%–85% of WDTCs, has the best prognosis and often metastasizes to the neck lymph nodes, whereas lung metastasis is rare. In contrast, FTC and poorly differentiated DTC tend to metastasize through hematogenous spread, especially to the lungs and bones.^[1,2]

Microscopic lymph node metastasis can be detected in up to 80% in PTC. The role of lymph node dissection in these metastases is contentious. However, in patients with clinical lymph node metastasis, the recurrence after lymphatic dissection is thought to be associated with micrometastases.^[3]

In order to be able to make a positive contribution to the survival and recurrence of lymph node dissection in thyroid cancer, metastatic lymph node dissection (berry picking) is not sufficient only, and systematic lymphatic dissection is needed. However, there has been confusion about the determination of neck lymphatic dissection areas and the extent of dissection. In addition, the lymphatic pattern of the thyroid is an important anatomical feature that affects lymphatic metastases of thyroid cancers in the neck. Therefore, it is important to know the standardized topographic lymphatic anatomy for the neck dissections to be performed in the DTC and their nomenclature. This approach will allow surgeons interested in DTC to perform the same type of neck dissections to establish an understandable communication between surgeons, endocrinologists, and nuclear medicine specialists interested in thyroid cancer. The aim of the present study was to use a common terminology in the examination, and naming of lymphatic dissection types should be done according to the state of the neck lymphatic pattern and disease.

History

In the 19th century, surgeons acknowledged that head and neck tumors metastasize to the neck lymph nodes, but they thought that curative resection was not possible

in the presence of metastatic lymph nodes and rarely removed the enlarged lymph nodes with the primary tumor. This approach was generally ineffective and confirmed the expectation of poor prognosis in these patients.^[4]

The en bloc removal of neck lymphatics is generally defined as radical neck dissection (RND). In 1888, Jawdyski, a Polish surgeon, published details of the RND technique in a Polish medical journal.^[5] This study was not widely known globally because it was published in Polish; in 1990, Towpik, a Polish surgeon, called attention to this work.^[6] Prior to this study, there were studies reporting that RND was performed at the end of the 19th century, but the technical details of the operations were not given in these studies.^[4,6] Crile from the Cleveland Clinic described the RND they performed systematically since the year 1900 and published the first largest series in RND in 1905 and 1906.^[7,8] In this respect, Crile is referred as the grandfather of neck dissection in North America and is considered to be the descriptor of RND.^[4,9] This technique was later developed by Martin et al.^[10] in New York Memorial Hospital.

The first descriptive study of the human lymphatic system was published by Rouviere in 1932.^[11] This study led the way to the idea that topographic classification of the neck lymph nodes should be performed. In this context, the Memorial Sloan-Kettering Cancer Center has created a scheme by dividing the lateral neck lymphatic system into five groups, which are topographically separated and widely used because it is an easy-to-remember grouping system.^[12] Nowadays, grouping of the lymph node regions of the neck is based on this classification system.

Owing to the high morbidity and anatomical deformity due to RND, this technique has been modified to develop new techniques with lower morbidity that could result in equivalent oncologic outcomes. In this context, first in 1963, Suarez, an Argentinean surgeon, described modified RND (MRND) as functional neck dissection,^[13] in which satisfactory successful results could be obtained. In contrast to RND, in functional neck dissection, important anatomical structures, such as sternocleidomastoid muscle (SCM), internal jugular vein, and spinal accessory nerve, are preserved. Since his study was published in Spanish, his work was often overlooked, and this method was attributed to other researchers and studies published in English. However, the true father of MRND or functional neck dissection is Suarez.^[14] In 1969, in a 2-week course in Europe, Bocca from Italy and Gavilian from Spain learned this technique from Suarez and popularized the method by applying this method in their own centers and publishing the clinical results they obtained with different studies.^[15–18]

In 1989, Medina divided MRND into three types.^[19] In MRND

Type I, only the spinal accessory nerve is preserved; in Type II, the spinal accessory nerve and internal jugular vein are preserved; and in Type III, the internal jugular vein, spinal accessory nerve, and SCM are jointly protected. In addition, RND and MRND were divided into two subgroups (A and B) according to the removed lymph node groups. According to this, Type A includes the excision of all lymph nodes in the posterolateral neck between Group I and Group V, whereas Type B includes the excision of the lymph nodes between Group II and Group V.^[19]

Approximately 10 years after the first identification of MRND, in 1972, Lindberg defined the topographic distribution and incidence of lymphatic metastases in different system cancers according to the location of the tumor, and his data were confirmed by Shah in 1990.^[20, 21] After these studies, SNDs of the lymph node groups with the highest risk of metastases of the primary tumor have begun to be performed in head and neck cancers, and their indications have increased gradually.^[22]

Overview of Neck Lymphatic System and Neck Dissection

There are differences in the anatomical division of the neck lymphatic system and naming of these parts. As noted in the History section, the neck lymphatic system is divided into different areas by considering the anatomical structures. These are names given according to the region, compartment, level, or group, and the term of the group will be used in the present study. The neck lymphatic system is generally described into two parts: superficial and deep neck (cervical) system. In particular, the deep lymphatic system of the neck targeted by thyroid cancers is divided into three parts: anterior, lateral, and posterior. However, the nomenclature of these groups appears complex. The anterior lymphatic system corresponds to Group VI, the lateral lymphatic system to Groups II, III, and IV, the posterior lymphatic system to Group V, and the posterolateral lymphatic system sums up Groups II, III, IV, and V. In addition, the upper mediastinal lymph nodes are grouped as Group VII in some studies, and Group VI (anterior lymphatic group) and Group VII (upper mediastinal lymphatic group) were combined together as the central neck lymphatic group. On the other hand, Group IA is termed as submental, and Group IB as submandibular. Groups II, III, and IV are classified as upper, middle, and lower deep cervical or jugular chain, whereas Group IIA is termed as jugulodigastric lymph nodes. Group V is used for the term posterior triangular or posterior neck lymph nodes, whereas Group VA is called as the accessory chain, and Group VB is termed as the supraclavicular lymph nodes or transverse cervical chain.

There are also some problems in the discrimination of the

boundaries or regions of these groups that are related to the anatomical, surgical, and radiological definitions made. The boundary between Group IB and Group IIA (medial anterior border of Group II) is anatomically the posterior wing of the digastric or the stylohyoid muscle. Radiologically, the sagittal plane passing through the posterior border of the submandibular gland is used. During surgery, two different methods may be used to determine the surgical boundaries. The first method is used to reach the anteromedial aspect of the stylohyoid muscle, and the second the posterior fascia of the submandibular gland. The most commonly accepted surgical boundary is the posterior fascia of the submandibular gland. The plane passing through the carotid artery bifurcation or inferior border of the hyoid bone is used for the caudal border between Group II and Group III, whereas the notch of the cricoid cartilage, the lower border of the cricoid cartilage radiologically and anatomically, or the transverse planes passing through the junction of the upper and lower wings of the omohyoid muscle in the surgery are used for the border between Group III and Group IV. For the identification of the boundary between Group III and Group IV, three different anatomical structures are used. The first one is the medial edge of the SCM, the second is the medial edge of the common carotid artery, and the third is the sternohyoid muscle. The most appropriate boundary is the common carotid artery according to computed tomography and magnetic resonance imaging. However, when performing Group III and IV dissections during surgery, the lateral side of the sternohyoid muscle is more suitable to use as a border because some of the target lymph nodes remain more superficial of the carotid artery. Indeed, when the common carotid artery is used as a border, these lymph nodes can remain out of the surgical field of view. Fig. 1 shows the most accepted schema of the deep neck lymphatic system after these delineations.

In the present study, the terms neck lymphatic dissection, neck dissection, and neck lymph node dissection are used synonymously for the dissection of the mentioned lymphatic groups. On the other hand, it is noteworthy that as different types of neck dissections are applied, different classification systems and descriptions have been used increasingly. This increasing number of concepts can create confusion and misunderstanding, and application of a uniform single type of an operation becomes impossible. For example, as described previously, MRND is also termed as functional neck dissection, and the removal of all lymph node groups in the lateral aspect is also defined as total neck dissection.^[23]

In 1988, the American Academy of Otolaryngology-Head and Neck Surgery established a sub-study group called the Head and Neck Surgery and Oncology Committee with the

aim of developing a simple, easily remembered uniform classification system that could be used by everyone in this regard. This group published its first study in 1991.^[9] This classification system was modified twice in 2002 and 2008 by the American Head and Neck Society and the American Academy of Otolaryngology-Head and Neck Surgery by considering the recommendations of the relevant committee, in addition to the new observations on the biological function of lymph node metastasis.^[24, 25] This description and lymph node grouping have been widely accepted and currently used.^[12]

In contrast to other head and neck tumors, thyroid cancers are known to metastasize to the anterior lymphatic system, often referred to as Group VI. Therefore, in contrast to other head and neck tumors, in the lymphatic dissection made for thyroid cancers, Group VI and also Group VII lymph nodes must be removed. However, the classification of the neck lymph node is mainly grouped into six. Group VII is considered to be the continuation of Group VI, and both are called as the central region lymph nodes. In addition, this grouping system and definitions are used in the joint reports published by the American Thyroid Association (ATA) on the evaluation and treatment of thyroid carcinoma metastases.^[26, 27]

Identification of the Neck Lymph Node Groups

The boundaries of the neck lymph node groups determined after three studies performed by the American Academy of Otolaryngology-Head and Neck Surgery and the American Head and Neck Society are given in Fig. 1a and Table 1. In this context, the boundaries of Groups I–V, which have been outlined above, will not be further described, but the anatomy of the central region closely related to thyroid cancers will be examined in detail.

In the first study published in 1991, the neck lymph nodes were divided into six groups.^[9] In the schema of Memorial Sloan-Kettering Hospital and in some studies as well, it was suggested that the superior mediastinal lymph nodes should be identified as Group VII; however, in the 2002 revision, it was indicated that it would be better to call it as the superior mediastinal group instead of Group VII because this lymph group was topographically out of the neck boundaries. Moreover, the retropharyngeal, periparathyroid, postauricular, and suboccipital lymph nodes were decided to name on their own terminologies because they remained outside the boundaries of the previously identified groups.^[24] On the other hand, some of the groups, among these six groups in the neck, have been suggested to have biologically independent regions and are called subgroups belonging to that group. In this context, Groups I, II, and V are divided into the A and B subgroups.^[24]

In the third study of this study group, Group VII was discussed, and it was once again emphasized that it should be mentioned with its name because it is outside the boundaries of the neck region. However, it has also been stated in many studies that the term Group VII is still used. It has been emphasized that some of the lymph nodes in this group are the continuation of the lymph nodes of the paratracheal lymph node chain and extend up to the innominate artery. In addition, some lymph nodes are able to descend below the innominate artery down to the vicinity of the aortic arch. Thus, sternotomy needs to be performed to remove these lymph nodes. In contrast, typical upper mediastinal lymphatic dissection can be performed through the cervical approach.

Owing to this, the study group stated that if the term Group VII is to be used, it should define the paratracheal and pretracheal lymph nodes extending from the sternal notch to the point where the innominate artery crosses the trachea, in other words, to the level of the innominate artery. They also mentioned that these lymph nodes can be called as the superior mediastinal lymph nodes. This area, identified in the previous revision, has been shown as Group VII in the schema of the neck lymph nodes (Fig. 1b).^[25]

Anatomy of the Central Region

The workshop of the American Academy of Otolaryngology-Head and Neck Surgery and the American Head and Neck Society described Group VI as an anterior group, and the suprasternal notch forms its lower border (Table 1).^[24] In addition, in the revised version of the previous consensus report of the study group of the American Head and Neck Surgery, the superior mediastinal lymph nodes that can be reached through the cervical approach could be called region VII.^[25] A year later, a study group of the ATA Surgery Working Group, the American Society of Endocrine Surgery, the American Academy of Otolaryngology-Head and Neck Surgery, and the American Head and Neck Society published a consensus report on the classification and terminology of central neck dissection (CND) in thyroid cancer (Fig. 1b). This report stated that the thyroid is located at the lower level of the neck, near the thoracic inlet, and that the lymphatic drainage of the thyroid is adjacent to the superior mediastinal region that can be reached through the cervical approach.^[26] As a result, Groups VI and VII were defined as the central region, and the boundaries of the central region were determined. According to this, the hyoid bone constitutes the superior boundary of the central region, the carotid arteries delineate the lateral part, the deep layer of the deep cervical fascia (prevertebral fascia) forms the posterior aspect, and the superficial layer of the deep cervical composes its anterior aspect. The

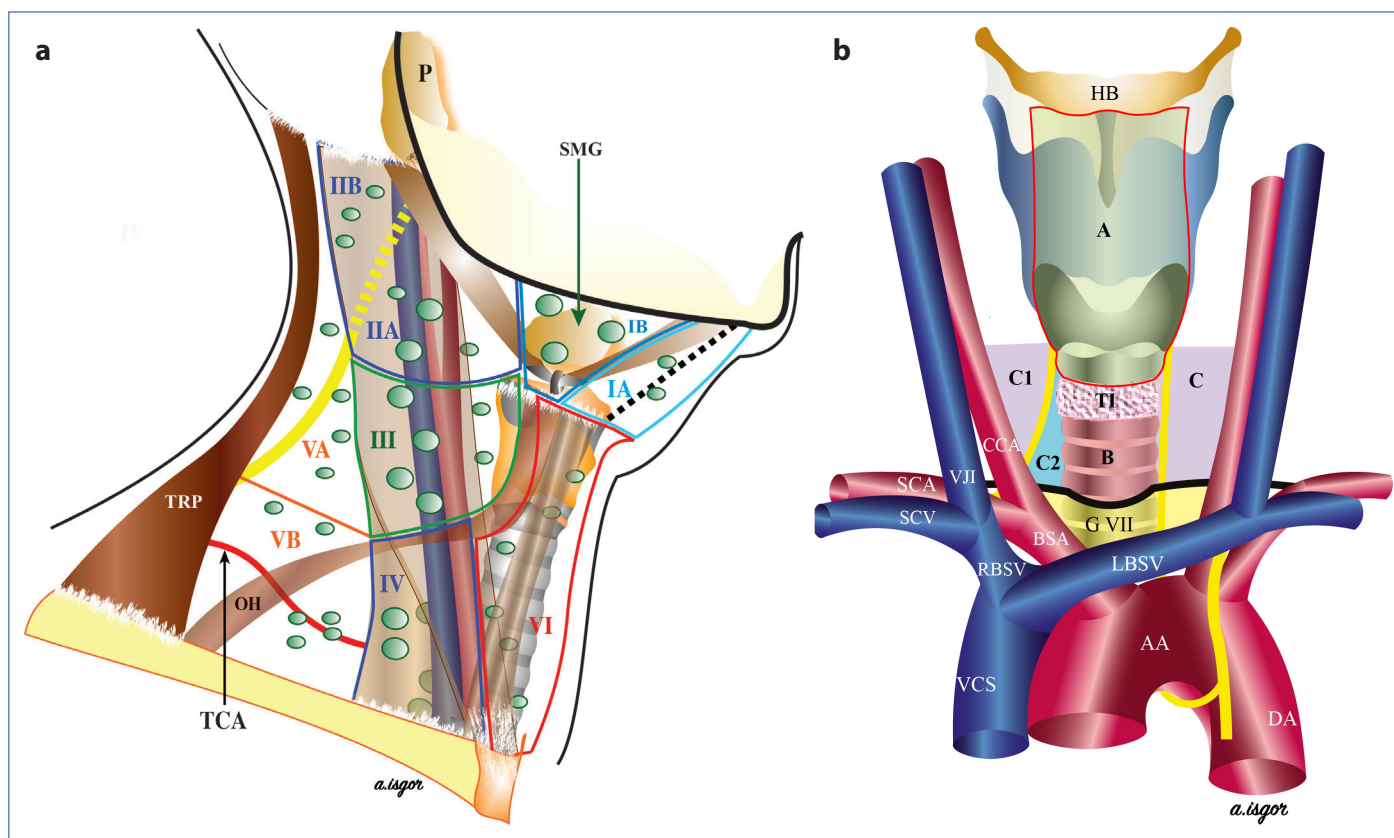


Figure 1. Distribution of the cervical lymph nodes. IA, IB, IIA, IIB, III, IV, VA, VB, and VI: lymphatic group numbers. P: parotid gland; SMG: submandibular gland; TRP: trapezius muscle; OH: omohyoid muscle; TCA: thyrocervical artery. **(a)** The schema of the central group. A: prelaryngeal group. B: pretracheal group. C: left paratracheal group. C1: right paratracheal posterolateral group. C2: right paratracheal anteromedial group. HB: hyoid bone; TI: isthmus of the thyroid; AA: arcus aorta; DA: descending aorta; BSA: brachiocephalic artery; SCA: subclavian artery; CCA: common carotid artery; VCS: vena cava superior; RBSV: right brachiocephalic vein; LBSV: left brachiocephalic vein; SCV: subclavian vein; VJI: vena jugularis interna. Group VII: seventh cervical lymphatic group. Dark black line: sternal notch. **(b)**

inferior boundaries of the central region constitute the innominate artery on the right and its symmetry on the axial plane at the left side.^[26] However, this definition of the inferior border is not clear because the innominate artery originates from the convex side of the aortic arch from a point near the left side in the anterior mid-section of the trachea. From there, it follows a slightly oblique course, crossing over the trachea to the right. At the level of the right sternoclavicular joint, 1–2 cm from the point where it crossed over the trachea, it divides into the right common carotid artery and right subclavian artery. In the consensus report, the lower border of Group VII also appears to be the point of origin of the innominate artery from the aortic arch.^[26] In the central dissection, it is not possible to descend from the neck to the convex surface of the aorta, and this area can only be reached through sternotomy. This segment of the innominate artery is also covered by the left innominate or left brachiocephalic vein. Owing to this, the lower limit is more clearly defined in the American Head and Neck Society consensus report regarding the indications and extent

of the central dissection in PTC. Accordingly, the lower border of the central region is the point where the innominate artery crosses over the trachea on the right, and the projection of this point on the axial plane is on the left side.^[28] In other words, the lower border of the central group is delineated with the medial side of the innominate artery on the right, the medial side of the left brachiocephalic vein in the middle, and the medial edge of the left carotid artery on the left.^[29] Since this inferior border can be reached through the cervical approach, it is a clearer definition for the lower border. After these discussions, it can be said that the anterior group consists of Group VI, and the central group comprises Groups VI and VII.

According to their anatomical locations, the lymph nodes of the central region divide into subgroups of the prelaryngeal (Delphian), pretracheal, and left and right paratracheal lymph nodes.^[28] Thyroid cancer often metastasizes to the lymph nodes in these four groups. The retroperitoneal and retroesophageal lymph nodes located in the posterior part are rarely involved. The majority of the central region

Table 1. The lymphatic groups of the neck and their borders

Group	Boundaries			
	Superior	Inferior	Anterior (medial)	Posterior (lateral)
Symphysis mandibula		Corpus of the hyoid bone	Anterior belly of the contralateral digastric muscle	Anterior belly of the ipsilateral digastric muscle
Lower edge of the mandibula		Posterior belly of the digastric muscle	Anterior belly of the digastric muscle	Stylohyoid muscle
Base of the skull		Horizontal plane passing below the hyoid bone	Stylohyoid muscle	Posterior border of the submandibular gland
Base of the skull		Horizontal plane passing inferior of the hyoid bone	Posterior border of the submandibular gland	The course of the spinal accessory nerve
Horizontal plane passing inferior of the hyoid bone		Horizontal plane passing inferior of the cricoid cartilage (intersection of the upper and lower bellies of the omohyoid muscle)	The course of the spinal accessory nerve	Posterior (lateral) edge of the SCM
Horizontal plane passing inferior to the cricoid cartilage (intersection of the upper and lower bellies of the omohyoid muscle)		Clavicula	Lateral edge of the sternohyoid muscle	Posterior (lateral) edge of the SCM
Intersection zone between trapezius muscle and SCM		Horizontal plane passing inferior to the cricoid cartilage	Lateral edge of the sternohyoid muscle	Posterior (lateral) edge of the SCM or sensory branches of the cervical plexus
Horizontal plane passing inferior to the cricoid cartilage		Clavicula	Posterior (lateral) edge of the SCM or sensory branches of the cervical plexus	Anterior edge of the trapezius muscle
Hyoid bone		Suprasternal notch	Posterior (lateral) edge of the SCM or sensory branches of the cervical plexus	Anterior edge of the trapezius muscle
Suprasternal notch		Intersection zone between innominate artery on the right side and trachea and its projection on the left side	Common carotid artery	Common carotid artery
			On the right side innominate artery	On the left side common carotid artery

lymph nodes are at the inferior of the larynx. Upper pole tumors may occasionally metastasize to the paralaryngopharyngeal lymph nodes coursing along the superior thyroid vessels at the deep layers of the sternohyoid and omohyoid muscles. Sometimes the mediastinal lymph nodes inferior to the innominate artery can also be involved.^[26]

Prelaryngeal lymph nodes: These lymph nodes are localized in the adipose tissue medial to the thyrohyoid muscle on both sides and bordered caudally by the upper edge of the thyroid isthmus and cranially by the hyoid bone.^[29]

Pretracheal lymph nodes: These lymph nodes are localized in the adipose tissue on the anterior aspect of the trachea between the edges of the trachea and bordered cranially by the lower edge of the isthmus and caudally by a line drawn from the intersection point between the innominate artery and the trachea.

Paratracheal lymph nodes: They are localized in the adipose tissue bordered cranially by the line passing through the lower edge of the cricoid cartilage, caudally by the line where the innominate artery crosses over the trachea on the right, the projection of this point on the axial plane on the left, laterally by the common carotid artery, and medially by the area between both edges of the trachea.^[29, 30] However, the right and left paratracheal dissection planes are also different owing to the difference in the path of the right and left recurrent laryngeal nerves (RLSs). Since the right subclavian artery and the aortic arch are at different levels, the right and left RLSs enter the paratracheal area from different angles and levels. The right RLS branches from the vagus nerve, crosses over the right subclavian artery obliquely at the anteroposterior direction, enters the paratracheal area beneath the common carotid artery from

a more anterior and lateral point relative to the left side, and progresses toward the laryngeal entrance. Owing to the oblique path of the RLS, the right paratracheal lymph nodes are localized in two different triangles formed posterolaterally and anteromedially to the nerve. Therefore, the posterolateral tissue near the RLS should be removed during right paratracheal dissection (Fig. 1b).^[28] Some of the right paratracheal lymph nodes around the inferior thyroid artery may remain behind the common carotid artery because the right common carotid artery is more ventral and medial than its left counterpart.^[26] However, it is beneficial not to enter this area in order to avoid injury to the sympathetic chain. The left RLS turns behind the aortic arch, enters into the tracheoesophageal sulcus from a more medial direction, and courses in the craniocaudal direction parallel to the groove to access into the larynx. Thus, on the left side, the paratracheal lymphatic tissue is located anterolateral to the RLS and esophagus.^[28] In this context, mobilization of RLS is not necessary when left paratracheal lymphatic dissection is performed.

Classification of Neck Dissections

Overview

The working group of the American Head and Neck Society and the American Academy of Otolaryngology-Head and Neck Surgery has identified specific rules for classifying and naming neck dissections and recommended grouping of neck dissections accordingly. In this classification, RND has been accepted as the standard basic intervention, whereas other neck dissections are adaptations of this intervention. Accordingly, neck dissections are divided into four basic groups (Table 2). Sparing one or more of the routinely removed non-lymphatic structures in the RND is

called MRND, and preservation of one or more of the routinely removed lymph node groups in the RND is termed as selective neck dissection (SND); in addition to routinely removed neck structures in RND, the removal of the lymph node group and/or non-lymphatic structures is called extended RND (ERND).^[9] In 1991, SNDs were grouped into four types: supraomohyoid, lateral, posterolateral, and anterior neck dissections. However, these special names were removed owing to subsequent neck dissections performed involving different groups.

Types of Neck Dissections

Radical Neck Dissection

In this method, all lymph node regions between Group I and Group V, ipsilateral spinal accessory nerve, internal jugular vein, and SCM are removed. However, patients with DTC often do not need RND. When the subepithelial and periparotid lymph nodes are removed in RND, the infra-parotid lymph nodes, buccal lymph nodes, retropharyngeal lymph nodes, and paratracheal lymph nodes localized in the posterior to the submandibular triangle are not removed.^[9]

Modified RND

As in RND, Group I–V lymph nodes are removed, but one or more than one of the non-lymphatic structures, such as spinal accessory nerve, internal jugular vein, and SCM, are preserved. In this context, the anatomical structure protected in MRND applied patients is indicated, for example, MRND where the spinal accessory nerve is spared or MRND (spinal accessory nerve).^[9] The head and neck surgery and oncology study group indicated these considerations in their first report, and MRND was schematized in a single figure. In the revised guidelines published in 2002, MRND was schematized into three different figures where only the spinal accessory nerve; the spinal accessory nerve together with the internal jugular vein; and finally, the internal jugular vein, spinal accessory nerve, and SCM were spared, and the preserved structures were indicated in each type of neck dissection.

In fact, these figures define MRND Types I, II, and III as suggested by Medina in 1989.^[19] However, since in this standardization the simplification of definitions and the avoidance of specific definitions as much as possible are the main objectives, so the types of surgery that the study group recommends are catchier and simpler. Since the three types described by Medina can be mixed with each other in practice, the working group's proposal can be easily used without causing confusion. In addition, these three types are not included in other combinations in which non-lymphatic structures other than these three types are protected.

Table 2. Classification of neck dissections (ref. no.: 24)

1991 classification	2002 classification
1. Radical neck dissection	1. Radical neck dissection
2. Modified radical neck dissection	2. Modified radical neck dissection
3. Selective neck dissection	3. Selective neck dissection (SND):
a. Supraomohyoid (Groups I, II, and III)	all types are named as SND. Removed lymph groups or subgroups are written in parenthesis
b. Lateral (Groups II, III, and IV)	
c. Posterolateral (Groups II, III, IV, and V)	
d. Anterior (Group VI)	
4. Extended radical neck dissection	4. Extended radical neck dissection

At the previous revision, the American Head and Neck Society study group reported that when five lymph node regions recommended by the Japanese neck dissection group were excluded from the classification, then it was termed as total neck dissection; if less than five lymph node regions were excluded, then this procedure was named as SND. They also indicated that these nomenclatures are less confusing than the conventional RND and MRND terminologies. However, it has been noted that the group is in search for more understandable terms rather than traditional terms.^[25] Nevertheless, a new proposal has not been made despite 10 years has passed since the previous revision.

Selective Neck Dissection

This term encompasses all lymph node dissections where one or more than one lymph node from the five lymph node groups were not removed during the RND. In other words, it encompasses all lymph node dissections where one or more than one lymph group or subgroups are excised. As shown in Table 2, in the 1991 classification, SND was divided into four subgroups: in supraomohyoid neck dissection, Groups I, II, and III; in lateral neck dissection, Groups II, III, and IV; in posterolateral dissection, Groups II, III, IV, and V; and in anterior neck dissection, Group VI are removed.^[9, 24] After this study, applied SND types increased gradually, and these four groups were unable to encompass all of them. In addition, different SND techniques have been used in these four subgroups. In the revision made in 2002, these special names under the SND have been removed, and it has been suggested that the procedure performed should be reported in parentheses next to the SND.^[24] This recommendation is extremely practical, and it may also prevent confusion. For example, SND that is frequently performed in practice is categorized as follows: SND (II, III, and IV), SND (IIA, III, and IV), and SND (II AB, III, and IV) lateral neck dissection; SND (II, III, IV, and V) posterolateral neck dissection; and SND (VI) and SND (VI and VII) are collected under the headings of anterior neck dissection and SND, respectively.^[22]

Identification of such removed groups in the operative note will contribute significantly to the identification of the extent of a possible secondary intervention in patient monitoring and recurrence. For example, if a recurrence was detected in Group V in a patient who had previously undergone lateral neck dissection, and if the SND (II, III, and IV) had been performed at the first operation, then at least SND (V) should be performed. If SND (II, III, IV, and V) had been previously performed, then the removal of the site of recurrence will suffice.

Extended RND

In addition to the removal of the structures during the RND, one or more lymph node groups and/or non-lymphatic structures are also removed. Examples of these lymphatic groups removed are the parapharyngeal (retropharyngeal), superior mediastinal, perifacial, and paratracheal lymph nodes, and examples of non-lymphatic structures include the carotid artery, hypoglossal nerve, vagus nerve, and paraspinal muscles. When the operation is named, the removed structure is also specified.

For example, an RND where only the external carotid artery is removed can be recorded as ERND (external carotid artery).^[9, 24] When lateral neck dissection is applied in thyroid cancer, SND is also usually performed. RND is rarely used in thyroid cancer. However, when central dissection is performed, this extended RND can be written as ERND (Groups VI and VII).

Thyroid Cancers and Lymphatic System of the Neck

Thyroid Lymphatic System (Distribution)

Thyroid follicles are surrounded by a large lymphatic network, and the lymphatic network in both lobes is in direct relationship with the mediastinum. This structure is considered to be one of the factors explaining the multifocal nature of thyroid cancers, including PTC. The intrathyroidal lymphatic network is the lymphatic channels in the subcapsular region and along the thyroid veins and the lymphatic trunks. These ducts, which are separated from the thyroid veins and thyroids, form efferent major lymphatic vessels, course toward the superior, lateral, and inferior directions together with the thyroid veins, and drain directly into Group VI, directly or indirectly into the lymph nodes contained in the internal jugular (Groups II, III, and IV) or transverse cervical chain.^[31] Therefore, the primary drainage zone of the thyroid is Group VI.^[3] Efferent lymphatics originating from Group VI course laterally in line with Groups IV, III, and II and inferiorly with Group VII.^[3, 31] In general, it is expected that the thyroid cancer cells will follow these directions and cause metastases to the neck lymph nodes.

Lymph Node Metastasis in DTC

Among WDTC, the rate of detection of lymph node metastasis at the time of diagnosis of PTC is higher than that of the FTC.^[32] During the first surgical procedure in PTC, approximately 35% of the patients have clinical, and 80% of the patients have microscopic lymph node metastasis.^[33] These metastases usually manifest first in the ipsilateral and then in the contralateral Group VI, followed by Group IV, III, IIA, and VB, sometimes Group IIB and VA lymph nodes.^[28] Invasion to Group VII often occurs after Group VI.^[31]

It is thought that there may also be a relationship between the location of the PTC in the thyroid and the group which may be metastatic, but Miralle et al.^[34] could not find a correlation between the location of the lymph node metastasis in the neck and the location in the thyroid. However, in PTC, the metastasis to the lateral neck regions without metastasis to the central region is associated with upper pole tumors, which occurs in approximately 8.7%–21.8% of the cases.^[35, 36] However, the rates of skip metastases in the series by Park et al.^[36] were 59.4%, 21.9%, 12.5%, and 6.2% in tumors originating from the upper, middle and lower poles, and the isthmus of the thyroid, respectively.

Lifetime Impact of Lymph Node Metastasis in DTC

There are different interpretations in this regard. Podnos et al.^[37] evaluated the effect of lymph node status in 9904 patients with WDTC with known lymph node status on prognosis using a database of the US Surveillance, Epidemiology, and End Results (SEER) study. The 14-year overall survival rate was 79% in patients with lymph node metastasis and 82% in patients without lymph node metastasis, and the intergroup difference was significant ($p < 0.05$). They determined that lymph node metastasis, age (> 45 years), distant metastasis, and tumor size were factors affecting prognosis in multivariate analysis.

Zaydfudim et al.^[38] analyzed 33,098 patients with WDTC (49% of 30,504 patients with PTC and 55% of 2584 patients with FTC aged ≥ 45 years) using the US SEER database regarding the years 1988 and 2003. They could not detect a significant effect of lymph node metastasis on survival times of the patients with PTC aged < 45 years; however, it adversely affected survival times and risk of death by 46% among patients aged < 45 years. However, in FTC, they determined lymph node metastasis as an effective factor on survival times of patients aged less than or over 45 years. Adam et al.^[39] evaluated data of patients with PTC aged < 45 years using the American National Cancer Database (NCDB) ($n = 47,902$) and SEER database ($n = 21,855$). In both patient groups, total survival was significantly lower in those with lymph node metastases. Up to six lymph node metastases affected prognosis, and prognosis worsened as the number of metastatic lymph nodes increased. In more than six lymph node metastases, an increase in the number of metastases had no effect, and prognosis was poor in all patients.

Findings related to clinical metastasis in preoperative ultrasonography (USG) in a single-center study were predictive factors for age-independent overall survival ($p < 0.001$), disease-specific survival ($p = 0.0097$), and disease-free survival ($p = 0.0005$). No significant difference was found in terms of overall survival, disease-specific survival, and disease-free

survival between patients without clinically evident central metastasis who had undergone central dissection and patients with or without microscopic metastasis gland.^[40]

In the previous update of the TNM version (version 8), which is effective in predicting prognosis, it is noted that the presence of lymph node metastasis was downgraded relative to the previous version. In this update, the age criterion was increased from 45 to 55 years, and all patients > 55 years with a tumor size up to T3 with central and/or lateral lymph node metastases were included in stage II category.^[41] In the previous 7 version, the patient group > 45 years with central metastases was included in stage III, and those with lateral metastases in stage IVA.^[43]

Impact of Lymph Node Metastasis on Recurrence in DCT

The rates of median recurrence risk were 2% (0%–9%) in the absence and 22% (10%–42%) in the presence of clinical lymph node metastasis, 24% (15%–32%) in the presence of extranodal metastasis, or 4% (3%–8%) in cases with less than five and 19% (7%–21%) in cases with more than five metastatic lymph nodes. In the previous ATA guideline, patients with clinical lymph node metastasis or with ≤ 5 micrometastasis (0.2 cm metastasis) were included in the low-risk group, those with clinical lymph node metastasis < 3 cm or > 5 pathological lymph node metastases in the moderate-risk group, and cases with lymph node metastasis > 3 cm in the high-risk group.^[32]

Nomenclature of the Neck Dissections in DTC

In thyroid cancer, SNDs containing one or more regions are generally applied. However, it is noteworthy that different terminologies related to dissection of the central and lateral regions are still used in thyroid cancer.

For example, as is seen, when there is no clinically positive disease in the central region, the removal of the tissue medial to RLS on the right side may be defined as the paratracheal lymph node sampling, whereas the removal of the lymph nodes medial to RLS together with unilateral or bilateral extraction of the prelaryngeal and pretracheal lymph nodes in the presence of clinical lymph node metastasis may be described as paratracheal lymph node dissection.^[44] These definitions are not accepted in the consensus report of the American Head and Neck Surgery Working Group. These dissections can even be thought of as “berry picking.” Central region dissection is SND where regions VI and VII are removed. This can be defined as SND (VI and VII), and it should be written in the operation note like this.

As mentioned earlier, SNDs containing one or more groups or subgroups are applied in the lateral neck region of thyroid cancer. However, it is noteworthy that different defini-

tions are used in the literature. For example, neck dissection from Group II to Group V has been described as total lateral neck dissection or posterolateral dissection.^[45] This dissection is an SND and can be described as SND (II–V). This will allow everyone to easily understand this definition. In the study published in 2016, the definition of functional neck dissection appears to be used for dissection of thyroid carcinoma in which regions II–VI are removed, and protected structures in MRND are also preserved. In fact, this should be described as SND (II–VI).^[46]

In another study, neck dissection from Region III to IV was described as superselective neck dissection.^[47] SND (III and IV) would be more appropriate to use instead of this special name. In 2017, MRND was defined as surgery in which the lymph nodes between regions II and V were removed, whereas the SCM, accessory nerve, and vena jugularis interna were preserved.^[48] In fact, this type of surgery was named by Medina in 1989 as MRND Type B.^[19]

The definition of MRND for the dissection where region II–V is removed is a commonly used definition in our country, but it is not generally stated which structure is preserved. The use of SND (II–V) for this dissection and the indication of the structure spared among non-lymphatic structures will make it easier for everyone to understand, for example, SND (II–V, spinal accessory nerve).

Definitions of Neck Dissections in DTC Prophylactic Dissection

Dissection performed when clinical lymph node metastasis was not detected based on preoperative clinical examination, imaging methods, and intraoperative evaluation (clinical N0) is called prophylactic dissection. Instead, of prophylactic dissection, the term elective dissection may be used. The point that should not be forgotten is that prophylactic central neck dissection (pCND) can be performed in WDTC, whereas lateral neck (Groups II–V) dissection should not be performed. Discussions on this subject will be tackled later.

Therapeutic Dissection

When clinical lymph node metastasis is detected based on preoperative clinical examination, imaging methods, and/or intraoperative evaluation (clinical N1), then the dissection performed is called therapeutic dissection.^[26, 28]

Extent of CND

Unilateral CND is the unilateral removal of the prelaryngeal, pretracheal, and paratracheal region lymph nodes.

Bilateral CND

The prelaryngeal, pretracheal, and bilateral paratracheal lymph node groups, in other words, four lymph nodes in

the central group (Groups VI and VII), are also removed.

It should be emphasized that berry picking, namely, one-by-one removal of clinically enlarged lymph nodes in this region, does not mean lymphatic dissection. Therefore, in the central group dissection, the entire lymphatic tissue together with the adipose tissue within the boundary of the anatomically defined region must be removed in one piece, if possible.

A review of 78.724 patients with PTC obtained from the NCDB was conducted, and 38.653 lymph node metastases were determined to allow an objective assessment of how much lymph nodes should be removed at the central dissection. When one lymph node was removed during the central dissection, there was a 53% false negativity in terms of microscopic metastasis, and this rate decreased <10% when more than six lymph nodes were removed. In this study, it was concluded that 6, 9, and 18 lymph nodes should be examined in T1b, T2, and T3 tumors in order to exclude microscopic metastatic disease with 90% reliability.^[49] The dissection should be performed at least unilaterally in a case where a CND has not been performed before. CND in this context, either pCBD or tCND, can be performed unilaterally or bilaterally depending on the choice of the surgeon and the patient's health condition. Rarely, CND can be performed in the form of extended dissection with the removal of one or several of the groups among the retropharyngeal, retroesophageal, paralaryngopharyngeal, and superior mediastinal lymph node groups caudal to the innominate artery. In this case, the resected additional group should be indicated in the operation note.^[26]

Prophylactic CND and its Extent

The realization of pCND in PTC is still controversial. The risk-benefit balance must be well established in the attempted intervention. For this reason, the operation should not increase the risk of complications while decreasing the risk of recurrence. In a meta-analysis, Wang et al. determined that 31 pCBD should be performed to prevent recurrence.^[50]

In the previous meta-analysis on pCND in PTC, 17 studies and 4437 patients were evaluated. In the group that underwent total thyroidectomy (TT) plus pCND, regional recurrence (lateral neck and central region) was significantly lower than in the TT group and in the pCBD group (4.6% vs. 6.9%, RR=0.66, 95% CI=0.49–0.90, p=0.008). The local recurrence rate in the central region was significantly lower in TT+pCND than in TT (3.4% vs. 1.1%, RR=0.35, 95% CI=0.18–1.68, p=0.002). However, the rate of lateral metastasis was similar (3.3% vs. 3.2%). In the pCND group, higher rates of transient hypocalcemia (28.7% vs. 17.7%, OR = 2.37, 95% CI= 1.89–2.96, p=<0.00001), persistent hypocalcemia (4.1%

vs. 2.3, OR=1.93, 95% CI=1.05–8.5, $p < 0.03$), and morbidity (OR=2.56, 95% CI=1.75–3.74, $p < 0.00001$) were detected. The rates of application of radioactive iodine treatment (RAI) were 74.6% in the pSND group and 59.9% in the TT group, that is, the application of RAI was higher in the dissection group. Although researchers reported that recurrence was lower in the pCND group since RAI treatment was applied more frequently, suggesting that RAI treatment may also be a partial effect in the reduction of local recurrence.^[51] Up to now, no consensus has been reached about whether or not pCND should be routinely performed. Regarding this issue, a multicenter, prospective, randomized longitudinal trial of 5840 patients with longer follow-up period which would have a statistical power of 80% should be planned. Its estimated cost amounts to nearly \$20 million. It is also unrealistic to conduct such a study.^[27]

On the other hand, in certain patients in the WTTC treatment, a gradual, step-by-step shift from TT to lobectomy and moving away from pCND has been observed with time.^[52] Today, considering the risk–benefit ratio, it is generally recommended to use pCND in selected patients instead of routine pCND. In this regard, the latest ATA guideline recommends pCND if it will affect additional treatment modalities in patients with T3 and T4 tumors and lateral metastases.^[32]

In addition, consensus reports from the European Society of Endocrine Surgery and the American Society of Head and Neck Surgery recommend pCND in men, elderly, and pediatric age group; patients with extrathyroidal spread; and cases with bilateral or multifocal tumors.^[28, 53] The guidelines of the British Thyroid Association suggest that in the presence of the above-mentioned features and aggressive histology, decision should be individualized for each patient.^[54] In general, it has been stated as the most rational approach, and the decision of pCND should be given by a multidisciplinary team together with the patient, considering the patient's risk–benefit balance in a patient-specific manner.^[28]

Discussions continue on the extent of pCND, and it appears that there are some differences in various studies and review guidelines. Basically, the variables that determine the extent of dissection, in other words, the determinants of unilateral or bilateral pCND, are as follows: complication rates and the effectiveness of the procedure, prognosis, and effective factors on recurrence. In general, the rates of transient and permanent RLS paralyzes in experienced centers that perform and do not perform pCND are similar. However, compared with TT, the rate of transient hypoparathyroidism is generally increased in both unilateral and bilateral pCND.^[55] In this context, the rate of transient

hypoparathyroidism is higher in bilateral pSND (52%–56%) than in unilateral pCND (29%–36%) (55,56). In addition, Giordano et al.^[56] detected higher rates ($p < 0.001$) of persistent hypoparathyroidism in bilateral pCBD (16.2%) than in both unilateral pCND (7%) and TT (6.3%). In a study comparing the effects of single and bilateral pCNDs on thyroglobulin levels, the postoperative baseline and stimulated thyroglobulin levels were not significantly different between the two groups as for radioiodine uptake.^[55]

Another controversy is that unilateral pCND may miss the metastasis present in the contralateral paratracheal region. Raffaelli et al.^[57] approached this debate from a different perspective. In a study where frozen sections of the ipsilateral CND materials were examined in tumors localized in one lobe, the sensitivity, specificity, and overall accuracy of frozen sections in determining lymph node metastasis were 80.7%, 100%, and 90%, respectively. In another prospective study of the same group, unilateral pCND was applied, and if metastasis was detected, then bilateral pCND was performed. They concluded that frozen section examination was a good indicator of metastasis status. They also stated that routine unilateral pCND and frozen section examination may be an alternative to bilateral pCND in determining staging and may also reduce morbidity.^[58] On the other hand, the cause of false negativity in this method may be due to micrometastases with limited clinical significance.^[57]

When you examine the guidelines, three different guides have different suggestions. The British Thyroid Association guidelines do not suggest unilateral CND as bilateral pCBD provides appropriate staging.^[54] In contrast, both the European Society of Endocrine Surgery and the American Society of Head and Neck Surgery consensus reports recommend that pCND be performed unilaterally by experienced teams to reduce the complication rate.^[28, 53] The ATA guideline indicates that pCND can be performed unilaterally or bilaterally according to patient characteristics.^[27]

Nowadays, many surgeons in general prefer to use unilateral pCND in terms of complication, but the frozen section method can be used to reduce the risk of metastatic tissue release to the contralateral side, and pCND can be extended according to the result.

Therapeutic CND and its Extent

tCND is the standard treatment to reduce recurrence and increase life span when clinical lymph node metastasis is present in the central region.^[28, 32, 59] However, debate is ongoing on whether the tCND should be performed on one or two sides. Whatever is done, the basic aim of the dissection is to reduce the recurrence of the disease and prolong life span.^[28] For this purpose, during thyroidectomy, lymphatic

metastatic disease should not be left behind, and the morbidity due to this surgery should be reduced. Otherwise, morbidity may be increased in the secondary intervention in case of need.

Rafaelli et al.^[59] suggested that bilateral tCND should be performed, whereas Shaha et al.^[60] recommended unilateral tCND, if metastasis is not suspected on the contralateral paratracheal group; otherwise, they recommend bilateral CBD. The ATA guidelines recommend bilateral tCND in the form of selective central dissection (Groups VI and VII) in the presence of clinical metastases in the central region.^[27] The British Thyroid Association guideline does not recommend unilateral tCND as it provides proper staging as is the case with pCND.^[54] The American Head and Neck Surgery Consensus Report suggests unilateral tCND in the presence of clinical paratracheal metastasis on one side and bilateral tCND in the presence of clinical metastases in both paratracheal regions. Nevertheless, they emphasized the importance of the decision of the surgeon regarding the extent of the tCND owing to safety concerns in surgery.^[28]

Most of the unilateral tCND recommendations are based on the suspicion of metastasis, especially in the contralateral paratracheal group for the extent of dissection. How to treat patients with only prelaryngeal or pretracheal lymph node metastasis is not clear. We think that it is more convenient to perform bilateral tCBD in these patients.

Lateral Neck Dissection and its Extent

Lateral neck dissection in WDTC in the form of SND is generally accepted as the therapeutic approach in the presence of clinical metastasis (N1b) in the lateral neck region, and the role of prophylactic lateral dissection in WDTC treatment is rejected. The previous ATA guideline recommends performing a therapeutic selective lateral neck dissection in patients with lateral neck metastases confirmed by fine-needle aspiration biopsy (FNAB) obtained from suspected lymph node and/or thyroglobulin measurement in wash water. The basic principle to reduce recurrence when lateral lymph node metastasis is detected is the selective removal of groups or groups with metastasis.^[61] Despite this basic recommendation, the extent of the therapeutic lateral neck dissection in WDTC is still controversial, and the following studies and results are presented chronologically.

The University of California, San Francisco endocrine surgery center suggests the routine dissection of Groups III and IV in the presence of lateral metastases in PTC, the involvement of zone II in dissection in the presence of metastasis and/or local aggressive disease in Group II and/or extensive metastasis and/or bilateral metastasis in Region III. In addition, other groups (Groups I and V) should

be included in the dissection if metastasis is present.^[62]

Farrag et al.^[45] suggested the routine dissection of Groups IIA, III, IV, and VB in the presence of lateral metastases. In Group IIA, the addition of Group IIB to the dissection was recommended, and elective dissection of Group VA was found to be unnecessary if metastasis, as confirmed by pre-operative FNAB or intraoperative macroscopic metastasis, was detected.

Similarly, the ATA surgical study group consensus report on lateral neck dissection in the DTC recommends SND involving at least Groups IIA, III, IV, and VB to ensure the optimal management of the disease in the presence of lateral metastases. In addition, since metastasis to Group I is rare, this group should not undergo prophylactic dissection. On the other hand, if IIB or IIA does not have suspected lymph node metastasis, there is no indication that Group IIB is added to the dissection. Similarly, in Group VA, dissection of this group may not be necessary if there is no suspected lymph node detected in the USG. The recommended approaches for Groups IIB and VA will help to minimize the morbidities of shoulder syndrome due to accessory nerve injury.^[63] In this consensus report, it is also emphasized that all surgical interventions for thyroid cancer treatment, including lateral neck dissection, should be performed by high-volume hospitals and experienced surgeons in order to minimize the risk of complications. On the other hand, Liao and Shindo indicated that therapeutic lateral neck dissection should include at least Groups IIA, III, and IV in WDTC, and that Group I should be added in the dissection if metastasis was present in this group.^[64] They also stated that there is no consensus in the routine dissection of Group V.

In a meta-analysis of lateral metastasis in WDTC, 18 studies involving 1145 patients and 1298 neck dissections were analyzed, and the rates of metastasis in Groups II, III, and IV were 53.4%, 70.5%, and 66.3%, respectively. The rate of metastasis was found to be 25.3% in Group V in studies where Group V was not divided into VA and VB subgroups and 7.9% and 21.5% in Groups VA and VB, respectively, in studies in which Group V was separated as VA and VB, respectively. In the presence of lateral neck metastases, routine dissection of Groups IIA, IIB, III, IV, and VB has been recommended in light of these data.^[65]

In a very recent retrospective study, Kim et al.^[48] detected total and microscopic metastasis rates in Group V as 13.9% and 8.6%, respectively. In patients with Group V dissection, the recurrence rate was determined as 2.7%, and patients with routine dissection had higher rates of shoulder syndrome with shoulder dysfunction (9.1% vs. 2.7%, $p=0.002$). In addition, in Group V, metastasis was found to be an in-

dependent risk factor for the possibility of metastasis in Groups II, III, and IV. In light of these findings, it was suggested that in the presence of lateral metastases, dissection of Groups II, III, and IV should be performed, and Group V should be added to the dissection if metastases are found in these three groups at the same time or in the presence of radiologically and/or clinically detected metastasis in Group V.

Summiting of Neck Dissection Materials to the Pathology Laboratory

When neck dissection is performed, adequate information should be given to the pathologist about the diagnosis, the prevalence of the disease, and the type of the operation performed. In addition, when the neck dissection material is removed in one piece and sent to the pathology laboratory, the pathologist will examine it according to his/her orientation and will misidentify the lymph node regions because any anatomical boundaries are not indicated beforehand. For this reason, the study group recommends that the surgeon should separate the lymph nodes removed during the final revision of the surgery, and that each group or subgroup be labeled and sent in separate boxes.^[25] If the dissection material is to be delivered in one piece, the groups may be stained differently, as we have done in our clinical practice, or surgical boundaries between groups should be marked with suture material. These approaches will allow pathological examination to be performed in the most appropriate way.

Disclosures

Peer-review: Externally peer-reviewed.

Conflict of Interest: None declared.

Authorship contributions: Concept – M.U., M.T.; Design – M.U., A.İ., M.T.; Supervision – M.U., A.İ.; Materials – M.U., M.T., A.İ.; Data collection &/or processing – M.U., M.T.; Analysis and/or interpretation – M.U., A.İ.; Literature search – M.U., A.İ., M.T.; Writing – M.U., M.T., A.İ.; Critical review – M.U., M.T.

References

- Cabanillas ME, McFadden DG, Durante C. Thyroid cancer. *Lancet* 2016;388:2783–95.
- Gillanders SL, O'Neill JP. Prognostic markers in well differentiated papillary and follicular thyroid cancer (WDTC). *Eur J Surg Oncol* 2018;44:286–296.
- Asimakopoulos P, Nixon IJ, Shaha AR. Differentiated and Medullary Thyroid Cancer: Surgical Management of Cervical Lymph Nodes. *Clin Oncol* 2017;29:283–289.
- Ferlito A, Rinaldo A, Silver CE, Shah JP, Suárez C, Medina JE, et al. Neck dissection: then and now. *Auris Nasus Larynx* 2006;33:365–74.
- Jawdyski F. A case of the primary cancer of the neck, so-called Volkmann's branchiogenic cancer. Resection together with internal jugular vein and common carotid artery. *Cure Gaz Lek* 1888;23:530–7.
- Towpik E. Centennial of the first description of the en bloc neck dissection. *Plast Reconstr Surg* 1990;85:468–70.
- Crile GW. On the surgical treatment of cancer of the head and neck. With a summary of one hundred and twenty-one operations performed upon one hundred and five patients. *Trans South Surg Gynecol Assoc* 1905;18:108–27.
- Crile GW. Excision of cancer of the head and neck. With special reference to the plan of dissection based on the hundred and thirty-two operations. *JAMA* 1906;47:1780–6.
- Robbins KT, Medina JE, Wolfe GT, Levine PA, Sessions RB, Pruet CW. Standardizing neck dissection terminology. Official report of the Academy's Committee for Head and Neck Surgery and Oncology. *Arch Otolaryngol Head Neck Surg* 1991;117:601–5.
- Martin H, Del Valle B, Ehrlich H, Cahán Wg. Neck dissection. *Cancer* 1951;4:441–99.
- Rouviere H. *Anatomie des Lymphatiques de l'Homme*. Paris: Masson et Cie; 1932.
- Shah JP, Strong E, Spiro RH, Vikram B. Surgical grand rounds. Neck dissection: current status and future possibilities. *Clin Bull* 1981;11:25–33.
- Suárez O. El problema de las metastasis linfaticas y alejadas del cancer de laringe e hipofaringe. *Rev Otorrinolaryngol* 1963;23:83–99.
- Ferlito A, Rinaldo A, Osvaldo Suárez: often-forgotten father of functional neck dissection (in the non-Spanish-speaking literature). *Laryngoscope* 2004;114:1177–8.
- Bocca E, Pignataro O, Oldini C, Cappa C. Functional neck dissection: an evaluation and review of 843 cases. *Laryngoscope* 1984;94:942–5.
- Bocca E, Pignataro O, Sasaki CT. Functional neck dissection. A description of operative technique. *Arch Otolaryngol* 1980;106:524–7.
- Gavilán C, Gavilán J. Five-year results of functional neck dissection for cancer of the larynx. *Arch Otolaryngol Head Neck Surg* 1989;115:1193–6.
- Gavilán J, Gavilán C, Herranz J. Functional neck dissection: three decades of controversy. *Ann Otol Rhinol Laryngol* 1992;101:339–41.
- Medina JE. A rational classification of neck dissections. *Otolaryngol Head Neck Surg* 1989;100:169–76.
- Lindberg R. Distribution of cervical lymph node metastases from squamous cell carcinoma of the upper respiratory and digestive tracts. *Cancer* 1972;29:1446–9.
- Shah JP. Patterns of cervical lymph node metastasis from squamous carcinomas of the upper aerodigestive tract. *Am J Surg* 1990;160:405–9.
- Ferlito A, Robbins KT, Silver CE, Hasegawa Y, Rinaldo A. Classification of neck dissections: an evolving system. *Auris Nasus Larynx* 2009;36:127–34.

23. Hasegawa Y, Saikawa M. Update on the classification and nomenclature system for neck dissection: revisions proposed by the Japan Neck Dissection Study Group. *Int J Clin Oncol* 2010;15:5–12.
24. Robbins KT, Clayman G, Levine PA, Medina J, Sessions R, Shaha A, et al.; American Head and Neck Society; American Academy of Otolaryngology-Head and Neck Surgery. Neck dissection classification update: revisions proposed by the American Head and Neck Society and the American Academy of Otolaryngology-Head and Neck Surgery. *Arch Otolaryngol Head Neck Surg* 2002;128:751–8.
25. Robbins KT, Shaha AR, Medina JE, Califano JA, Wolf GT, Ferlito A, et al; Committee for Neck Dissection Classification, American Head and Neck Society. Consensus statement on the classification and terminology of neck dissection. *Arch Otolaryngol Head Neck Surg* 2008;134:536–8.
26. Carty SE, Cooper DS, Doherty GM, Duh QY, Kloos RT, Mandel SJ, et al. American Thyroid Association Surgery Working Group; American Association of Endocrine Surgeons; American Academy of Otolaryngology-Head and Neck Surgery; American Head and Neck Society. Consensus statement on the terminology and classification of central neck dissection for thyroid cancer. *Thyroid* 2009;19:1153–8.
27. Carling T, Carty SE, Ciarleglio MM, Cooper DS, Doherty GM, Kim LT, et al; American Thyroid Association Surgical Affairs Committee. American Thyroid Association design and feasibility of a prospective randomized controlled trial of prophylactic central lymph node dissection for papillary thyroid carcinoma. *Thyroid* 2012;22:237–44.
28. Agrawal N, Evasovich MR, Kandil E, Noureldine SI, Felger EA, Tufano RP, et al. Indications and extent of central neck dissection for papillary thyroid cancer: An American Head and Neck Society Consensus Statement. *Head Neck* 2017;39:1269–1279.
29. İlgör A, Uludağ A. Boynun fonksiyonel ve cerrahi anatomisi. In: İlgör A, Uludağ M, editor. *Tiroit*. 1st. İstanbul: Nobel Tıp Kitabevleri; 2013. p.749–73.
30. Tufano RP, Potenza A, Randolph GW. Central Neck Dissection: Technique. In: Randolph GW, editor. *Surgery of the Thyroid and Parathyroid Glands*. 2nd. Philadelphia: Elsevier Saunders; 2013. p. 373–81.
31. İlgör A, Uludağ M. Tiroidin Fonksiyonel ve Cerrahi Anatomisi. In: İlgör A, Uludağ M, editor. *Tiroit*. 1st. İstanbul: Nobel Tıp Kitabevleri; 2013. p. 775–800.
32. Haugen BR, Alexander EK, Bible KC, Doherty GM, Mandel SJ, Nikiforov YE, et al. 2015 American Thyroid Association Management Guidelines for Adult Patients with Thyroid Nodules and Differentiated Thyroid Cancer: The American Thyroid Association Guidelines Task Force on Thyroid Nodules and Differentiated Thyroid Cancer. *Thyroid* 2016;26:1–133.
33. Gimm O, Rath FW, Dralle H. Pattern of lymph node metastases in papillary thyroid carcinoma. *Br J Surg* 1998;85:252–4.
34. Mirallié E, Visset J, Sagan C, Hamy A, Le Bodic MF, Paineau J. Localization of cervical node metastasis of papillary thyroid carcinoma. *World J Surg* 1999;23:970–3.
35. Lei J, Zhong J, Jiang K, Li Z, Gong R, Zhu J. Skip lateral lymph node metastasis leaping over the central neck compartment in papillary thyroid carcinoma. *Oncotarget* 2017;8:27022–33.
36. Park JH, Lee YS, Kim BW, Chang HS, Park CS. Skip lateral neck node metastases in papillary thyroid carcinoma. *World J Surg* 2012;36:743–7.
37. Podnos YD, Smith D, Wagman LD, Ellenhorn JD. The implication of lymph node metastasis on survival in patients with well-differentiated thyroid cancer. *Am Surg* 2005;71:731–4.
38. Zaydfudim V, Feurer ID, Griffin MR, Phay JE. The impact of lymph node involvement on survival in patients with papillary and follicular thyroid carcinoma. *Surgery* 2008;144:1070–7.
39. Adam MA, Pura J, Goffredo P, Dinan MA, Reed SD, Scheri RP, et al. Presence and Number of Lymph Node Metastases Are Associated With Compromised Survival for Patients Younger Than Age 45 Years With Papillary Thyroid Cancer. *J Clin Oncol* 2015;33:2370–5.
40. Moreno MA, Edeiken-Monroe BS, Siegel ER, Sherman SI, Clayman GL. In papillary thyroid cancer, preoperative central neck ultrasound detects only macroscopic surgical disease, but negative findings predict excellent long-term regional control and survival. *Thyroid* 2012;22:347–55.
41. Amin MB, Edge S, Greene F, Byrd DR, Brookland RK, Washington MK, et al., editors. *AJCC cancer staging manual*. 8th. New York: Springer; 2017.
42. Edge SB, Byrd DR, Compton CC, Fritz AG, Greene FL, Trotti A, editors. *AJCC cancer staging manual*. 7th. New York: Springer; 2010.
43. Mizrachi A, Shaha AR. Lymph Node Dissection for Differentiated Thyroid Cancer. *Mol Imaging Radionucl Ther* 2017;26:10–15.
44. McAlister ED, Goldstein DP, Rotstein LE. Redefining classification of central neck dissection in differentiated thyroid cancer. *Head Neck* 2014;36:286–90.
45. Farrag T, Lin F, Brownlee N, Kim M, Sheth S, Tufano RP. Is routine dissection of level II-B and V-A necessary in patients with papillary thyroid cancer undergoing lateral neck dissection for FNA-confirmed metastases in other levels. *World J Surg* 2009;33:1680–3.
46. Xu J, Chen C, Zheng C, Wang K, Shang J, Fang X, et al. Application of a cervical low incision in the functional neck dissection of thyroid papillary carcinoma. *Mol Clin Oncol* 2016;4:477–482.
47. An C, Zhang X, Wang S, Zhang Z, Yin Y, Xu Z, et al. Efficacy of Superselective Neck Dissection in Detecting Metastasis in Patients with cN0 Papillary Thyroid Carcinoma at High Risk of Lateral Neck Metastasis. *Med Sci Monit* 2017;23:2118–2126.
48. Kim SK, Park I, Hur N, Lee JH, Choe JH, Kim JH, et al. Should Level V Be Routinely Dissected in N1b Papillary Thyroid Carcinoma? *Thyroid* 2017;27:253–260.
49. Robinson TJ, Thomas S, Dinan MA, Roman S, Sosa JA, Hyslop T. How Many Lymph Nodes Are Enough? Assessing the Adequacy of Lymph Node Yield for Papillary Thyroid Cancer. *J Clin Oncol* 2016;34:3434–9.
50. Wang TS, Cheung K, Farrokhyar F, Roman SA, Sosa JA. A meta-

- analysis of the effect of prophylactic central compartment neck dissection on locoregional recurrence rates in patients with papillary thyroid cancer. *Ann Surg Oncol* 2013;20:3477–83.
51. Zhao W, You L, Hou X, Chen S, Ren X, Chen G, et al. The Effect of Prophylactic Central Neck Dissection on Locoregional Recurrence in Papillary Thyroid Cancer After Total Thyroidectomy: A Systematic Review and Meta-Analysis : pCND for the Locoregional Recurrence of Papillary Thyroid Cancer. *Ann Surg Oncol* 2017;24:2189–2198.
52. Goepfert RP, Clayman GL. Management of the central compartment in differentiated thyroid carcinoma. *Eur J Surg Oncol* 2018;44:327–331.
53. Sancho JJ, Lennard TW, Paunovic I, Triponez F, Sitges-Serra A. Prophylactic central neck dissection in papillary thyroid cancer: a consensus report of the European Society of Endocrine Surgeons (ESES). *Langenbecks Arch Surg* 2014;399:155–63.
54. Perros P, Boelaert K, Colley S, Evans C, Evans RM, Gerrard Ba G, et al; British Thyroid Association. Guidelines for the management of thyroid cancer. *Clin Endocrinol (Oxf)* 2014;81 Suppl 1:1–122.
55. Raffaelli M, De Crea C, Sessa L, Giustacchini P, Revelli L, Bellantone C, et al. Prospective evaluation of total thyroidectomy versus ipsilateral versus bilateral central neck dissection in patients with clinically node-negative papillary thyroid carcinoma. *Surgery* 2012;152:957–64.
56. Giordano D, Valcavi R, Thompson GB, Pedroni C, Renna L, Gradoni P, et al. Complications of central neck dissection in patients with papillary thyroid carcinoma: results of a study on 1087 patients and review of the literature. *Thyroid* 2012;22:911–7.
57. Raffaelli M, De Crea C, Sessa L, Giustacchini P, Bellantone R, Lombardi CP. Can intraoperative frozen section influence the extension of central neck dissection in cN0 papillary thyroid carcinoma? *Langenbecks Arch Surg* 2013;398:383–8.
58. Raffaelli M, De Crea C, Sessa L, Fadda G, Bellantone C, Lombardi CP. Ipsilateral Central Neck Dissection Plus Frozen Section Examination Versus Prophylactic Bilateral Central Neck Dissection in cN0 Papillary Thyroid Carcinoma. *Ann Surg Oncol* 2015;22:2302–8.
59. De Crea C, Raffaelli M, Sessa L, Lombardi CP, Bellantone R. Surgical approach to level VI in papillary thyroid carcinoma: an overview. *Updates Surg* 2017;69:205–9.
60. Shaha AR, Silver CE, Angelos P, Nixon IJ, Rodrigo JP, Sanabria A, et al. The central compartment - Center of controversy, confusion, and concern in management of differentiated thyroid cancer. *Eur J Surg Oncol* 2017;43:1981–4.
61. Schmidbauer B, Menhart K, Hellwig D, Grosse J. Differentiated Thyroid Cancer-Treatment: State of the Art. *Int J Mol Sci* 2017;18.
62. Caron NR, Tan YY, Ogilvie JB, Triponez F, Reiff ES, Kebebew E, et al. Selective modified radical neck dissection for papillary thyroid cancer-is level I, II and V dissection always necessary? *World J Surg* 2006;30:833–40.
63. Stack BC Jr, Ferris RL, Goldenberg D, Haymart M, Shaha A, Sheth S, et al.; American Thyroid Association Surgical Affairs Committee. American Thyroid Association consensus review and statement regarding the anatomy, terminology, and rationale for lateral neck dissection in differentiated thyroid cancer. *Thyroid* 2012;22:501–8.
64. Liao S, Shindo M. Management of well-differentiated thyroid cancer. *Otolaryngol Clin North Am* 2012;45:1163–79.
65. Eskander A, Merdad M, Freeman JL, Witterick IJ. Pattern of spread to the lateral neck in metastatic well-differentiated thyroid cancer: a systematic review and meta-analysis. *Thyroid* 2013;23:583–92.