

Received: 2016.10.14  
Accepted: 2016.12.02  
Published: 2017.06.07

# Treatment of Transverse with or without Posterior Wall Fractures of Acetabulum Using a Modified Smith-Petersen Combined with Kocher-Langenbeck Approach

Authors' Contribution:  
Study Design A  
Data Collection B  
Statistical Analysis C  
Data Interpretation D  
Manuscript Preparation E  
Literature Search F  
Funds Collection G

E 1 **Tu Hu\***  
C 1 **Haitao Xu\***  
D 1 **Chaolai Jiang**  
B 2 **Geliang Ren**  
B 1 **Zhiquan An**

1 Department of Orthopedics, Shanghai Jiao Tong University Affiliated Sixth People's Hospital, Shanghai, P.R. China  
2 Department of Trauma Orthopedics, Huainan Xinhua Hospital, Huainan, Anhui, P.R. China

\* These authors contributed equally to this work

**Corresponding Author:** Zhiquan An, e-mail: zhiquan\_an@163.com  
**Source of support:** Departmental sources

**Background:** The aim of this study was to explore the surgical treatment of transverse with or without posterior wall fractures of the acetabulum.





**Material/Methods:** We surgically treated 21 consecutive cases of pure transverse (7 cases) and with posterior wall (14 cases) fractures of the acetabulum. The anterior column fractures were firstly reduced, temporarily fixed through a modified Smith-Petersen small incision, and finally fixed after the fixation of the posterior column and wall fractures, which were reduced and fixed through a Kocher-Langenbeck approach. The operative time, intra-operative blood loss, quality of reduction (Matta criteria), perioperative complications, osseous union, subsequent complications, and hip function evaluation were recorded.

**Results:** The mean operative time was 198.1 min and the mean intra-operative blood loss was 938.1 ml. Anatomic reduction of the anterior column was obtained in 20 cases and was imperfect in 1 case. All posterior column and wall fractures were anatomically reduced. We followed up 18 cases for a mean duration of 16.3 (8–30) months. All the fractures achieved osseous union. The mean Harris score was 85.1 points, with an excellent result in 7 cases, good in 8, fair in 2, and poor in 1. According to modified Merle d' Aubigne and Postel score system, the results were excellent in 2 cases, good in 15, and poor in 1. Avascular necrosis of the femoral head occurred in 1 case, heterotopic ossification in 3 cases, and numbness of the anterolateral thigh in 6 cases.

**Conclusions:** For transverse with or without posterior wall fractures of the acetabulum, reduction and fixation of anterior and posterior column should be done in sequence, and a modified Smith-Petersen small incision might be a good choice in reduction and fixation of the anterior column because it possesses advantages of direct visualization and minimal invasion.

**MeSH Keywords:** **Acetabulum • Fracture Fixation • Surgical Instruments**

**Full-text PDF:** <http://www.medscimonit.com/abstract/index/idArt/901966>

 3386  4  10  25



## Background

Pure transverse and associated posterior wall fractures are common types of acetabular fractures, in which the former accounts for 19% and the latter 20% [1]. The main fracture lines of these 2 types of acetabular fractures both originate from the anterior column, go through the quadrilateral plate, and finally end at the posterior column. The property of these fractures incurs a similarity when a surgical procedure is applied. It is a consensus that the displaced pure transverse fractures and associated posterior wall fractures should be surgically treated; however, many controversies exist regarding selection of the optimal approach and desirable fixations, especially for anterior column fractures.

In recent studies, the Koch-Langenbeck (K-L) approach is recommended for the reduction and internal fixation of fractures of both anterior and posterior columns in treating transverse with or without posterior wall fractures of the acetabulum [2–5]. According to the literature, fractures of the posterior column and posterior wall can be reduced directly, but fractures of the anterior columns always have to be reduced indirectly by palpating the fracture line from the greater sciatic notch when the K-L approach is used. Regardless of which way the anterior column fracture is reduced and maintained through the K-L approach, whether the fracture line of anterior column can be palpated clearly from the greater sciatic notch is still debatable. Collinge et al. and Negrin et al. compared the reduction qualities of transverse fractures through the K-L approach in prone or lateral position and found that the displacement of anterior column persistently existed no matter which position was used. The mean gap between the main fragments was 2.1 mm (lateral) and 1.3 mm (prone), while the maximum displacement was 7 mm [6,7]. The authors believed that this displacement might be caused by the weight of the ipsilateral lower limb. Negrin found that it is difficult to accomplish an anatomic reduction of the anterior column fracture of transverse with or without posterior wall fractures of acetabulum through the K-L approach alone. Masse et al. proposed a modified K-L approach involving digastric trochanteric flip osteotomy and dislocation of the femoral head to achieve reductions of the anterior and posterior columns under direct vision [8]. Of the 31 patients in Masse's report, fracture reduction was defined as anatomic in 65% cases, imperfect in 16%, and poor in 19%; 2 patients developed symptomatic femoral head avascular necrosis. This approach may offer increased visualization with easier reduction; however, it subjects patients to increased morbidity and has limited clinical applicability due to potential risks of femoral head avascular necrosis.

The surgical outcomes of acetabular fractures are closely related to the qualities of reduction. According to Li et al., if the displacement of a transverse acetabular fracture is more than

2 mm, incidence of traumatic arthritis increases dramatically [9]. Thus, we think it is still a critical issue to select a proper approach to improve the reduction quality of transverse with or without posterior wall fractures of the acetabulum and to decrease the occurrence of complications.

From February 2013 to May 2015, 21 consecutive cases of transverse with or without posterior wall fractures of acetabulum were surgically treated by our senior author (ZQ An) through a modified Smith-Petersen small incision combined with K-L approach. We successfully followed up 18 cases for at least 8 months and satisfactory results were obtained.

## Material and Methods

### Patients

There were 16 men and 5 women with an average age of 45.1 years (range, 19–62 years) in this cohort; 14 were injured on the left side and 7 on the right side (Table 1). The study was approved by the local ethical committee. Patients were asked to give their informed consent to the use of an unconventional approach when they were eligible according to the selection criteria. The mechanism of the initial injury was a traffic accident in 15 cases, mass injury in 3 cases, falling down in 2 cases, and falling from height in 1 case. There were 7 pure transverse fractures and 14 transverse and associated posterior wall fractures according to the classification of Judet and Letournel [10,11]. Four patients had isolated acetabular fractures and in 17 patients the acetabular fractures were combined with other injuries. Among these injuries, 10 cases had other organ injuries, 5 had posterior dislocation of the hip joint, 6 had pelvic fractures, and 4 had fractures in the extremities. The average interval from injury to surgery was 15.1 days (range, 3–39 days). All fractures were confirmed by radiography on anteroposterior (AP), iliac oblique, and obturator oblique views. 3D CT scanning was performed in all cases. The mean maximum distance between the broken ends of the anterior column on the coronal view of preoperative CT (Figure 1) was 6.8 mm (range, 3–12 mm) (Table 2). The inclusion criterion in the study was displaced transverse with or without posterior wall fractures of the acetabulum in adults. The exclusion criteria were undisplaced fractures, premature fractures in the acetabulum, and pathological fractures.

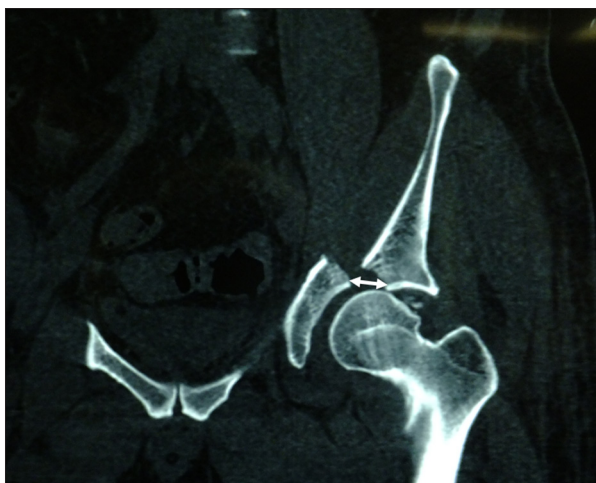### Surgical technique

All surgical procedures were performed by one of the authors (ZQ An). Under general anesthesia with intra-tracheal intubation, the patient was placed in floating position on a radiolucent operative table permitting intra-operative unobstructed fluoroscopy on AP and iliac oblique and obturator oblique

**Table 1.** Population data.

Patient number	Gender	Age (years)	Side	Fracture type	Follow-up (months)
1	Female	44	Left	T + PW	28
2	Male	35	Right	T	26
3	Male	56	Left	T	30
4	Male	58	Right	T + PW	Lost
5	Male	49	Right	T + PW	16
6	Male	27	Left	T + PW	18
7	Male	58	Left	T	18
8	Male	32	Left	T + PW	18
9	Male	54	Left	T + PW	18
10	Female	19	Left	T	16
11	Male	46	Left	T + PW	13
12	Male	43	Right	T	12
13	Male	47	Left	T	15
14	Female	46	Left	T + PW	12
15	Male	31	Right	T + PW	13
16*	Male	46	Left	T + PW	Death
17	Male	62	right	T + PW	12
18	Male	39	left	T + PW	9
19	Female	59	right	T	12
20	Male	52	Left	T + PW	9
21	Female	40	left	T + PW	8

T – transverse; T + PW – transverse and posterior wall; \* Died of pulmonary embolism 3 days after surgery.



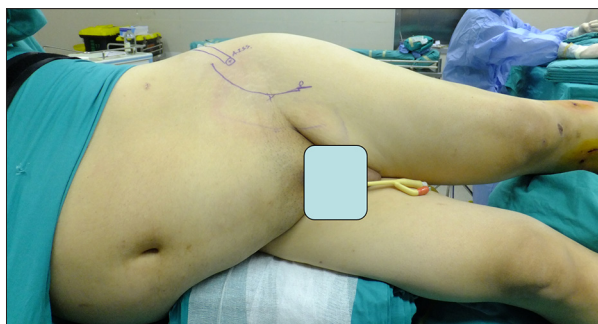
**Figure 1.** The displacement of the main fragment of the anterior column was measured on the coronal view of a 3D CT scan.

views. The affected limb was draped free to allow for intra-operative reduction maneuvers.

Firstly, the patient was placed in supine position. A modified Smith-Petersen incision was made starting 1.5 cm medially and superiorly to the anterior superior iliac spine (ASIS) and curved distally through the lateral side of the mid-point of the inguina toward the anterolateral thigh and ended 2 cm distal to inguina (Figure 2). The aponeurosis of the external oblique muscle and fascia lata were dissected along the incision. The inguinal ligament was incised medial to its insertion of the ASIS. The lateral femoral cutaneous nerve was carefully protected. With hip flexion at about 60° and adequate adduction, the iliopsoas muscle was retracted medially and the anterior column fracture line was exposed starting from the anterior edge of the anterior wall, passing through the pelvic brim and to the anterior portion of the quadrilateral plate. The hematoma and embedded soft tissue between the fragments were cleaned. A pointed reduction clamp was used to

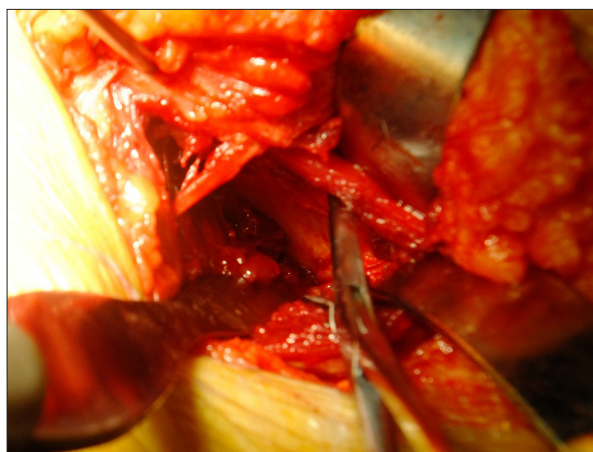
**Table 2.** Patient demographics.

Parameter	Value
Age (years)	45.1 (19–62)
Male gender	16
Injured side	
Left	14
Right	7
Mechanism of injury	
Traffic accident	15
Injured by a mass	3
Falling	2
Falling from height	1
Fracture classification	
Transverse	7
Transverse and posterior wall	14
Accompanying injuries	
Other organ injury	10
Posterior dislocation of hip joint	5
Pelvic fractures	6
Fractures in extremities	4
Interval from injury to surgery (days)	15.1 (3–39)
Maximum displacement of the anterior column (mm)	6.8 (3–12)



**Figure 2.** The patient was placed in a floating position and a modified Smith-Peterson incision was marked on the skin.

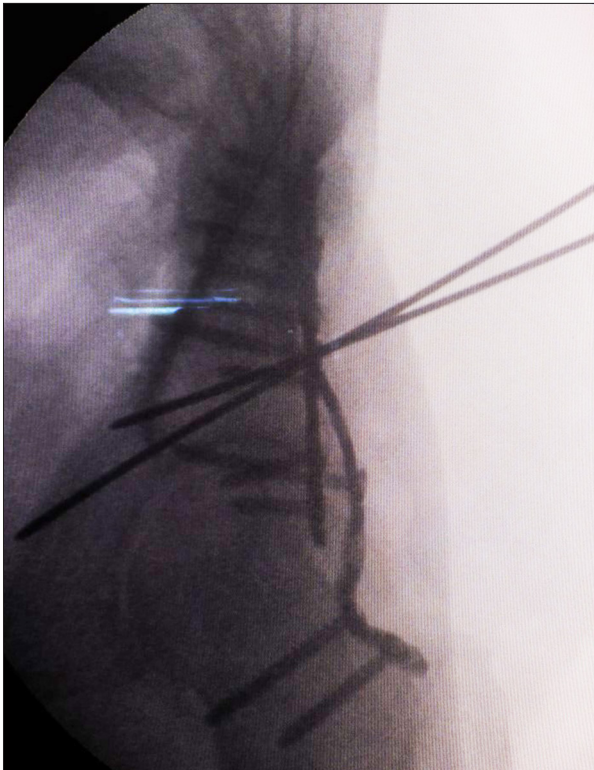
reduce the anterior column fracture. One tip of the clamp was placed on the lateral side of the anterior inferior iliac spine (AIIS) and the other on the inner side of the pelvic brim of the main distal fragment (Figure 3). With the assistant's continuous traction of the affected lower extremity and internal and



**Figure 3.** A pointed reduction clamp was used to reduce anterior column fractures.

external rotation of the femoral head, the posterior-superior displacement of the distal fragment could be reduced. Medial displacement of the fragment could be always rectified with the constant compression of the reduction clamp. The anatomic reduction was identified under direct visualization by checking the fracture line at the anterior edge of the anterior wall, pelvic brim, and the anterior part of the quadrilateral plate, then one or two 2.0-mm K-wires were used to temporarily fix the fracture. The wires were drilled from the outer cortex of the AIIS, passing through the fracture line and the distal fragment, with its tip emerged into the pelvic cavity near the pelvic brim about 1 cm distal to the fracture line. The wires should be placed as vertical to the fracture line as possible. The reduction and the position of the wires were checked with the C-arm on obturator oblique view to make sure that the anterior column was anatomically reduced and the wires were in the anterior column without entering the hip joint.

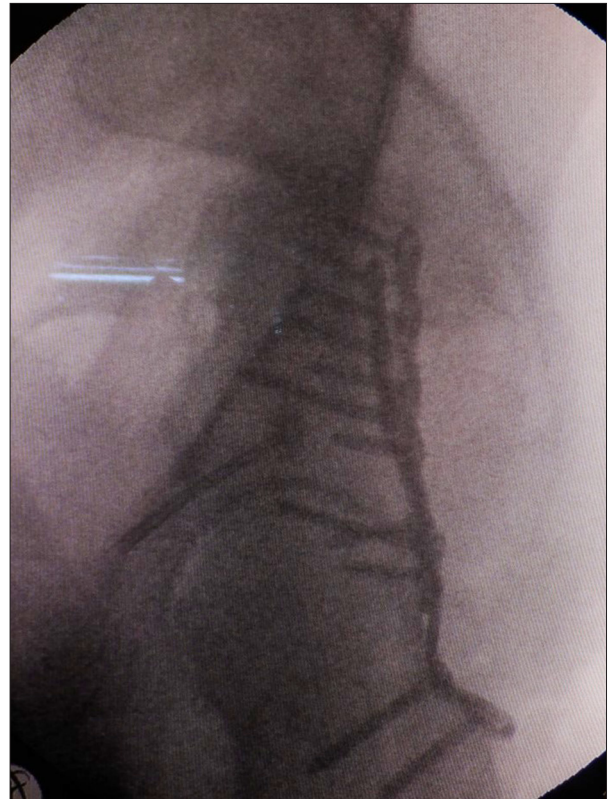
Then, the patient was changed to lateral decubitus position. K-L approach was applied to expose the fractures of posterior column and posterior wall, similar to a previously described method [4]. The hematoma and embedded soft tissue among the fragments were cleaned as mentioned above. The joint cavity was checked and thoroughly irrigated to ensure that all debris had been removed, especially in cases of associated posterior wall fractures. The posterior column was firstly restored, and then the marginal impacted articular fragments, and lastly the retroacetabular fragment. The reductions were temporarily maintained with K-wires and pointed reduction forceps. Cancellous bone graft harvested from the greater trochanter was used if necessary. Both column fractures were checked with the C-arm to identify that the anatomic reduction was achieved. A reconstruction plate (usually 6 holes) was firstly applied to fix the posterior column fracture. The posterior wall fractures were then stabilized with a contoured reconstruction plate (usually 8 holes) placed distally on the ischial tuberosity



**Figure 4.** The anterior column fracture was first reduced and temporarily fixed with 2 K-wires, and then the posterior column and wall fractures were reduced and fixed with 2 plates. Before application of final fixation of the anterior column fracture, its position was checked again on the C-arm.

and proximally on the intact ilium. Two screws were inserted into the most distal and proximal 2 holes in each end of the plate. Ideally, 1 more screw was inserted into the hole closest to the main fracture line in each side. The tips of these 2 screws should emerge out of the cortex of the quadrilateral plate, as confirmed by palpation. A spring plate was used to fix the small fragments near the rim of acetabulum, if necessary (Figure 4).

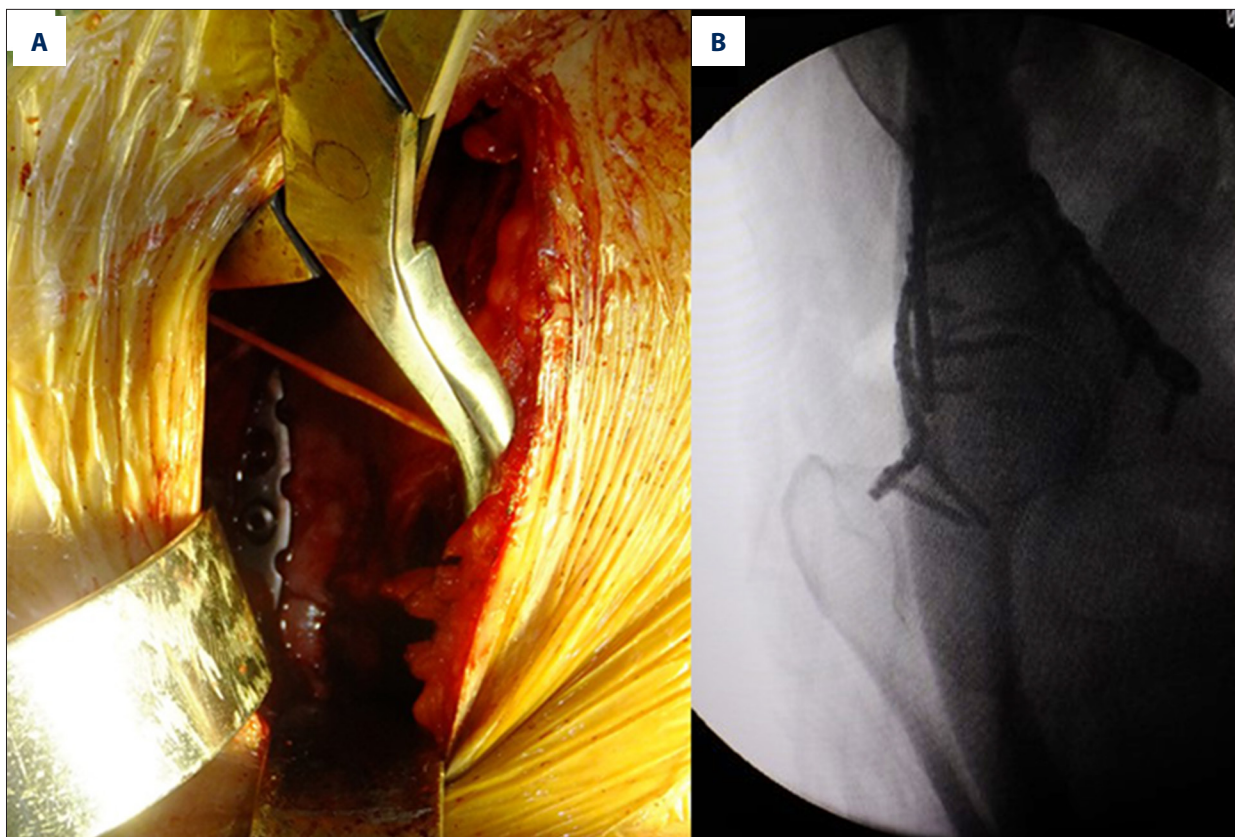
Finally, the patient was changed to supine position and we determined if there was re-displacement of the anterior column fracture, confirmed again under direct vision. Keeping the pointed reduction clamp in the position mentioned above, a drill sleeve was placed on the outer cortex of the AIIS along the K-wire inserted before. The position of the drill sleeve was maintained by 1 assistant and the 2.0-mm K-wire was drilled out and a 1.2-mm guide wire was inserted into the path created by the 2.0-mm K-wire through the drill sleeve. The drill sleeve was removed while keeping the 1.2-mm K-wire in position. A 4.0-mm cannulated screw was inserted along the guide wire and tightened firmly leaving 2 or 3 threads emerged out of the cortex of the distal fragment. One more screw was used if possible (Figure 5).



**Figure 5.** The reductions and screws and plates on both columns were finally checked. In this patient, the anterior and posterior column were anatomically reduced and are shown on obturator oblique view.

A short reconstruction plate was used, isolated or combined with the cannulated screw, if motion was found after a cannulated screw fixation, or if it was difficult to fix with cannulated screws (Figure 6). The plate was placed across the fracture line on the superior side of the pelvic brim and parallel to the pelvic brim. At least 2 screws were drilled at the end of the plate. The second most distal screw was placed on the superior pubic rim near the outlet of the obturator canal. This screw was directed medially and distally to prevent injury to the obturator artery and entering the joint. The proximal screws were directed superiorly and medially to avoid entering the acetabulum. The clamp was then removed.

The stabilities of fractures on both columns were checked under direct vision, while the hip was passively moved in flexion, and extension, as well as internal and external rotation, to make sure that the internal fixations were stable. The reductions and the adequate length and direction of screws were confirmed by C-arm on the AP, iliac oblique, and obturator oblique views.



**Figure 6.** A short, contoured reconstruction plate was also used to isolate and fix this anterior column fracture (A, B).

The incisions were then routinely closed with re-suturing of the inguinal ligament after a drainage tube was placed in each incision.

In this series, the anterior columns of the 21 patients were fixed with 2 cannulated screws in 8 cases, 1 cannulated screw in 6 cases; 1 cannulated screw combined with a reconstruction plate in 3 cases, and only 1 reconstruction plate in 4 cases. The posterior columns were stabilized with 2 reconstruction plates in 17 cases, 2 reconstruction plates combined with a spring plate in 3 cases, and 1 reconstruction plate in 1 case (Table 3).

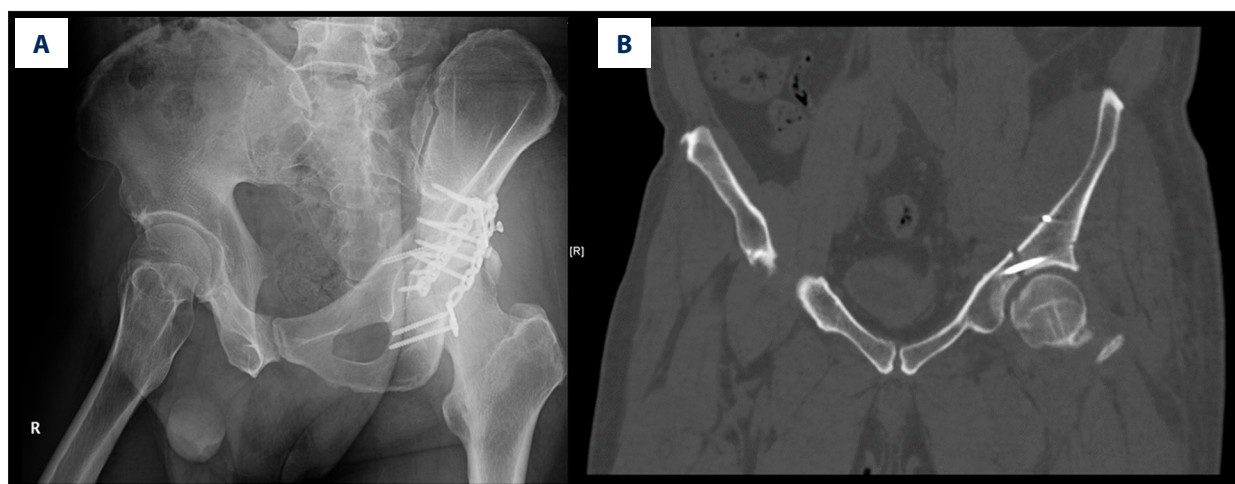
**Postoperative care**

After the operations, active hip flexion and extension were encouraged as soon as pain was relieved. The drainage tubes were removed 48 h after the operation. The stitches were removed 2 weeks postoperatively. Non-weight-bearing motions were permitted in bed within 6 weeks. Partial weight bearing started 3 months postoperatively when the osseous union was confirmed by X-ray film or CT scan. Full weight bearing was permitted half a year after the operation. The patients were followed up every month within 3 months and every 3 months half a year after surgery. One year after the operation, the patients were followed up every 6 months. X-rays were taken

**Table 3.** Fixation patterns.

Fixation pattern	Value
<b>Anterior column</b>	
Two cannulated screws	8
One cannulated screw	6
One cannulated screw combining reconstruction plate	3
Reconstruction plate	4
<b>Posterior column</b>	
Two reconstruction plates	17
Two reconstruction plates & a steel spring plate	3
One reconstruction plate	1

on the AP, iliac oblique, and obturator oblique views, and the hip functions were checked at each time point.



**Figure 7.** A 54-year-old patient with anterior column of the transverse and associated posterior wall fractures, fixed with a cannulated screw. (A) postoperative X-ray examination. (B) A 3-mm gap was identified on a postoperative CT scan; hip function was excellent.

### Outcome evaluation

The reduction was evaluated on the first postoperative radiography on the AP, iliac oblique, and obturator oblique views and CT scan (if necessary) according to the Matta criteria [12]. If the measured displacement was less than 1 mm, it was categorized as anatomical reduction; if it was in the range of 1–3 mm, it was imperfect reduction; and if it was >3 mm, it was poor reduction.

The surgical time was calculated from the skin incision to suture. Intra-operative blood loss was recorded. Perioperative complications, degree of osseous union, and later complications were recorded. The presence of heterotopic ossification was recorded and graded according to Brooker classification [13]. The hip functions were evaluated by using the criteria of the modified Harris score [14] and modified Merle d' Aubigne and Postel score system.

### Results

The mean surgical time was 198.1 min (range, 120–400 min; SD, 82.6), whereas the mean intra-operative blood loss was 938.1 ml (range, 400–2500 ml; SD, 609.9). On the first postoperative radiography of the AP, iliac oblique, and obturator oblique views, anatomic reduction of the anterior column was identified in 20 cases. An imperfect reduction was identified in 1 case (case 9) (Figure 7), probably due to the untightened screw and insufficient compression at the fractures site. All 21 cases obtained anatomic reduction in the posterior column. 3D CT scan was applied in 4 cases to confirm anatomic reduction.

Unfortunately, 1 case in this cohort died due to pulmonary embolism. One case was unable to complete the hip function

evaluation because of spine nerve injuries caused by fracture of the first lumbar vertebra, but osseous union was achieved at 9 months after the operation. One case was lost to follow-up.

Data of the other 18 patients were available to analysis. The mean duration of these 18 cases was 16.3 months (range, 8–30 months). All the fractures were united smoothly without second intervention. The mean modified Harris score was 85.1 (range, 53.2–96.8); excellent results were obtained in 7 cases (including case 9), good in 8, fair in 2, and poor in 1, with an excellent and good rate of 83.3%. According to the modified grading system of Merle d' Aubigne and Postel, the results were excellent in 2 cases, good in 15, and poor in 1, leading to an excellent and good rate of 94.0%. An avascular necrosis of the femoral head developed in 1 case (case 6), and heterotopic ossification occurred in 3 cases (2 cases of Brooker II and 1 case of Brooker I). Numbness in the anterolateral thigh skin was identified in 6 cases. No superficial or deep infections were found in all patients and no hardware failure happened (Table 4). A typical case was shown in Figures 8–10.

### Discussion

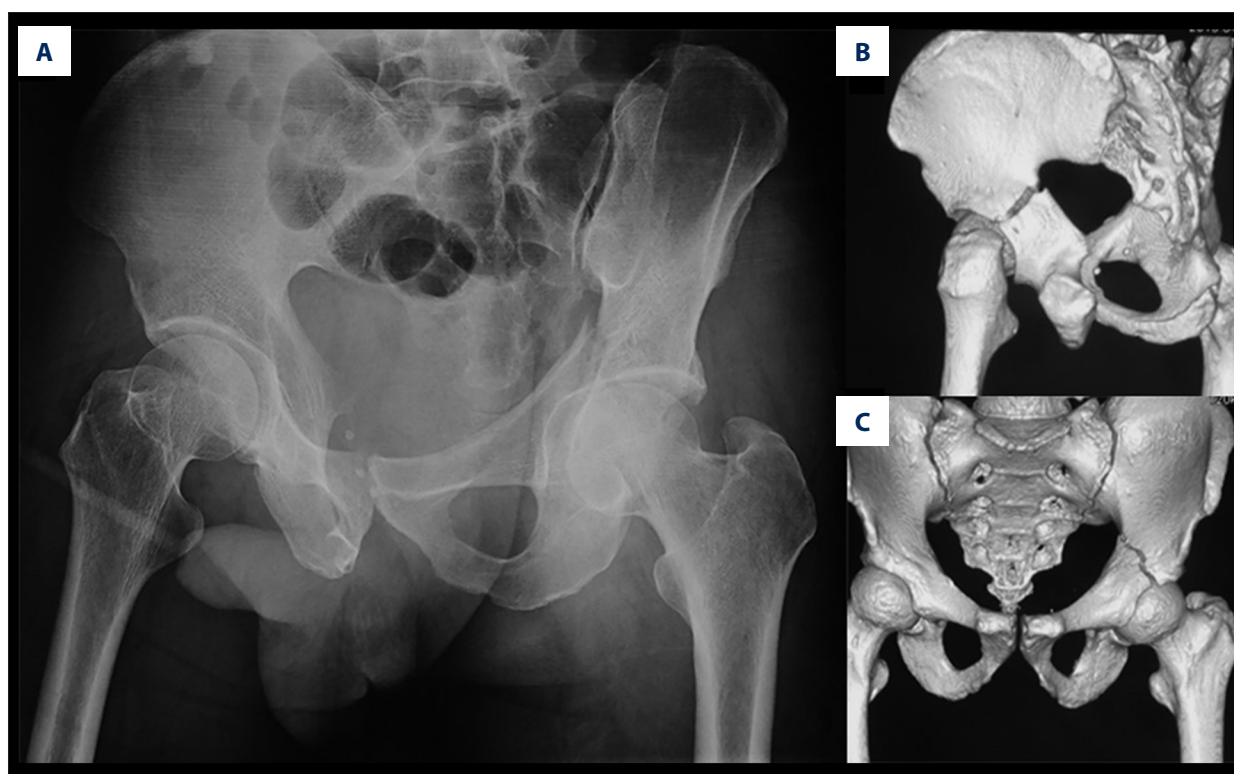
There is still controversy regarding the optimal approach to reduce and stabilize anterior column fracture of transverse with or without posterior wall fractures of the acetabulum.

It is obviously difficult to achieve anatomic reduction only through the K-L approach because of the weight of the lower extremity. Although anterior column fractures were satisfactorily exposed by a conventional ilioinguinal approach, extensive soft tissue dissection is unavoidable [15,16]. The modified Stoppa [17–20] and para-rectus approaches [21] are minimally invasive, but these approaches also have disadvantages of

**Table 4.** Surgical data and clinical outcomes.

Characteristic	Value
Surgical time (minutes)	198.1 (140–400)
Blood loss (ml)	938.1 (400–2500)
Anatomic reduction achieved	
Anterior column	20/21
Posterior column	21/21
Follow-up length (months)	16.3 (8–30)
Modified Harris Score	
Excellent	7
Good	8
Fair	2
Poor	1

Characteristic	Value
Merle d'Aubigne & Postel hip score	
Excellent	2
Good	15
Fair	0
Poor	1
Complications	
Avascular necrosis of the femoral head	1
Heterotopic ossification	3
Thigh numbness	6



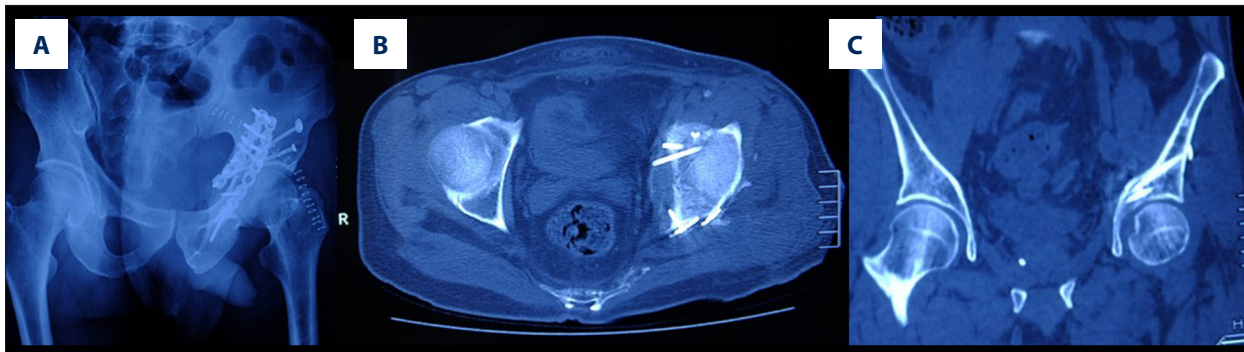
**Figure 8.** A 56-year-old patient (case 3) had a left transverse acetabular fracture, surgically treated by using a modified Smith-Petersen incision combined with K-L approach. **(A)** X-ray showed obvious displacement at the fracture site. **(B, C)** 3D reconstruction of the fracture.

insufficient exposure, as well as difficulty in reducing fractures and maintaining the reductions.

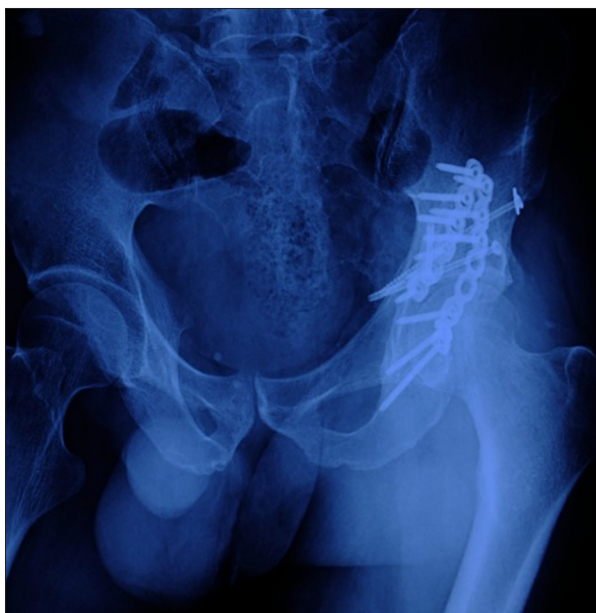In transverse with or without posterior wall fractures of the acetabulum, the anterior column is a simple pattern that needs to be anatomically reduced and firmly fixed. Reduction of the posterior

column and wall can only be done after satisfactory anatomic reduction of the anterior column fracture. In this case series, 21 cases of transverse with or without posterior wall fractures of the acetabulum were surgically treated, in which the posterior column and wall were treated through K-L approach and anatomic reduction was obtained, which is consistent with previous reports.





**Figure 9.** A postoperative X-ray (A) and CT scan (B, C) demonstrated an anatomic reduction of the fracture was obtained in case 3.



**Figure 10.** Complete union of the fracture was obtained 3 years after surgery in case 3.

In this study, the anterior column fractures were reduced and internally fixed through a modified Smith-Peterson approach. Anatomic reduction of the anterior column was achieved in 20 cases. One case was imperfectly reduced because of technical reasons.

All the anterior and posterior incisions achieved primary healing without superficial or deep infections. The 18 cases were followed up for at least 8 months. Although 1 case developed avascular necrosis of the femoral head, good hip function was regained among other patients, with a high Harris score (mean, >85) and excellent and good rate of 83.3%. According to the modified Merle d' Aubigne & Postel scoring system, among our 18 patients, excellent result was obtained in 2 cases, good in 15, and poor in 1, with an excellent and good rate of 94.0%. The difference between the 2 scoring systems may be because poor knee function resulted from a femoral shaft fracture in 1 case treated with retrograde intramedullary nailing and an

open knee dislocation associated with an anterior skin defect, which might have contributed to the lower Harris score. Zhang et al. reported the results of treating transverse with or without posterior wall fractures of the acetabulum by using a single K-L approach; among all 17 cases, 9 had anatomic reduction, 5 had imperfect reduction, and 3 had poor reduction [3]. Our results were superior to those reported by Zhang et al. No important tissue except for lateral femoral cutaneous nerve is injured in this approach. Only the inguinal ligament is dissected near its insertion to the ASIS. The iliopsoas is medially retracted; the fracture line of the anterior column laying in the anterior edge of acetabulum and the pelvic brim and anterior part of the quadrilateral plate become visible. Reduction can be done under direct vision. This approach has the advantages of visualization and minimal invasion. The disadvantage of this approach is that it might damage the anterolateral femoral cutaneous nerve, since 6 cases developed numbness in the anterolateral thigh.

The best fixation of the anterior column of pure transverse and associated posterior wall fractures is still in dispute. Two cannulated screws were recommended to stabilize the anterior column fracture, and the direction of the screws should be aligned with the anterior column [22,23]. Plating osteosynthesis was also reported [24]. In our series, anterior column fractures were fixed with cannulated screws in 14 cases, of which 6 cases were fixed with only 1 screw. The screws were placed vertical to the fracture line to compress the fragment and to prevent displacement. A short reconstruction plate was used in 7 cases in which screw fixation was inadequate, which is different from the traditional plate fixation [25]. In traditional plating osteosynthesis of anterior column fractures, a long, contoured reconstruction plate is placed on the pelvic brim from the superior pubic ramus to the ilium close to the sacroiliac joint, and a big incision is made to insert the plate. In 7 cases, a 4–5-hole plate was applied to fix the anterior column fractures and 2 screws were inserted in each end of the plate. Theoretically, this fixation may not be stable enough. Fortunately, no hardware failure or re-displacement occurred during the follow-up in these 7 cases, which might

be attributed to firm fixation of the posterior column prior to fixing the anterior column.

In this study, all posterior columns except 1 were fixed with 2 plates. At least 6 screws were inserted proximal and distal to the main fracture line. This strong fixation of the posterior column may somewhat increase anterior column stability, but its intrinsic mechanism needs further investigation. The limited number of patients and short follow-up time were the main weakness of our study. Further research with more cases and longer follow-up are needed.

## References:

- Moed BR, Reilly MC: Acetabulum fractures. In: Rockwood and Green's fractures in adults, Rockwood CA, Buchholz RW, Court-Brown CM et al., (eds.), Lippincott Williams & Wilkins, 2010; 1475–83
- Giordano V, do Amaral NP, Pallottino A et al: Operative treatment of transverse acetabular fractures: is it really necessary to fix both columns? *Int J Med Sci*, 2009; 6: 192–99
- Zhang L, Xu M, He C et al: [Effectiveness of acetabular transverse and posterior wall fractures by Kocher-Langenbeck approach.] *Zhongguo Xiu Fu Chong Jian Wai Ke Za Zhi*, 2010; 24: 1428–31 [in Chinese]
- Alexa O, Malanca RI, Puha B et al: Results of surgical treatment of acetabular fractures using Kocher-Langenbeck approach. *Chirurgia (Bucur)*, 2013; 108: 879–85
- Bogdan Y, Dwivedi S, Tornetta P 3<sup>rd</sup>: A surgical approach algorithm for transverse posterior wall fractures aids in reduction quality. *Clin Orthop Relat Res*, 2014; 472: 3338–44
- Collinge C, Archdeacon M, Sagi HC: Quality of radiographic reduction and perioperative complications for transverse acetabular fractures treated by the Kocher-Langenbeck approach: prone versus lateral position. *J Orthop Trauma*, 2011; 25: 538–42
- Negrin LL, Seligson D: The Kocher-Langenbeck approach: Differences in outcome of transverse acetabular fractures depending on the patient's position. *Eur J Trauma Emerg Surg*, 2010; 36: 369–74
- Masse A, Aprato A, Rollero L et al: Surgical dislocation technique for the treatment of acetabular fractures. *Clin Orthop Relat Res*, 2013; 471: 4056–64
- Li XG, Tang TS, Sun JY: Results after surgical treatment of transtectal transverse acetabular fractures. *Orthop Surg*, 2010; 2: 7–13
- Judet R, Judet J, Letournel E: Fractures of the acetabulum: Classification and surgical approaches for open reduction. Preliminary report. *J Bone Joint Surg Am*, 1964; 46: 1615–46
- Letournel E: Acetabulum fractures: Classification and management. *Clin Orthop Relat Res*, 1980; (151): 81–106
- Matta JM: Fractures of the acetabulum: Accuracy of reduction and clinical results in patients managed operatively within three weeks after the injury. *J Bone Joint Surg Am*, 1996; 78: 1632–45
- Brooker AF, Bowerman JW, Robinson RA, Riley LH Jr.: Ectopic ossification following total hip replacement. Incidence and a method of classification. *J Bone Joint Surg Am*, 1973; 55: 1629–32
- Ovre S, Sandvik L, Madsen JE, Roise O: Modification of the Harris Hip Score in acetabular fracture treatment. *Injury*, 2007; 38: 344–49
- Matta JM: Operative treatment of acetabular fractures through the ilioinguinal approach: A 10-year perspective. *J Orthop Trauma*, 2006; 20: 520–29
- Xue Z, Qin H, Ding H, An Z: A novel approach for treatment of acetabular fractures. *Med Sci Monit*, 2016; 22: 3680–88
- Isaacson MJ, Taylor BC, French BG, Poka A: Treatment of acetabulum fractures through the modified Stoppa approach: Strategies and outcomes. *Clin Orthop Relat Res*, 2014; 472: 3345–52
- Liu Y, Yang H, Li X et al: Newly modified Stoppa approach for acetabular fractures. *Int Orthop*, 2013; 37: 1347–53
- Sagi HC, Afsari A, Dziadosz D: The anterior intra-pelvic (modified rives-stoppa) approach for fixation of acetabular fractures. *J Orthop Trauma*, 2010; 24: 263–70
- Elmadag M, Guzel Y, Aksoy Y, Arazi M: Surgical treatment of displaced acetabular fractures using a modified stoppa approach. *Orthopedics*, 2016; 39: e340–45
- Farouk O, Kamal A, Badran M et al: Minimal invasive para-rectus approach for limited open reduction and percutaneous fixation of displaced acetabular fractures. *Injury*, 2014; 45: 995–99
- Chang JK, Gill SS, Zura RD et al: Comparative strength of three methods of fixation of transverse acetabular fractures. *Clin Orthop Relat Res*, 2001; (392): 433–41
- Zheng Z, Wu W, Yu X et al: Axial view of acetabular anterior column: A new X-ray projection of percutaneous screw placement. *Arch Orthop Trauma Surg*, 2015; 135: 187–92
- Yildirim AO, Alemdaroglu KB, Yuksel HY et al: Finite element analysis of the stability of transverse acetabular fractures in standing and sitting positions by different fixation options. *Injury*, 2015; 46(Suppl. 2): S29–35
- Shazar N, Brumback RJ, Novak VP, Belkoff SM: Biomechanical evaluation of transverse acetabular fracture fixation. *Clin Orthop Relat Res*, 1998; (352): 215–22

## Conclusions

This pilot study describes a sequential reduction technique in surgical treatment of transverse with or without posterior wall fractures of the acetabulum. Modified Smith-Petersen small incision might be a good choice in reduction and fixation of the anterior column because it possesses advantages of visualization and minimal invasion.

## Conflict of interest

The authors declare that they have no conflict of interest.