JCEM Case Reports, 2023, **1**, 1–6
https://doi.org/10.1210/jcemcr/luad084
Advance access publication 14 July 2023
Case Report

Vitamin D Hydroxylation-deficient Rickets Type 1A Misdiagnosed as Normocalcemic Primary Hyperparathyroidism

Pamela Rivero-García,[1,*] Juan José Aguilar-Lugo-Gerez,[2,*] Tamara N. Kimball,[1] and Alfredo Adolfo Reza-Albarrán[3]

[1]Department of Genetics, Instituto Nacional de Ciencias Médicas y Nutrición Salvador Zubirán. Vasco de Quiroga 15, Belisario Domínguez, Sección XVI, Delegación Tlalpan, 14080 Mexico City, Mexico
[2]Department of Internal Medicine, Instituto Nacional de Ciencias Médicas y Nutrición Salvador Zubirán. Vasco de Quiroga 15, Belisario Domínguez, Sección XVI, Delegación Tlalpan, 14080 Mexico City, Mexico
[3]Department of Endocrinology, Instituto Nacional de Ciencias Médicas y Nutrición Salvador Zubirán. Vasco de Quiroga 15, Belisario Domínguez, Sección XVI, Delegación Tlalpan, 14080 Mexico City, Mexico

Correspondence: Pamela Rivero-García, MD, Department of Genetics, Instituto Nacional de Ciencias Médicas y Nutrición "Salvador Zubirán", Vasco de Quiroga 15, Belisario Domínguez, Sección XVI, Delegación Tlalpan, 14080 Mexico City, Mexico. Email: pamela.riverog@incmnsz.mx.
*Contributed equally to this work as the first authors.

Abstract

Vitamin D hydroxylation-deficient rickets type 1A is an autosomal recessive disorder caused by pathogenic variants in *CYP27B1* gene, which encodes for 1α-hydroxylase, the enzyme responsible for the conversion of 25-OH vitamin D into its active form 1,25(OH)2 vitamin D. We report the case of a 3-year-old female Mexican patient with growth retardation and progressive bone deformity, whose laboratory studies showed 25-OH vitamin D deficiency, a normal serum calcium and an elevated intact parathyroid hormone level that remained high despite calcitriol, cholecalciferol, and calcium supplementation. ^{99m}Tc sestamibi gammagram showed findings suggestive of parathyroid hyperplasia. Bone histomorphometry showed an image consistent with hyperparathyroidism without findings of osteomalacia, so normocalcemic primary hyperparathyroidism was suspected and a subtotal parathyroidectomy was performed, with the patient developing postoperative hypoparathyroidism. When she arrived at our clinic at age 18 years, she showed calcium- and calcitriol-dependent hypocalcemia, with secondary hyperparathyroidism and low levels of 1,25(OH)2 vitamin D in the absence of a 25-OH vitamin D deficiency, reflecting a defect in 1α-hydroxylation. Molecular testing revealed compound heterozygous variants in *CYP27B1* gene. This is the first reported case of an inherited disorder of vitamin D metabolism that was diagnosed and surgically treated as primary hyperparathyroidism.

Key Words: vitamin D hydroxylation-deficient rickets type 1A, pseudovitamin-D-deficiency rickets, normocalcemic primary hyperparathyroidism, *CYP27B1*, rickets

Abbreviations: FGF23, fibroblast growth factor-23; iPTH, intact PTH; PHPT, primary hyperparathyroidism; PV, pathogenic variant.

Introduction

Any alteration that generates a sustained deficiency of calcium or phosphate can cause a defect in bone mineralization known as osteomalacia, characterized clinically by deformation of long bones resulting from mechanical stress on weak bone tissue. When mineral substrate deficiency occurs during growth, a different entity known as rickets occurs, in which patients present with growth retardation and widening of growth plates. During its activation, vitamin D undergoes 2 successive hydroxylation reactions. The first occurs in hepatocytes with the addition of the OH group at carbon 25, forming 25-OH vitamin D [25-(OH)D]. The second hydroxylation occurs at carbon 1 (ie, 1α-hydroxylation), in renal proximal tubule cells, producing the active form 1,25(OH) 2 vitamin D [1,25-(OH)2D]. It plays an important role in calcium and phosphate homeostasis by favoring their intestinal absorption [1].

Worldwide, the most common cause of rickets is nutritional deficiency of vitamin D. However, there are less frequent alterations that selectively affect the enzymatic reactions that vitamin D undergoes during its activation. The 1α-hydroxylation by the 1α-hydroxylase is under a tight positive control of PTH and a negative control of fibroblast growth factor-23 (FGF23), which control calcium and phosphate homeostasis, respectively. Pathogenic variants (PVs) with loss of function in *CYP27B1* gene that codes for 1α-hydroxylase cause a type of rickets with an autosomal recessive inheritance pattern that has been reported in approximately 200 cases, receiving different names, such as vitamin D hydroxylation-deficient rickets type 1A or pseudo-vitamin D deficiency rickets type 1A (OMIM #264700). Subjects with a functional enzyme may suffer from acquired inhibition, such as loss of the physiological stimulus of PTH (ie, hypoparathyroidism and pseudohypoparathyroidism) or an excess

Received: 13 February 2023. **Editorial Decision:** 20 June 2023. **Corrected and Typeset:** 14 July 2023
© The Author(s) 2023. Published by Oxford University Press on behalf of the Endocrine Society.
This is an Open Access article distributed under the terms of the Creative Commons Attribution-NonCommercial-NoDerivs licence (https://creativecommons.org/licenses/by-nc-nd/4.0/), which permits non-commercial reproduction and distribution of the work, in any medium, provided the original work is not altered or transformed in any way, and that the work is properly cited. For commercial re-use, please contact journals.permissions@oup.com

of FGF23-mediated inhibition (eg, chronic kidney disease, hypophosphatemic rickets, tumor-induced osteomalacia, fibrous dysplasia) [2]. Deficiency of 1α-hydroxylase causes hypocalcemia and hypophosphatemia, leading to rickets. In addition, hypocalcemia induces secondary hyperparathyroidism that increases bone turnover rate.

Case Presentation

We present the case of a 27-year-old Mexican woman, born to nonconsanguineous parents, with normal birth length and weight. She presented delayed motor development milestones and growth retardation with progressive large bone deformity and rotoscoliosis. At the age of 3 years, she was referred to a pediatric institution. Initial workup showed vitamin D deficiency, an elevated intact PTH (iPTH) with normal total serum calcium and phosphate, and a low 24-hour urinary calcium and phosphate excretion. Initial laboratory data are shown in Table 1. Vitamin D deficiency rickets was initially suspected, so oral supplementation of cholecalciferol, calcitriol, and calcium was started at doses of up to 3000 units, 0.25 µg and 1.5 g/d, respectively. During the following 2 years, calcium and phosphate levels remained within normal range at 2.15 to 2.32 and 0.87 to 1.03 mmol/L, respectively (8.6-9.3 and 2.7-3.2 mg/dL), but iPTH remained elevated at the range of 57.4 to 64.9 pmol/L (542-612 pg/mL) despite her 25-(OH)D levels rising to 92.35 nmol/L (37 ng/mL) (reference range, 74.99-246.6 nmol/L; 30-100 ng/mL). So further investigation was conducted, with a ^{99m}Tc sestamibi parathyroid gammagram performed at the age of 4 years, which showed accumulation of the radiotracer in lower poles of the thyroid gland, suggestive of parathyroid hyperplasia. At the age of 5 years, a bone biopsy of the iliac crest with double tetracycline labeling was conducted that demonstrated findings consistent with hyperparathyroidism without changes of osteomalacia (Table 2). Thus, the etiology of the persistent hyperparathyroidism was suspected to be primary hyperparathyroidism (PHPT). Subtotal parathyroidectomy was performed at 5 years, with removal of 3/4 parathyroid glands. Histopathological study reported clear cell hyperplasia. She developed hypocalcemia with an albumin-corrected serum calcium of 1.55 mmol/L (6.2 mg/dL) and an inappropriately normal iPTH of 5.51 pmol/L (52 pg/mL), consistent with postoperative hypoparathyroidism; therefore; oral calcium and calcitriol supplementation were increased up to 10 g/d and 0.50 µg/d, respectively. She was lost to follow-up by pediatric endocrinology. From the age 10 to 17 years, she required several bilateral osteotomies in both the tibia and femur, the placement of a titanium bar in the dorsolumbar spine, and costoplasty of ribs 11 and 12 because of friction with the iliac bone.

Table 1. Initial laboratory data of the Mexican patient with vitamin D hydroxylation-deficient rickets type 1A

Parameter	Results	Reference range
Intact parathyroid hormone (iPTH)	73.7 pmol/L (695 pg/mL)	0.85-7.05 pmol/L (8.0-66.5 pg/mL)
Serum calcium	2.32 mmol/L (9.3 mg/dL)	2.12-2.5 mmol/L (8.5-10.0 mg/dL)
Serum phosphate	1.03 mmol/L (3.2 mg/dL)	0.9-1.32 mmol/L (2.8-4.1 mg/dL)
24-h urinary calcium excretion	0.0045 mmol/d (0.18 mg/day)	6.25 mmol/d (<250 mg/d)
24-h urinary phosphate excretion	0.29 mmol/d (9.12 mg/d)	29 mmol/d (<900 mg/d)
25-OH vitamin D	24.96 nmol/L (10 ng/mL)	74.99-246.6 nmol/L (30-100 ng/mL)

Diagnostic Assessment

At age 18 years, she was evaluated at our institution. On physical examination, clear evidence of rickets was noted with a height of 1.15 m (*z*-score of −5.2 for height potential), significant scoliosis, long bones deformities (such as enlarged elbows and genu valgum), and enamel hypoplasia (Fig. 1). Bone radiographs were compatible with rickets, showing long bone bowing, scoliosis, and metaphyseal widening with diaphyseal cortical thickening (Fig. 2). Laboratory data revealed an elevated iPTH of 14.84 pmol/L (139.9 pg/mL), albumin-corrected serum calcium of 1.87 mmol/L (7.5 mg/dL), and free serum calcium of 0.83 mmol/L (3.33 mg/dL) (reference range, 1.07-1.3 mmol/L; 4.3-5.2 mg/dL), despite being supplemented with oral calcium and calcitriol. Serum phosphate was within the normal range at 1.42 mmol/L (4.4 mg/dL). The 24-hour urinary calcium and phosphate excretion were 0.45 and 13.5 mmol/d, respectively (18 and 420 mg/d, respectively). 25-(OH)D level was found sufficient at 95.85 nmol/L (38.4 ng/mL), but with a discordantly low 1,25-(OH)2D of 28.8 pmol/L (12 pg/mL) (reference range, 47.8-190.3 pmol/L; 19.9-79.3 pg/mL).

Treatment

Therefore, a clinical diagnosis of VDDR-1A was made, and the supplementation dose of calcium and calcitriol was gradually raised up to 18 g/day and 1 µg/day, respectively; with cost being a limitation to further increase the dose of calcitriol.

Outcome and Follow-up

Over the following years, serum phosphorus and albumin-corrected calcium remained in the range of 0.83 to 1.35 and 1.83 to 2.23 mmol/L, respectively (2.6-4.2 and 7.32-8.94 mg/dL).

Table 2. Histomorphometric values of iliac crest bone biopsy with double tetracycline labeling of the Mexican patient with vitamin D hydroxylation-deficient rickets type 1A

Parameter	Results	Reference ranges
Osteoid volume (O.Ar)	2.70%	3.19 ± 0.82
Mineralized volume (Md.Ar)	26.05%	21.03 ± 3.30
Fibrosis volume (Fb.Ar)	17.97%	0.32 ± 0.31
Osteoid thickness (O.Wi)	6.99 µm	5.80 ± 1.40
Osteoblast surface (Ob.S/BS)	7.21%	5.40 ± 1.30
Osteoclast surface (Oc.S/BS)	17.28%	1.40 ± 0.72
Eroded surface (ES/BS)	21.4%	14.8 ± 4.4
Osteoid apposition rate (OAR)	0.58 µm/d	1.20 ± 0.30
Mineral apposition rate (MAR)	1.83 µm/d	1.11 ± 0.17
Mineralization lag time (Mlt)	<1 day	12 ± 4
Bone formation rate (BFR/BS)	1570.89 $\mu m^3/\mu m^2/d$	1275 ± 168

Figure 1. Whole-body photographs of the Mexican patient with vitamin D hydroxylation-deficient rickets type 1A.

The 24-hour urinary calcium and phosphate excretion remained in the range of 0.45 to 1.67 and 7.3 to 17.2 mmol/d, respectively (18-67 and 228-533 mg/d). iPTH and bone turnover markers levels steadily decreased as shown in Fig. 3. Femoral neck bone mineral density *z*-score increased from −1.4 at 18 years to −0.1 at 27.

At the age of 26 years, next-generation sequencing of the *CYP27B1* gene was performed, finding 2 novel compound heterozygous variants. Extension studies were carried out in relatives (Fig. 4), with both parents being heterozygous carriers.

Discussion

Up to 50% of PHPT pediatric patients present with some degree of bone deformity [3]. However, only a few dozen cases of PHPT manifesting with a frankly rachitic phenotype have been reported [4]. The mechanism that generates rickets in those subjects remains unknown. It could be phosphopenic because of the phosphaturic effect of PTH. However, in the few reported PHPT patients with a rachitic phenotype in which 25-(OH)D level was measured, there was a concurrent vitamin D deficiency, which could possibly explain the rachitic phenotype [4]. It is even reasonable that the increased bone turnover rate induced by PHPT unmasks rickets in those who have concurrent vitamin D deficiency as a result of a greater demand for mineral substrate for the newly synthesized osteoid.

In addition, PHPT and vitamin D deficiency are mutually aggravating entities because PHPT can increase the consumption of 25-(OH)D [5], whereas vitamin D deficiency directly and indirectly stimulates PTH production, even in the autonomic overproduction state of PHPT. It has even been theorized that chronic vitamin D deficiency can trigger PHPT through parathyroid hyperplasia, after a sustained stimulus for PTH production [6].

At the time of initial diagnosis, the current case presented with normocalcemic hyperparathyroidism in the presence of vitamin D deficiency. When one encounters a similar situation, it is essential to perform a trial of calcium and cholecalciferol supplementation. The development of hypercalcemia unmasks a case of PHPT, whereas the persistence of normocalcemia with normalization of iPTH levels suggests vitamin D deficiency. In the rare case that normocalcemic hyperparathyroidism persists, a disorder of vitamin D metabolism should be suspected. In this case, calcitriol was erroneously started together with cholecalciferol, and the fact that the patient did not develop hypercalcemia or normalize iPTH did not lead to the suspicion of a vitamin D metabolism disorder, as it should have. Interestingly, histomorphometry showed an image consistent with hyperparathyroidism without findings compatible with osteomalacia, which unfortunately made the treating team suspect PHPT. Those findings, in the presence of a persistently elevated iPTH, suggest that the supplemental dose of calcitriol at that time (ie, 0.25 μg/d) was sufficient to mineralize bone and reverse the histomorphometric changes of osteomalacia, but was not high enough to suppress PTH secretion.

After the wrongfully indicated subtotal parathyroidectomy, the patient developed hypocalcemia, which was originally attributable to postsurgical hypoparathyroidism. The calcitriol dose she then received (ie, 0.50 μg/d), although higher than that which reversed the histomorphometric changes of osteomalacia, somehow failed to bring her up to her height potential. This suggests that the supplemental dose she received was suboptimal because as Edouard et al showed, when appropriate treatment of VDDR-1A is instituted before closure of growth plates, rickets changes are usually reversed and height potential is generally achieved [7].

During the years following the subtotal parathyroidectomy, the residual parathyroid tissue probably underwent reactive hyperplasia that eventually reverted to the state of secondary hyperparathyroidism. However, at this time, the degree of hyperparathyroidism failed to compensate for the

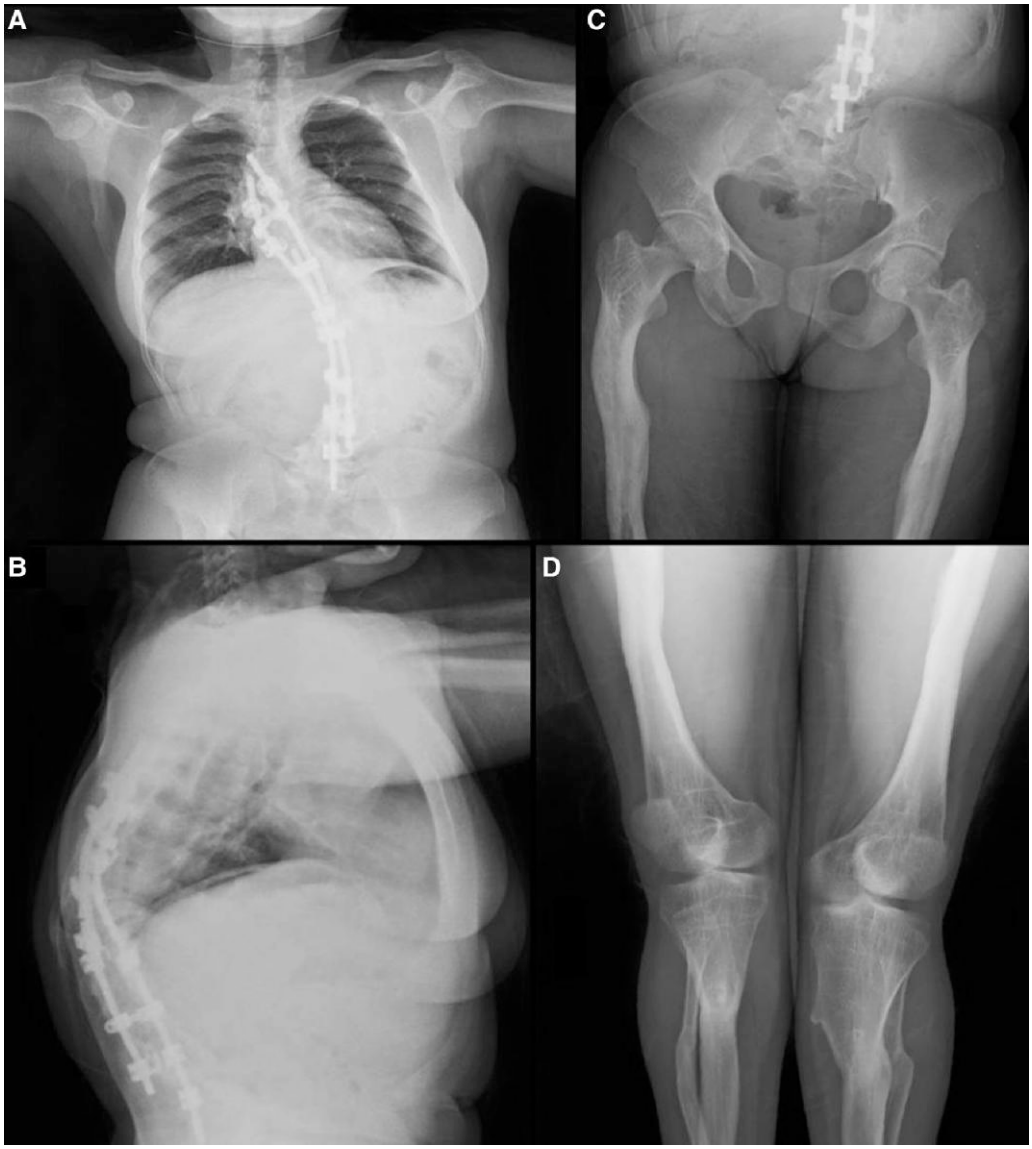

Figure 2. Plain radiography findings of the Mexican patient with vitamin D hydroxylation-deficient rickets type 1A. (A, B) Thoracolumbar scoliosis with convexity to the left, with compensatory thoracic scoliosis with convexity to the right. Transpedicular bars of T4-L5, with loss of continuity of the left lateral bar at the level of T12. Significant decrease in multilevel intervertebral spaces. Facet joints with sclerosis. (C) Pelvis with lateralization to the left. Femur with bowing and metaphyseal widening, as well as diaphyseal cortical thickening. (D) Metaepiphyseal widening at the level of bilateral femoral condyles. Bowing of the tibia and fibula. Decreased tibiofemoral spaces, predominantly in bilateral medial compartments. Decreased left patellofemoral joint space.

enzymatic defect, leaving her with calcium- and calcitriol-dependent hypocalcemia, unmasking the underlying disorder in vitamin D metabolism.

When the patient was evaluated in our clinic, the rachitic phenotype with enamel hypoplasia pointed to a calcipenic origin of the rickets because enamel mineralization is more dependent on calcium availability and is usually absent in hypophosphatemic rickets [8]. During the workup, iPTH was found to be elevated, indicating a state of secondary hyperparathyroidism or pseudohypoparathyroidism. Hypocalcemia was found to be secondary to impaired intestinal absorption and not to renal losses because a 24-hour urine collection did not reveal hypercalciuria. Low levels of 1,25-(OH)2D with normal 25-(OH)D confirmed a defect in 1α-hydroxylation. The absence of hyperphosphatemia ruled out pseudohypoparathyroidism; however, the predominance of hypocalcemia over hypophosphatemia as well as the aforementioned presence of enamel hypoplasia suggested VDDR-1A over rickets mediated by FGF23 overproduction. Finally, *CYP27B1* gene sequencing confirmed the diagnosis of VDDR-1A.

Previous studies have shown that VDDR-1A phenotype is inversely correlated with residual 1α-hydroxylase activity [2] but not with specific biochemical parameters such as 1,25-(OH) 2D, suggesting that other enzymatic pathways may play a role [9]. The residual enzymatic activity of our patients is unknown because it could not be measured, and both variants were novel. The first, c.361C > T (p.Gln121*), is a nonsense variant that causes premature termination, resulting in a shorter nonfunctional protein. It is classified as a PV according to the American College of Medical Genetics and Genomics criteria. Computational tools predict that c.1137-6A > G splicing variant has a deleterious effect on the protein. Although initially classified as a variant of uncertain significance, with the information provided by this case it was reclassified as a likely PV.

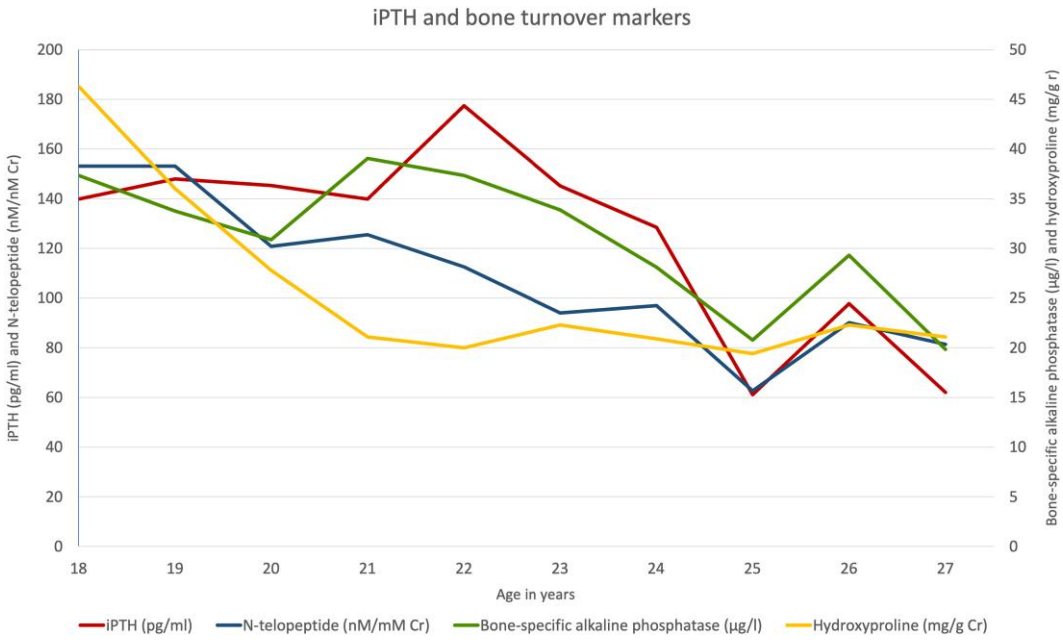

Figure 3. Levels of intact parathyroid hormone (iPTH) and bone turnover markers of the Mexican patient with vitamin-D hydroxylation-deficient rickets type 1A. Levels steadily decreased after the diagnosis was made and the supplementation dose of calcium and calcitriol was raised up to 18 g/d and 1 µg/d, respectively. Reference ranges: iPTH (12-88 pg/mL), N-telopeptide (5-65 nM/mM Cr), bone-specific alkaline phosphatase (8-14.3 µg/dL), hydroxyproline (6-25 mg/g Cr).

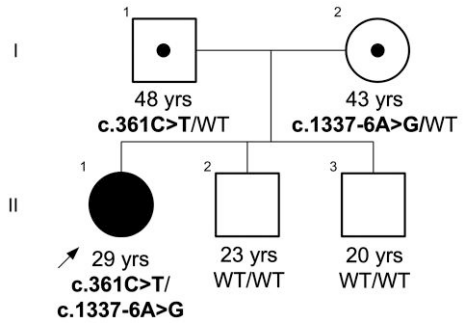

Figure 4. Family tree of the Mexican patient with vitamin D hydroxylation-deficient rickets type 1A. The proband was the only case in the family. Both parents were heterozygous carriers of the disease and both siblings were wild-type homozygous. The arrow refers to the proband, males are shown in squares, and females in circles. Dots indicate carriers and fill indicates the presence of vitamin-D hydroxylation-deficient rickets type 1A. WT: wild-type.

This variant is likely responsible for any residual activity of the enzyme in our patient.

There are multiple reported cases of normocalcemic PHPT incorrectly diagnosed as rickets because of vitamin D deficiency [10]. However, to our knowledge, this is the first reported case of an inherited vitamin D metabolism disorder that was diagnosed and surgically managed as normocalcemic PHPT.

The fact that our patient was misdiagnosed prevented her from receiving an adequate supplementary dose of calcitriol to reverse the rachitic phenotype before closure of growth plates, leaving her with a greater burden of disease that included the need for several orthopedic surgeries. In addition, that she was mistreated with a subtotal parathyroidectomy also left her with a more challenging long-term management because of the decreased stimulatory effect of PTH on renal tubular calcium reabsorption. This leaves her at increased risk of urolithiasis and nephrocalcinosis because she is expected to excrete more calcium at the same serum calcium concentration than patients with 1α-hydroxylase deficiency with a preserved parathyroid function.

Learning Points

- If appropriate treatment of VDDR-1A with calcium and calcitriol supplementation is instituted before closure of growth plates, rickets changes are usually reversed, and height potential is generally achieved.
- Biallelic PV in the gene encoding 1α-hydroxylase causes VDDR-1A in which vitamin D cannot be activated, resulting in rickets.
- Biochemical diagnosis is based on demonstrating hypocalcemia, hypophosphatemia, and secondary hyperparathyroidism, together with low 1,25-(OH)2D, without a justifying 25-(OH)D deficiency.
- In patients presenting with high iPTH, low 25-(OH)D, and normal serum calcium, a trial of calcium and vitamin D supplementation is essential to distinguish normocalcemic hyperparathyroidism from vitamin D deficiency or a defect in its metabolism.

Acknowledgments

The authors thank Dr. Luis Chavez, who contributed to the development of this case report.

Contributors

P.R. and J.J.A. wrote the manuscript; T.K. contributed to case detection and checked and edited the manuscript; A.A.R. was involved in management of this patient and manuscript submission; and all authors read and agreed to the final version of the manuscript.

Funding

No public or commercial funding.

Disclosures

The authors have nothing to disclose.

Informed Patient Consent for Publication

Signed informed consent obtained directly from the patient.

Data Availability Statement

Some or all datasets generated during and/or analyzed during the current study are not publicly available but are available from the corresponding author on reasonable request.

References

1. Sabbagh Y, Carpenter TO, Demay MB. Hypophosphatemia leads to rickets by impairing caspase-mediated apoptosis of hypertrophic chondrocytes. *Proc Natl Acad Sci U S A*. 2005;102(27):9637-9642.
2. Kaygusuz SB, Alavanda C, Kirkgoz T, *et al*. Does genotype-phenotype correlation exist in vitamin-D-dependent rickets type IA: report of 13 new cases and review of the literature. *Calcif Tissue Int*. 2021;108(5):576-586.
3. Boro H, Khatiwada S, Alam S, *et al*. The spectrum of manifestations of primary hyperparathyroidism in children and adolescents. *Pediatr Endocrinol Diabetes Metab*. 2022;28(3):178-187.
4. Pitukcheewanont P, Numbenjapon N, Costin G. Ectopic thymic parathyroid adenoma and vitamin-D deficiency rickets: a 5-year-follow-up case report and review of literature. *Bone*. 2008;42(4):819-824.
5. Vélayoudom-Céphise FL, Wémeau JL. Primary hyperparathyroidism and vitamin-D deficiency. *Ann Endocrinol (Paris)*. 2015;76(2):153-162.
6. Lumb GA, Stanbury SW. Parathyroid function in human vitamin-D deficiency and vitamin-D deficiency in primary hyperparathyroidism. *Am J Med*. 1974;56(6):833-839.
7. Edouard T, Alos N, Chabot G, Roughley P, Glorieux FH, Rauch F. Short- and long-term outcome of patients with pseudo-vitamin-D deficiency rickets treated with calcitriol. *J Clin Endocrinol Metab*. 2011;96(1):82-89.
8. Gjørup H, Beck-Nielsen SS, Haubek D. Craniofacial and dental characteristics of patients with vitamin-D-dependent rickets type 1A compared to controls and patients with X-linked hypophosphatemia. *Clin Oral Investig*. 2018;22(2):745-755.
9. Fortin CA, Girard L, Bonenfant C, *et al*. Benefits of newborn screening for vitamin-D-dependant rickets type 1A in a founder population. *Front Endocrinol (Lausanne)*. 2022;13:887371.
10. Dutta D, Kumar M, Das RN, *et al*. Primary hyperparathyroidism masquerading as rickets: diagnostic challenge and treatment outcomes. *J Clin Res Pediatr Endocrinol*. 2013;5(4):266-269.