

# Subcutaneous tissue-sparing dorsal slit with new marking technique

## A novel circumcision method

Zhao-Long Jiang, MM<sup>a</sup>, Cheng-Wen Sun, MM<sup>b</sup>, Jian Sun, BD<sup>b</sup>, Gao-Feng Shi, PhD<sup>a</sup>, Hu Li, MM<sup>a,\*</sup>

### Abstract

Circumcision is a very common surgical procedure that is performed for medical and traditional purposes in the world. However, many technical of circumcision is needed to improve. Thus, this study introduced a novel method of circumcision that is a refined version of the sleeve technique, termed subcutaneous tissue sparing dorsal slit with new marking, and evaluated the safety and efficacy of this novel method of circumcision.

The randomized clinical trial included 93 adult patients with redundant foreskin or phimosis treated from May 2015 to March 2017. Patients were randomly divided into the novel circumcision method (n=45) or conventional dissection (n=48). The groups were compared regarding rates of intraoperative hemorrhage, operative time, pain, healing, satisfaction with penis appearance, and relevant adverse events.

No patient suffered any obvious complication. Compared with the patients given conventional dissection, the patients who underwent the new surgical device experienced significantly less wound healing time, scar width, and recovery time ( $P < .05$ ). The new method resulted in greater intraoperative bleeding volume and surgical time ( $P < .05$ ). The rate of satisfaction with appearance of the penis was significantly higher in the group treated with the novel technique. In addition, the cost of surgery of these 2 methods was similar.

Based on the above research, we found that subcutaneous tissue-sparing dorsal slit with new marking technique was an effective and safe procedure for circumcision, and deserved further application in clinical practice.

**Keywords:** adult circumcision, circumcision, phimosis, redundant foreskin

### 1. Introduction

Circumcision is a very common surgical procedure that is performed for medical and traditional purposes, worldwide.<sup>[1-3]</sup> The protective effect of circumcision against invasive penile cancer is well documented.<sup>[3,4]</sup> Adult circumcisions are usually performed for medical indications, the commonest being phimosis.<sup>[5]</sup> Globally, the rate of male circumcision is 30% to 34% and is especially common in Western countries. In China, circumcision has recently increased with 44.6% of patients

accepting the procedure. However, compared with other populations, the practice remains relatively low.<sup>[6]</sup>

Reports regarding complications of circumcision have varied widely, from <1% to 55%.<sup>[5-7]</sup> Circumcision reduces the risk of sexually transmitted disease and cancer susceptibility and improves general health.<sup>[5,7,8]</sup> However, patients and practitioners are often concerned about rare complications, such as excessive intra- and post-operative wound bleeding, hematoma, infection, secondary phimosis, epidermal inclusion cysts, and urinary dysfunction.<sup>[7-10]</sup> Thus, there is a need for more effective and safer methods of circumcision to avoid these complications.

Different techniques and modifications of circumcision reportedly reduce the risk of complications.<sup>[8,11,12]</sup> Herein, we describe a novel technique of circumcision, which retains more prepuce while sparing the frenulum.

In clinical practice, we often use methylene blue or a marking pen to indicate the incision line. However, the incision line often appears diffuse or disappears, resulting in excessive or insufficient excision. During conventional dissection, even severe postoperative asymmetry can result. Here, we are the first to recommend the use of silk thread to stitch the fixed-point mark, which is clear and firm. Therefore, surgeons with little experience are less likely to make mistakes.

We have termed our novel circumcision method as subcutaneous tissue-sparing dorsal slit with a new marking technique. This is a safe surgical approach, designed to reduce postoperative blood loss and complications, and shorten the wound healing time.<sup>[11,12]</sup>

This study evaluated the clinical efficacy, safety, and benefits of circumcision via subcutaneous tissue-sparing dorsal slit with the

Editor: Massimo Tusconi.

Z-LJ and C-WS contributed equally to this work.

The Institutional Review Board of Affiliated Hospital of Jiangnan University approved this randomized, multicenter clinical study, and all patients provided written consent.

The authors have no conflicts of interest to disclose.

<sup>a</sup> Department of Plastic Surgery, <sup>b</sup> Department of Urology, Affiliated Hospital of Jiangnan University, Wuxi, China.

\* Correspondence: Hu Li, Department of Plastic Surgery, Affiliated Hospital of Jiangnan University, Wuxi, 214062, China (e-mail: jxzl2008@126.com).

Copyright © 2019 the Author(s). Published by Wolters Kluwer Health, Inc. This is an open access article distributed under the terms of the Creative Commons Attribution-Non Commercial-No Derivatives License 4.0 (CCBY-NC-ND), where it is permissible to download and share the work provided it is properly cited. The work cannot be changed in any way or used commercially without permission from the journal.

Medicine (2019) 98:16(e15322)

Received: 27 December 2018 / Received in final form: 6 March 2019 /

Accepted: 25 March 2019

<http://dx.doi.org/10.1097/MD.00000000000015322>

**Table 1**  
**Clinical data of individual patients included in the study.**

	A	B
Subjects, n	45	48
Age, yr	31.96 ± 6.502	30.4 ± 7.825
Redundant foreskin, n (%)	42 (93.3%)	43 (89.6%)
Phimosis, n (%)	3 (6.7%)	5 (10.4%)
Intraoperative bleeding volume, mL	12.53 ± 2.7	5.96 ± 1.3*
Surgical time, min	58.93 ± 7.2	44.52 ± 7.6*
Wound healing time, d	12.4 ± 2	20.1 ± 5.4*
Scar width, mm	1.44 ± 0.624	2.13 ± 0.89*
Recovery time, d	7.1 ± 1.9	10.8 ± 3.1*
Surgery cost, USD	185.94 ± 9.3	185.47 ± 17.5
Satisfaction with penis appearance	88.89%	58.33%

\*Significant difference cf. Group A ( $P < .05$ ).

new marking technique, relative to that of conventional dissection, in a randomized, multi-center clinical trial.

**2. Methods**

The Institutional Review Board of Affiliated Hospital of Jiangnan University approved this randomized, multicenter clinical study, and all patients provided written consent.

**2.1. Clinical data**

From May 2015 to March 2017, 93 adult patients underwent circumcision to treat redundant foreskin or phimosis and were included in this study as research subjects (Table 1). Of the 93 patients, 45 were randomly selected to receive the novel circumcision method (i.e., subcutaneous tissue-sparing dorsal slit with new marking technique; Group A), and the

other 48 patients were given conventional dissection circumcision (Group B).

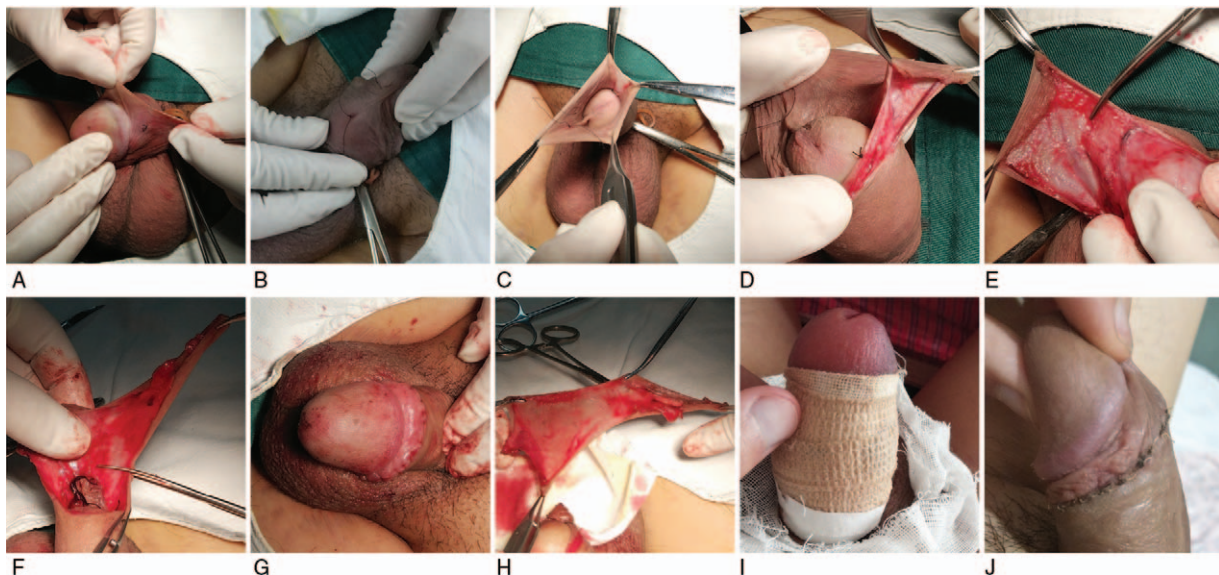
All the selected patients (or guardians of minors) provided informed consent for frenulum preservation before the procedure, which was performed in accordance with the standards prescribed by the Institutional Ethics committee. The 2 groups were compared regarding postoperative blood loss, operative time, pain, healing, satisfaction with penis appearance and relevant adverse events. The intraoperative blood loss was calculated as follows: a completely soaked 5 cm × 5 cm piece of gauze has an average carrying capacity of 3.25 mL of blood. In addition, all operations were performed by the same doctor.

**2.2. Subcutaneous tissue-sparing dorsal slit with new marking technique**

The patient was placed supine and given local anesthesia (Fig. 1). The 2 layers (internal and external plates) were cut off separately so that the adhering blood vessels could be stripped off. The wound is small, and the swelling is fast and the pain is slight after operation. The approach involved resection of the redundant foreskin using scalpel or scissors. The inner mucosal layer was trimmed to 3 mm above the coronal region. After meticulous hemostasis using unipolar electrocautery, the edges of the skin were approximated using absorbable sutures. Notably, the cost of the device studied is also expected to be relatively low, but it is not yet in commercial production.

**2.3. Statistical analysis**

Student *t* test was applied for analyzing continuous variables. The chi-squared test was used for categorical variables. Statistical analyses were performed using SPSS 22.0 software. Most data are



**Figure 1.** Operative procedure with lateral approach. (A) Fixed point of dorsal circumcision. (B) Frenulum side circumcision of private line fixed-point. (C) Incision of the dorsal circumcision plate and the separation and avoidance of posterior lateral circumcision plate. (D) Separation of gaps between internal and external plates and the incision of the circumcision plate. (E) Incision of the inner plate until the lace side and dorsal side. (F) Separation the surface vessels from the outer surface of the foreskin, and removing the outer plate of the prepuce. (G) Sew up with 6-0 absorbable lines. (H) Unwrapping the circumcision tissue. (I) Elastic bandage pressure bandage area. (J) One week after the operation.

**Table 2**  
**Relevant complications in these 2 groups.**

	A (n=45)	B (n=48)	P values
Hematoma	0	4	.067
Infection	2	8	.056
Wound dehiscence	0	1	.516
Reoperation	0	1	.516

reported as mean and range.  $P < .05$  was considered statistically significant.

### 3. Results

Each patient in the study population underwent a successful operation with a satisfactory prognosis (Table 1). During a mean postoperative follow-up of 10 months (6–12 months), no serious complications were found, and no patient experienced severe pain or dysfunction. Compared with the patients given conventional dissection, the patients who underwent the new technique experienced significantly less wound healing time, scar width, and recovery time, while the intraoperative bleeding volume, surgical time, and the rate of satisfaction with appearance of the penis was significantly higher. The cost of surgery to the 2 groups was similar. Compared with the routine operation, significant differences were detected about the above data in the new technique (all  $P < .05$ ).

Among the patients, only 1 suffered intraoperative incision errhysis (Table 2). Postoperative complications were few but included hematoma, wound dehiscence, incision errhysis, and edema. One patient experienced low-grade fever with postoperative incisional pain in Group A and recovered without further intervention within 1 week. In Group B, we found that 3 patients had postoperative incision errhysis, 2 patients had hematoma, and 1 patient had wound dehiscence.

### 4. Discussion

The present study shows that circumcision using a novel, disposable device that is a refined version of the sleeve technique, termed subcutaneous tissue-sparing dorsal slit with new marking, provided equivalent outcomes with the current conventional dissection technique. Notably, circumcision using subcutaneous tissue-sparing dorsal slit with new marking technique resulted in reduced postoperative bleeding and incidence of complications, compared with the conventional dissection technique. Therefore, these observations indicate that this novel technique may be a valid alternative for adult circumcision.

Circumcision has been widely used to limit the spread of sexually transmitted diseases such as human immunodeficiency virus in Africa and Western countries.<sup>[5,13,14]</sup> It may also limit other reproductive tract diseases, including urinary infection and penile cancer.<sup>[15]</sup> Many adult patients, particularly in China where circumcision is less well accepted, are concerned with the potential drawbacks of conventional circumcision, including repeat circumcision, surgical complications, impairment of sexual abilities, and cost.<sup>[6–10]</sup> The recent development of minimally invasive and disposable instruments for circumcision has increased patients' acceptance of circumcision.<sup>[16]</sup> In addition, this new technology, like traditional circumcision, is suitable for patients with phimosis and prepuce stenosis without

requiring additional surgery.<sup>[16]</sup> These benefits are highly desirable.

The method that we introduce here, circumcision by subcutaneous tissue-sparing dorsal slit, was developed to prevent intraoperative bleeding effectively by separating the superficial dorsal veins and vessels between the inner and outer ring before transection of the foreskin. This allows removal of the foreskin surgically or by natural atrophy.<sup>[17]</sup> As a result, there is very little postoperative hematoma, and infection, pain, and other risks associated with adult circumcision are limited, and the risk of uncomfortable and unpleasant sexual intercourse is reduced.<sup>[18]</sup> In comparison, during conventional circumcision surgery, the superficial dorsal vein of the penis is directly ligated and hemostasis is achieved with sutures, causing a relatively large amount of intraoperative bleeding.<sup>[19,20]</sup>

With our method, most of the subcutaneous blood vessels are retained; some of the blood vessels are too circuitous to cut and ligate under direct vision during the operation. Therefore, there is little bleeding throughout the process and the possibility of postoperative complications such as hematoma. As in sleeve circumcision, our method only excises the internal and external plates of the penis and preserves most of the blood vessels and connective tissue, which ensures less postoperative bleeding, less injury, faster healing, and refractory intractable lymphedema.

Our technique has several advantages compared with sleeve circumcision. First, for patients with phimosis or prepuce stenosis, circumcision should be performed longitudinally.<sup>[21]</sup> Second, the patient who is undergoing circumcision under local anesthetic is at a state of anxiety, and thus there is a variable degree of penile retraction.<sup>[22]</sup> Excessive excision of the foreskin at circumcision is a common surgical error, and results in a spectrum of problems ranging from pain at the suture line on erection to concealed penis syndrome.<sup>[23]</sup> In the present method, the foreskin is pulled through the blood vessel forceps, and the position of the silk thread is fixed and not affected. In addition, sleeve circumcision only excises the internal and external plates of the circumcision, and the excess subcutaneous tissue may result in a thick ring and a bloated shape after the circumcision. Thus, our technique can remove some subcutaneous tissue and achieve a better appearance.

In this randomized, multicenter clinical trial, we randomly assigned the 93 patients to receive either the novel circumcision method (Group A;  $n=45$ ) or conventional circumcision (Group B;  $n=48$ ). The novel circumcision method achieved satisfactory results, with obvious safety and efficacy, less intraoperative bleeding volume and significantly less pain. While the cost of surgery was comparable between these groups, longer operative time and more intraoperative blood loss were associated with the novel technique compared with the conventional. In addition, more intraoperative blood loss in Group A might be associated with intraoperative complete debonding of soft tissue, longer operative time and intraoperative relax after the tourniquet recompression. Most importantly, we found that this operative method could get satisfactory field of vision, smooth operation, and obvious safety and effects in the present study.

The large sample size of the present study helped ensured sufficient statistical evidence to confirm the safety and efficacy of this novel circumcision method, relative to the conventional technique. However, the patients included in this study were mainly Asian, and no other populations have been tested. Thus, the influence of ethnicity has not been considered. Well-designed studies with large sample populations should be conducted to

validate this novel circumcision technology with regard to diagnosis and treatment. In addition, the ability to fine isolate tissue was required in this study, which resulted into increasing the intraoperative bleeding volume and surgical time, compared with the traditional surgical method. Besides, the results of this study were based on unadjusted estimates, so we should take into consideration the effect of multiple confounders such as surgical equipment, the proficiency of the surgeon, different operation modes, and so on. Hence, to improve reliability of the study, more studies should need to explore the strategy of diagnosis and treatment of redundant foreskin or phimosis in the subsequent years.

## 5. Conclusion

Subcutaneous tissue-sparing dorsal slit with a new marking technique is a novel circumcision method that is effective and safe and deserves further application.

## Author contributions

Zhao-Long Jiang and Hu Li designed and performed most of the investigation, data analysis and wrote the manuscript; Gao-Feng Shi took and processed the intraoperative pictures; Cheng-Wen Sun and Jian Sun contributed to interpretation of the data and analyses. All of the authors have read and approved the manuscript.

**Conceptualization:** Gao-Feng Shi.

**Data curation:** Cheng-Wen Sun, Hu Li.

**Formal analysis:** Zhao-Long Jiang, Cheng-Wen Sun, Jian Sun, Hu Li.

**Funding acquisition:** Zhao-Long Jiang, Cheng-Wen Sun, Jian Sun, Gao-Feng Shi, Hu Li.

**Investigation:** Zhao-Long Jiang, Cheng-Wen Sun, Jian Sun, Gao-Feng Shi, Hu Li.

**Methodology:** Jian Sun, Gao-Feng Shi, Hu Li.

## References

- [1] Martin A, Nataraja RM, Kimber C, et al. The use of tissue glue for circumcision in children: systematic review and meta-analysis. *Urology* 2018;115:21–8.
- [2] Di Pietro ML, Teleman AA, Di Pietro ML, et al. Preventive newborn male circumcision: what is the child's best interest. *Cuad Bioet* 2017;28:303–16.
- [3] Brook I. Infectious complications of circumcision and their prevention. *Eur Urol Focus* 2016;2:453–9.
- [4] Earp BD. Do the benefits of male circumcision outweigh the risks? A critique of the proposed CDC guidelines. *Front Pediatr* 2015;3:18–24.
- [5] Lawal TA, Olapade-Olaopa EO. Circumcision and its effects in Africa. *Transl Androl Urol* 2017;6:149–57.
- [6] Zhou B, Ning C, McCann CD, et al. Impact of educational interventions on acceptance and uptake of male circumcision in the general population of Western China: a multicenter cohort study. *Sci Rep* 2017;7:14931–9.
- [7] Gold G, Young S, O'Brien M, et al. Complications following circumcision: presentations to the emergency department. *J Paediatr Child Health* 2015;51:1158–63.
- [8] Darby R. Risks, benefits, complications and harms: neglected factors in the current debate on non-therapeutic circumcision. *Kennedy Inst Ethics J* 2015;25:1–34.
- [9] Gurney JM, Jaszczak N, Perkins JH, et al. Complications of male circumcision treated at a military hospital in Afghanistan. *US Army Med Dep J* 2013;93–7.
- [10] Hutcheson JC. Male neonatal circumcision: indications, controversies and complications. *Urol Clin North Am* 2004;31:461–7.
- [11] Abdulwahab-Ahmed A, Mungadi IA. Techniques of male circumcision. *J Surg Tech Case Rep* 2013;5:1–7.
- [12] Hargreave T. Male circumcision: towards a World Health Organisation normative practice in resource limited settings. *Asian J Androl* 2010;12:628–38.
- [13] Bell K. HIV prevention: making male circumcision the 'right' tool for the job. *Glob Public Health* 2015;10:552–72.
- [14] Sharma SC, Raison N, Khan S, et al. Male circumcision for the prevention of human immunodeficiency virus (HIV) acquisition: a meta-analysis. *BJU Int* 2018;121:515–26.
- [15] Fathalla MF. Reproductive health: a global overview. *Ann N Y Acad Sci* 1991;626:1–0.
- [16] Huo ZC, Liu G, Li XY, et al. Use of a disposable circumcision suture device versus conventional circumcision: a systematic review and meta-analysis. *Asian J Androl* 2017;19:362–7.
- [17] Shenoy SP, Marla PK, Sharma P, et al. Frenulum sparing circumcision: step-by-step approach of a novel technique. *J Clin Diagn Res* 2015;9:PC01–3.
- [18] Hall KS, Kusunoki Y, Gatny H, et al. Stress symptoms and frequency of sexual intercourse among young women. *J Sex Med* 2014;11:1982–90.
- [19] El-Kassaby AW, Osman T, Abdel-Aal A, et al. Dynamic three-dimensional spiral computed tomographic cysto-urethrography: a novel technique for evaluating post-traumatic posterior urethral defects. *BJU Int* 2003;92:993–6.
- [20] Rajaian S, Rajadoss MP, Nayak S, et al. Traumatic rectourethral fistula repair: a potential application of porcine small intestinal submucosa. *Indian J Urol* 2013;29:148–50.
- [21] Pillai RG, Al Naieb Z. Plastibell circumcision supported by a calcium-alginate fibre dressing to reduce bleeding. *Arab J Urol* 2015;13:179–81.
- [22] Chang SF, Hung CH, Hsu YY, et al. The effectiveness of health education on maternal anxiety, circumcision knowledge, and nursing hours: a Quasi-experimental study. *J Nurs Res* 2017;25:296–303.
- [23] Yuan Y, Zhang Z, Cui W, et al. Clinical investigation of a novel surgical device for circumcision. *J Urol* 2014;191:1411–5.