

## Surgical Technique

## Single-Sided Reciprocating Saw for Tibial Component Removal During Revision Total Knee Arthroplasty

Rohan Gopinath, MD <sup>a</sup>, Scott Koenig, MD <sup>a</sup>, Aaron Johnson, MD <sup>a</sup>, Farshad Adib, MD <sup>a</sup>, Geoffrey Van Flandern, MD <sup>b</sup>, Sumon Nandi, MD, MBA <sup>a,\*</sup>

<sup>a</sup> Department of Orthopaedics, University of Maryland Medical Center, Baltimore, MD, USA

<sup>b</sup> Department of Orthopedic Surgery, New England Baptist Hospital, Boston, MA, USA

## ARTICLE INFO

## Article history:

Received 20 July 2020

Received in revised form

12 January 2021

Accepted 26 January 2021

Available online xxx

## Keywords:

Saw

Tibial component

Knee

Revision

Arthroplasty

## ABSTRACT

Revision total knee arthroplasty often necessitates removing well-fixed components. Tibial tray removal is challenging because of 1) physical barriers posed by the component pegs, keel, or stem in accessing the implant-bone interface circumferentially and 2) proximity of vulnerable structures including the patellar tendon, collateral ligaments, popliteal artery, and distal femur. In this report, we present a step-by-step technique for removal of a well-fixed tibial component using a single-sided reciprocating saw.

© 2021 Published by Elsevier Inc. on behalf of The American Association of Hip and Knee Surgeons. This is an open access article under the CC BY-NC-ND license (<http://creativecommons.org/licenses/by-nc-nd/4.0/>).

## Introduction

The incidence of revision total knee arthroplasty (TKA) is increasing at a rate even faster than that of primary TKA [1]. The most common indications for revision TKA are infection, aseptic loosening, instability, and stiffness [2–4]. The gold-standard treatment for these conditions requires component removal [5–7]. Effective removal of well-fixed components preserves bone stock for subsequent reconstruction while avoiding fracture. Tibial component removal in revision TKA is challenging for multiple reasons. First, the keel, pegs, or stem below the tibial tray pose physical barriers to accessing the implant-bone interface circumferentially from the anterior aspect of the component. In addition, there is potential for injury to adjacent structures in close proximity that limit implant accessibility, including the femur, collateral ligaments, patellar tendon, and neurovascular structures. The well-established technique of using stacked osteotomes for tibial component removal may impart an eccentric force onto the implant that results in tibial plateau fracture [8]. Periprosthetic

fracture as well as injury to ligaments, extensor mechanism, or vessels can drastically alter the postoperative course of revision TKA and compromise the ultimate outcome. In this report, we present a technique for tibial component removal using a single-sided reciprocating saw that maximizes preservation of bone stock and soft tissues.

## Surgical technique

## Exposure

Tibial component removal that preserves bone stock and minimizes risk of fracture or injury to adjacent structures during revision TKA first requires gaining exposure to the proximal tibia. The authors favor the medial parapatellar approach for revision TKA as it allows maximum lateral subluxation of the extensor mechanism. After medial parapatellar arthrotomy, if the patella can be manually dislocated out of the trochlear groove with the knee flexed, the proximal extent of the arthrotomy is sufficient.

The next steps in exposure prepare for subluxation of the tibia anterior to the distal-most extent of the femur with the knee in flexion, which provides circumferential access to the tibial component. Place a drill pin in the tissue at the medial aspect of the tibial tuberosity to prevent peeling of the patellar tendon insertion

\* Corresponding author. Chief of Adult Reconstruction, 110 S. Paca Street, Suite 300, Baltimore, MD 21201, USA. Tel.: +1 410 683 4107.

E-mail address: [sumon.nandi@gmail.com](mailto:sumon.nandi@gmail.com)

as the knee is flexed and patella subluxed. Remove the polyethylene liner and, if indicated, the femoral component to decrease soft tissue tension about the knee to prevent traction injury to the collateral ligaments or extensor mechanism.

The final steps in exposure deliver the tibia anterior to the femur in flexion. Place a retractor at the anterolateral aspect of the tibia to retract the extensor mechanism. Hyperflex the knee and externally rotate the tibia to deliver the proximal tibia anteriorly. Place a retractor immediately against the posterior tibial cortex to translate the proximal tibia anterior to the femur. Use a retractor along the medial tibia to protect the medial collateral ligament during component removal.

#### *Tibial component removal*

The goals of component removal are preservation of bone stock and integrity of structures adjacent to the implant. We describe here the use of a single-sided reciprocating saw to achieve these goals during tibial component removal in revision TKA. A rongeur is first used to remove bony overgrowth impeding visualization of the interface between the tibial tray and bone circumferentially around the implant. While protecting the patellar tendon with a rake, a narrow end-cutting oscillating saw blade (Fig. 1a) is used to create a trough immediately below the anterior aspect of the tibial tray by advancing the blade as far posteriorly as the implant will allow. The challenge in tibial component removal is now apparent—circumferential access to the implant–bone interface that is impeded by the component’s keel, pegs, or stem as well as adjacent anatomic structures.

A single-sided reciprocating saw (Fig. 1b) remedies these concerns by allowing circumferential access to the tibial implant–bone interface. The cutting side of the blade is first directed medially, placed within the anterior trough previously created and passed immediately below the lateral aspect of the tibial tray with a medially directed force until contact with the keel, pegs, or stem is made (Fig. 2a). Then, the cutting edge of the blade is oriented laterally, placed within the anterior trough, and passed below the medial tibial tray with a laterally directed force until advancement is no longer possible (Fig. 2b). Optimal exposure of the posterior tibial tray is then achieved by confirming that the knee is hyperflexed with tibia externally rotated and applying pressure to the posterior tibial retractor until the posterolateral tibia is anterior to the lateral femoral condyle. Finally, with the single-sided reciprocating saw positioned parallel to the posterior border of the tibial tray with teeth pointed anteriorly, the blade tip is advanced under the tray from posteromedial to posterolateral tibia with

simultaneous anteriorly directed force until the keel, peg, or stem is contacted (Fig. 2c).

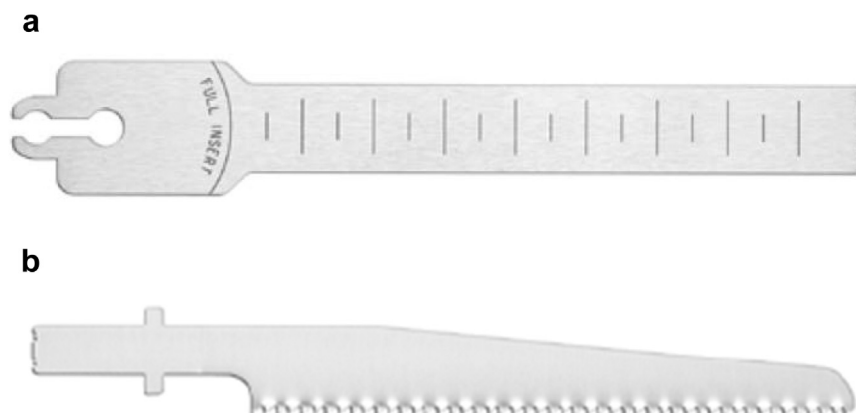
While standing next to the patient’s ipsilateral thigh and facing the foot of the bed, a curved quarter-inch osteotome is used to disrupt any remaining material adherent to the posterior aspects of the tibial component (Fig. 2d). By this time, the tibial component will have lifted slightly off the tibial plateau. If this has not yet occurred, then additional work is required with the curved quarter-inch osteotome to further disrupt the implant–bone interface posteriorly. If the tibial component is still not mobile, only then is a broad, flat osteotome impacted into the implant–bone interface anteriorly. A second broad, flat osteotome is stacked on top of the first osteotome and then malleted underneath the tibial tray. This limited stacked osteotome technique can be used across the anterior aspect of the tibial component until it is mobile. However, levering the osteotomes against the tibial plateau or striking the undersurface of the osteotomes imparts an eccentric force that may result in tibial plateau fracture and hence should be avoided [8].

The final step in component removal requires an axially directed force. We prefer to use a universal tibial baseplate extractor that attaches to a slap-hammer (Zimmer-Biomet, Warsaw, IN) (Fig. 3a). This device has prongs that grasp the undersurface of the tibial tray medially and laterally, regardless of design (Fig. 3b). Care must be taken to ensure the tibia is translated anterior to the femoral condyles, providing a clear path for component extraction to avoid iatrogenic damage to the distal femur. Knee hyperflexion, external rotation of the tibia, and use of a posterior tibial retractor are helpful in achieving this goal.

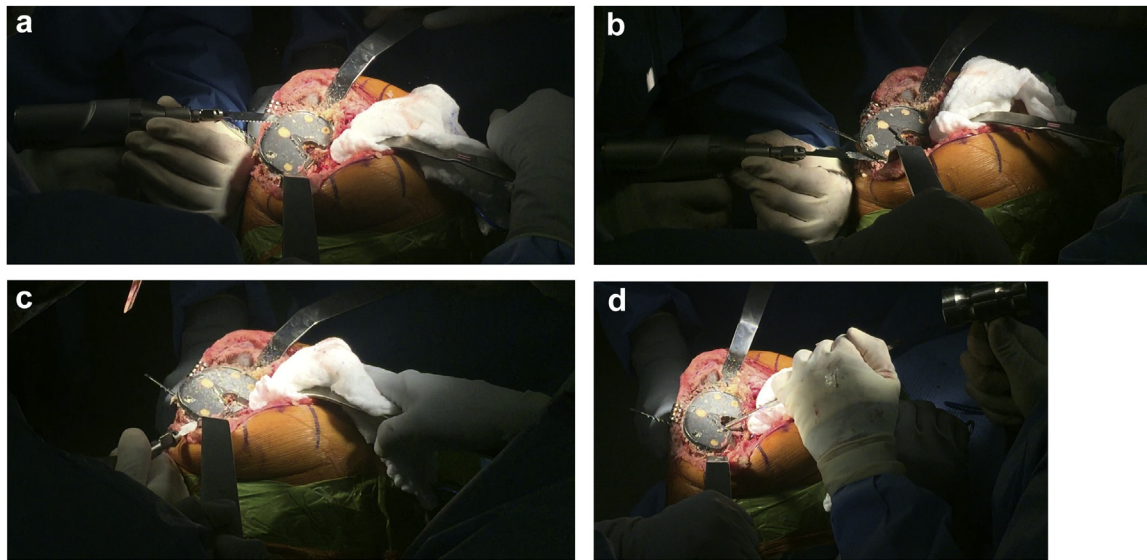
#### *Stemmed tibial component removal*

Removal of a stemmed tibial component requires utilization of all the aforementioned techniques. However, component extraction may necessitate additional measures. After use of the universal tibial baseplate extractor, the tibial component may sit slightly proud above the tibial plateau but remain fixed within the tibia. In this case, the knee is placed on a radiolucent triangle with tibia translated anteriorly using a posterior tibial retractor. The tapered edge of a 1-inch straight osteotome is placed on the undersurface of the tibial tray anteriorly and held in-line with the tibial shaft. A mallet is then used to firmly strike the back of the osteotome until the stemmed tibial component is dislodged.

Additional barriers to implant removal include adjuncts such as cones or sleeves, which require extraction techniques beyond the scope of this article.



**Figure 1.** Narrow end-cutting oscillating saw blade (a) and single-sided reciprocating saw blade (b). Pictures courtesy of Stryker (Kalamazoo, MI).



**Figure 2.** Single-sided reciprocating saw blade passed laterally below the tibial tray (a), then medially (b), and finally posteriorly proceeding from medial to lateral (c). Finally, a quarter-inch curved osteotome is used posteriorly (d).

A video demonstrating the technique described herein is available for viewing at the following link: <https://www.dropbox.com/s/sscw06pmcfd7t2c/Tibial%20Component.mp4?dl=0>.

## Discussion

Revision TKA often necessitates tibial component removal. However, the keel, pegs, or stem of the tibial component hamper

circumferential access to the implant-cement interface. Access is further limited by the close proximity of structures susceptible to injury, including the collateral ligaments, patellar tendon, popliteal artery, and distal femur. Tibial component removal is described only in very general terms in the literature, and no effective solution to the above challenges is discussed [9,10]. The use of various tools are enumerated, but associated risks such as tibial plateau fracture are presented without remedy [8]. In this report, we present a step-by-step technique for removal of a well-fixed tibial component using a single-sided reciprocating saw.

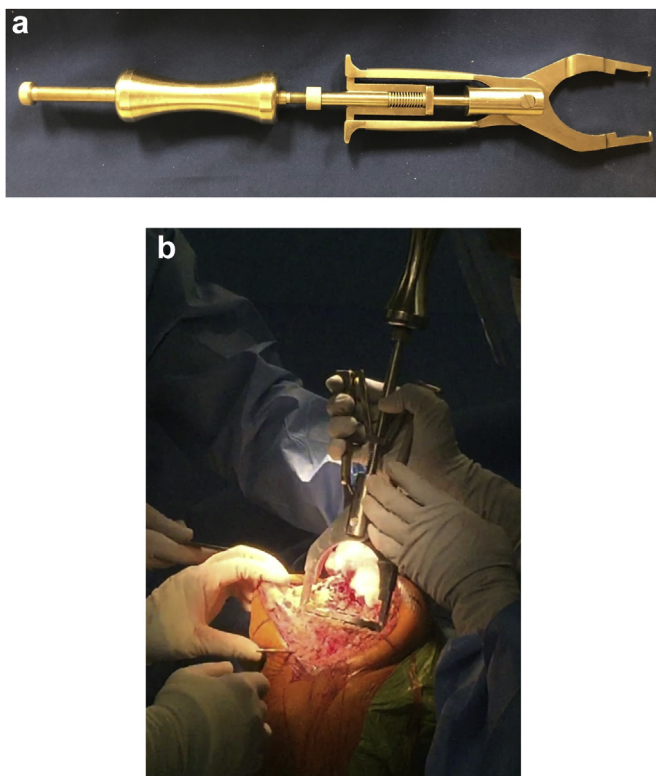
There are several advantages to using a single-sided reciprocating saw in tibial component removal during revision TKA. The stability of the stout blade and ease with which it can be maneuvered allow for the implant-cement (cemented fixation) or implant-bone (cementless fixation) interface to be precisely disrupted, thus preserving bone stock. Efficiency is promoted by the long cutting edge of the blade. During use, the teeth of the saw blade are always pointed away from adjacent anatomic structures, such as the patellar tendon, collateral ligaments, and popliteal vessels. Risk of injury to these structures is further minimized by the anterior-posterior, not medial-lateral, excursion of the single-sided reciprocating saw blade. The side of end cutting blades with medial-lateral excursion can bluntly traumatize the patellar tendon or collateral ligaments.

## Summary

The most common indications for revision TKA necessitate removal of well-fixed implants. Tibial tray removal is challenging because of 1) physical barriers posed by the component pegs, keel, or stem in accessing the implant-bone interface circumferentially and 2) proximity of vulnerable structures including the patellar tendon, collateral ligaments, popliteal artery, and distal femur. For the first time, we describe the use of a single-sided reciprocating saw blade for facile, tissue-preserving tibial component removal.

## Conflict of interest

A. Johnson and S. Nandi are in the medical/orthopaedic publications editorial/governing board of Arthroplasty Today. S. Nandi is a board member at/made committee appointments for AAOS and AAHKS.



**Figure 3.** Universal tibial baseplate extractor (a) grasping the undersurface of the tibial tray (b). Picture courtesy of Zimmer-Biomet (Warsaw, IN).

For full disclosure statements refer to <https://doi.org/10.1016/j.artd.2021.01.016>.

## References

- [1] Kurtz SM, Ong KL, Lau E, et al. Impact of the economic downturn on total joint replacement demand in the United States: updated projections to 2021. *J Bone Joint Surg Am* 2014;96(8):624.
- [2] Le DH, Goodman SB, Maloney WJ, et al. Current modes of failure in TKA: infection, instability, and stiffness predominate. *Clin Orthop Relat Res* 2014;472:2197.
- [3] Sharkey PF, Hozack WJ, Rothman RH, Shastri S, Jacoby SM. Insall Award Paper. Why are total knee arthroplasties failing today? *Clin Orthop Relat Res* 2002;(404):7.
- [4] Callaghan JJ, O'Rourke MR, Saleh KJ. Why knees fail: lessons learned. *J Arthroplasty* 2004;19(4 Suppl 1):31.
- [5] Scuderi GR, Springer BD. Evaluation and management of the infected total knee arthroplasty. *Instr Course Lect* 2013;62:349.
- [6] Babis GC, Trousdale RT, Morrey BF. The effectiveness of isolated tibial insert exchange in revision total knee arthroplasty. *J Bone Joint Surg Am* 2002;84:64.
- [7] Bedard M, Vince KG, Redfern J, et al. Internal rotation of the tibial component is frequent in stiff total knee arthroplasty. *Clin Orthop Relat Res* 2011;469:2346.
- [8] Sassoon AA, Wyles CC, Norambuena-Morales GA, et al. Intraoperative fracture during aseptic revision total knee arthroplasty. *J Arthroplasty* 2014;29(11):2187.
- [9] Mason JB, Fehring TK. Removing well-fixed total knee arthroplasty implants. *Clin Orthop Relat Res* 2006;446:76.
- [10] Masri BA, Mitchell PA, Duncan CP. Removal of solidly fixed implants during revision hip and knee arthroplasty. *J Am Acad Orthop Surg* 2005;13:18.