



Case Series

Acute hematogenous osteomyelitis in children: Management of pandiaphysitis with extensive bone destruction: A case series of thirteen child

Mohamed Zairi^{a,*}, Ahmed Amin Mohseni^a, Ahmed Msakni^a, Chaker Jaber^b, Kacem Mensia^c, Walid Saied^a, Sami Bouchoucha^a, Rim Boussetta^a, Mohamed Nabil Nessib^a

^a Faculty of Medicine of Tunis, Department of Pediatric Orthopedic Surgery, Bechir Hamza Children's Hospital, Tunis, Tunisia

^b Faculty of Medicine of Tunis, Department of Cardiovascular Surgery, Hospital of Pneumo-Phtisiology Abderrahman Mami, Tunis, Tunisia

^c Specialist Surgeon, Department of Pediatric Orthopedic Surgery, Bechir Hamza Children's Hospital, Tunis, Tunisia



ARTICLE INFO

Keywords:

Case series
Acute hematogenous osteomyelitis
Children
Pandiaphysitis
Extensive bone destruction
Staphylococcus aureus

ABSTRACT

Introduction: and Importance: Acute hematogenous osteomyelitis (AHO) poses a public health problem in severe forms from the outset or with delayed diagnosis. The aim of this work is to describe the management of pandiaphysitis with extensive bone destruction by the Ilizarov external fixator and antibiotics and to evaluate the results.

Methods: This is a retrospective, descriptive, cross-sectional and single-center study. It was performed over a seven-year period. We included children with acute hematogenous osteomyelitis complicated by pandiaphysitis of the long bones with extensive bone necrosis. All patients underwent stabilization with an Ilizarov external fixator and antibiotic therapy adapted to the antibiogram in ten cases. One patient had the induced membrane technique. All the patients underwent dynamization of the Ilizarov external fixator followed by immobilization with a cast or a splint for the lower limb.

Outcomes: 13 medical files were collected during the study period. The sex ratio was 1.6, the average age was 7.56 years. Three localization sites: humerus for 3 cases, femur for 3 cases and tibia for 7 cases. The germ has been identified in ten cases. Methicillin-resistant staphylococcus aureus was the most common. Bone consolidation is obtained in all cases with an average delay of ten months.

Conclusion: The Ilizarov external fixator associated with antibiotics has proven its effectiveness in the management of pandiaphysitis with extensive bone destruction. This method is an alternative in the therapeutic arsenal available to pediatric orthopedic surgeons.

Level of evidence: IV, Case series.

1. Introduction

Acute hematogenous osteomyelitis (AHO) is a bone infection that spreads hematogenously [1]. Usually caused by the hematogenous dissemination of septic emboli carried to the terminal blood vessels of bone from distant infectious processes during transient bacteraemia [2]. It poses a public health problem in severe forms from the outset or with delayed diagnosis [3]. Several therapeutic techniques are used. Financial expenses of antibiotics and the functional and psychological

repercussions are high. The objectives of this work are to describe our strategy in the management of pandiaphysites following AHO and evaluate clinical and radiological results.

2. Methods

This is a retrospective, descriptive, cross-sectional and single-center study of consecutive case series. It was performed over a seven-year period, from January 2013 to December 2019 in a multidisciplinary

* Corresponding author. Department of Pediatric Orthopedics Bechir Hamza Children's Hospital in Tunis, 167 Boulevard du 9, Avril, 1938, Tunisia.

E-mail addresses: mohammed.zairi@hotmail.fr (M. Zairi), ahmedaminemohsni@hotmail.com (A.A. Mohseni), dr.ahmedmsakni@gmail.com (A. Msakni), jaberchaker@yahoo.fr (C. Jaber), kacemmensia@yahoo.fr (K. Mensia), walid.saied@rns.tn (W. Saied), sami.bouchoucha@yahoo.com (S. Bouchoucha), boussettaram@hotmail.fr (R. Boussetta), nessibnabil@gmail.com (M.N. Nessib).

<https://doi.org/10.1016/j.amsu.2022.104578>

Received 13 July 2022; Received in revised form 29 August 2022; Accepted 4 September 2022

Available online 8 September 2022

2049-0801/© 2022 The Authors. Published by Elsevier Ltd on behalf of IJS Publishing Group Ltd. This is an open access article under the CC BY-NC-ND license (<http://creativecommons.org/licenses/by-nc-nd/4.0/>).

Table 1

Summary table of epidemiological data and results.

Patients	Age (years)	Sex	Bone	Secondary sites	Germs	antibiotic	EF	Bone graft	Follow-up (months)	complications
1	3	F	Femur	Non	MRSA	T/G	Ilizarov	Non		LLLI
2	3	M	Tibia	heart, lungs, knee, ankle	MRSA	T/G	Ilizarov	Yes		LLLI
3	5,5	M	Tibia	Non	SE	T/G	Ilizarov	Non		–
4	6	M	Humerus	Non	MSSA	AC-A/G	Ilizarov	Non		–
5	6,2	F	Tibia	Non	MSSA	T/G	Ilizarov	Non		–
6	7	M	Tibia	Non	–	AC-A/G	Ilizarov	Non		–
7	7	M	Femur	Non	MSSA	AC-A/G	Ilizarov	Non		JS-Knee
8	9	F	Humerus	Non	SE	T/G	Ilizarov	Non		–
9	9,5	M	Humerus	Non	MSSA	AC-A/G	Ilizarov	Non		JS-Knee
10	10	F	Femur	Non	SE	AC-A/G	Ilizarov	Non		–
11	10,2	F	Tibia	Non	MSSA	AC-A/G	Ilizarov	Non		–
12	10,9	M	Tibia	Non	–	AC-A/G	Ilizarov	Non		–
13	11	M	Tibia	Non	–	AC-A/G	Ilizarov	Non		JS-Ankle

F: Female, M: Male, MRSA: Methicillin-resistant staphylococcus aureus, MSSA: Methicillin-sensitive staphylococcus aureus, SE: staphylococcus epidermidis, T/G: Teicoplanine/Gentamicine, AC-A/G: Acide clavulanique-Amoxicilline/Gentamicine, LLLI: lower limb length inequality, JS: joint stiffness.

pediatric hospital-university center. The diagnostic and therapeutic management (medical and surgical) was carried out by a senior pediatric orthopedic surgeon, expert in this field, for all patients after the meeting of the medical staff cross-speciality. We included children with AHO complicated by pandiaphysitis of the long bones with extensive bone necrosis. Children with sickle cell disease were excluded. All children had a physical examination, an inflammatory laboratory investigation (erythrocyte sedimentation rate (ESR), C-reactive protein (CRP), and white blood cell (WBC) count), a series of blood cultures, an X-ray and an ultrasound. Technitium 99 m (^{99m}Tc) bone scintigraphy and MRI were performed. Bone CT is done in all children when the images of bone lysis appear on an x-ray. After the diagnosis of AHO was confirmed, all of the children underwent surgery: under general anesthesia, we performed surgical drainage of the periosteal abscess, bipolar trepanation of the bone, washing from proximal to distal of the bone marrow with physiological serum. A closure of the various planes on one or two large-caliber drains, placed in direct contact with the bone. We end with immobilization of the limb in a splint.

A probabilistic antibiotic therapy based on Clavulanic acid-Amoxicillin and Gentamicin by the parenteral route is started after the bacteriological samples in all the patients. It is adjusted after 48 hours depending on the result of the antibiogram. When signs of pandiaphysitis with extensive bone necrosis appeared, the Ilizarov external fixator was used. Bone grafting has also been used using the induced membrane technique. Analysis of the results was based on bone consolidation and functional recovery. We performed a literature search on PubMed using the keywords: Acute hematogenous osteomyelitis, Antibiotic, Children, Ilizarov external fixator, Induced membrane, Othofix, Bone graft. The most recent and relevant articles have been selected.

This case series has been reported in line with the PROCESS Guideline [4] Agha RA, Sohrabi C, Mathew G, Franchi T, Kerwan A, O'Neill N for the PROCESS Group. The PROCESS 2020 Guideline: Updating Consensus Preferred Reporting Of CasE Series in Surgery (PROCESS) Guidelines, International Journal of Surgery 2020; 84:231–235.

3. Results

13 medical files were collected during the study period (7 years). The sex ratio was 1.6 with 8 boys and 5 girls. The average age was 7.56 years with extremes ranging from 3 to 11 years. The average time between the onset of clinical signs and surgery is 72 h with extremes of 18 hours to 4 days. 5 children had prior antibiotic therapy of which 3 children had corticosteroid therapy. Fever above 39 °C, circumferential and transfixing bone pain and infected fascies were present in all children. Three localization sites were identified: the distal femoral metaphysis in 3 cases, the proximal tibial metaphysis in 4 cases and distal in 3 cases and the proximal humeral metaphysis in 3 cases.

The initial X-ray was without abnormalities in all patients. The biological inflammatory syndrome was constant with polynuclear neutrophilic hyperleukocytosis (mean WBC = 15,000 ele/ml), mean CRP at 103 mg/ml, mean ESR = 49 mm at the 1st hour. The initial ultrasound revealed localized periosteal detachment in 3 cases and extensive circumferential periosteal detachment in 4 cases. Bone scintigraphy, performed in 5 children, showed hyperfixation. MRI performed in 6 children demonstrated extensive circumferential periosteal detachment and pandiaphysitis. Bone CT assessed the extent of bone necrosis and revealed intramedullary bone abscesses that were present in all 13 patients. The average time to perform CT is 20 days post-operatively, with extremes ranging from 15 to 28 days.

Bacteriological samples were positive in 10 children: 2 cases of Methicillin-Susceptible Staphylococcus aureus (MSSA), 5 cases of Methicillin-Resistant Staphylococcus aureus (MRSA) and 3 cases of staphylococcus epidermidis (SE). Antibiotic tolerance monitoring was based on the search for digestive signs such as vomiting and abdominal pain. No treatment-related complications were observed.

Faced with bone fragility associated with a pathological fracture in 4 cases, diaphyseal immobilization was performed with an Ilizarov external fixator. We didn't do a bone resection. The bone graft in two stages according to the Masquelet technique is performed in one case because there was a bone defect, allowed consolidation.

The average duration of external fixation was 10 months (the extremes ranging from 8 to 13 months) including a period of energization of 2 months. For the lower limb, after removal of the external fixator, a cast or an orthosis is put in place for two months.

Table 1 summarizes the epidemiological, clinical and complications data.

4. Discussion

In our study, 13 patients with infected nonunion of the long bone secondary to pandiaphysitis in AHO were treated by antibiotic and Ilizarov external fixator (IEF) without bone resection. The goal of treatment was to eradicate infection and achieve union while maintaining a good function of the upper members and legs [5]. Management of AHO requires appropriate antimicrobial treatment to eradicate the infection. The child's clinical features, age, and the microbiological profile of the geographic area should be evaluated for diagnosis and in the choice of antibiotic treatment [6]. This typically begins with intravenous (IV) antibiotics to cover the most likely causative organism until culture or sensitivity data are available [7,8]. Several recent studies have examined treatment strategies, including a rapid transition to oral antimicrobial therapy and a shortened overall course of therapy [9].

The culture yield in children with AHO is low [10]. The microbiological etiology was identified in 76% of the children. Staphylococcus was the only pathogen identified. The prevalence of MRSA infection is

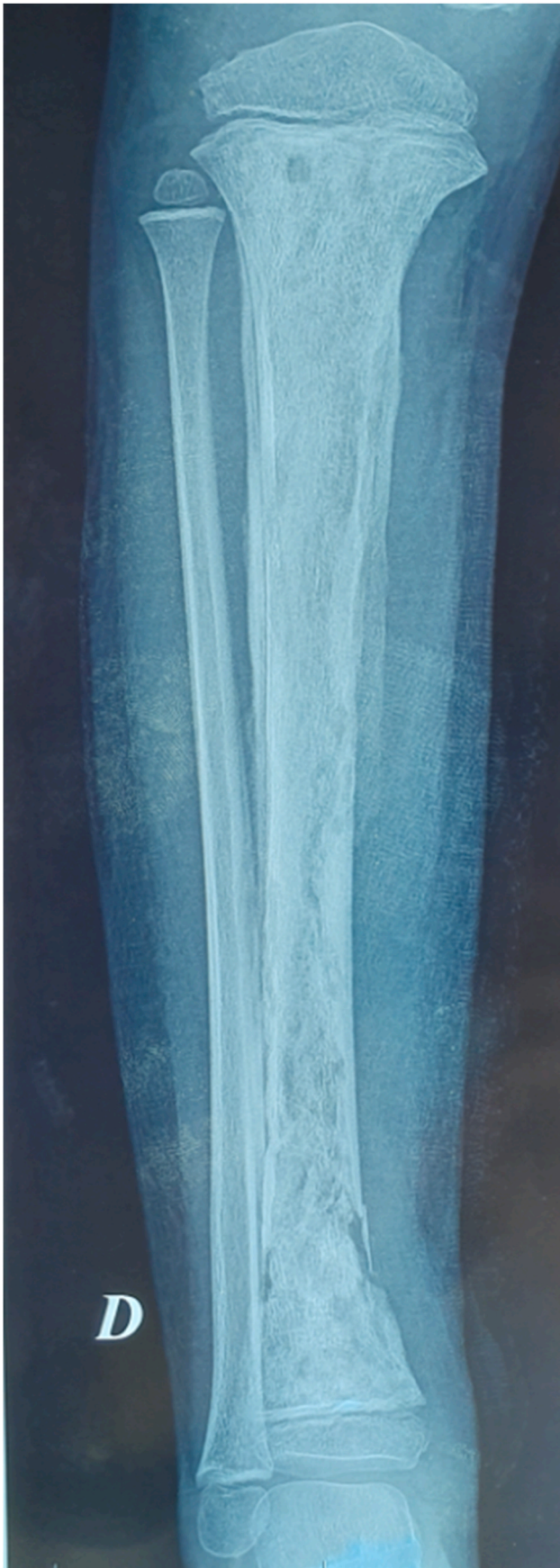

Fig. 1. X-ray of the right tibia: pathological fracture with extensive bone destruction following acute osteomyelitis.

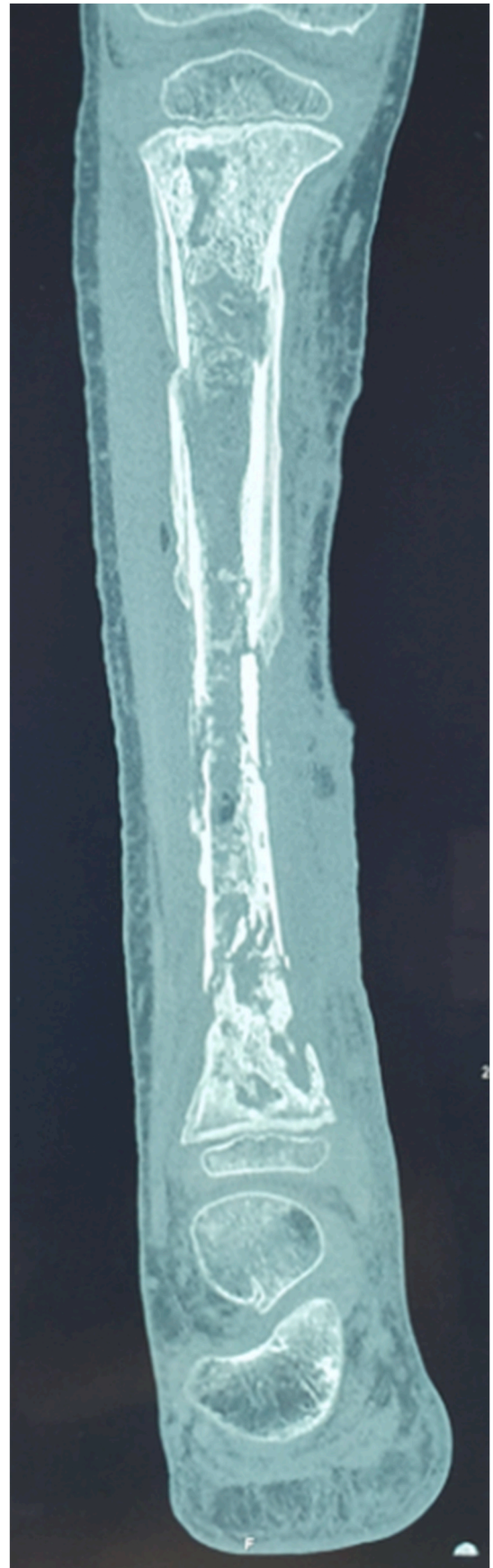


Fig. 2. Coronal CT scan showing the extent and importance of the bone lesions.

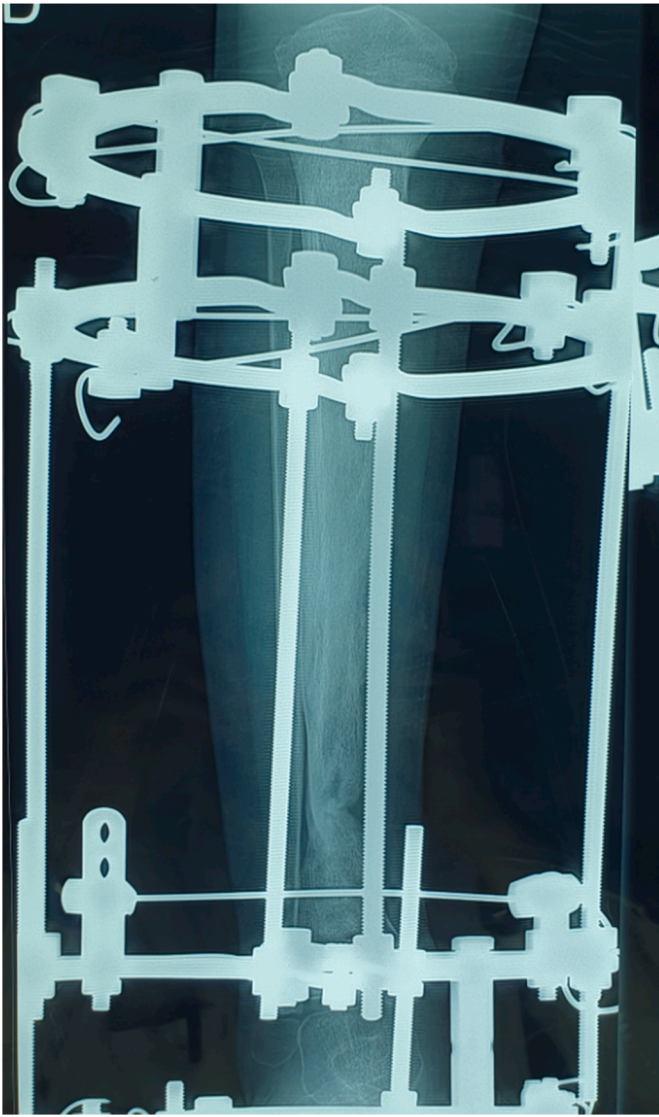

Fig. 3. Bone consolidation underway 3 months after placement of the Ilizarov external fixator and antibiotic therapy.

high in our setting, 20% isolates of *S. aureus*. The rate of MRSA acquired in the community is increased in the United States of America [7,11], but in Europe is still low and less than 2% [12].

In all cases, extensive osteomyelitis was associated with permeative destruction of cortical and medullary bone, without soft tissue defect. The idea of Ilizarov external fixator consists of bipolar stabilization of long bone and systemic antibiotic were eradicating bacteria. Being circular, the Ilizarov fixator allows uniform compression of the nonunion site which stimulates bone healing and corrects axis defects in the event of limb deformity [5,13,14].

In the presence of a significant spontaneous bone defect, we recommend the induced-membrane technique of bone reconstruction described by A.C. Masquelet to shorten the healing period and prevent septic nonunion [15]. Masquelet technique is an efficient procedure for long bone reconstruction after severe infection [16]. However, to obtain optimal results, it is essential to follow the principles of the two stages of the procedure. After debridement, the technique involves separately placing a foreign body membrane using a cement methyl methacrylate polymer spacer followed by a second procedure to fill the defect with cancellous bone. The induced membrane is like a biological chamber that protects the autograft and induces new bone formation promoting growth factors secretion [17]. This technique is used in the tibia for one

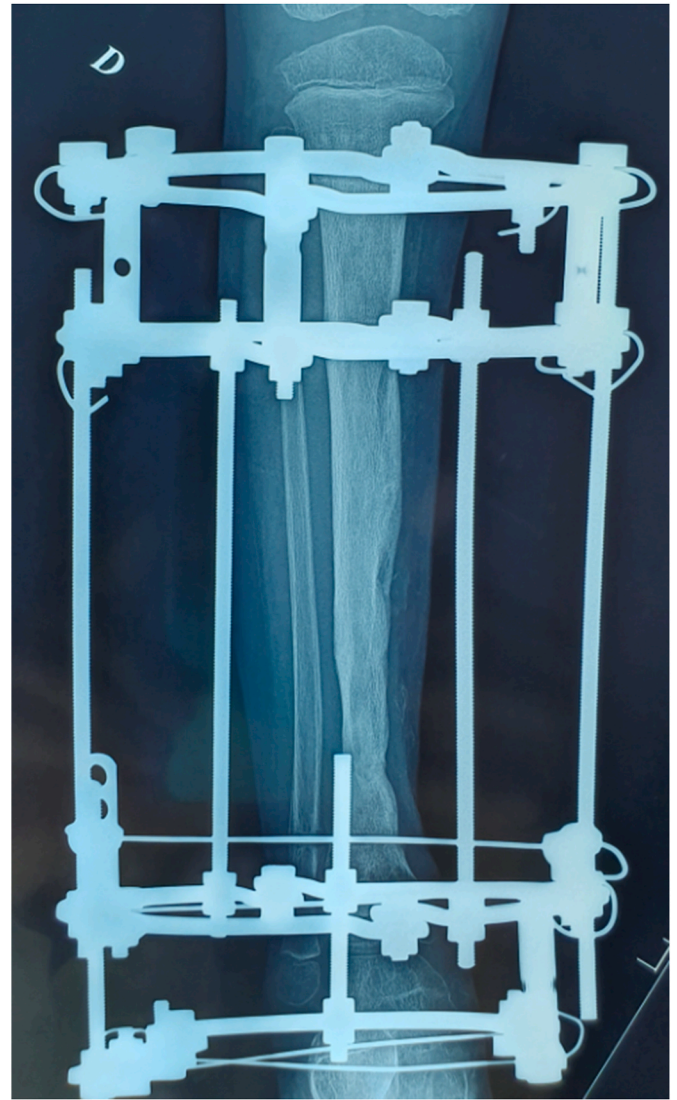

Fig. 4. X-ray at 6 months of Ilizarov external fixator.

case. The induced membrane technique can achieve bone healing in large bone defects secondary to infected non-union in children and adolescents [18,19].

Unlike adults [20,21], extensive bone resection should not be done because the child's bone tissue is rich in progenitor cells and the potential for remodeling is great. This tissue can resist infection and will undergo remodeling which gives it strength. Furthermore, this approach was able to provide new bone formation in a limb resulting in full weight-bearing [20].

Monitoring of IEF was clinical (by looking for compartment syndrome and skin condition near the pins) and radiological (progression of calcification and bone union).

After bone consolidation, a two-month IEF dynamization period is observed for better bone ossification and prevents the risk of fracture.

When the IEF is removed, a plastered immobilization or the use of an orthosis is placed in the lower limb for two months to ensure a transition from removal of the IEF to full weight bearing.

At the mean follow-up of 4 years 7 months, all the bones have consolidated. There was a lower limb length inequality in two cases and were replaced by high shoes. Joint stiffness in 5 cases (2 elbows and 3 knees) treated by physiotherapy.

Our strategy is illustrated by a clinical case in Figs. 1–8.

Several limitations to the present study need to be addressed. This

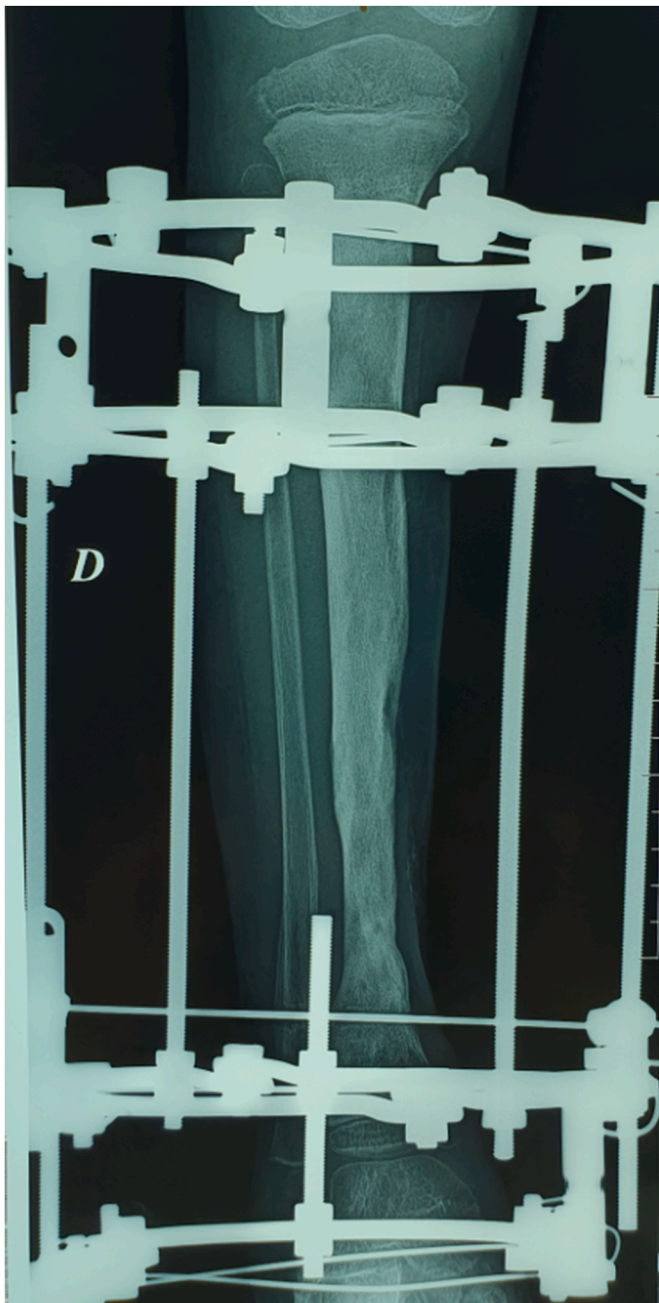

Fig. 5. X-ray at 8 months of Ilizarov external fixator: the quality of the bone formed allows the fixator to be removed.

report represents a retrospective study, single-center series and a limited case series. The experience of more groups is mandatory to gather enough clinical evidence regarding this issue.

5. Conclusions

The Ilizarov external fixator associated with antibiotic therapy represents an effective and safe solution for the management of acute hematogenous osteomyelitis of long bones complicated by pandiaphysitis with extensive bone lesions. It helps to preserve the bone capital of the child and guide bone consolidation. This strategy makes us the most effective and the least expensive in the management of a pathology that is relatively common in poor countries.

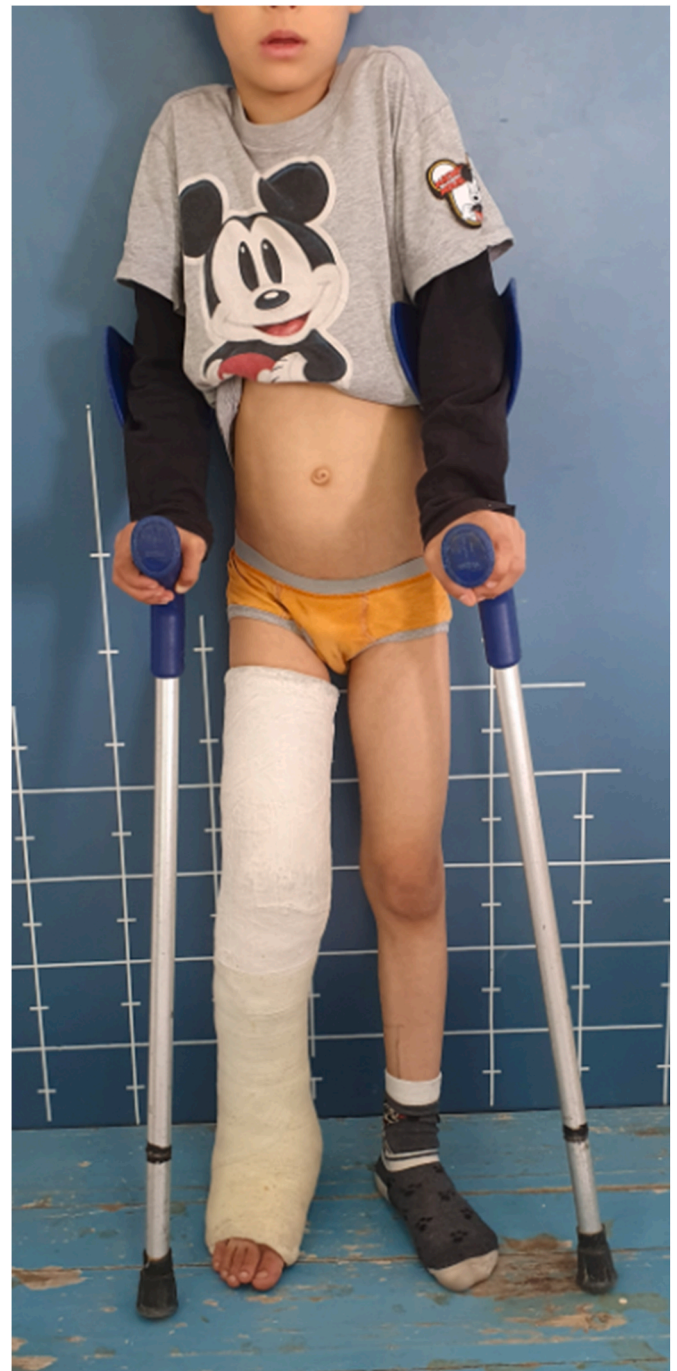

Fig. 6. Plaster cast with permission to walk.

Ethics approval

All data including photos are anonymous. It is a retrospective work respecting anonymity and processing data from medical records.

Funding

No funding

Author contribution

Mohamed Zairi: Writing drafting the article. Ahmed Msakni: conception and design, revising it critically. Rim Boussetta: revising it

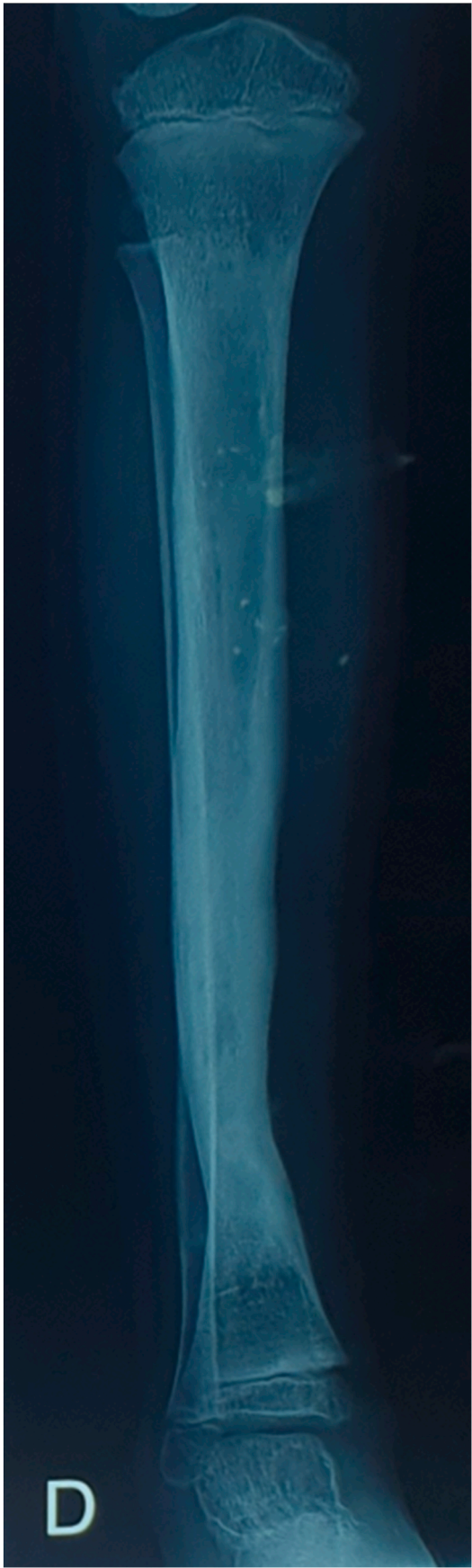


Fig. 7. Frontal right tibia x-ray: bone consolidation after 10 months of treatment.

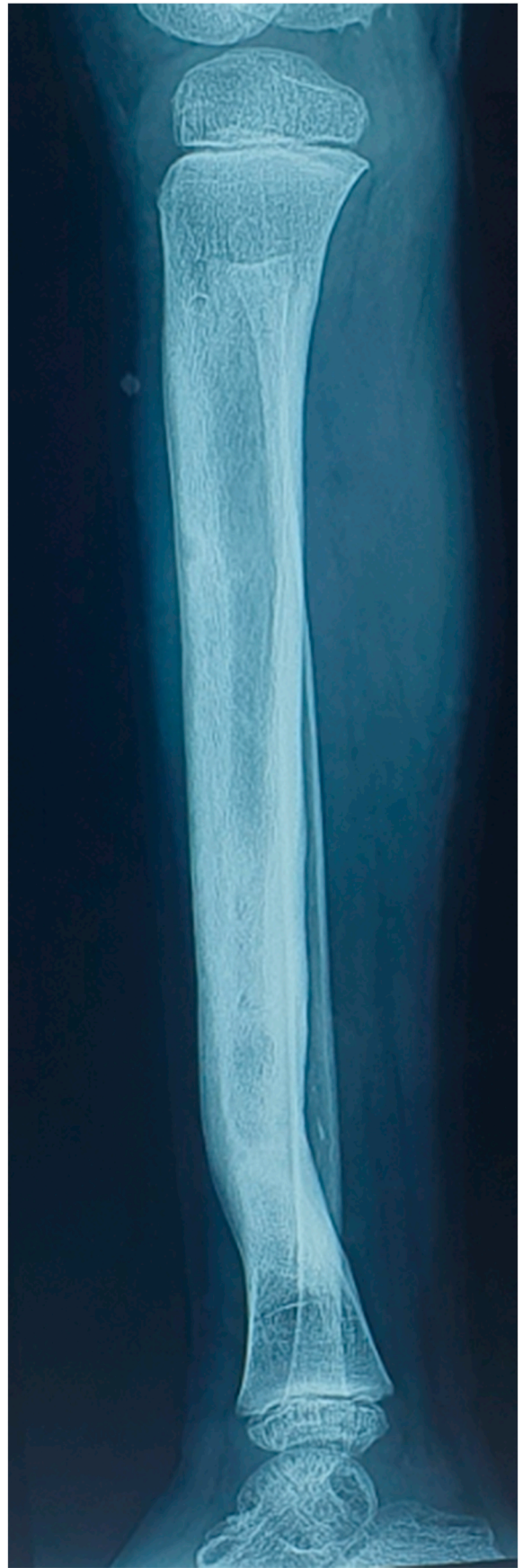

Fig. 8. Profile x-ray of the right tibia: bone union after 10 months of treatment.

critically for important intellectual content. Ahmed Amin Mohseni: revising it critically. Mohamed Nabil Nessib: final approval of the version to be published. Walid Saied: final approval of the version to be published. Sami Bouchoucha: final approval of the version to be published. Chaker Jaber: revising it critically. Kacem Mensia: revising it critically.

Guarantor

Mohamed Zairi.

Consent

Written informed consent was obtained from the patient's guardians for publication of this case series and accompanying images. A copy of the written consent is available for review by the Editor-in-Chief of this journal on request.

Provenance and peer review

Not commissioned, externally peer reviewed.

Availability of data and material

All data is available for the reading committee.

Declaration of competing interest

The authors declare that there are no conflicts of interest.

Appendix A. Supplementary data

Supplementary data to this article can be found online at <https://doi.org/10.1016/j.amsu.2022.104578>.

References

- [1] C. Thévenin-Lemoine, J. Vial, J.L. Labbé, B. Lepage, B. Ilharborde, F. Accadbled, MRI of acute osteomyelitis in long bones of children: pathophysiology study, *Orthop Traumatol Surg Res* 102 (7) (2016) 831–837.
- [2] G. Autore, L. Bernardi, S. Esposito, Update on acute bone and joint infections in paediatrics: a narrative review on the most recent evidence-based recommendations and appropriate antimicrobial therapy, *Antibiotics* 9 (8) (2020) 486.
- [3] A.A. Mohseni, R. Boussetta, M. Zairi, W. Saied, A. Msakni, S. Bouchoucha, M. N. Nessib, Management of septic non union and discrepancy of humerus in a child: a case report, *Int J Surg Case Rep* 77 (2020) 472–475.
- [4] R.A. Agha, C. Sohrabi, G. Mathew, T. Franchi, A. Kerwan, O'Neill N for the PROCESS Group, The PROCESS 2020 guideline: updating Consensus preferred reporting of CasE series in surgery (PROCESS) Guidelines, *Int. J. Surg.* 84 (2020) 231–235.
- [5] B.S. El-Alfy, M. Maaty, T. Niazy, Reconstruction of infected nonunion of the distal humerus by Ilizarov external fixator, *Injury* 52 (6) (2021) 1418–1422.
- [6] S. Congedi, C. Minotti, C. Giaquinto, L. Da Dalt, D. Donà, Acute infectious osteomyelitis in children: new treatment strategies for an old enemy, *World J Pediatr* 16 (5) (2020) 446–455.
- [7] S.S. Funk, L.A.B. Copley, Acute hematogenous osteomyelitis in children: pathogenesis, diagnosis, and treatment, *Orthop. Clin. N. Am.* 48 (2) (2017) 199–208.
- [8] E. Serrano, I. Ferri, L. Galli, E. Chiappini, Amoxicillin-clavulanic acid empirical oral therapy for the management of children with acute haematogenous osteomyelitis, *Antibiotics* 9 (8) (2020) 525.
- [9] I. Thomsen, C.B. Creech, Advances in the diagnosis and management of pediatric osteomyelitis, *Curr. Infect. Dis. Rep.* 13 (5) (2011) 451–460.
- [10] J.V. Heideken, R. Bennet, M. Eriksson, O. Hertting, A 10-year retrospective survey of acute childhood osteomyelitis in Stockholm, Sweden, *J. Paediatr. Child Health* 56 (12) (2020) 1912–1917.
- [11] Z. Alhinai, M. Elahi, S. Park, et al., Prediction of adverse outcomes in pediatric acute hematogenous osteomyelitis, *Clin. Infect. Dis.* 71 (9) (2020) e454–e464.
- [12] C. Calvo, E. Nunez, M. Camacho, et al., Epidemiology and management of acute, uncomplicated, septic arthritis and osteomyelitis, *Pediatr. Infect. Dis. J.* 35 (12) (2016) 1288–1293.
- [13] P. Yin, Q. Zhang, Z. Mao, T. Li, L. Zhang, P. Tang, The treatment of infected tibial nonunion by bone transport using the Ilizarov external fixator and a systematic review of infected tibial nonunion treated by Ilizarov methods, *Acta Orthop. Belg.* 80 (3) (2014) 426–435.
- [14] K. Tong, Z. Zhong, Y. Peng, et al., Masquelet technique versus Ilizarov bone transport for reconstruction of lower extremity bone defects following posttraumatic osteomyelitis, *Injury* 48 (7) (2017) 1616–1622.
- [15] A.C. Masquelet, F. Fitoussi, T. Begue, G.P. Muller, Reconstruction of the long bones by the induced membrane and spongy autograft, *Ann. Chir. Plast. Esthet.* 45 (3) (2000) 346–353.
- [16] A. Hara, M. Yokoyama, S. Ichihara, T. Kudo, Y. Maruyama, Masquelet technique for the treatment of acute osteomyelitis of the PIP joint caused by clenched-fist human bite injury: a case report, *Int J Surg Case Rep* 51 (2018) 282–287.
- [17] S. Careri, R. Vitiello, M. Oliva, A. Ziranu, G. Maccauro, C. Perisano, Masquelet technique and osteomyelitis: innovations and literature review, *Eur. Rev. Med. Pharmacol. Sci.* 23 (2 Suppl) (2019) 210–216.
- [18] M. Rousset, M. Walle, L. Cambou, et al., Chronic infection and infected non-union of the long bones in paediatric patients: preliminary results of bone versus beta-tricalcium phosphate grafting after induced membrane formation, *Int. Orthop.* 42 (2) (2018) 385–393.
- [19] A.A. Mohseni, R. Boussetta, W. Saied, et al., Congenital pseudarthrosis of the forearm treated with induced membrane technique: a case report, *Int J Surg Case Rep* 77 (2020) 584–590.
- [20] M. Reichelt, S. Gehmert, A. Krieg, A. Nowakowski, Bone crushing in infected pseudarthrosis—an extraordinary way to treat osteomyelitis caused by resistant bacteria, *J. Orthop. Case Rep.* 9 (6) (2020) 74–77.
- [21] C. Qin, L. Xu, J. Liao, J. Fang, Y. Hu, Management of osteomyelitis-induced massive tibial bone defect by monolateral external fixator combined with antibiotics-impregnated calcium sulphate: a retrospective study, *BioMed Res. Int.* 2018 (2018), 9070216.