


## CASE REPORT

# Unusual radiologic manifestation of pseudoprogression in pulmonary metastases after durvalumab treatment in metastatic bladder urothelial cancer

Eun Young Kim<sup>1</sup>, Inkeun Park<sup>2\*</sup> , Young Saing Kim<sup>2\*</sup>, Hee Kyung Ahn<sup>2</sup>, Hee Young Lee<sup>1</sup> & Jeong Ho Kim<sup>1</sup>

1 Department of Radiology, Gil Medical Center, Gachon University College of Medicine, Incheon, South Korea

2 Division of Medical Oncology, Department of Internal Medicine, Gil Medical Center, Gachon University College of Medicine, Incheon, South Korea

## Keywords

Bladder cancer; durvalumab; immunotherapy; lung metastasis; pseudoprogression.

## Correspondence

Inkeun Park and Young Saing Kim, Division of Medical Oncology, Department of Internal Medicine, Gil Medical Center, Gachon University College of Medicine, 21, Namdong-daero 774 beon-gil, Namdong-gu, Incheon 21565, South Korea.

Tel: +82 32 460 3229

Fax: +82 32 460 2391

Email: ingni79@gilhospital.com;

zoomboom@hanmail.net

\*These authors contributed equally to this work.

Received: 12 December 2018;

Accepted: 7 January 2019.

doi: 10.1111/1759-7714.12994

Thoracic Cancer **10** (2019) 1016–1018

## Introduction

Durvalumab is a novel immune checkpoint inhibitor (ICI) that blocks PD-L1, and is approved for locally advanced or metastatic urothelial cancer (UC) and unresectable stage III non-small cell lung cancer (NSCLC). ICIs can present pseudoprogression (initial tumor enlargement with subsequent tumor regression), hyperprogression, and immune-related adverse events (irAEs).

We describe a case of metastatic bladder UC that shows an unusual response pattern to durvalumab: ground-glass opacity (GGO) changes in multiple pulmonary metastases one month after treatment initiation and subsequent reso-

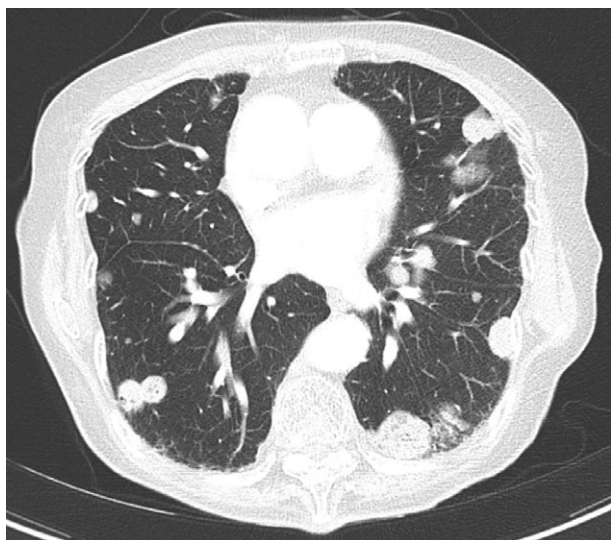
## Abstract

Durvalumab is an immune checkpoint inhibitor that blocks PD-L1. Unlike cytotoxic chemotherapy or molecularly targeted agents, immune checkpoint inhibitors occasionally present distinct response patterns, including radiologic pseudoprogression (initial tumor enlargement with subsequent tumor regression) and immune-related adverse events in normal tissues. We report a case of unusual computed tomography (CT) findings of pseudoprogression of pulmonary metastases in a patient with metastatic bladder cancer after durvalumab treatment: multiple pulmonary metastases turned into ground-glass opacity on first follow-up CT; on second follow-up CT, and after sustained treatment of the PD-L1 inhibitor, the lesion was resolved.

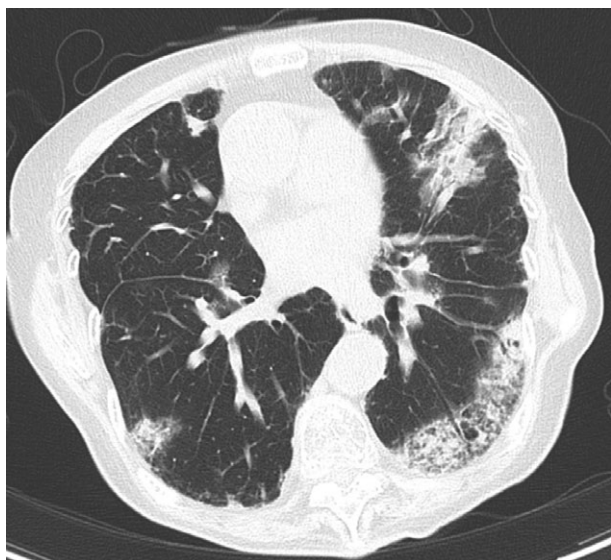
lution of GGO lesions at the next follow-up after sustained durvalumab treatment.

## Case report

A 75-year-old woman was diagnosed with metastatic bladder UC with multiple pulmonary metastases (Fig 1). One month after the initiation of durvalumab treatment, she complained of mild shortness of breath. She did not report cough, sputum, or fever, and physical examination and laboratory findings revealed no abnormal findings. On chest radiography, multiple pulmonary metastases

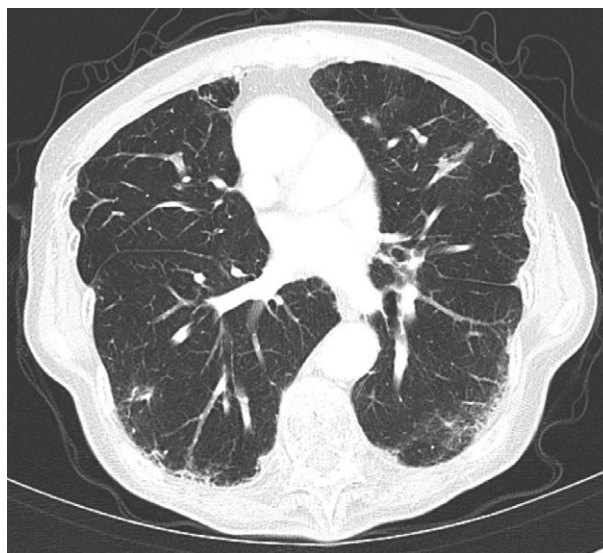


**Figure 1** Multiple pulmonary metastases in a 75-year-old female patient with bladder cancer. Initial chest computed tomography shows multiple pulmonary metastases.



**Figure 2** The first follow-up examination obtained one month after the initiation of durvalumab treatment. Chest computed tomography shows pulmonary metastases transformed into ground-glass opacity.

appeared to have slightly increased in size. However, chest computed tomography (CT) examination showed changes in the multiple solid pulmonary metastases as they turned into ill-defined areas of GGO (Fig 2). Durvalumab treatment was continued as the symptoms soon improved without the need for corticosteroid treatment. On the next follow-up CT (one month later with



**Figure 3** The second follow-up computed tomography examination performed one month later after continuous durvalumab treatment. The extent of ground-glass opacity decreased and nearly disappeared.

sustained durvalumab treatment), the extent of GGO had markedly decreased (Fig 3). The primary bladder mass had also decreased (not shown here). At the last follow-up 26 months from the initiation of durvalumab, the patient was doing well, with a durable response.

## Discussion

Durvalumab is an ICI that blocks PD-L1. Treatment with ICIs can present great challenges as their mode of action and response pattern are distinct from that of conventional chemotherapeutic agents;<sup>1</sup> initial tumor enlargement with subsequent tumor regression, termed pseudoprogression, has been reported as a distinct response pattern to ICIs. On the other hand, an accelerated tumor growth rate after treatment initiation, called hyperprogression, has also been reported. To make matters more complicated, ICIs can induce potentially serious irAEs that can accompany radiologic changes in various organs.<sup>2</sup>

Among irAEs, pneumonitis is an uncommon but potentially fatal toxicity, and the imaging findings of immune-related pneumonitis include the development of GGO and consolidations with patterns of non-specific interstitial pneumonia, cryptogenic organizing pneumonia (COP), and diffuse alveolar damage, which are usually observed in the first three months after initiating ICI therapy.<sup>2</sup> Because the distribution of GGO was subpleural and peribronchovascular in our case, it can mimic ICI-related pneumonitis of a COP pattern. However in our case, the symptoms were mild and improved soon after without corticosteroid treatment. In addition, after the initiation of durvalumab,

ill-defined GGO lesions were found where solid nodules of multiple pulmonary metastases had been located, which, along with the bladder tumor, had significantly decreased by the second follow-up after sustained durvalumab treatment. Considering the longitudinal imaging findings and clinical course, the GGO change in pulmonary metastases is an unusual response pattern that may be related to pseudoprogression. One plausible mechanism of this finding is simultaneous transient immune-cell infiltration and inflammatory response in treating the metastatic pulmonary nodules; however, the patient refused further diagnostic procedures, such as bronchoalveolar lavage or biopsy. As some case reports have revealed peritumoral GGO as treatment-related pneumonitis in patients with NSCLC<sup>3</sup> and melanoma<sup>4,5</sup> treated with nivolumab, the possibility of a concurrent mild form of pneumonitis cannot be excluded, and further studies are warranted to provide a better understanding of this phenomenon.

The reported radiologic findings of pseudoprogression are the development of new lesions or an increase in the size of original tumors.<sup>6–8</sup> To the best of our knowledge, no series have described the GGO change in tumors as an unusual radiologic pattern of pseudoprogression.

In conclusion, our case shows that pseudoprogression can occur in lung metastases from metastatic UC, with an unfamiliar pattern of turning into ill-defined GGOs. To improve the quality of care in the immunotherapy era, both clinicians and radiologists should be aware of the pseudoprogression phenomenon and keep in mind that pseudoprogression can occur in various patterns.

## Disclosure

No authors report any conflict of interest.

## References

- 1 Wang Q, Gao J, Wu X. Pseudoprogression and hyperprogression after checkpoint blockade. *Int Immunopharmacol* 2018; **58**: 125–35.
- 2 Wang GX, Kurra V, Gainor JF *et al.* Immune checkpoint inhibitor cancer therapy: Spectrum of imaging findings. *Radiographics* 2017; **37**: 2132–44.
- 3 Kato R, Hayashi H, Tanizaki J, Tanaka K, Takeda M, Nakagawa K. Peritumoural ground-glass opacity associated with tumour pseudoprogression in a patient with non-small cell lung cancer treated with nivolumab. *ESMO Open* 2017; **2** (1): e000145.
- 4 Sano T, Uhara H, Mikoshiba Y *et al.* Nivolumab-induced organizing pneumonia in a melanoma patient. *Jpn J Clin Oncol* 2016; **46**: 270–2.
- 5 Nakashima K, Naito T, Omori S *et al.* Organizing pneumonia induced by nivolumab in a patient with metastatic melanoma. *J Thorac Oncol* 2016; **11**: 432–3.
- 6 Somarouthu B, Lee SI, Urban T, Sadow CA, Harris GJ, Kambadakone A. Immune-related tumour response assessment criteria: A comprehensive review. *Br J Radiol* 2018; **91**: 20170457.
- 7 Katz SI, Hammer M, Bagley SJ *et al.* Radiologic pseudoprogression during anti-PD-1 therapy for advanced non-small cell lung cancer. *J Thorac Oncol* 2018; **13**: 978–86.
- 8 Hammer M, Bagley S, Aggarwal C *et al.* Thoracic imaging of non-small cell lung cancer treated with anti-programmed death receptor-1 therapy. *Curr Probl Diagn Radiol* 2018. <https://doi.org/10.1067/j.cpradiol.2018.01.005>.