

Open Access

Transcatheter Closure of a Residual Patent Ductus Arteriosus After Surgical Ligation in Children

Osman Baspinar, MD, Metin Kilinc, MD, Mehmet Kervancioglu, MD, and Ahmet Irdem, MD

Department of Pediatric Cardiology, Gaziantep University Medical Faculty, Gaziantep, Turkey

ABSTRACT

Background and Objectives: To assess the safety and efficacy of transcatheter closure of residual ductal flow after initial surgical ligation of the arterial duct. **Subjects and Methods:** Between June 2005 and December 2009, transcatheter occlusion of residual postsurgical ductus arteriosus was performed in six children. **Results:** The mean patient age was 10 ± 5.5 years; mean post-procedural time since the initial surgical closure was 6.3 ± 4.5 years. The mean diameter of the patent ductus arteriosus on angiography was 1.3 ± 0.5 mm (range, 0.8 to 2.4 mm). Three different types of coils were used successfully without any complications. **Conclusion:** Transcatheter occlusion of residual postsurgical arterial duct is a safe and successful procedure. However, attention should be paid due to the distorting shape of the arterial duct. (*Korean Circ J* 2011;41:654-657)

KEY WORD: Child.

Introduction

Transcatheter closure of patent ductus arteriosus (PDA) has largely replaced surgical ligation in different age groups. Currently, fewer children need surgical intervention than in the past. Residual PDA flow is seen after transcatheter closure or surgical intervention. Residual shunt through a previously occluded ductus arteriosus may be a result of suboptimal occlusion or recanalisation of a totally occluded ductus arteriosus. The reported frequency of residual shunts after PDA ligation varies from 3% to 23%.¹⁻³⁾ Most commonly, residual shunts are trivial and hemodynamically insignificant, but have different sizes.⁴⁾⁵⁾ Many reports on coil occlusion of a residual PDA after transcatheter occlusion of PDA are published.⁶⁾ The aim of this study was to present our experience with postoperative residual PDA and our attempt to establish a strategy for the management of patients with residual shunts using this experience.

Received: February 11, 2011

Accepted: March 28, 2011

Correspondence: Osman Baspinar, Department of Pediatric Cardiology, Gaziantep University Medical Faculty, 27310 Gaziantep, Turkey
Tel: 00 90 532 345 54 77, Fax: 00 90 342 360 39 28
E-mail: osmanbaspinar@hotmail.com

• The authors have no financial conflicts of interest.

© This is an Open Access article distributed under the terms of the Creative Commons Attribution Non-Commercial License (<http://creativecommons.org/licenses/by-nc/3.0>) which permits unrestricted non-commercial use, distribution, and reproduction in any medium, provided the original work is properly cited.

Subjects and Methods

Between June 2005 and December 2009, transcatheter PDA closure was performed in 190 patients. Six of them had a residual PDA after surgical ligation. Informed consent was obtained from all the patients. All data were collected retrospectively from the patients' records. The characteristics of the patients are summarized in Table 1. Double ligation through a left lateral thoracotomy was the surgical technique used on all the patients. None of the patients had symptoms of heart failure. Diagnosis of residual ductal flow was made on the basis of physical examination, and/or echocardiography.

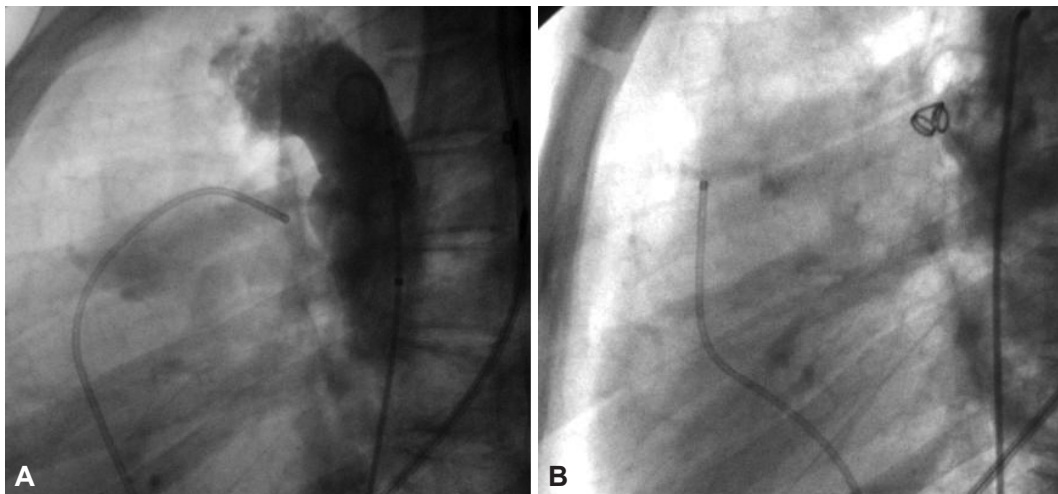
The transcatheter occlusion of the PDA was performed under sedation and local anesthesia. Antegrade vascular access was obtained via the femoral vein and retrograde vascular access via the femoral artery. The size of the arterial duct was measured in the lateral or right oblique position. Three types of coil occluders were used in the study. Selection of implant device was based on the morphology and diameter of the PDA. The implant devices used were Nit-Occlud device (PFM Medical, Cologne, Germany), Gianturco coils (Cook Cardiology, Bloomington, IN, USA) and Flipper Detachable embolization coils (Cook Medical, IN, USA) PDA coils. An antegrade approach was preferred when Nit-Occlud device was used, however, when coils were used, retrograde approach is suggested. These devices were placed as reported previously.⁷⁾ Aortic angiography was routinely performed at the end of

Table 1. Baseline characteristics of the patients

Patient No.	Age (years)	Weight (kg)	Sex	Mean post-procedural time since the initial surgical closure (years)
1	7	19.8	Male	5.5
2	18	43	Female	3
3	3	13	Female	2.5
4	13	33	Female	12.5
5	6	18	Female	3
6	13	39.5	Female	11.5

Table 2. Residual ductus measurements and coil sizes

Patient No.	The narrowest diameter (mm)	The ampulla diameter (mm)	The length (mm)	Device and size
1	1.3	3	3.1	Nit-occlud coil 6/5
2	1.5	14.5	4.1	Gianturco coil 38-5-5
3	0.8	1.3	2.3	Detachable Cook coil 3/4
4	2.4	10.4	4.8	Nit-occlud coil 6/5
4	During the second intervention			Detachable Cook coil 5/4
5	1.1	1.1	2.5	Gianturco coil 38-2-3
6	1.2	12.7	5.4	Detachable Cook coil 6/5

**Fig. 1.** A: aortic angiogram demonstrating distorted shape and small postoperative flow like that in an aortopulmonary window. B: follow-up angiogram showing after placement of 38-5-5 Gianturco coil.

the procedure. Patients were discharged on the second day following the procedure. Physical examination, chest radiography, and echocardiography were performed 24 hours, 1 month, and 1 year after device placement in all the patients.

Statistical analysis was performed using Statistical Package for the Social Sciences (SPSS) version 10.0 (SPSS, Inc., Chicago, IL, USA). Descriptive statistics were calculated for frequencies, means and standard deviations.

Results

Transcatheter interventions were performed at a mean period of 6.3 ± 4.5 years (range, 2.5 to 12.5 years) after the initial surgical closure. The mean patient age at catheterization was 10 ± 5.5 years (range, 3 to 18 years) (Table 1). The mean dia-

meter of the PDA on angiography was 1.3 ± 0.5 mm (range, 0.8 to 2.4 mm) (Table 2). The PDAs were of the unclassified type because they had a smooth ductal ampulla and a very short, thin aortopulmonary communication like a miniature aortopulmonary window (Figs. 1-4). Meaningful shunt ratios were observed in two patients only; their shunt ratios were 1.24 and 1.67 and residual ductal diameters were 1.5 mm and 2.42 mm, respectively.

Transcatheter occlusion was performed twice in patient no. 4 because of insufficient closure of the residual PDA. The patient needed a second detachable Cook coil in addition to the Nit-Occlud coil. Hence a total of four procedures were performed via a retrograde approach and the other three via an antegrade approach. The types of devices used were; Flipper detachable coils used three times, Nit-Occlud coils used two

times, Gianturco coils used two times. All coils were successfully implanted. There were no complications. Complete occlusion of the ductal flow immediately after coil emboliza-

tion was angiographically demonstrable in 4 patients. Complete occlusion occurred one month later in patient No. 6. One patient had an additional mild aortic stenosis, and the

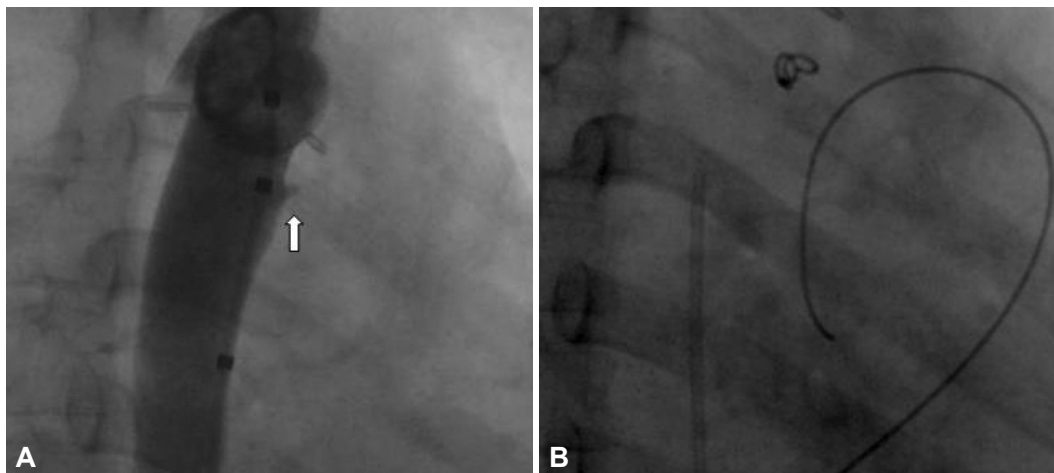


Fig. 2. A: aortic angiogram demonstrating distorted shape and a small, postoperative flow such as a short collateral. B: follow-up angiogram showing after placement of 38-2-3 Gianturco coil.

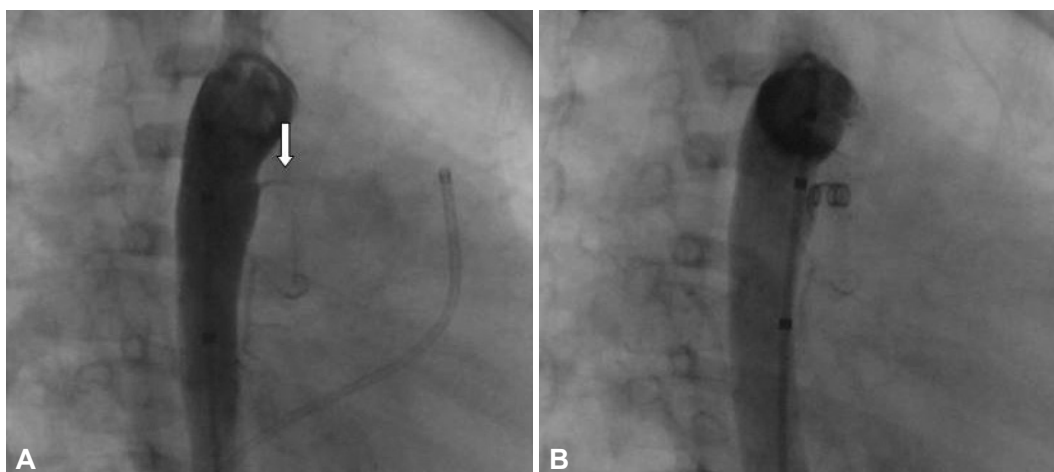


Fig. 3. A: aortic angiogram demonstrating distorted shape and a small postoperative flow such as a short collateral. B: follow-up angiogram showing after placement of 3/4 Flipper detachable coil.

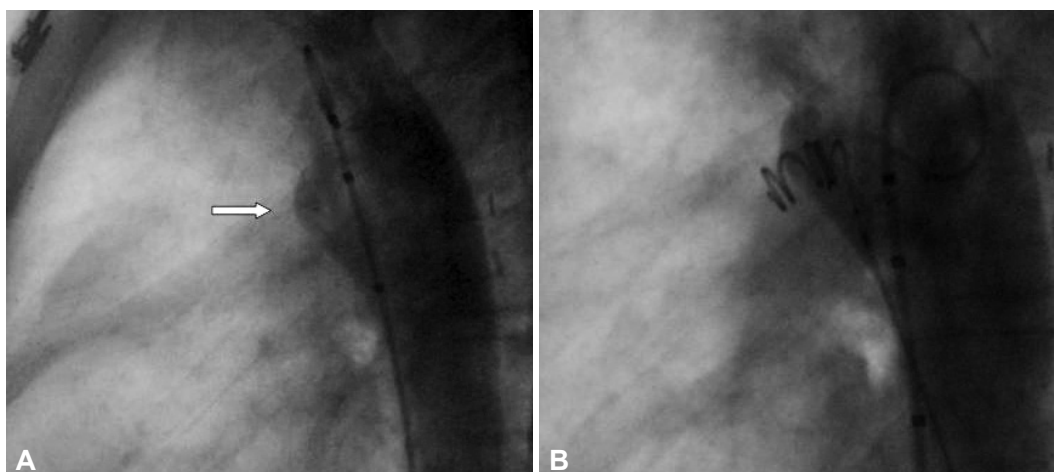


Fig. 4. A: aortic angiogram demonstrating distorted shape and small postoperative flow such as that in an aortopulmonary window. B: follow-up angiogram showing after placement of 6/5 Flipper detachable coil.

other one had hereditary multiple exostoses disease.

Discussion

Double ligation technique involving ligatures on the pulmonary and aortic ends of the ductus has also been widely used. Ductal division usually offers complete closure, whereas ligation has been reported to be associated with recurrences, either due to recanalization or incomplete closure.^{3,8)} Podnar and Masura⁴⁾ reported that double ligation through a left lateral thoracotomy had been the surgical technique used in their patients with postoperative residual ductus arteriosus. Although surgical ligation of PDA is a safe and effective procedure, incomplete closure during ligation or recanalization after ligation may cause residual leaks. In all our patients' the surgical technique used was double ligation. We think that because of a higher recurrence rate, ligation and division technique should be preferred instead of the double ligation method.

Interventional catheterization has replaced surgery for closure of every type of PDA except in the newborn period. But, percutaneous closure of residual PDA after surgical ligation can be more difficult because of aortopulmonary window-like appearance. Also, the management of a tiny PDA ("silent" PDA) can be controversial.⁹⁾ Indeed, many of the residual ductal flows were detected only by color Doppler echocardiography and are not of clinical significance. We recommend closure of all patent arterial ducts, regardless of their size. The twin goals of PDA closure are to achieve interruption of the left-to-right shunt and to avoid the risk of bacterial endocarditis. Hence, the presence of residual leaks should be considered a failure of the procedure. The devastating effects of endocarditis, coupled with the perception of more anecdotal reports of endocarditis with the silent duct, as well as the low risk of interventions, has led us to recommend closure of the patent arterial duct in these situations. Also, Moore

et al.⁷⁾ advocated the closure of all silent PDA's via a retrograde or snare technique using a coil-type device. In the case of a small postoperative residual shunt, insertion of a coil seems to be the optimal therapy due to the favorable design and high efficacy.

It can be traumatic for those parents to learn that a residual PDA still exists; especially, for those who cannot accept the presence of a residual PDA after surgical ligation. Podnar and Masura⁴⁾ and Kusa et al.⁵⁾ stated that they also closed the residual leaks after initial surgical attempts, similar to this study.

In conclusion, transcatheter closure of a residual PDA existing from an initial procedure performed via surgical ligation is suitable for most patients. The diameter and morphology of the residual PDA after surgical ligation is particularly suitable for coil occlusion.

REFERENCES

- 1) Zucker N, Qureshi SA, Baker EJ, Deverall PB, Tynan M. *Residual patency of the arterial duct subsequent to surgical ligation. Cardiol Young* 1993;3:216-9.
- 2) Sørensen KE, Kristensen B, Hansen OK. *Frequency of occurrence of residual ductal flow after surgical ligation by color-flow mapping. Am J Cardiol* 1991;67:653-4.
- 3) Demir T, Öztunc F, Cetin G, et al. *Patency or recanalization of the arterial duct after surgical ligation and transfixion. Cardiol Young* 2007; 17:48-50.
- 4) Podnar T, Masura J. *Transcatheter occlusion of residual patent ductus arteriosus after surgical ligation. Pediatr Cardiol* 1999;20:126-30.
- 5) Kusa J, Szkutnik M, Czerpak B, Bialkowski J. *Percutaneous closure of previously surgical treated arterial ducts. EuroIntervention* 2008; 3:584-7.
- 6) Ovaert C, McCrindle BW, Nykanen D, Freedom RM, Benson LN. *Transcatheter management of residual shunts after initial transcatheter closure of a patent arterial duct. Can J Cardiol* 2003;19:1493-7.
- 7) Moore JW, Levi DS, Moore SD, Schneider DJ, Berdjis F. *Interventional treatment of patent ductus arteriosus in 2004. Catheter Cardiovasc Interv* 2005;64:91-101.
- 8) Jones JC. *Twenty-five years' experience with surgery of patent ductus arteriosus. J Thorac Cardiovasc Surg* 1965;50:149-65.
- 9) Lloyd TR, Beekman RH 3rd. *Clinically silent patent ductus arteriosus. Am Heart J* 1994;127:1664-5.