



## Research paper

# The influence of right-left error in the placement of the Cc electrode in tibial nerve somatosensory evoked potentials (SEPs)



Kazusa Takahashi<sup>a,b</sup>, Chizuko Oishi<sup>a,c</sup>, Yuichi Hamada<sup>a</sup>, Kazutoshi Nishiyama<sup>b</sup>, Masahiro Sonoo<sup>a,\*</sup>

<sup>a</sup> Department of Neurology, Teikyo University School of Medicine, Kaga 2-11-1, Itabashi-ku, Tokyo 1738606, Japan

<sup>b</sup> Department of Neurology, Kitasato University School of Medicine, Kitazato 1-15-1, Minami-ku, Sagami-hara, Kanagawa 2520375, Japan

<sup>c</sup> Department of Neurology, Kyorin University School of Medicine, Shinkawa 6-20-2, Mitaka, Tokyo 1818611, Japan

## ARTICLE INFO

## Article history:

Received 5 December 2020

Received in revised form 17 May 2021

Accepted 3 June 2021

Available online 5 July 2021

## Keywords:

Somatosensory evoked potentials

Tibial nerve

Contralateral central area electrode

P38

N30

## ABSTRACT

**Objective:** At our laboratory, we routinely record tibial nerve somatosensory evoked potentials (SEPs) using 5 channels including the second cervical vertebra (C2S)-contralateral central area (Cc) and Cz' (2 cm posterior to Cz)-Cc derivations. In a man with lumbar spondylotic myelopathy, symptoms improved after surgery, although the N21-P38 interval was markedly prolonged in comparison with that before surgery. We presumed that the Cc electrode was actually placed on the ipsilateral central area (Ci) at the second examination. Inspired by this episode, we investigated the influence of the right-left error in the placement of the Cc electrode.

**Methods:** Subjects were 20 healthy volunteers. Tibial nerve SEPs were recorded with 8 leads including Cz'-Cc, Cz'-Ci, C2S-Cc and C2S-Ci.

**Results:** For the Cz'-Ci lead, the P38 potential diminished in amplitude, was absent or became negative. For the C2S-Ci lead, a large negative potential corresponding to the phase reversal of P38 was frequently observed.

**Conclusions:** Tibial nerve SEPs using the Cz'-Cc or C2S-Cc lead are distorted if the Cc electrode is placed on the opposite side.

**Significance:** When a strange result is obtained in tibial nerve SEPs, we should check for a right-left error in the Cc electrode placement.

© 2021 International Federation of Clinical Neurophysiology. Published by Elsevier B.V. This is an open access article under the CC BY-NC-ND license (<http://creativecommons.org/licenses/by-nc-nd/4.0/>).

## 1. Introduction

Somatosensory evoked potentials (SEPs) are widely used for the evaluation of various diseases affecting the somatosensory pathway. The Cz' (2 cm posterior to Cz)-Fz lead has been conventionally used for recording the cortical component of tibial SEPs (American Electroencephalographic Society, 1984). However, the P38 potential, the first cortical component, may be very small or even undetectable in a small number of subjects in the Cz'-Fz lead (Seyal et al., 1983). To avoid misunderstandings that arise when cortical components are absent in such cases, previous researchers and guidelines have recommended the simultaneous recording of the Cz'-Fz and Ci (ipsilateral central electrode)-Cc (contralateral central electrode) leads (Chiappa, 1990; Nuwer et al., 1994). However, recording multiple channels is troublesome for routine examination. In our previous study (Miura et al., 2003), we proposed

recording the single channel of the Cz'-Cc lead, in which P38 was clearly observed for all subjects even when it was absent in the Cz'-Fz or Ci-Cc leads. Accordingly, the routine montage at our laboratory includes Cz'-Cc and C2S the second cervical vertebra-Cc leads.

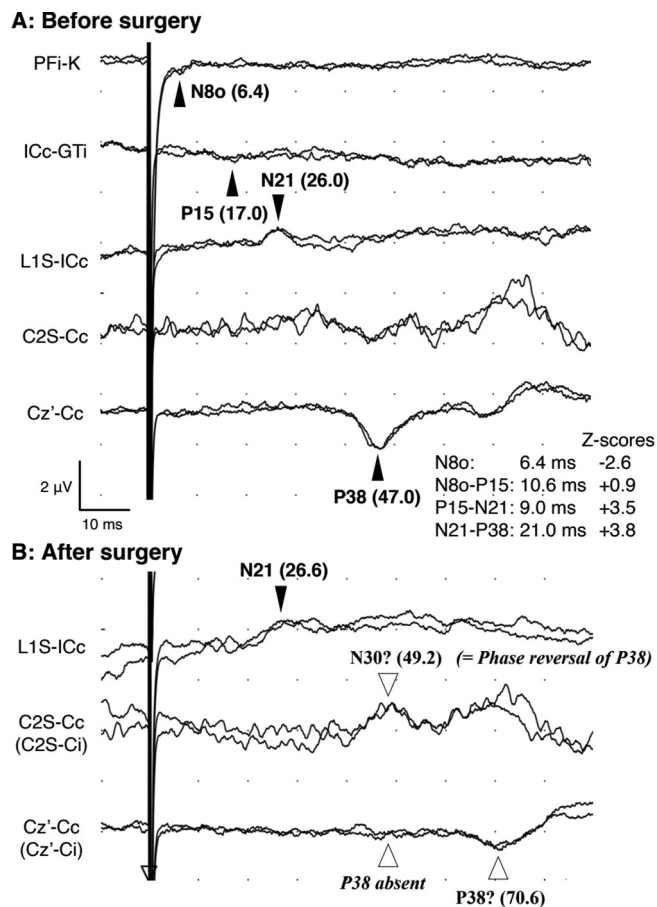
However, this method has a drawback in that there is a possibility that the Cc electrode could be placed on the opposite side. We experienced a case where such a mistake led to the misinterpretation of SEP results. In this study, we present this case and attempt to clarify the reasons for the misinterpretation by investigating the scalp distribution of the cortical components.

## 2. Case presentation

A 71-year-old man with a diagnosis of lumbar spondylosis was referred to us for examination before surgery. He had experienced difficulty walking for five years. Neurological examinations revealed distal weakness of both lower limbs and bilateral positive Babinski sign. His lumbar MRI showed spinal stenosis at the L2/3,

\* Corresponding author.

E-mail address: [sonoom@med.teikyo-u.ac.jp](mailto:sonoom@med.teikyo-u.ac.jp) (M. Sonoo).



**Fig. 1.** Tibial nerve SEPs of the index case (a 71-year-old man with lumbar spondylosis). A: Before surgery. The P15–N21 and N21–P38 intervals were prolonged. B: After surgery. The N21–“P38” interval was much longer than before surgery. The “N30” peak was also extremely delayed. This was later interpreted that the “Cc” electrode was placed on the opposite side, at the ipsilateral central area (Ci). The P38 potential disappeared in the Cz’–Ci lead and a later component was misinterpreted as P38. The “N30” potential in the C2S–Ci lead was actually the phase reversal of P38.

L3/4 and L4/5 levels. Tibial nerve SEPs showed marked prolongations of the P15–N21 and N21–P38 intervals whereas the N8o–P15 interval was normal (Fig. 1A). The N30 potential may be present at around 32 ms, but the latency was too short for N30 in this case so we finally judged that N30 was not clearly identifiable. Prolongation of the P15–N21 interval was consistent with lumbar spondylosis. Prolongation of the N21–P38 interval was thought to be due to cervical spondylotic myelopathy, which was also suspected from the cervical MRI.

His symptoms improved after surgery and the SEP examination was ordered again. On this occasion however the N21–P38 interval was 44.0 ms, which was much longer than before. N30 was also extremely delayed while the P15–N21 interval was almost the same as before (Fig. 1B). We eventually judged that the Cc electrode was placed on the opposite side at the second examination, as explained later. Inspired by this episode, we investigated the scalp distribution of the cortical components of healthy volunteers

to clarify the influence of right-left error in the placement of the Cc electrode.

### 3. Methods

Subjects were 20 healthy volunteers (10 men and 10 women, age 28–61 years) with no neurological abnormalities. Informed consent was obtained from each subject, and the study design was approved by the Ethics Committee of the Teikyo University School of Medicine (approval number: 09-059-2).

The tibial nerve was stimulated at the ankle at a rate of around 1 to 2 Hz. EEG disc electrodes were used for recording and were placed at several sites, including C2S, contralateral earlobe (Ac), Cz’, Fz, Cc, and Ci. SEPs were recorded with the following 8 leads: Cz’–Cc, Cz’–Ci, C2S–Cc, C2S–Ci, Cz’–Fz, Ci–Cc, Cz’–Ac and Ci–Ac. Evoked potentials were amplified and filtered between 5 and 2,000 Hz (–3 dB). We averaged around 300 responses, and two averages were superimposed. SEPs were examined bilaterally for all subjects.

### 4. Results

#### 4.1. Control subjects

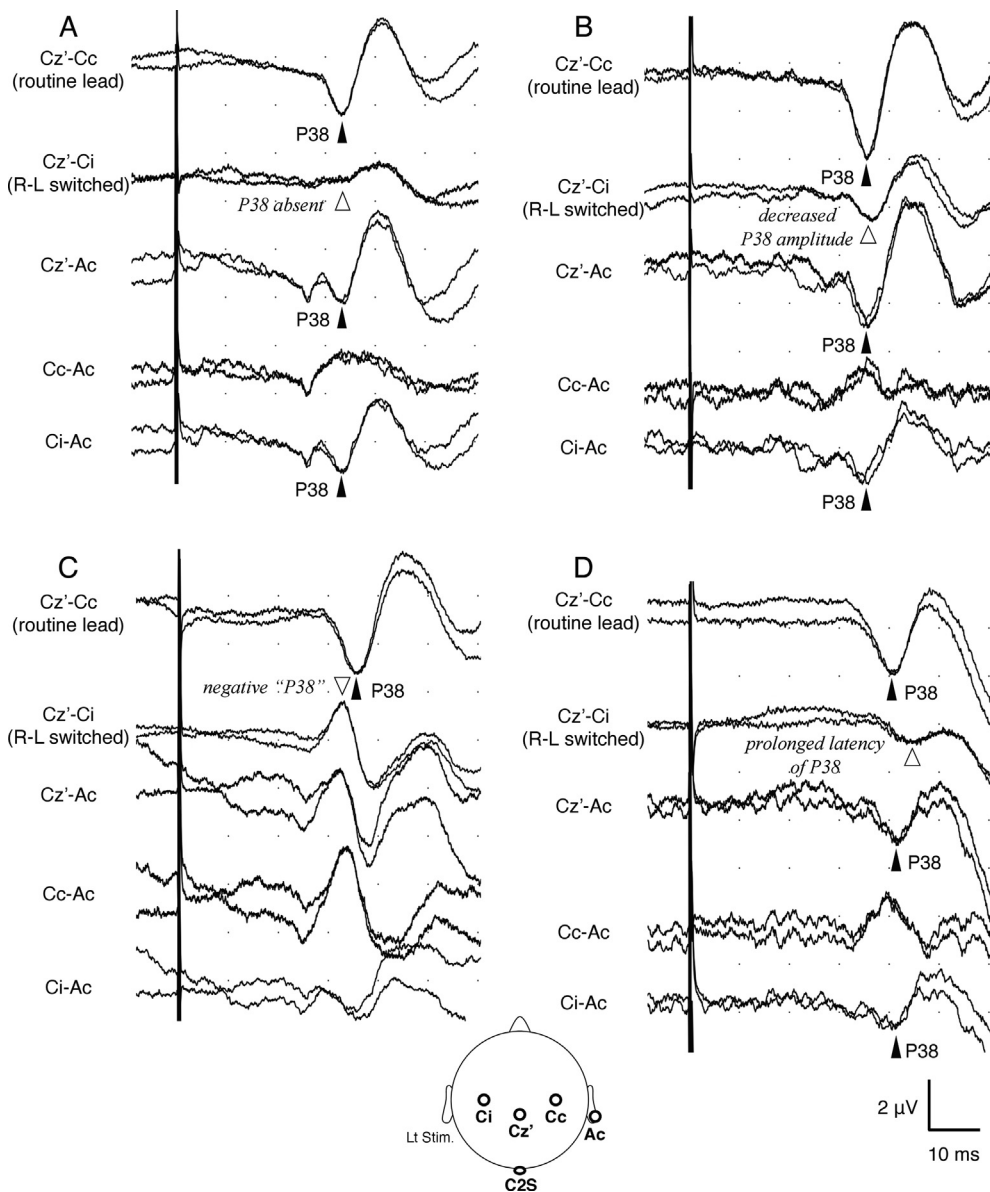
Various patterns of the waveforms of the P38 potentials in the Cz’–Cc and Cz’–Ci leads are presented in Fig. 2. Fig. 2A shows typical waveforms in cardinal derivations in a representative subject. The P38 potential was observed as a negative deflection in both Cz’–Ac and Ci–Ac, whereas this was not observed in the Cc–Ac lead where a dull negative deflection was observed. Accordingly, a P38 potential was recorded in the Cz’–Cc lead, whereas virtually no potential was recorded in the Cz’–Ci lead because Ci was roughly equipotential to Cz’ regarding P38. In this situation, if the Cc electrode is wrongly placed on the opposite side, we would assume the Cz’–Ci lead to be the Cz’–Cc lead and would erroneously judge that P38 is absent.

This pattern, i.e. absent P38 in the Cz’–Ci lead, was observed in 2 legs (Fig. 2A). The most frequent pattern was that the amplitude of P38 in the Cz’–Ci lead was smaller than that in the Cz’–Cc lead: the former was 11–82% of the latter (33 legs; Fig. 2B). P38 was negative in three legs (Fig. 2C) and its latency was markedly prolonged in two legs (Fig. 2D).

We use the C2S–Cc lead to record the N30 potential. If Ci is used instead of Cc, a negative potential would be observed in the “C2S–Cc” lead, which is actually the C2S–Ci lead (Fig. 3). This potential is actually a phase reversal of the P38 since a large P38 potential is usually recorded at the Ci electrode. However, this may be wrongly identified as N30 with a prolonged latency (Fig. 3).

#### 4.2. Interpretation of the index case (Fig. 1B)

It is inconceivable that the central conduction was markedly prolonged after surgery despite clinical improvement. Based on the above results in normal subjects, the SEP waveforms of the index case after surgery are best explained by a right-left error in the placement of the Cc electrode as follows. P38 was most likely absent in the “Cz’–Cc” (actually Cz’–Ci) lead, as was observed in some control subjects. A later potential was then erroneously identified as P38. The latency of N30 in the C2S–Cc (actually C2S–Ci)



**Fig. 2.** Various patterns of the P38 waveform in the Cz'-Cc and Cz'-Ci leads. A: P38 forms a clear positive deflection in the Cz'- contralateral earlobe (Ac) and Ci-Ac leads. However, P38 is not observed in the Cc-Ac lead and is replaced by a broad negative potential. Consequently, a definite P38 potential is recorded in the Cz'-Cc lead, whereas P38 disappears in the Cz'-Ci lead. B: P38 is smaller in the Cz'-Ci lead than that in the Cz'-Cc lead. C: P38 becomes negative in the Cz'-Ci lead. D: The latency of P38 is prolonged in the Cz'-Ci lead. The placement of major electrodes (following left tibial nerve stimulation) is shown at the bottom.

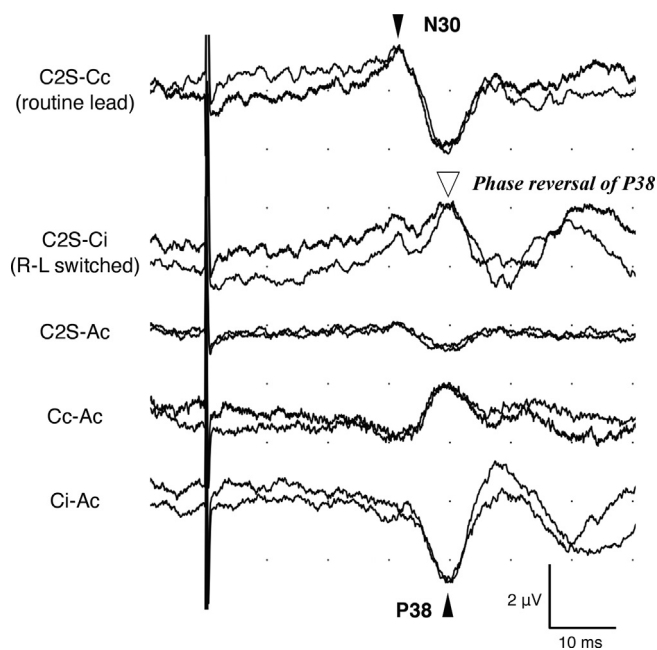
lead was almost the same as that of P38 before surgery. This strongly suggests that it is a mirror image of P38 as shown in Fig. 3.

### 5. Discussion

The present study revealed that if the Cc electrode is placed on the opposite side, the P38 potential may be absent because the Ci electrode may be roughly equipotential to Cz' regarding P38 in some cases. In the index case, this is what seemed to have occurred and a later potential was erroneously identified as P38. We might have erroneously concluded that the SEP had worsened despite

clinical improvement if we had not formulated the theory that the Cc electrode was placed on the opposite side. It is important to consider the possibility of a technical error such as a right-left switch.

Our method using the Cz'-Cc lead may well be criticized. However, this method has a definite advantage in that the P38 potential is clearly observable for all subjects in this single lead, and is best suited for routine examinations (MacDonald, 2001; Miura et al., 2003). We can probably introduce some measure to avoid the right-left error, such as confirming that the Cc and contralateral iliac crest ICc electrodes are placed on the same side.



**Fig. 3.** The effect of the right-left error on N30 (a 37-year-old man). In the C2S-Ci lead, a large negative potential corresponding to the phase reversal of P38 is observed. This may be misinterpreted as N30.

### Declaration of Competing Interest

The authors declare that they have no known competing financial interests or personal relationships that could have appeared to influence the work reported in this paper.

### Acknowledgements

This work was partly supported by the Health and Labour Sciences Research Grant on Intractable Diseases (Neuroimmunological Diseases) from the Ministry of Health, Labour and Welfare of Japan (20FC1030).

### References

- American Electroencephalographic Society, 1984. Guidelines for clinical evoked potential studies. *J. Clin. Neurophysiol.* 1 (1), 3–54.
- Chiappa, K.H., 1990. Evoked potentials in clinical medicine. Raven Press, New York.
- MacDonald, D.B., 2001. Individually optimizing posterior tibial somatosensory evoked potential P37 scalp derivations for intraoperative monitoring. *J. Clin. Neurophysiol.* 18 (4), 364–371.
- Miura, T., Sonoo, M., Shimizu, T., 2003. Establishment of standard values for the latency, interval and amplitude parameters of tibial nerve somatosensory evoked potentials (SEPs). *Clin. Neurophysiol.* 114 (7), 1367–1378.
- Nuwer, M.R., Aminoff, M., Desmedt, J., Eisen, A.A., Goodin, D., Matsuoka, S., Mauguière, F., Shibasaki, H., Sutherling, W., Vibert, J.-F., 1994. IFCN recommended standards for short latency somatosensory evoked potentials. Report of an IFCN committee. *Electroencephalogr. Clin. Neurophysiol.* 91 (1), 6–11.
- Seyal, M., Emerson, R.G., Pedley, T.A., 1983. Spinal and early scalp-recorded components of the somatosensory evoked potential following stimulation of the posterior tibial nerve. *Electroencephalogr. Clin. Neurophysiol.* 55 (3), 320–330.