

The Scarless Latissimus Dorsi Flap Provides Effective Lower Pole Prosthetic Coverage in Breast Reconstruction

Mark A. Lee, MBBS, FRACS*
Kirstin G. Miteff, MBBS†

Background: The evolution of surgical breast cancer treatment has led to the oncologically safe preservation of greater amounts of native skin, yet we are still often using flaps with large skin paddles, thereby resulting in significant donor-site scars. This explains the increasing appeal of acellular dermal matrix reconstructions. Acellular dermal matrices can, however, have significant problems, particularly if there is any vascular compromise of the mastectomy skin flaps. We have developed a method of raising the latissimus dorsi flap through the anterior mastectomy incisions without requiring special instruments or repositioning. This can provide autologous vascularized cover of the prosthesis.

Methods: A clear surgical description of the scarless latissimus dorsi flap harvest is provided, and our results of a retrospective cohort review of 20 consecutive patients with 27 traditional latissimus dorsi breast reconstructions were compared with those of 20 consecutive patients with 30 scarless latissimus dorsi breast reconstructions.

Results: Operative time, length of stay, and complication rates were reduced in the scarless group. Patients Breast-Q scores were equivalent in each group. The aesthetic assessment was good/excellent in 77% of both groups; however, subscale assessment was better in the scarless group. This was statistically significant ($P = 0.0$).

Conclusions: Breast reconstruction using the scarless latissimus dorsi flap is time effective, requires no patient repositioning, and uses standard breast instrumentation. It is safe and versatile while reducing the risk of exposed prosthesis if native skin necrosis occurs. It is a vascularized alternative to acellular dermal matrices. (*Plast Reconstr Surg Glob Open* 2014;2:e147; doi: 10.1097/GOX.0000000000000089; Published online 13 May 2014.)

Developments in breast reconstruction over the last few decades have seen a trend toward the preservation of more native breast skin and an increase in the number of contralateral prophylactic

and bilateral reconstructions for high-risk genetic susceptibility.^{1,2} There has also been an increase in the use of fat transfer in secondary revisionary surgery³ and the exploding use of acellular dermal matrices (ADMs) for lower pole prosthetic cover.⁴⁻¹⁴

The use of ADM has grown with the advantages of decreasing operating time and no donor-site scar when compared with the use of alloplastic material with higher cost and higher rate of complications

From the *Department of Plastic Surgery, St John of God Hospital, Subiaco, Western Australia, Australia; and †Department of Plastic, Reconstructive and Maxillofacial Surgery, Royal Perth Hospital, Perth, Western Australia, Australia. Received for publication July 31, 2013; accepted February 26, 2014.

Presented at IPRAS, February 27, 2013, Santiago, Chile, and PSC, April 25, 2013, Melbourne, Australia.

Copyright © 2014 The Authors. Published by Lippincott Williams & Wilkins on behalf of The American Society of Plastic Surgeons. PRS Global Open is a publication of the

American Society of Plastic Surgeons. This is an open-access article distributed under the terms of the Creative Commons Attribution-NonCommercial-NoDerivatives 3.0 License, where it is permissible to download and share the work provided it is properly cited. The work cannot be changed in any way or used commercially.

DOI: 10.1097/GOX.0000000000000089

(including seroma, infection, flap necrosis, and ultimately reconstructive failure).^{4,15} We have developed a technique to harvest a latissimus dorsi flap using standard breast surgery instruments and without requiring repositioning of the patient to cover the lower pole of prosthesis.

Breast reconstruction ideally involves the use of biological reconstruction for control and coverage of the lower pole of the breast prosthesis. This gives the security of fully vascularized coverage of the prosthesis in the event of skin necrosis. The scarless latissimus dorsi flap^{16,17} can harvest a significant proportion of the latissimus dorsi using standard breast surgery instruments and without requiring endoscopic instrumentation. It has the added significant advantage of no donor scar.

PATIENTS AND METHODS

The authors retrospectively reviewed a cohort of 20 consecutive patients with 30 scarless latissimus dorsi breast reconstructions between December 2009 and July 2012 compared with 20 consecutive patients with 27 traditional latissimus dorsi breast reconstructions. All data collected represent senior surgeon's experience (M.L.). Minimum follow-up was 15 months. Data comprised patient demographics, body mass index, immediate or delayed reconstruction, chemotherapy and radiotherapy status, cancer status, and associated medical risk factors (Table 1). Outcome measures included operative time, length of stay, and pain requirements of intraoperative and postoperative complications. Major complications include deep vein thrombosis, pulmonary embolism, and skin flap necrosis. Minor complications include seroma, hematoma, infection or cellulitis, reoperation, and implant loss. The objective aesthetic outcomes were evaluated by clinical photographic assessment by 5 plastic surgeons, 5 registrars, 5 nurses, and 5 laypersons using a global (excellent, good, fair, and poor) and subscale standardized assessment (Table 2).¹⁸⁻²⁰ Patient satisfaction was evaluated using the previously validated BREAST-Q questionnaire and scoring template.^{21,22}

Surgical Technique

Preoperatively the anterior border of latissimus dorsi is marked with the arm at 90° and adducting against resistance to elicit muscle activity. The infra-

Disclosure: *The authors have no financial interest to declare in relation to the content of this article. The Article Processing Charge was paid for by the authors.*

Table 1. Patient Demographics

	Age (yr) and BMI (mean)	Timing of Breast Reconstruction	Cancer Type	SNB/AXCL	Radiotherapy	Chemotherapy/Hormonal Treatment	Smoking
Scarless latissimus dorsi reconstruction (n = 30)	48.55	Bilateral/unilateral: 10:10	Prophylactic: 14	SNB +ve: 4	Pre-op: 1	Pre-op: 8	Active: 1
	BMI: 23.9	Immediate: 15	DCIS: 10	SNB -ve: 5	Post-op: 1	Post-op hormonal: 9	Ex-smoker: 6
		Delayed: 4	LCIS: 3	AXCL: 8			Nonsmoker: 13
Traditional latissimus dorsi reconstruction (n = 30)	50.35	Immediate/delay: 1	Multifocal: 3	SNB +ve: 3	Pre-op: 5	Pre-op: 11	Ex-smoker: 2
	BMI: 25.6	Bilateral/unilateral: 7:13	Prophylactic: 7	SNB -ve: 6	Post-op: 6	Post-op hormonal: 5	Nonsmoker: 18
		Immediate: 13	DCIS: 11	AXCL: 9			
		Delayed: 4	LCIS: 6				
		Immediate/delay: 3	Multifocal: 3				

All variables: not significant $P > 0.05$.
 AXCL, axillary clearance; BMI, body mass index; DCIS, ductal carcinoma insitu; LCIS, lobular carcinoma insitu; SNB, sentinel node biopsy.

Table 2. Cosmetic Assessment Tool

Subscale	0	1	2
Volume of breast mound	Marked discrepancy relative to contralateral side	Mild discrepancy relative to contralateral side	Symmetrical Volume
Contour (shape) of breast mound	Marked contour deformity or shape asymmetry	Mild contour deformity or shape asymmetry	Natural or symmetrical contour
Placement of breast mound	Marked displacement	Mild displacement	Symmetrical and aesthetic placement
Inframammary fold	Poorly defined/not identified	Defined but with asymmetry or lack of medial definition	Defined and symmetrical
Breast mound scars	Poor (hypertrophy, contracture)	Fair (wide scars, poor color but without hypertrophy, contracture)	Good (thin scars, good color match)

mammary fold and lateral border of the breast are identified and marked.

The patient is anesthetized in a supine position, with the ipsilateral arm free draped. The mastectomy is completed by the oncologic breast surgeon, preserving as much native skin as is oncologically safe. The latissimus dorsi harvest can be done through a periareolar incision or inferolateral submammary incision (Fig. 1).

The skin flaps are retracted laterally, and the anterior free edge of the latissimus dorsi is found superficially in the axilla at the level of the fourth costal cartilage. Often, the thick edge can be rolled and palpated. It is important not to go too deep until the edge is identified. With the free edge found, dissection proceeds superiorly and inferiorly to the level of the limits of the retractor. It is important to try and keep as much lateral wall of the mastectomy cavity intact. This dissection is performed with 19-cm Tebbetts fiber optic SS retractor, long forceps, and simple long diathermy pencil. The assistant is on the contralateral side to the surgeon to provide adequate retraction and visualization (Figs. 2 and 3).

Dissection then advances dorsally freeing as much tissue as possible and dissecting the length of the tendon to its insertion. Blunt dissection is performed around the tendon using the index finger. At this stage, it is important to identify the superior edge of latissimus dorsi as it turns caudal to the scap-

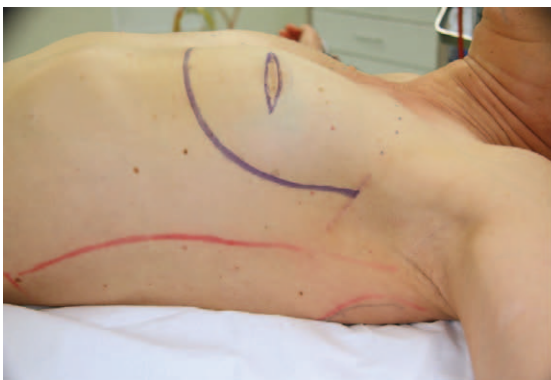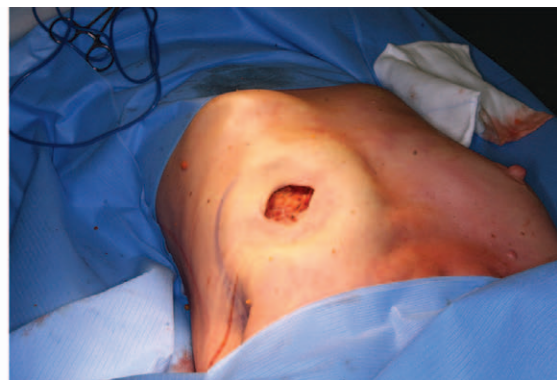ula. Adequate flap dimensions can be raised to the limits of the Tebbetts retractor (Fig. 4).

The ventral surface can then be safely dissected. Caudally, there are often few vessels, and this is an easy plan of dissection. It is easier to proceed further medially in the ventral plane than in the dorsal plane; this gains an extra few centimeters of flap. The inferior scapula fat pad, in the triangle of auscultation above latissimus dorsi, is a critical landmark as the thoracodorsal vascular axis is superior to this point and this is the landmark for superior to inferior division of the muscle.

The latissimus dorsi is then released from the superior edge at the triangle of auscultation to as far inferiorly as can be reached by the retractor. The yield is usually around 25×15 cm paddle. Once the muscle paddle is freed inferiorly, it can be used to provide counter traction while dissecting superiorly to free the pedicle. The thoracodorsal vessels are now easily found and secured; the serratus branch is not usually ligated but can be ligated if more mobility is required. Similarly, the thoracodorsal nerve can be divided at this stage (Figs. 5 and 6).

The last procedure is division of the latissimus dorsi tendon, with the pedicle identified and secured; the tendon can be divided at the fibrous portion.

The muscle is now fully islanded and can be gently stretched across the midline. The pectoralis

**Fig. 1.** Patient positioning.

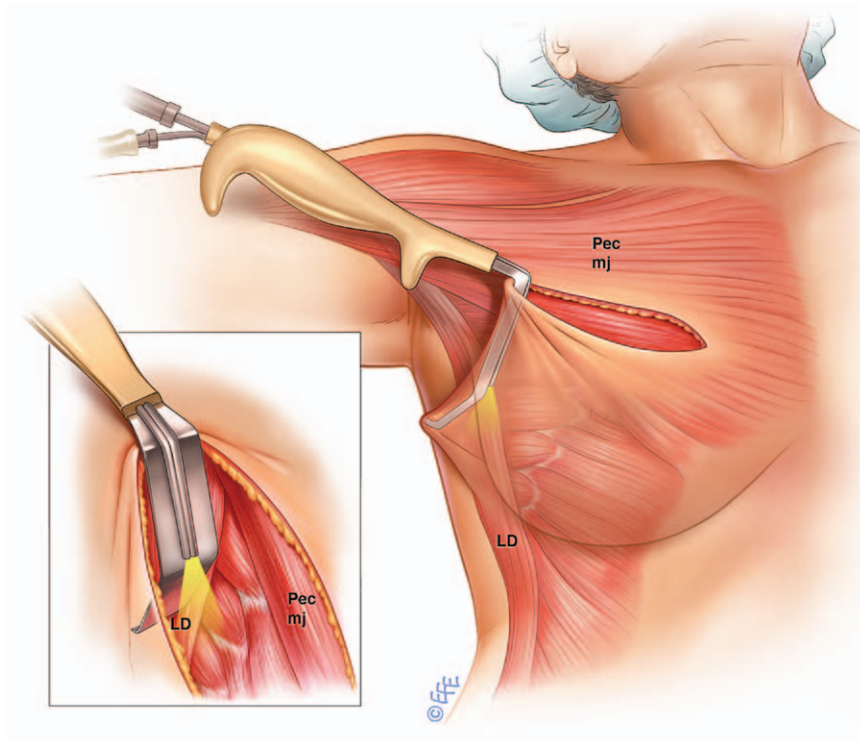


Fig. 2. Anterior border of latissimus dorsi.

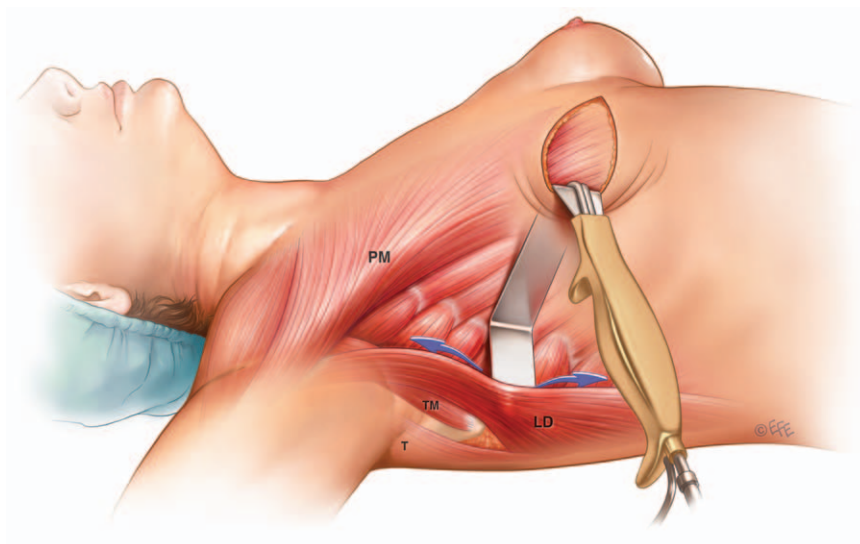


Fig. 3. Dissection procedure.

major is now elevated and can be fully released in the inferomedial quadrant. The latissimus dorsi is secured to the lower free edge of pectoralis major inferiorly and medially, extending to the inframammary fold with 1.0 vicryl sutures (Fig. 7). Antibiotic wash and insertion of the prosthesis can now be performed. Relatively tension free closure and immediate on table expansion to 75% volume is our usual practice. Single-stage direct-to-implant proce-

dures are also possible at this stage for complete skin- and nipple-sparing mastectomies. Care is taken to reconstruct the lateral wall with external bolster sutures, and the wound is closed over 2 suction drains (Fig. 8).

Statistical Analysis

Statistical comparisons were made with 2-tailed Fisher's exact test with a value of $P < 0.05$.

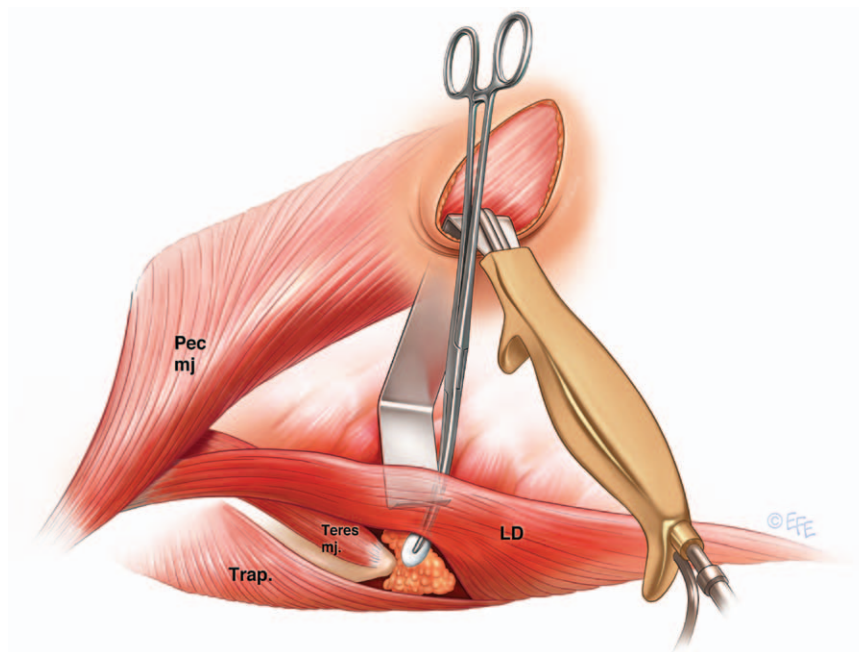


Fig. 4. Critical landmark.

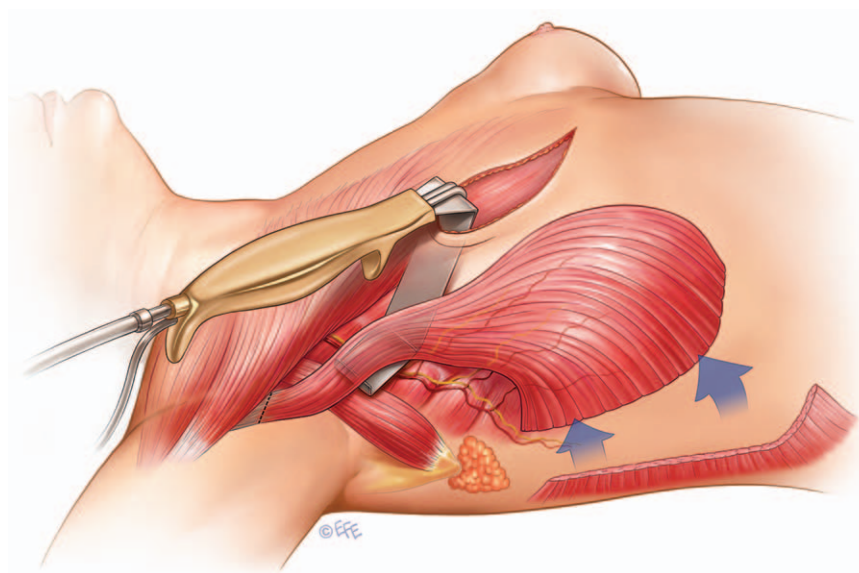


Fig. 5. The flap is released inferiorly and medially.

RESULTS

Twenty patients with traditional latissimus dorsi breast reconstruction with 27 flaps were compared with 20 patients with scarless latissimus dorsi reconstruction with 30 flaps. Our data showed that these were a well-matched cohort of patients with respect to baseline demographics and breast cancer profile and treatment (Table 1). Minimum follow-up was 15 months.

The scarless latissimus dorsi breast reconstruction was equivalent to traditional latissimus breast re-

construction ($P = 0.12$) for both intraoperative pain requirements and postoperative patient-controlled analgesia. The intraoperative time was compared for both unilateral and bilateral reconstruction, with significantly reduced operative time for bilateral reconstruction of 1 hour ($P = 0.014$). Unilateral reconstruction showed a 10-minute reduction, which was not significant ($P = 0.40$).

Patient length of stay in hospital was reduced by 1½ days in the scarless latissimus dorsi reconstruction ($P = 0.013$). Complications occurred in both groups,

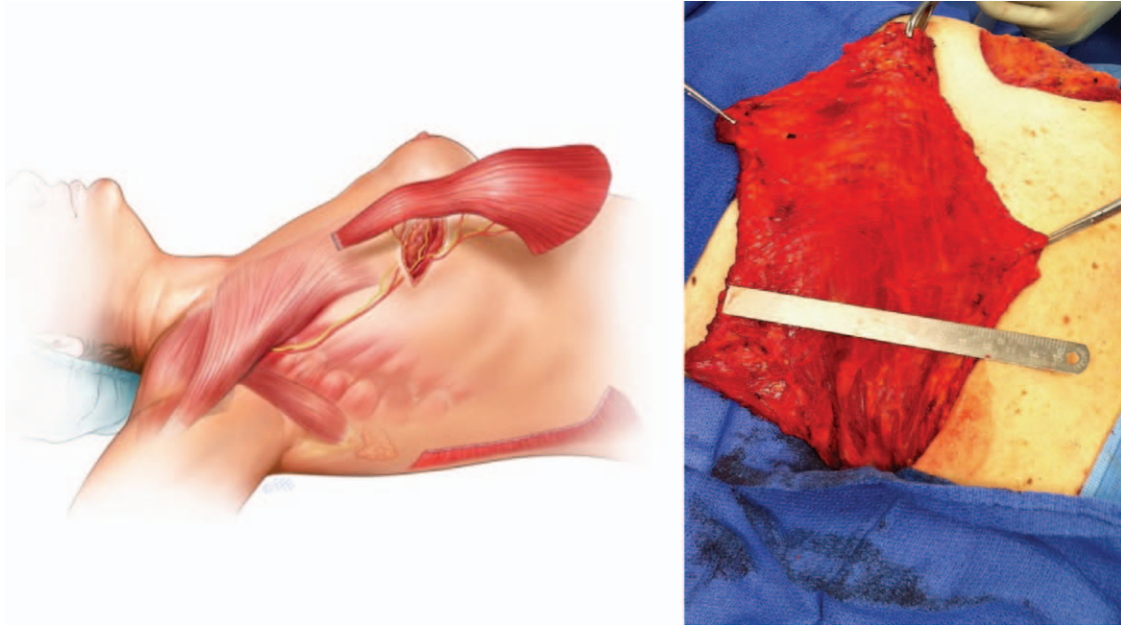


Fig. 6. The scarless latissimus dorsi harvested on the thoracodorsal vessels.

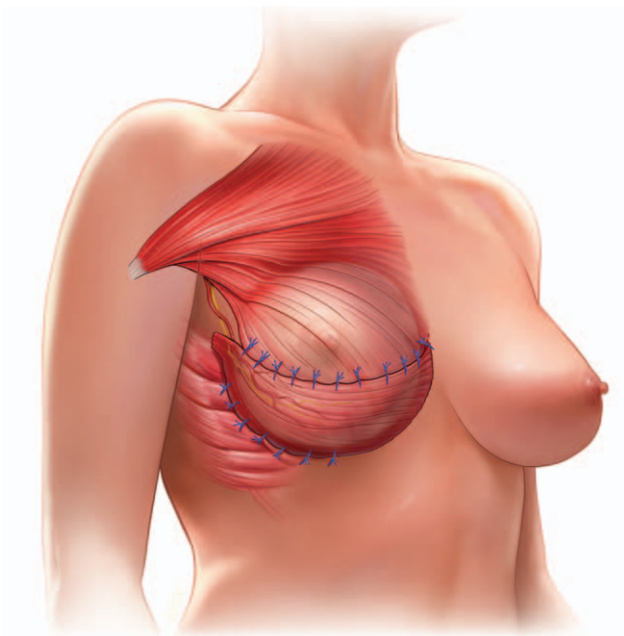


Fig. 7. The latissimus dorsi flap is sutured to inferior edge of pectoralis major and inframammary fold.

with an overall reduction of 25% in the scarless latissimus dorsi group predominately due to reduced seroma formation (Table 3). No cases of capsular contracture requiring reoperation were noted in either group. Native breast necrosis was managed conservatively in both cases (Fig. 9). Average implant size was 248cm³ and 417cm³ for traditional latissimus dorsi flap reconstruction and scarless latissimus dorsi flap reconstruction, respectively.

Patient satisfaction was assessed using the standardized Breast-Q questionnaire. Response rate was 80% for both groups. There was no significant difference in the Breast-Q scores for traditional and scarless latissimus dorsi flap reconstruction, which assesses the satisfaction of the breasts, outcome, and nipple reconstruction and reviews psychosocial, sexual, and physical domains of the patient ($P > 0.05$) (Fig. 10).

Aesthetic outcomes were assessed globally, with both groups reporting 77% good to excellent results ($P > 0.05$) (Fig. 11). The subscale analysis was statistically significant ($P = 0$) (Fig. 12) when individual assessment of the breast volume, contour, breast mound placement, inframammary fold, and breast scars was considered and tallied. These aesthetic results can be seen in Figs. 13 and 14.

DISCUSSION

All forms of breast reconstruction carry their own set of advantages and disadvantages; no technique is ideal in all cases. Universal goals in all forms of reconstructive surgery, however, should include, wherever possible, minimizing scars, shortening operative time, and decreasing hospital stay.²³⁻²⁷ This procedure has been described before^{16,17}; however, we hoped to describe clearly our personal technique that requires no endoscopic equipment and no patient repositioning and that can be performed using instruments available to all plastic surgeons around the world. This procedure enables us significant savings in operating time, with the reconstructive surgeon able to start operating with a second team after

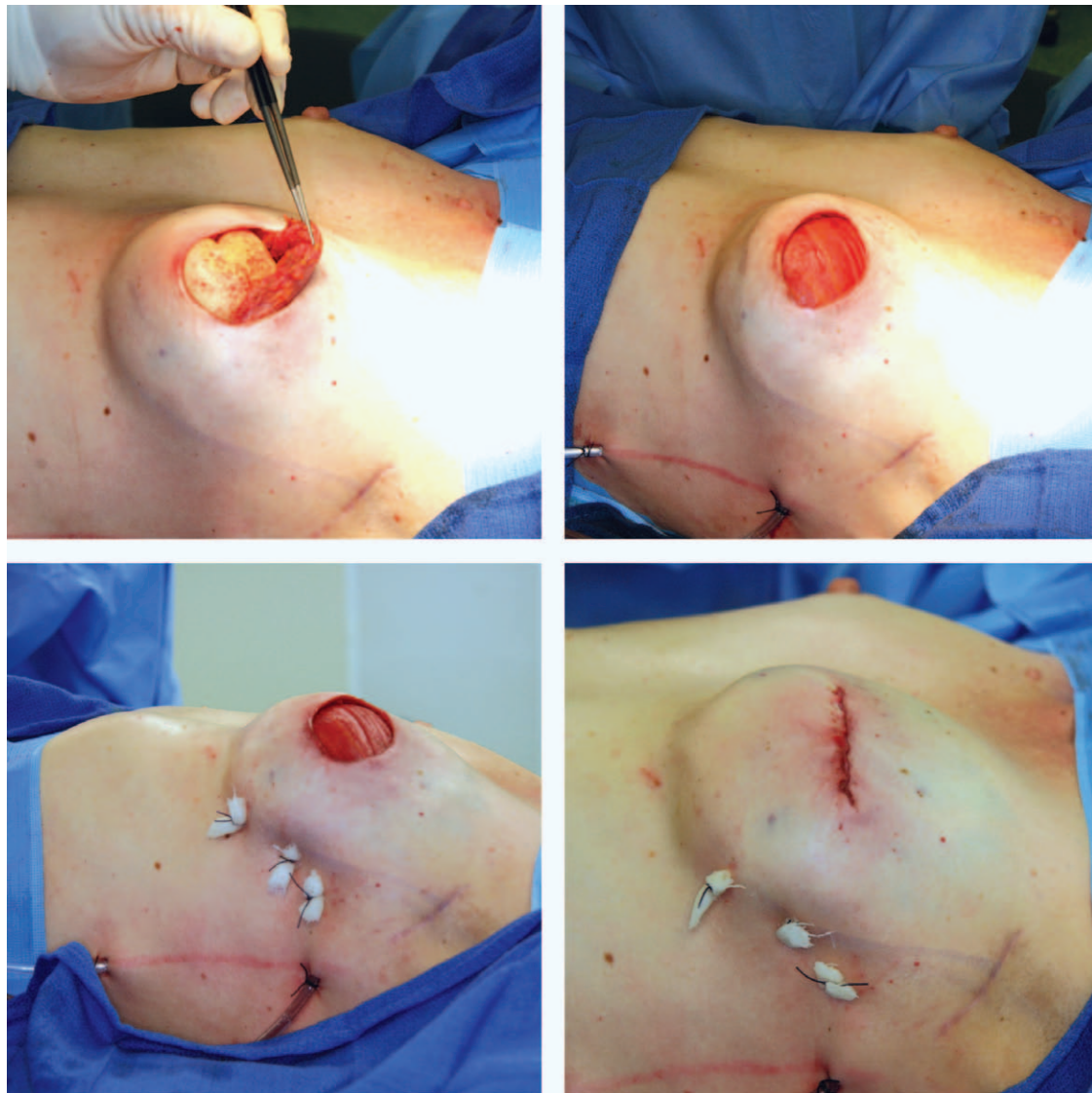


Fig. 8. Direct-to-implant/tissue expander 75% fill. External bolster sutures and 2 closed suction drains.

Table 3. Complications of Scarless Latissimus Dorsi Flap Reconstructions

Complications	Scarless Latissimus Dorsi Incidence (%)	Traditional Latissimus Dorsi Incidence (%)
Seroma	7 (23)	8 (30)
Infected seroma	—	3 (11)
Cellulitis	2 (6)	1 (3.7)
Native breast—dehiscence	1 (3)	—
Native breast—necrosis	2 (6)	—
Hematoma	1 (3)	—
Back wound—dehiscence/necrosis	—	2 (6.4)
Flap necrosis	—	1 (3.7)
Infected implant	—	3 (11)
Total	13 (43)	18 (67)

completion of the first side. Also there are no added risks in turning an anesthetized patient prone. We have also demonstrated a significant reduction in the length of hospital stay, which reduces costs.

Today, importing large skin paddles from the abdomen or back is often not necessary due to the extended oncologically sound preservation of native breast skin. When used, skin paddles from these sites often have significant color mismatch and can produce a less than ideal aesthetic result. Today, we can also use the power of tissue expansion to grow more skin, particularly when the lower pole is covered with well-vascularized tissue. We believe that the avoidance of an imported skin paddle apart from the area of the nipple-areolar complex will give a better long-

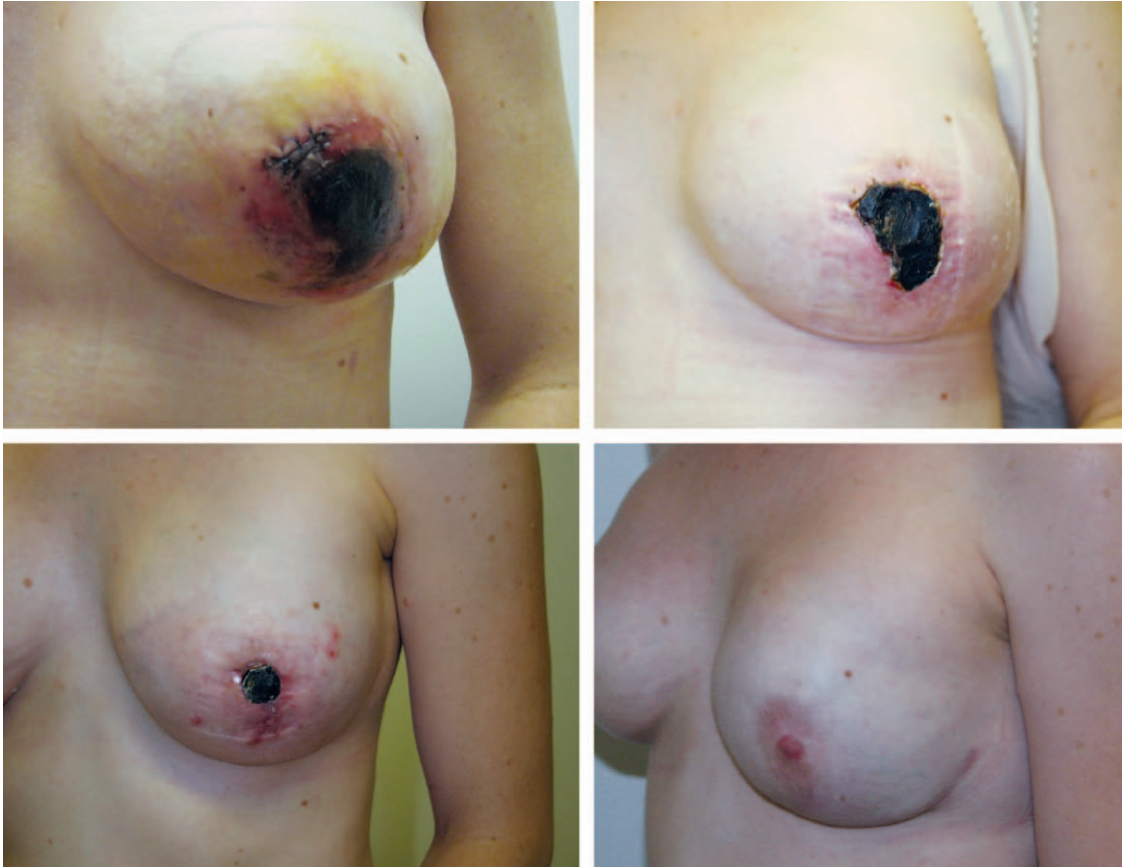


Fig. 9. Patient with scarless latissimus dorsi with overlying skin necrosis safely managed nonoperatively with excellent result.

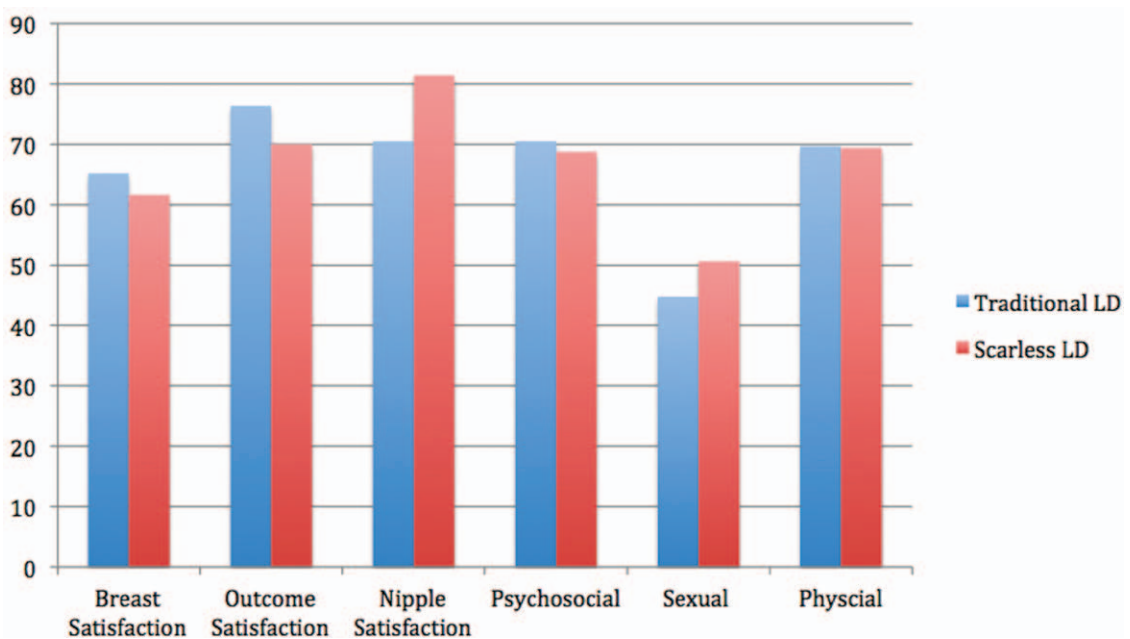


Fig. 10. Breast-Q questionnaire results.

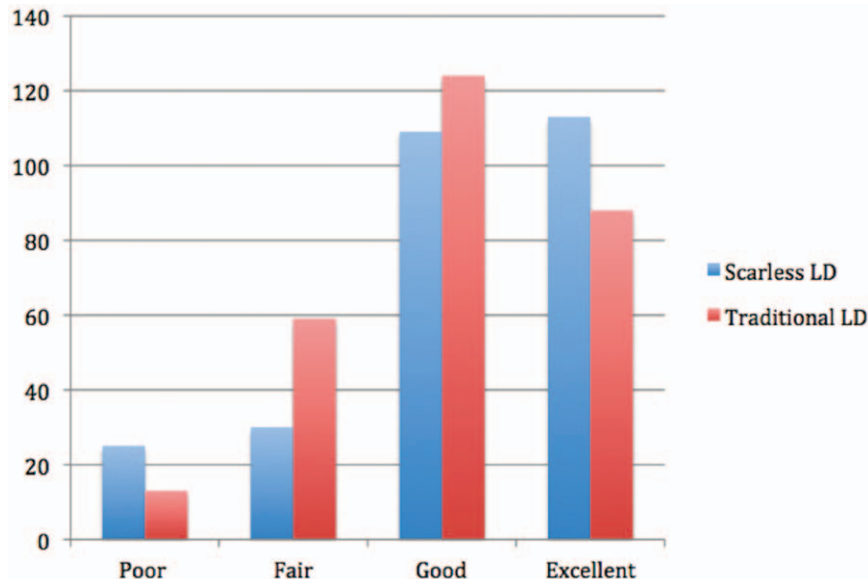


Fig. 11. Overall aesthetic assessment.

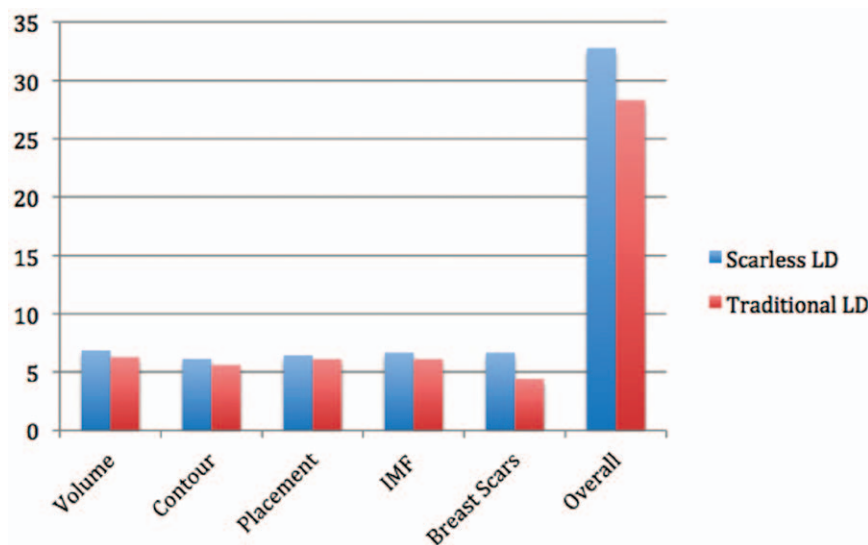


Fig. 12. Aesthetic assessment subscale analysis ($P = 0$).

term result. The “scarless” latissimus dorsi allows this with no unsightly scar but enough laxity in the lower pole to allow faster and more predictable tissue expansion or even direct-to-implant coverage.

In this study, we did not formally assess function or deformity of the back. Only part of the muscle is taken in this technique, and future refinements may allow preservation of tendon and nerve function to the residual muscle. Anecdotally, the scarless group was certainly in no way more functionally compromised than the traditional group. The scarless group obviously had no scars, but some patients did have a minor residual contour deformity. In all cases, this was significantly less than that of the patients with

the traditional flap. Formal physical therapy assessments of long-term function will be the subject of further studies.

We expected to encounter an overall decrease in pain in the scarless group, but this was not significantly different in the 2 groups. Longer term follow-up may show a decrease in the incidence of longer term chronic pain sometimes seen in latissimus dorsi flap donor sites.

One valid criticism of the technique is the lack of the ability to monitor the flap in traditional ways. It was certainly a dilemma when developing the technique but on balance it was felt that the extremely low risk of flap compromise was outweighed by the

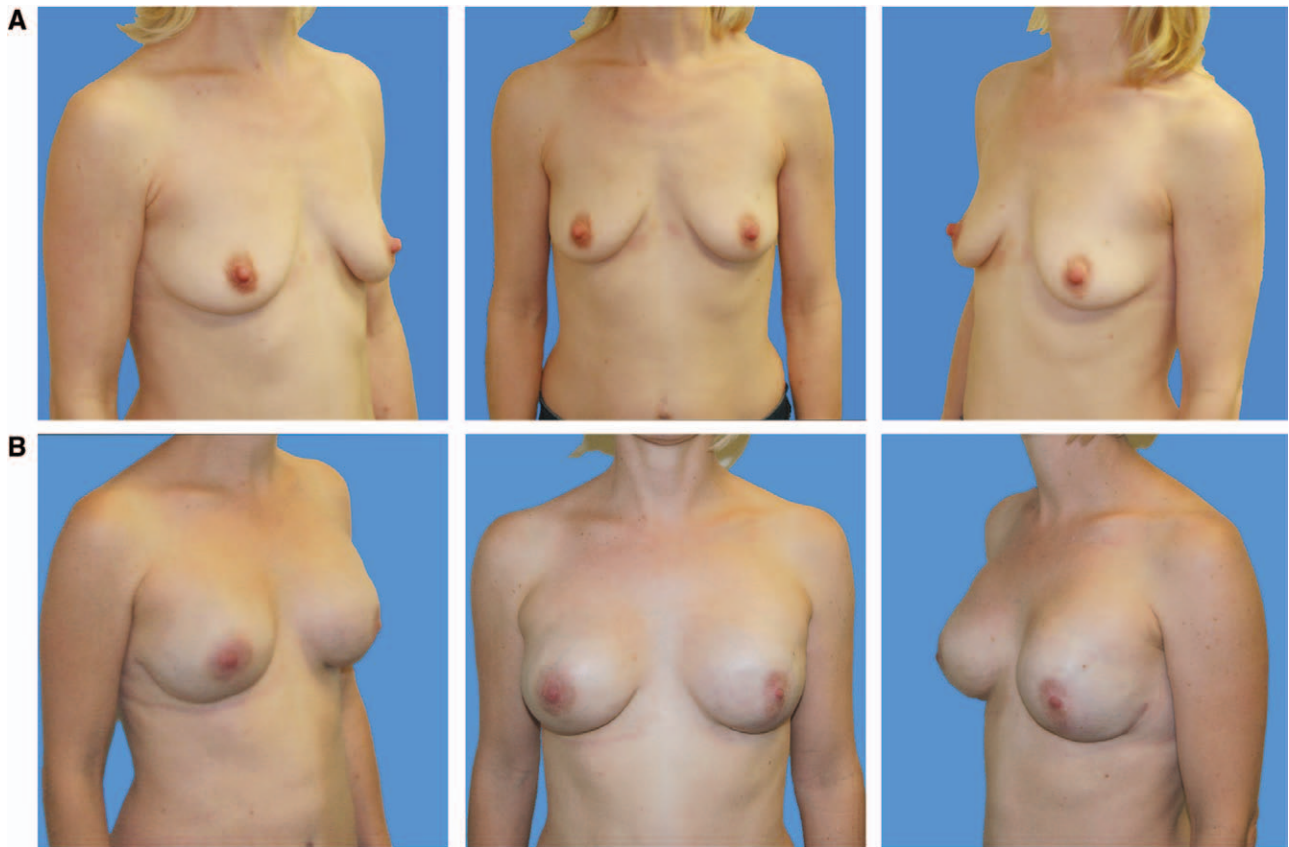

Fig. 13. Preoperative (A) and postoperative (B) views of the patient with native skin necrosis.

benefits of no scar, shorter operative time, and no repositioning. There are many examples of buried flaps in the plastic surgery literature: hemifacial atrophy, lymphedema surgery, omental flaps, and pressure sore reconstruction—to name a few. In this study, all 2-stage cases showed viable muscle at the time of implant exchange, and none of the direct-to-implant single stages showed any clinical signs that would suggest vascular flap compromise. The flap is fully islanded and can be stretched significantly across the midline, and so the inset is under very little tension. If using a tissue expander, the device can be left minimally filled if there is any concern. The flap is monitored clinically, that is, its swelling and tissue turgor. If one suspected vascular compromise postoperative, we would suggest duplex Doppler ultrasound evaluation to look for blood flow in the muscle; this has the added advantage of assessing for hematoma or seroma.

We see the great advantage in this technique for bilateral prophylactic mastectomy in young BRCA-positive women. We know that prophylactic mastectomy reduces lifetime cancer risk by 90%.²⁸ However, there are barriers to undertaking this surgery. The diagnosis of BRCA gene mutation is invariably made at an age and time when relationships are in an early

stage and body image is crucial. Patients' decision to undergo a potentially lifesaving procedure can be easier if the procedure has no donor-site scars and can be done in a single stage through only a mastectomy or inframammary incision.

Submuscular tissue expansion evolved in an era of delayed breast reconstruction. It has the advantage of no donor scar and avoids the need for unsightly skin paddles. In the era of immediate reconstruction, however, there are disadvantages. First, dissection to strip serratus anterior off the chest wall ribs inferolaterally is difficult and often produces significant postoperative pain. Second, due to tightness and fragility of this lower pole coverage, rapid expansion cannot be done, often resulting in a wrinkled redundant skin in the ptotic breast. Third, due to the tightness of the lower pole, tissue expanders can be a little unpredictable. Expanders tend to migrate high and even rotate. If the expander is not fully submuscular, the final implant often shows rippling.

Scarless latissimus dorsi avoids many of these problems. The dissection required to provide lower pole muscular cover avoids the painful periosteal stripping associated with serratus anterior harvest, and tissue expanders or implants can be directly placed at the time of mastectomy and rapidly

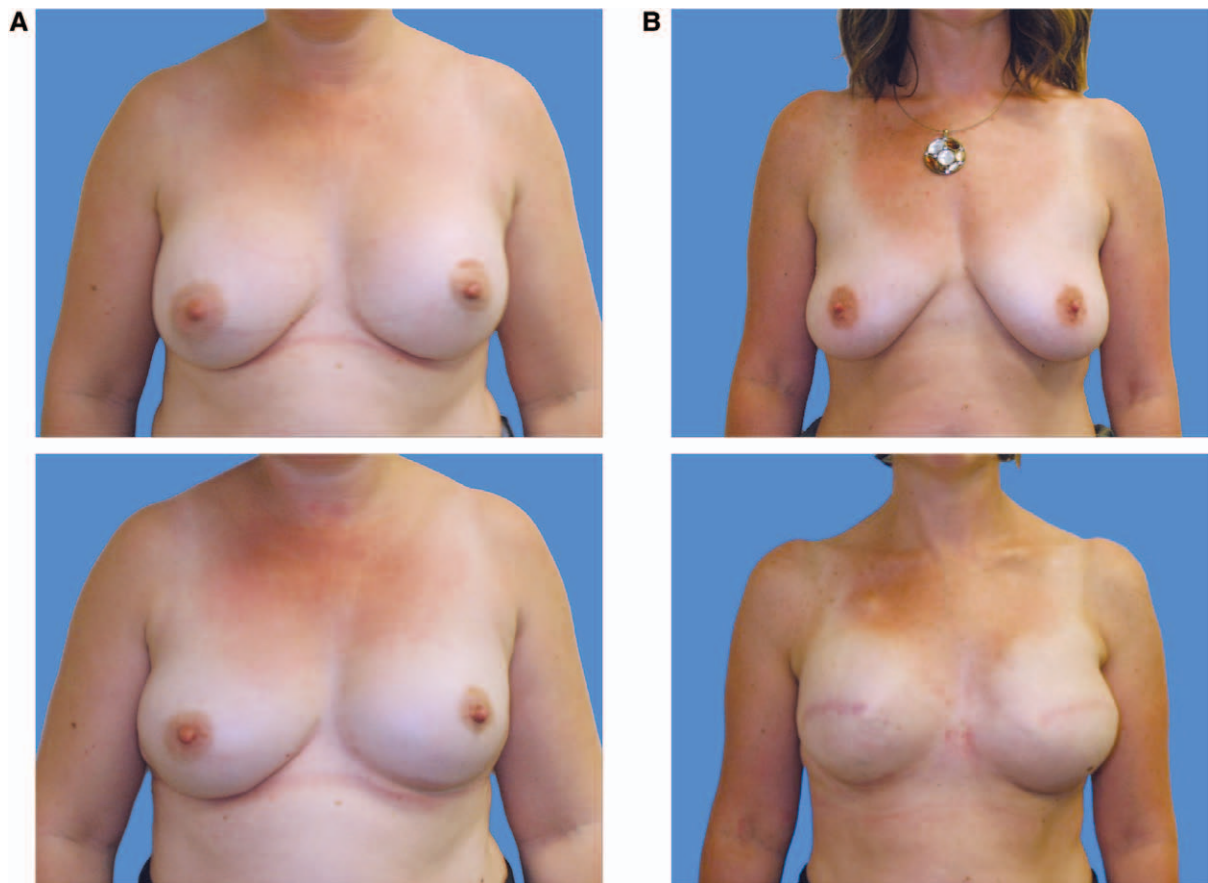


Fig. 14. Preoperative and postoperative views. A, Skin- and nipple-sparing mastectomy and scarless latissimus dorsi flap reconstruction. B, Skin-sparing mastectomy and bilateral scarless latissimus dorsi flap reconstruction.

expanded in a more controlled manner due to the loose lower pole.

The recent advent of biologic ADM reconstructions has flooded the breast reconstruction market with the distinct advantage of no donor-site morbidity. It seems to be the “quick fix” of breast reconstruction and is an attractive option in bilateral reconstruction, especially in young and athletic women. The use of ADM, however, can be disastrous if the ADM becomes exposed or infected, and this may lead to reconstructive failure. Drains are often required for long periods of time due to increased seroma and infection rates. There is also an unknown entity found in ADMs that is variously referred to as the “red breast syndrome”²⁸ and the additional unknown future risks of xenografts and allografts. ADM devices can be expensive and difficult to access in many parts of the world due to regulations covering the importation of human and animal tissue. We feel that this technique can be performed in parts of the world without access to ADM devices, mainly to provide “lifeboat” protection against the unpredictable risk of mastectomy skin necrosis.

It also shares many of the attractive advantages of ADMs, namely, no donor scar, less operative time than traditional flaps, and shorter hospital stay. This study compared scarless latissimus dorsi reconstruction with traditional myocutaneous reconstruction, but in reality scarless latissimus dorsi reconstruction is probably closer in technique to ADM reconstruction. A future study comparing these 2 techniques more formally along similar lines would be helpful in demonstrating the advantages or disadvantages particularly in terms of function.

One of the patients in this series suffered some native skin necrosis as shown in Figure 9. The oncologic breast surgeon inadvertently holed out when thinning the tissue behind the nipple. Having a fully vascularized muscle coverage over the entire implant allowed me (M.L.) the confidence to treat this conservatively. Over 4 weeks, the eschar healed and lifted with a very acceptable final result. She had a small nipple graft and tattoo to complete her breast reconstruction. We would not have had this confidence for conservative management with an ADM deep to this necrotic skin.

Reconstruction with ADMs does have a number of advantages such as no donor-site morbidity, good control of the infra mammary fold, and lower pole projection. However, it is expensive, with the products ranging from \$1500 USD to \$3500 USD each (significantly more expensive in Australia). It is therefore not surprising to see many alternatives now being produced at much cheaper cost. Despite this laudable trend, the fundamental risks of infection and exposure remain, and not infrequently, their development is beyond the control of the reconstructive surgeon.

The scarless latissimus dorsi technique has no added cost apart from the implant or the tissue expander and fully covers the entire implant, allowing significant peace of mind should an area of native skin necrosis become apparent postoperatively.

Longer operating times and rolling an anesthetized patient also have inherent risks. These include venous thrombosis, pulmonary embolus, pressure sores, nerve injury, and airway compromise, not to mention surgeon fatigue.

During the standard bilateral latissimus dorsi harvest for breast reconstruction, the reconstructive surgeon can start operating only after both the mastectomies have been completed. This significantly adds to operating time, and the reconstructive surgeon is unproductive for some hours. By contrast, the scarless latissimus dorsi harvest allows reconstruction to begin after the first mastectomy is completed, and thus it significantly reduces operating time and therefore risk.

CONCLUSIONS

This method of breast reconstruction is relatively time effective, requires no patient repositioning, and uses standard breast instruments. It is safe, reducing the risk of exposed prosthesis if native skin necrosis occurs. It requires no endoscopic equipment, expensive ADM, or special training, and it is versatile, able to be used in both immediate and delayed reconstructions, and has particular advantage in prophylactic mastectomy and reconstruction.

Mark Lee, MBBS, FRACS

Suite 317/25 McCourt Street
Subiaco
Western Australia 6008
Australia

E-mail: mark@markleoplasticsurgeon.com.au

REFERENCES

1. Trabulsky PP, Anthony JP, Mathes SJ. Changing trends in postmastectomy breast reconstruction: a 13-year experience. *Plast Reconstr Surg.* 1994;93:1418–1427.
2. Rosson GD, Magarakis M, Shridharani SM, et al. A review of the surgical management of breast cancer: plastic reconstructive techniques and timing implications. *Ann Surg Oncol.* 2010;17:1890–1900.
3. Salgarello M, Visconti G, Barone-Adesi L. Fat grafting and breast reconstruction with implant: another option for irradiated breast cancer patients. *Plast Reconstr Surg.* 2012;129:317–329.
4. Kim JYS, Davila AA, Persing S, et al. A meta-analysis of human acellular dermis and submuscular tissue expander reconstruction. *Plast Reconstr Surg.* 2012;129:28–41.
5. Nahabedian MY. Acellular dermal matrices in primary breast reconstruction: principles, concepts and indications. *Plast Reconstr Surg.* 2012;130(5 Suppl 2):44S–53S.
6. Breuning KH, Cowell AS. Inferolateral AlloDerm hammock for implant coverage in breast reconstruction. *Ann Plast Surg.* 2007;59:250–255.
7. Spear SL, Parikh PM, Reisin E, et al. Acellular dermis assisted breast reconstruction. *Aesthetic Plast Surg.* 2008;32:418–425.
8. Nahabedian MY, Mesbahi AN. Breast reconstruction with tissue expanders and implants. In: Nabadedian MY, ed. *Cosmetic and Reconstructive Breast Surgery.* London: Elsevier; 2009:1–90.
9. Salzberg AC. Non-expansive immediate breast reconstruction using acellular tissue matrix graft (Alloderm). *Ann Plast Surg.* 2006;57:1–5.
10. Zienowicz RJ, Karacaoglu E. Implant-based breast reconstruction with allograft. *Plast Reconstr Surg.* 2007;120:373–381.
11. Namnoum JD. Expander/implant reconstruction with AlloDerm: recent experience. *Plast Reconstr Surg.* 2009;124:387–394.
12. Salzberg CA, Ashikari AY, Koch RM, et al. An 8-year experience of direct-to-implant immediate breast reconstruction using human acellular dermal matrix (AlloDerm). *Plast Reconstr Surg.* 2011;127:514–524.
13. Israeli R, Feingold RS. Acellular dermal matrix in breast reconstruction in the setting of radiotherapy. *Aesthet Surg J.* 2011;31(7 Suppl):51S–64S.
14. Martin L, O’Dohnohue JM, Horgan K, et al; Association of Breast Surgery and the British Association of Plastic, Reconstructive and Aesthetic Surgeons. Acellular dermal matrix (ADM) assisted breast reconstruction procedures. Joint Guidelines from the Association of Breast Surgery and the British Association of Plastic, Reconstructive and Aesthetic Surgeons. *Eur J Surg Oncol.* 2013;39:425–429.
15. Israeli R. Complications of acellular dermal matrices in breast surgery. *Plast Reconstr Surg.* 2012;130(5 Suppl 2):159S–172S.
16. Bittar SM, Sisto J, Gill K. Single-stage breast reconstruction with the anterior approach latissimus dorsi flap and permanent implants. *Plast Reconstr Surg.* 2012;129:1062–1070.
17. Elliott LF, Ghazi BH, Otterburn DM. The scarless latissimus dorsi flap for full muscle coverage in device-based immediate breast reconstruction: an autologous alternative to acellular dermal matrix. *Plast Reconstr Surg.* 2011;128:71–79.
18. Tsoukas LI, Fentiman IS. Breast compliance: a new method for evaluation of cosmetic outcome after conservative treatment of early breast cancer. *Breast Cancer Res Treat.* 1990;15:185–190.
19. Garbay JR, Rietjens M, Petit JY. The aesthetic results for breast reconstruction in 323 women after amputation of the breast for cancer. *J Gynaecol Obstet Biol Reprod (Paris)* 1992;21:405–412.
20. Lwery JC, Wilkins EG, Kuzon WM, et al. Evaluation of aesthetic results in breast reconstruction: an analysis of reliability. *Ann Plast Surg.* 1996;36:601–606.

21. Pusic AK, Scott A, Klok J, et al. Development of a new patient reported outcome measure for breast surgery: the Breast-Q. *Plast Reconstr Surg*. 2009;124:345–353.
22. Memorial Sloan-Kettering Cancer Centre. The Breast-Q. Available at: <https://webcore.mskcc.org/breastq/get-bq.html>. Accessed November 13, 2012.
23. Tansini I. Sopra il mio nuovo processo di amputazione della mammella. *Gaz Med Ital*. 1906;57:141.
24. D'Este S. La technique de l'amputation de la mamelle pour carcinome mammaire. *Rev Chir*. 1912;45:194.
25. Bostwick J III, Carlson GW. Reconstruction of the breast. *Surg Oncol Clin N Am*. 1997;6:71–89.
26. Schneider WJ, Hill HL Jr, Brown RG. Latissimus dorsi myocutaneous flap for breast reconstruction. *Br J Plast Surg*. 1977;30:277–281.
27. Bostwick J III, Vasconez LO, Jurkiewicz MJ. Breast reconstruction after a radical mastectomy. *Plast Reconstr Surg*. 1978;61:682–693.
28. Kim JY, Connor CM. Focus on technique: two stage implant-based breast reconstruction. *Plast Recon Surg*. 2012;130(5 Suppl 2):104S–115S.
29. Hartmann LC, Schaid DJ, Woods JE, et al. The efficacy of bilateral mastectomy in women with a family history of breast cancer. *N Engl J Med*. 1999;340:77–84.