

Successful treatment of occult hyperadrenocorticism with mitotane but not trilostane in a dog

Su-Min Park¹ | Kyeong-Bo Kim¹ | Woo-Jin Song²  | Hwa-Young Youn¹ 

¹Laboratory of Veterinary Internal Medicine, Department of Veterinary Clinical Science, College of Veterinary Medicine, Seoul National University, Seoul, Republic of Korea

²Laboratory of Veterinary Internal Medicine, College of Veterinary Medicine, Jeju National University, Jeju, Republic of Korea

Correspondence

Hwa-Young Youn, Laboratory of Veterinary Internal Medicine, Department of Veterinary Clinical Science, College of Veterinary Medicine, Seoul National University, Seoul 08826, Republic of Korea.
Email: hyoun@snu.ac.kr

Woo-Jin Song, Laboratory of Veterinary Internal Medicine, College of Veterinary Medicine, Jeju National University, Jeju 63243, Republic of Korea.
Email: ssong@jejunu.ac.kr

Funding information

Seoul National University R&DB Foundation, Grant/Award Number: 550-20190060; Research Institute of Veterinary Science in College of Veterinary Medicine, Jeju National University

Abstract

Background: Occult (or atypical) hyperadrenocorticism (HAC) shows clinical signs and laboratory abnormalities similar to classic hyperadrenocorticism, but normal signs in routine screening tests such as the corticotropin (ACTH) stimulation test and low-dose dexamethasone suppression test (LDDST). Here, we describe a case of occult HAC in a Yorkshire terrier treated with mitotane.

Case: An 11-year-old spayed female presented to the Veterinary Teaching Hospital of Seoul National University because of respiratory distress symptoms, polyphagia, and polydipsia, suggestive of HAC. In abdominal sonography, enlargement of the caudal pole of the left adrenal gland was found, but the cortisol level of post-ACTH stimulation test was below the cut-off value, and LDDST was negative. To finalise the diagnosis of occult HAC, 17-hydroxyprogesterone (17-OHP) was examined. The concentrations of 17-OHP (pre- and post-ACTH stimulation) were found to be elevated. As occult HAC was highly suspected, we prescribed trilostane for trial therapy. At first, the clinical signs improved, but they later worsened. We changed medication as trilostane to mitotane, and the symptoms were relieved after mitotane administration.

Conclusion: This is a unique case of occult HAC in which the response to mitotane was better than trilostane.

KEYWORDS

17-hydroxyprogesterone, mitotane, occult hyperadrenocorticism

1 | INTRODUCTION

Hyperadrenocorticism (HAC), known as Cushing's disease, is one of the most common endocrine diseases in dogs. Based on the symptoms, such as polydipsia or polyuria with excellent appetite, poor hair coat, symmetrical alopecia, a "pot-bellied" appearance, and panting, the corticotropin (ACTH) stimulation test, low-dose dexamethasone

suppression test (LDDST), and the urinary corticoid:creatinine ratio are implemented for diagnosis (Behrend et al., 2013). Dogs with occult (or atypical) HAC show clinical signs and laboratory abnormalities similar to classic HAC, but normal signs in routine screening tests such as the ACTH stimulation test and LDDST. Sex hormone-producing adrenal tumours are associated with occult HAC and sex hormones induce these symptoms (Syme et al., 2001). Here, we describe a case of occult HAC in a Yorkshire terrier treated with mitotane.

Su-Min Park and Kyeong-Bo Kim contributed equally to this work.

This is an open access article under the terms of the Creative Commons Attribution-NonCommercial-NoDerivs License, which permits use and distribution in any medium, provided the original work is properly cited, the use is non-commercial and no modifications or adaptations are made.

© 2021 The Authors *Veterinary Medicine and Science* Published by John Wiley & Sons Ltd

2 | CASE REPORT

An 11-year-old spayed female Yorkshire terrier presented to the hospital because of respiratory distress symptoms, polyphagia and polydipsia. In the local animal hospital, an LDDST was performed. Cortisol levels 4 and 8 hr after the LDDST were under 0.5 µg/dl, so the possibility of classical HAC was evaluated as low.

On physical examination, the dog's systolic blood pressure was 160 mmHg (reference range, 90–140 mmHg) by the Doppler method. In the bilateral eyes, neovascularisation and severe scleral hyperaemia were found. There were no significant findings in auscultation. Complete blood counts and serum chemistry were within the normal limits. In thoracic radiography and echocardiography, there were no remarkable findings that could cause respiratory distress. To determine the cause of the respiratory problem, fluoroscopy was conducted, and a partial pharyngeal collapse was found when the dog was panting. However, we thought that the pharyngeal collapse was not the primary factor of symptoms and that it was only the aggravating factor. In abdominal radiography, liver enlargement was found and increased volume of liver parenchyma was found in abdominal sonography. Also, the cranial pole of the left adrenal gland was 0.41 cm and the caudal pole was 0.67 cm, which reached the criteria for adrenal gland enlargement (median width in Yorkshire terrier, 0.43 cm) (Choi et al., 2011). Otherwise, the right adrenal gland pole sizes were 0.42 cm and 0.38 cm, respectively (Figure 1). To initially determine HAC, an ACTH stimulation test was performed. Pre-ACTH stimulation cortisol was 2.95 µg/dl and post-ACTH stimulation cortisol was 18.7 µg/dl, which is under the diagnostic cut-off value for HAC (>24 µg/dl) (Bennaim et al., 2019). Also, 17-hydroxyprogesterone (17-OHP) was measured to identify occult HAC. The concentration of basal 17-OHP was 0.94 ng/ml, and post-ACTH 17-OHP was 2.36 ng/ml, which is considered positive for HAC (>1.32 ng/ml) (Ristic et al., 2002). Thus, we diagnosed the dog with occult HAC.

At first, trilostane was prescribed at 0.75–1 mg/kg per oral (PO) q 12 hr. The symptoms were slightly improved. However, after a month, the respiratory distress, polyphagia and polydipsia

symptoms of the dog were worse than before trilostane administration. Therefore, we changed medication to mitotane. Mitotane was prescribed at 25 mg kg⁻¹ day⁻¹ for 4 days followed by a 3-day rest period. After induction, polydipsia improved, but respiratory distress and polyphagia were still present. Therefore, the mitotane dosage was increased to 40 mg kg⁻¹ day⁻¹ for 5 days followed by a 2-day rest period. After the second induction, an ACTH stimulation test was again performed and post-ACTH stimulation cortisol was 3.38 µg/dl. There was no electrolyte imbalance. The dog's symptoms of respiratory distress, polyphagia and polydipsia were relieved. Therefore, 30 mg kg⁻¹ week⁻¹ mitotane was prescribed for maintenance. Unfortunately, after a month, the dog showed acute ataxia with severe pain, and was diagnosed as cervical intervertebral disc disease. And the dog was lost to follow up.

3 | DISCUSSION

HAC is one of the most common endocrine diseases in dogs. It is caused by primarily pituitary-dependent HAC (PDH), followed by adrenal tumours. However, in occult HAC, PDH and adrenal tumours cause the disease at equal rates (Greco, 2007). In this case, although additional diagnostic approaches for the enlarged caudal pole of the left adrenal gland were not performed, an adrenal tumour was highly suspected judging from the fact that only one side of the adrenal gland was enlarged.

Occult HAC is similar to classic HAC in many respects, like clinical signs and laboratory abnormalities, despite normal serum cortisol levels. This is possible because of excessive sex hormones, especially 17-OHP. 17-OHP has intrinsic glucocorticoid activity and increases the bioavailability of cortisol by displacing it from cortisol-binding protein (Benitah et al., 2005). Diagnostic tools, such as the ACTH stimulation test and LDDST, are not applicable for occult HAC, as they are likely to be normal. There was an effort to utilise the LDDST by extending the test (from 8 to 12 hr), although the results were not different between healthy dogs and dogs with occult HAC (Fowler

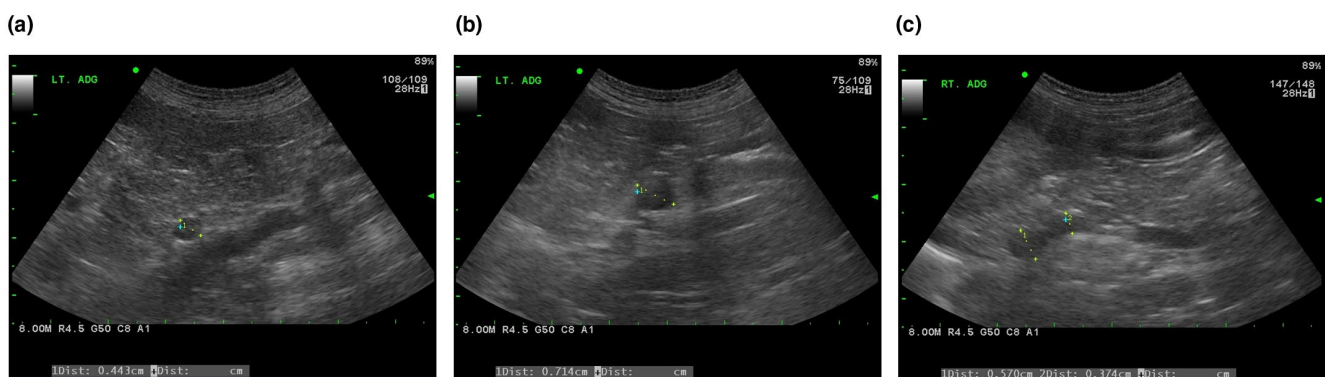


FIGURE 1 Cranial pole of left adrenal gland was measured as 0.443 cm (a) and caudal pole was measured as 0.714 cm (b), which is over the adrenomegaly criteria. On the contrary, Cranial and caudal pole of right adrenal gland was measured as 0.570 cm and 0.374 cm (c), which is under the adrenomegaly criteria

et al., 2017). Therefore, measurements of sex hormone concentrations before and after the ACTH stimulation test are useful for diagnosing occult HAC. Diagnosis is based on the increased concentration of one or more adrenal sex hormones (androstenedione, oestradiol, progesterone or 17-OHP) pre- and post-ACTH stimulation (Scott-Moncrieff, 2009). Although the authors could not measure all of these sex hormones, it was not difficult for us to diagnose this dog as occult HAC by history taking (clinical signs), physical examination, and the serum concentrations of basal and post-ACTH stimulation 17-OHP.

Trilostane and low-dose mitotane have been recommended to treat occult HAC (Nelson & Couto, 2014). Trilostane is a competitive inhibitor of 3- β -hydroxysteroid dehydrogenase, which mediates the conversion of pregnenolone to progesterone in the adrenal gland (Ristic et al., 2002). There are several reports of treatment of occult HAC with trilostane and the successful control of clinical signs (Kim et al., 2012; Lee et al., 2020). However, although it is not published, there is a report that some dogs have recurring clinical signs of HAC while taking trilostane (Oliver, 2007). Consistent with the report, the dog in this study deteriorated after trilostane administration. Insufficient trilostane dosage might be the reason. However, in general, when the trilostane dosage is not sufficient, the symptoms are partially resolved and very rarely worsen. Therefore, we have prescribed mitotane which is an adrenocorticolytic agent targeting the adrenal zonae reticularis and fasciculata (Behrend & Kennis, 2010), instead of trilostane. Although the dog could not be followed up for long term, it was obvious that mitotane but not trilostane was fully effective in this case.

4 | CONCLUSION

To the authors' knowledge, it is the first case report of an occult HAC dog that worsened after administering trilostane, and showed better response to mitotane.

ACKNOWLEDGEMENTS

We are very thankful to the BK21 PLUS Program for Creative Veterinary Science Research. This study was funded by Seoul National University R&DB Foundation (550-20190060), and by Research Institute of Veterinary Science in College of Veterinary Medicine, Jeju National University.

CONFLICT OF INTEREST

There are no conflicts of interest to report.

AUTHOR CONTRIBUTION

Sumin Park: Data curation; Data curation; Investigation; Investigation; Project administration; Writing-original draft. **Kyeong-Bo Kim:** Data curation; Formal analysis; Writing-original draft. **Woo-Jin Song:**

Conceptualization; Supervision. **Hwa-Young Youn:** Funding acquisition; Supervision.

PEER REVIEW

The peer review history for this article is available at <https://publons.com/publon/10.1002/vms3.482>.

DATA AVAILABILITY STATEMENT

Data available on request from the authors.

ORCID

Woo-Jin Song  <https://orcid.org/0000-0002-9195-551X>

Hwa-Young Youn  <https://orcid.org/0000-0002-0283-1348>

REFERENCES

- Behrend, E. N., & Kennis, R. (2010). Atypical Cushing's syndrome in dogs: Arguments for and against. *The Veterinary Clinics of North America. Small Animal Practice*, 40, 285–296. <https://doi.org/10.1016/j.cvsm.2009.11.002>
- Behrend, E. N., Kooistra, H. S., Nelson, R., Reusch, C. E., & Scott-Moncrieff, J. C. (2013). Diagnosis of spontaneous canine hyperadrenocorticism: 2012 ACVIM consensus statement (small animal). *Journal of Veterinary Internal Medicine*, 27, 1292–1304. <https://doi.org/10.1111/jvim.12192>
- Benitah, N., Feldman, E. C., Kass, P. H., & Nelson, R. W. (2005). Evaluation of serum 17-hydroxyprogesterone concentration after administration of ACTH in dogs with hyperadrenocorticism. *Journal of the American Veterinary Medical Association*, 227, 1095–1101. <https://doi.org/10.2460/javma.2005.227.1095>
- Bennaïm, M., Shiel, R. E., & Mooney, C. T. (2019). Diagnosis of spontaneous hyperadrenocorticism in dogs. Part 2: Adrenal function testing and differentiating tests. *The Veterinary Journal*, 252, 105343. <https://doi.org/10.1016/j.tvjl.2019.105343>
- Choi, J., Kim, H., & Yoon, J. (2011). Ultrasonographic adrenal gland measurements in clinically normal small breed dogs and comparison with pituitary-dependent hyperadrenocorticism. *Journal of Veterinary Medical Science*, 73, 985–989. <https://doi.org/10.1292/jvms.10-0479>
- Fowler, K. M., Frank, L. A., Morandi, F., & Whittemore, J. C. (2017). Extended low-dose dexamethasone suppression test for diagnosis of atypical Cushing's syndrome in dogs. *Domestic Animal Endocrinology*, 60, 25–30. <https://doi.org/10.1016/j.domaniend.2017.03.002>
- Greco, D. S. (2007). Hyperadrenocorticism associated with sex steroid excess. *Clinical Techniques in Small Animal Practice*, 22, 12–17. <https://doi.org/10.1053/j.ctsap.2007.02.002>
- Kim, J.-H., Hong, Y.-J., Lee, H.-S., Park, J. H., & Park, C. (2012). Atypical Cushing's syndrome associated with sex steroids excess in a dog. *Journal of Veterinary Clinics*, 29, 400–403.
- Lee, G.-W., Yoo, C.-R., Lee, D., & Park, H. M. (2020). Favorable outcome of pheochromocytoma in a dog with atypical Cushing's syndrome and diabetes mellitus following medical treatment: A case report. *BMC Veterinary Research*, 16, 3. <https://doi.org/10.1186/s12917-019-2225-x>
- Nelson, R. W., & Couto, C. G. (2014). *Small animal internal medicine* (5th ed.). Elsevier/Mosby.
- Oliver, J. (2007). Steroid profiles in the diagnosis of canine adrenal disorders. In *Proc 25th Ann Vet Med Forum* (pp. 471–473).
- Ristic, J. M. E., Ramsey, I. K., Heath, F. M., Evans, H. J., & Herrtage, M. E. (2002). The use of 17-hydroxyprogesterone in the diagnosis of canine hyperadrenocorticism. *Journal of Veterinary Internal*

- Medicine*, 16, 433–439. <https://doi.org/10.1111/j.1939-1676.2002.tb01261.x>
- Scott-Moncrieff, J. (2009). Atypical and subclinical hyperadrenocorticism. In J. Bonagura, & D. Twedt (Eds.), *Kirk's current veterinary therapy XIV* (pp. 219–224). Saunders.
- Syme, H. M., Scott-Moncrieff, J. C., Treadwell, N. G., Thompson, M. F., Snyder, P. W., White, M. R., & Oliver, J. W. (2001). Hyperadrenocorticism associated with excessive sex hormone production by an adrenocortical tumor in two dogs. *Journal of the American Veterinary Medical Association*, 219, 1725–1728. <https://doi.org/10.2460/javma.2001.219.1725>

How to cite this article: Park S-M, Kim K-B, Song W-J, Youn H-Y. Successful treatment of occult hyperadrenocorticism with mitotane but not trilostane in a dog. *Vet Med Sci*. 2021;7:1150–1153. <https://doi.org/10.1002/vms3.482>