

In Situ Aortic Reconstruction with Femoral Vein after Post-EVAR Infection

Hong Kyung Shin, Jae Young Park, and Taeseung Lee

Department of Surgery, Seoul National University Bundang Hospital, Seongnam, Korea

A 78-year-old male presented with early gastric cancer and a 5.5 cm-sized infrarenal abdominal aortic aneurysm, detected during regular screening. Endovascular aneurysm repair (EVAR) was performed first, followed by laparoscopic distal gastrectomy. After gastrectomy, the patient underwent computed tomography (CT) scan due to persistent fever, which showed increased perigraft fluid collection around the right iliac limb graft. Echocardiography also revealed mitral valve vegetation, consistent with infective endocarditis. Despite intensive antibiotic treatment, the patient had persistent fever and showed fluid extension to the psoas muscle on CT scan. On the 49th post operative day (POD) after EVAR, stent graft explantation and aortic reconstruction with the left superficial femoral vein was performed. Ligation of the right iliac artery for infection control and simultaneous femoro-femoral bypass was also performed. The patient was discharged on the 46th POD after graft removal without any events

Key Words: Abdominal aortic aneurysm, Endovascular procedures, Prosthesis-related infections, Femoral vein

Received March 1, 2014

Revised April 15, 2014

Accepted April 20, 2014

Corresponding author: Taeseung Lee
Department of Surgery, Seoul National University Bundang Hospital, 82 Gumi-ro 173beon-gil, Bundang-gu, Seongnam 463-707, Korea
Tel: 82-31-787-7092
Fax: 82-31-787-4078
E-mail: tslee@snuh.org
Conflict of interest: None.

Copyright © 2014, The Korean Society for Vascular Surgery

This is an Open Access article distributed under the terms of the Creative Commons Attribution Non-Commercial License (<http://creativecommons.org/licenses/by-nc/3.0>) which permits unrestricted non-commercial use, distribution, and reproduction in any medium, provided the original work is properly cited.

Vasc Spec Int 2014;30(2):72-75 • <http://dx.doi.org/10.5758/vsi.2014.30.2.72>

INTRODUCTION

Stent graft infection following endovascular aortic aneurysm repair (EVAR) is rare, but is a serious complication related with significant morbidity and high mortality. It was first reported in 1993 and has a reported incidence of 0.43%-0.50% based on case reports and small sized studies [1,2].

We present a novel technique for treatment of infected graft after EVAR by in situ aorto-uniiliac reconstruction using a single superficial femoral vein (SFV), with ligation of the infected right iliac artery and crossover femoro-femoral bypass using a prosthetic graft.

CASE

A 78-year-old male patient was admitted with a 5.5 cm-

sized infrarenal abdominal aortic aneurysm (AAA) and early gastric cancer (EGC) detected during routine screening. His medical history revealed hypertension controlled by medications and he had no previous operation history. After evaluation of the gastric cancer, treatment for AAA was performed first, followed by staged treatment for EGC. EVAR was performed with a GORE EXCLUDER AAA Endoprosthesis (WL Gore & Associates, Newark, DE, USA) and distal laparoscopic gastrectomy was performed 12 days later. Both procedures were uneventful.

On the 18th post operative day (POD) from gastrectomy, the patient presented with intermittent fever and lower abdominal tenderness. Laboratory results showed leukocytosis ($18.5 \times 10^9/L$) and increased C-reactive protein levels (13.4 mg/dL). Blood cultures revealed *methicillin-sensitive Staphylococcus aureus* bacteremia. The patient underwent computed tomography (CT) scan that revealed

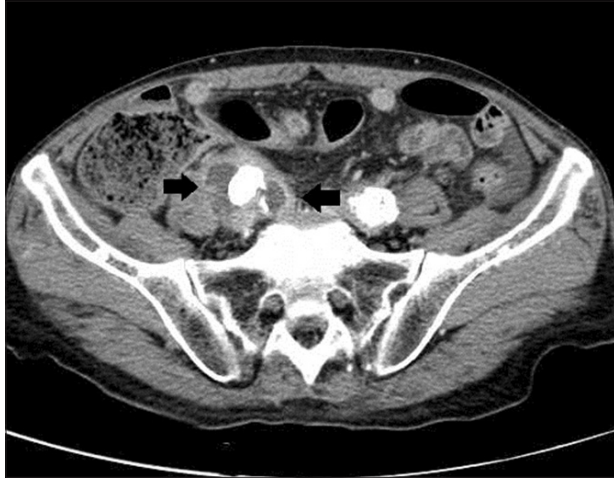

Fig. 1. Perigraft fluid collection on post-endovascular aneurysm repair computed tomography.

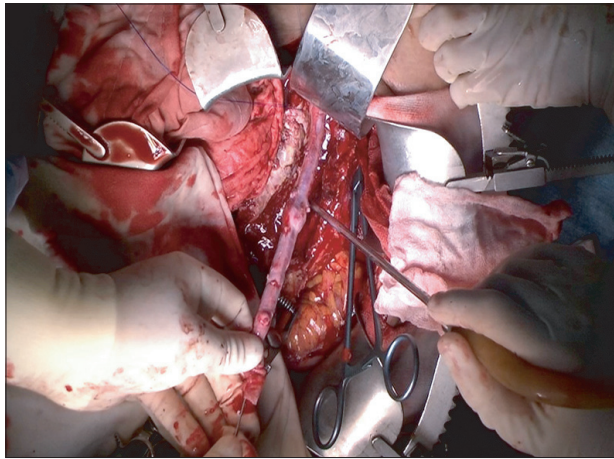


Fig. 2. Valvulotomy after proximal aortic flow restoration.

perigraft fluid collection around the right iliac limb graft (Fig. 1). Echocardiography also revealed mitral valve vegetation which was consistent with infective endocarditis. After consultation with the infectious disease specialist, stent graft removal was decided in order to control the bacteremia. Stent graft removal was performed on the 49th POD after EVAR (37th POD after gastrectomy) with in situ reconstruction using autogenous SFV.

1) Procedure details

After long midline laparotomy, exploration of the abdominal cavity revealed relatively normal findings without evidence of severe adhesion, despite having undergone a previous operation. Through a retroperitoneal approach, the previous aneurysm sac was exposed and opened. The stent graft, aneurysm sac and periaortic tissues were excised

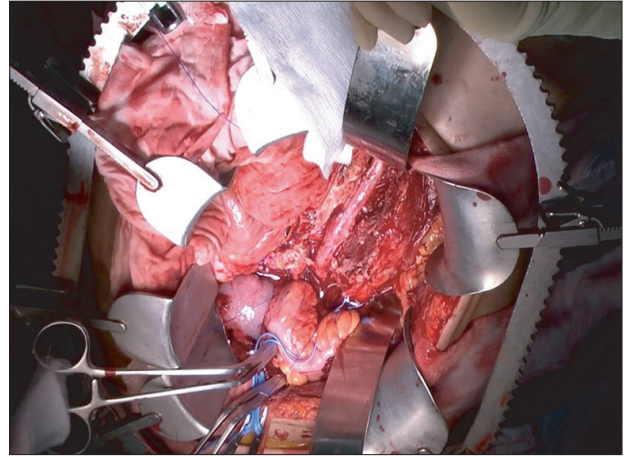


Fig. 3. Aorto-uniiliac reconstruction with superficial femoral vein.

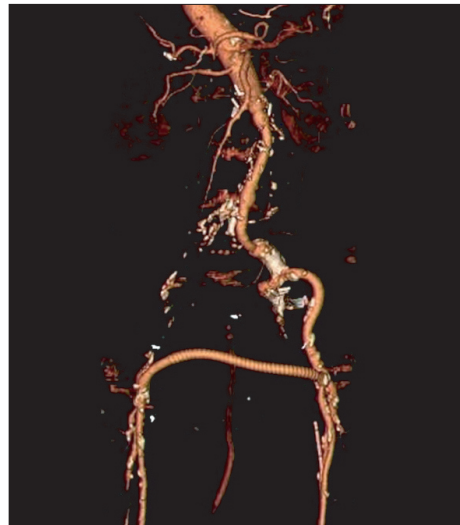


Fig. 4. Follow-up computed tomography after aortic reconstruction.

entirely. Fortunately, the graft could be removed easily without the need for modified explantation techniques such as the use of a syringe [3]. The proximal right iliac artery was resected and the stump was ligated in a double-layered fashion. A drain was inserted along the right iliac artery territory to prevent progression of infection in the right groin sinus.

After removal of the infected stent graft, the left SFV was harvested for a length of 20 cm with preservation of the great saphenous vein. The venous graft was anastomosed end-to-end with the aorta in a non-reversed fashion. After restoration of aortic flow, valvulotomy was performed (Fig. 2-3). The graft was sutured distally with the left common iliac artery in end-to-end fashion. Finally, crossover femoro-femoral bypass with a polytetrafluoroethylene (PTFE) graft

was performed with subcutaneous tunneling through a clean subcutaneous fat layer. Bilateral pulses were strongly palpable after the whole procedure.

There were no immediate complications during hospital stay. One month after reconstruction, laboratory findings were normalized and there was no further bacterial growth in blood cultures, while CT scan and echocardiography showed improved state of infection and infective endocarditis (Fig. 4). After management of residual infection and infective endocarditis, the patient was discharged on the 46th POD after aortic reconstruction without any complications.

DISCUSSION

Aortic stent graft infection is a rare complication after EVAR and there is no consensus to guide management. Although graft infection in open aneurysm repair is well described, literature in the endovascular area is still lacking.

In many reports, management of aortic stent graft infection consists of removal of the graft with debridement of infected tissue, arterial reconstruction, and antibiotic therapy. The ideal procedure for reconstruction is still controversial and there are two treatment options: in situ reconstruction versus extra-anatomical bypass. In infected aortic aneurysm cases, a high incidence of complications from extra-anatomical bypass with prosthetic graft have been reported, such as aortic stump disruption and risk of reinfection [4,5].

There are three graft options for in situ reconstruction: rifampin-soaked synthetic grafts, autogenous vein grafts and cryopreserved allografts. In some cases, rifampin soaked synthetic grafts have been shown to be effective for aortic graft infections with low virulent and limited *S. epidermidis* [6]. The well-known disadvantages of cryopreserved human tissue include the risk of calcification, dilatation or even rupture of the graft [7].

Aortic reconstruction using the femoral vein for graft infection was first reported 20 years ago, but there have been few large series reported since then [8]. Daenens et al. [9] reported a 10-year experience of autogenous SFV

reconstruction in 49 cases with a 5-year survival rate of 60%. Ehsan and Gibbons [10] reported a 10-year experience of 48 arterial reconstructions with femoro-popliteal veins (24 of them being aortic). In their report, primary patency was 75% and 62%, and secondary patency 93% and 91% at 2 and 5 years, respectively.

In situ reconstruction after resection of abdominal aneurysms using the SFV has emerged as a feasible treatment and has shown promising results [11-16]. However, most of the reconstructions require bilateral vein harvesting, which is related with increased operation time and postoperative complications. On the other hand, there are only few reports about in situ reconstruction of infected aortic aneurysms performed with unilateral vein harvesting.

In this case we performed an aorto-uniiliac bypass using a single SFV. The use of only a single SFV has been reported before [12]. However, instead of using an inverted-Y aorto-biiliac graft, as most reports suggested, we performed an aorto-uniiliac, non-reversed, end-to-end anastomosis of the left common iliac artery, with right common iliac ligation and femoro-femoral bypass. Several reports that used a single SFV have pointed out the limitation of short length of the autogenous vein graft. However this technique did not need a longer graft length since an aorto-uniiliac end-to-end anastomosis was performed.

To our knowledge, this surgical procedure has not been reported before, especially for stent graft infection. Considering the higher trunk to limb ratio in Asian individuals, this technique may be more suitable.

On the other hand, additional procedures and the use of a prosthetic graft for femoro-femoral bypass increases the chance of complications and infection. For the prevention of graft infection, it is important to keep with the necessary measures to separate the operation field between the infected and clean fields.

Aortic reconstruction using a single femoral vein for post-EVAR infection has several advantages, like other in situ reconstructions. By using an autogenous vein graft, we can expect lower infection rates and good patency. Unlike other reported reconstruction techniques using the SFV, this procedure can be performed with a single SFV.

REFERENCES

- 1) Fiorani P, Speziale F, Calisti A, Misuraca M, Zaccagnini D, Rizzo L, et al. Endovascular graft infection: preliminary results of an international enquiry. *J Endovasc Ther* 2003;10:919-927.
- 2) Ducasse E, Calisti A, Speziale F, Rizzo L, Misuraca M, Fiorani P. Aortoiliac stent graft infection: current problems and management. *Ann Vasc Surg* 2004;18:521-526.
- 3) Koning OH, Hinnen JW, van Baalen JM. Technique for safe removal of an aortic endograft with suprarenal fixation. *J Vasc Surg* 2006;43:855-857.

- 4) Taylor LM Jr, Deitz DM, McConnell DB, Porter JM. Treatment of infected abdominal aneurysms by extra-anatomic bypass, aneurysm excision, and drainage. *Am J Surg* 1988; 155:655-658.
- 5) Seeger JM, Pretus HA, Welborn MB, Ozaki CK, Flynn TC, Huber TS. Long-term outcome after treatment of aortic graft infection with staged extra-anatomic bypass grafting and aortic graft removal. *J Vasc Surg* 2000;32: 451-459; discussion 460-461.
- 6) Bandyk DF, Novotney ML, Back MR, Johnson BL, Schmacht DC. Expanded application of in situ replacement for prosthetic graft infection. *J Vasc Surg* 2001;34:411-419; discussion 419-420.
- 7) Noel AA, Gloviczki P, Cherry KJ Jr, Safi H, Goldstone J, Morasch MD, et al; United States Cryopreserved Aortic Allograft Registry. Abdominal aortic reconstruction in infected fields: early results of the United States cryopreserved aortic allograft registry. *J Vasc Surg* 2002;35:847-852.
- 8) Nevelsteen A, Lacroix H, Suy R. Autogenous reconstruction with the lower extremity deep veins: an alternative treatment of prosthetic infection after reconstructive surgery for aortoiliac disease. *J Vasc Surg* 1995; 22:129-134.
- 9) Daenens K, Fourneau I, Nevelsteen A. Ten-year experience in autogenous reconstruction with the femoral vein in the treatment of aortofemoral prosthetic infection. *Eur J Vasc Endovasc Surg* 2003;25:240-245.
- 10) Ehsan O, Gibbons CP. A 10-year experience of using femoro-popliteal vein for re-vascularisation in graft and arterial infections. *Eur J Vasc Endovasc Surg* 2009;38:172-179.
- 11) Gibbons CP, Ferguson CJ, Fligelstone LJ, Edwards K. Experience with femoro-popliteal vein as a conduit for vascular reconstruction in infected fields. *Eur J Vasc Endovasc Surg* 2003; 25:424-431.
- 12) Gibbons CP, Ferguson CJ, Edwards K, Roberts DE, Osman H. Use of superficial femoropopliteal vein for suprainguinal arterial reconstruction in the presence of infection. *Br J Surg* 2000;87:771-776.
- 13) Clagett GP, Valentine RJ, Hagino RT. Autogenous aortoiliac/femoral reconstruction from superficial femoral-popliteal veins: feasibility and durability. *J Vasc Surg* 1997;25:255-266; discussion 267-270.
- 14) Cardozo MA, Frankini AD, Bonamico TP. Use of superficial femoral vein in the treatment of infected aorto-iliofemoral prosthetic grafts. *Cardiovasc Surg* 2002;10:304-310.
- 15) Benjamin ME, Cohn EJ Jr, Purtil WA, Hanna DJ, Lilly MP, Flinn WR. Arterial reconstruction with deep leg veins for the treatment of mycotic aneurysms. *J Vasc Surg* 1999;30:1004-1015.
- 16) Beck AW, Murphy EH, Hocking JA, Timaran CH, Arko FR, Clagett GP. Aortic reconstruction with femoral-popliteal vein: graft stenosis incidence, risk and reintervention. *J Vasc Surg* 2008;47:36-43; discussion 44.