



Gross Trunnion Failure in the Bipolar Hemiarthroplasty; Raising Concern about Short Trunnion: A Case Report

Kangbaek Kim, MD, Junpyo Lee, MD, Jeong Joon Yoo, MD, Hee Joong Kim, MD

Department of Orthopaedic Surgery, Seoul National University Hospital, Seoul, Korea

There have been some reports of gross trunnion failure (GTF) in total hip arthroplasty. Here, we report a case of GTF 19 years after bipolar hemiarthroplasty using a 28-mm head with a 14/16 taper bore. Compared to other GTF reports, the current case had some unusual aspects: bipolar hemiarthroplasty, 28-mm head, relatively late-onset, and no apparent findings of metallosis though a severe one was evident. A Computed tomography scout view provided valuable information in evaluating polyethylene, metal head, and neck inside the bipolar cup. The current report suggests a need for concern regarding short trunnion length which may be associated with GTF.

Key Words: Hip, Arthroplasty, Prosthesis failure

The head-and-neck modular system in a total hip arthroplasty implant allows surgeons to adjust soft tissue tension, offset, and leg length intraoperatively¹⁾. Despite the modular system's advantages, there is a risk for metal debris associated with the additional interface, leading to wear and early failure which is termed "trunnionosis"²⁾. It has been suggested that the mechanism of trunnionosis is related to micromotion and fretting on the connection system, followed by mechanically assisted crevice corrosion³⁾. There are many factors known to cause trunnionosis including the

taper design, the surface topography and roughness, femoral head size and length, and stem offset^{4,8)}. Porter et al.⁹⁾ reported that increased cases of trunnionosis have been attributed to a larger head and thinner taper than has been used previously. Though there are repeated reports of trunnionosis, reports of gross trunnion failure (GTF) are rare. In addition, most published reports have been focused on total hip arthroplasty. In the current study, we report the case of a patient with GTF 19 years after bipolar hemiarthroplasty using a 28-mm head with 14/16 taper bore.

CASE REPORT

In January 2000, a 47-year-old man whose body mass index (BMI) was 26 kg/m² had undergone bipolar hemiarthroplasty of the left hip for osteonecrosis of the femoral head at another institution. A Centrax bipolar prosthesis, Exeter head (28 mm; Stryker Orthopaedics, Mahwah, NJ, USA), and ABG I stem (Stryker Howmedica Osteonics, Mahwah, NJ, USA) implants were used. There were no complications and the left hip was symptom-free for approximately 19 years. The patient started began follow-up at the current institution in December 2012 and underwent total

Submitted: October 29, 2020 **1st revision:** November 12, 2020

Final acceptance: November 17, 2020

Address reprint request to

Hee Joong Kim, MD

(<https://orcid.org/0000-0002-3994-5672>)

Department of Orthopedic Surgery, Seoul National University Hospital, 101 Daehak-ro, Jongno-gu, Seoul 03080, Korea

TEL: +82-2-2072-2970 **FAX:** +82-2-764-2718

E-mail: oskim@snu.ac.kr

This is an Open Access article distributed under the terms of the Creative Commons Attribution Non-Commercial License (<http://creativecommons.org/licenses/by-nc/4.0>) which permits unrestricted non-commercial use, distribution, and reproduction in any medium, provided the original work is properly cited.

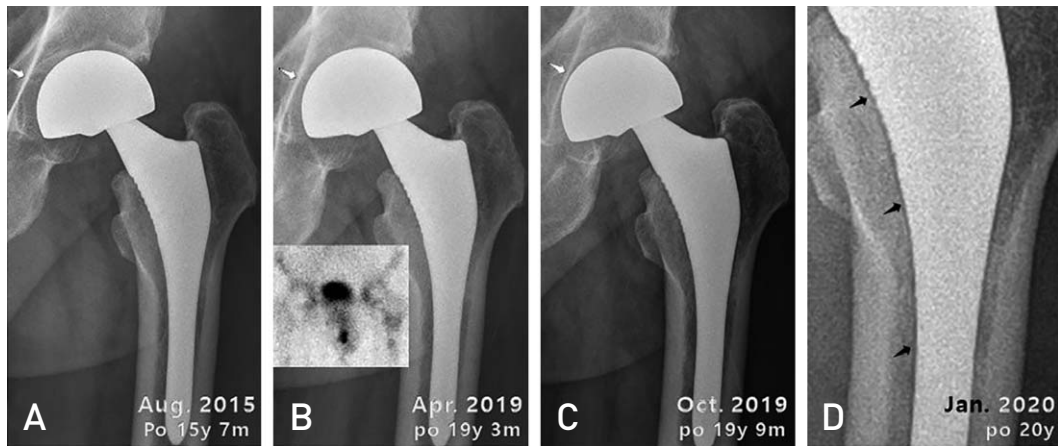


Fig. 1. Consecutive postoperative plain radiographs following thigh pain initially reported in January 2019. (A) Plain radiograph of contralateral side total hip arthroplasty. There was no symptom on the left side. (B) Migration of the bipolar cup (white arrows) and increased radioisotope uptake around the proximal half and the tip of the stem (inset) noticed in April 2019. (C) Rapid progression of the cup migration apparent in October 2019. (D) A fine radiolucent line along the medial margin of the stem (black arrows) detected in January 2020.

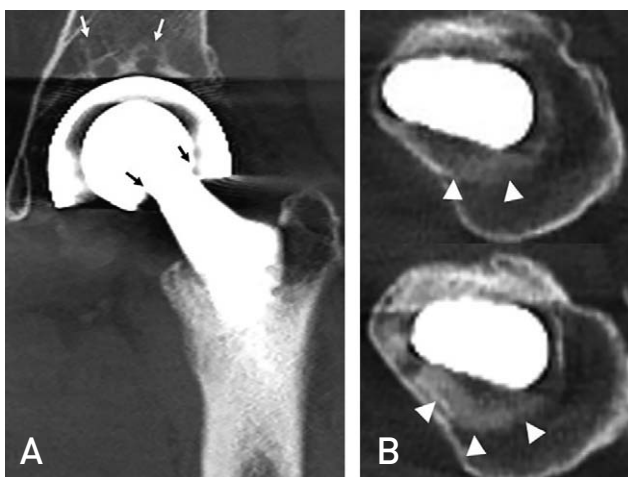


Fig. 2. No remarkable abnormalities aside from subchondral cystic changes in the acetabulum (white arrows) were initially recognized on computed tomography images in April 2019; however, the cone of the stem did not coincide with the head center (black arrows) (A), and marked sclerotic changes around the proximal stem were noted retrospectively (white arrowheads) (B).

hip arthroplasty of the right hip for osteonecrosis of the femoral head in May 2015. He visited the clinic with a complaint of left thigh pain without noise in early April 2019. Thus, left hip pain developed without any triggering event at 19 years and 2 months after hemiarthroplasty. Plain radiographs indicated mild superomedial migration of the bipolar cup compared with those taken four years earlier (Fig. 1A, B). Infection markers were negative in blood. Bone scintigraphy showed mildly increased uptake around the

proximal half and the tip of the stem (Fig. 1B). No abnormalities were initially recognized around the stem on computed tomography (CT) images, which revealed only mild subchondral cystic changes in the acetabulum (Fig. 2A). Thigh pain persisted even with non-steroidal anti-inflammatory agents treatment, and further migration of the bipolar cup was detected on radiographs 6 months later (Fig. 1C). Due to the relatively rapid migration of the bipolar cup, conversion to total hip arthroplasty was recommended, at which time the patient's BMI was 30 kg/m². Preoperative radiographs were taken three months later in January 2020 and demonstrated a fine radiolucent line along the medial margin of the stem (Fig. 1D). In revision surgery, the operation field was completely stained black, and the stem was easily removed (Fig. 3). The trunnion was destroyed entirely, and the base of the neck was indented deeply as a result of the impingement of the lower edge of the head bore (Fig. 3). Conversely, the polyethylene liner was relatively intact, though the inner bearing motion between the polyethylene liner and the metal head was not evaluated. The cancellous bone around the proximal portion of the stem and the greater trochanter were replaced by soft tissue containing metal debris. The replacement was so complete that only cortical bone remained after thorough curettage of the soft tissue. It was discovered that the proximal femur around the stem was sclerotic, not radiolucent on CT due to the metal debris. After meticulous debridement, revision surgery was completed using a cementless AML stem (Depuy Orthopaedics, Warsaw, IN, USA) and cementless Trilogy cup (Zimmer Biomet, Warsaw, IN, USA) with an allobone

graft. The patient recovered well and returned to normal activity as scheduled without complications.

DISCUSSION

The current study is the first GTF case report in the bipolar hemiarthroplasty, and unlike cases of total hip arthroplasty, the cause of GTF is unknown. However, we assume that the GTF mechanisms of metal on polyethylene (MoP) total hip arthroplasty and bipolar hemiarthroplasty are similar. Bansal et al. reported that risk factors of GTF on the MoP total hip arthroplasty included being male, increased BMI, Ti-12Mo-6Zr-2Fe stem, higher offset, and large femoral head¹⁰.

In the current case, the patient was male and obese. We

also assume that a short trunnion is related to GTF which may have impacted the current case where an Exeter head was used with an ABG I stem. Both have the same taper design of 14/16, and exact fit was confirmed by the manufacturer. The ABG I stem trunnion is shorter (10 mm) than that of other popular implants (≈ 15 mm). Additionally, due to the shorter taper length and larger moment per unit area a short trunnion is likely to increase fretting corrosion. Higgs et al.¹¹ reported that there was no significant effect of trunnion length on the fretting corrosion in a retrieval study; however, the differences in the length and surface area were only 8% and 20%, respectively. Brock et al.¹² similarly reported a higher volumetric wear rate with a short trunnion compared to a long trunnion (0.4 mm³/yr vs. 0.1 mm³/yr). Mistry et al.¹³ reported that a short trunnion might be associated with high-

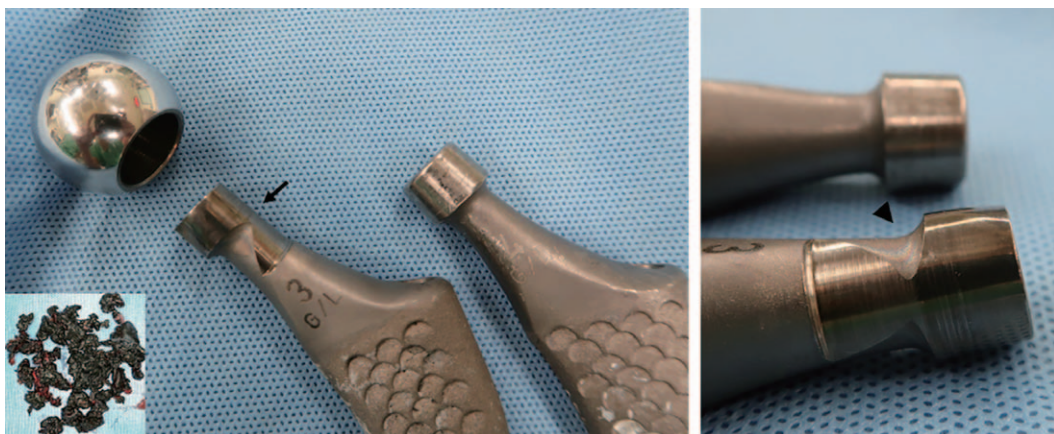


Fig. 3. The proximal femoral bone around the stem was replaced with black soft tissue (inset). The removed stem shows extensive damage in the trunnion (arrow) and deep notching (arrowhead) in the neck at the impingement site where the edge of the head bore has no remarkable evidence of damage.

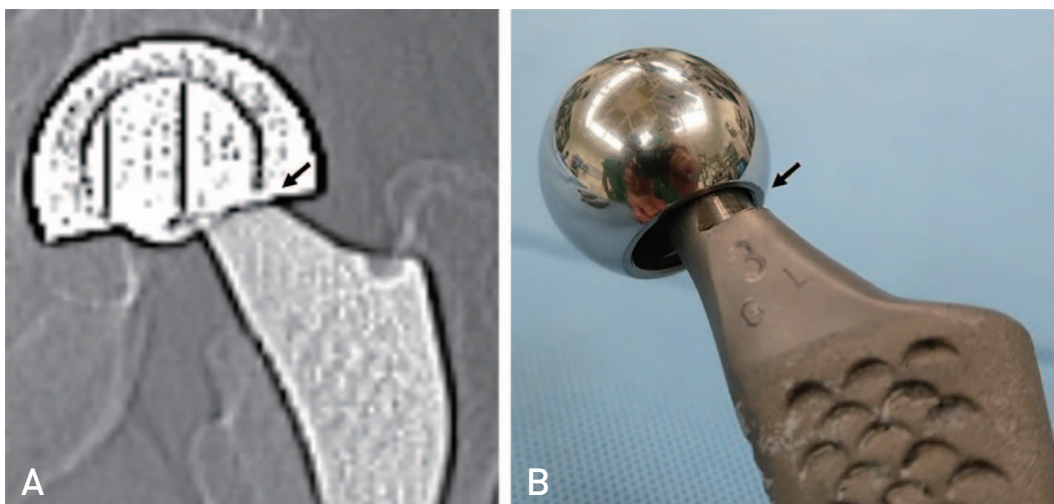


Fig. 4. Scout computed tomography image shows a clear outline of the head (A). The lateral margin of the neck is located outside of the edge of the head bore (arrows) (A, B).

er edge loading on the trunnion base. Furthermore, Pastides et al.²⁾ suggested that the slimmer and smaller taper reduced the chance of successful interference fit, causing malseating and micromotion. Considering that the majority of stems used in reported GTF cases are the accolade TMZF stem, which has a short trunnion (10.5 mm), further studies on trunnion length are necessary¹⁰⁾.

According to the current systematic review, GTF was typically detected 4 to 14 years after total hip arthroplasty¹⁰⁾. In our case, GTF occurred relatively late, 19 years after bipolar hemiarthroplasty. Del Balso et al.¹⁴⁾ suggested that compared with total hip arthroplasty, torque force at the head and neck junction decreased in bipolar hemiarthroplasty due to added articulation. We suggest that the difference in prosthesis component movement between total hip arthroplasty and bipolar hemiarthroplasty may have resulted in the late development of GTF in the current case.

Revision surgery was delayed due to a subtle abnormality on plain radiographs and CT images, which was missed initially. There were no findings of bubble sign or cloud sign associated with metallosis. A bipolar cup made it difficult to evaluate the position change of the head and neck. When the CT images were reviewed retrospectively, the cone of the stem did not coincide with the head center (Fig. 2A). Additionally, marked sclerotic changes were noticed in the medullary space around the proximal stem (Fig. 2B). These findings were unusual and believed to be the shadow of metal debris. The area was intraoperatively found to be filled with black-colored soft tissue characteristic of metallosis. Due to the shadow of metal debris, the cancellous bone of the proximal femur around the stem looked dense rather than lucent on CT images.

It is well known that metal ion levels rise in trunnionosis and GTF. In this case, however, the serum metal ion level was not measured as it was not considered trunnionosis prior to the revision surgery.

Decisive evidence of the trunnion failure was detected in the scout view of a CT scan (Fig. 4) as the metal neck was displaced laterally in the metal head. We have used the scout view to evaluate the polyethylene liner, metal head, and neck inside the bipolar cup as the components are clearly demarcated on the scout view. Had more attention been paid to the head and neck positions, diagnosis could have been made earlier.

In conclusion, compared with other GTF reports, there are some unusual aspects in the current case, including bipolar hemiarthroplasty, the use of a 28-mm head, relatively late-onset, and no apparent metallosis findings on

plain radiographs and CT images. We also propose the need for further studies regarding the effect of trunnion length on trunnionosis.

ACKNOWLEDGEMENTS

This work was supported by a grant (No. 06-2003-063) from the Institution Research Fund.

CONFLICT OF INTEREST

The authors declare that there is no potential conflict of interest relevant to this article.

REFERENCES

1. Archibeck MJ, Cummins T, Carothers J, Junick DW, White RE Jr. *A comparison of two implant systems in restoration of hip geometry in arthroplasty.* *Clin Orthop Relat Res.* 2011;469:443-6.
2. Pastides PS, Dodd M, Sarraf KM, Willis-Owen CA. *Trunnionosis: a pain in the neck.* *World J Orthop.* 2013;4:161-6.
3. Gilbert JL, Buckley CA, Jacobs JJ. *In vivo corrosion of modular hip prosthesis components in mixed and similar metal combinations. The effect of crevice, stress, motion, and alloy coupling.* *J Biomed Mater Res.* 1993;27:1533-44.
4. Tan SC, Teeter MG, Del Balso C, Howard JL, Lanting BA. *Effect of taper design on trunnionosis in metal on polyethylene total hip arthroplasty.* *J Arthroplasty.* 2015;30:1269-72.
5. Munir S, Walter WL, Walsh WR. *Variations in the trunnion surface topography between different commercially available hip replacement stems.* *J Orthop Res.* 2015;33:98-105.
6. Meneghini RM, Lovro LR, Wallace JM, Ziemba-Davis M. *Large metal heads and vitamin E polyethylene increase frictional torque in total hip arthroplasty.* *J Arthroplasty.* 2016;31:710-4.
7. Lavernia CJ, Iacobelli DA, Villa JM, Jones K, Gonzalez JL, Jones WK. *Trunnion-head stresses in THA: are big heads trouble?* *J Arthroplasty.* 2015;30:1085-8.
8. Del Balso C, Teeter MG, Tan SC, Lanting BA, Howard JL. *Taperosis: does head length affect fretting and corrosion in total hip arthroplasty?* *Bone Joint J.* 2015;97:911-6.
9. Porter DA, Urban RM, Jacobs JJ, Gilbert JL, Rodriguez JA, Cooper HJ. *Modern trunnions are more flexible: a mechanical analysis of THA taper designs.* *Clin Orthop Relat Res.* 2014;472:3963-70.
10. Bansal T, Aggarwal S, Dhillon MS, Patel S. *Gross trunnion failure in metal on polyethylene total hip arthroplasty-a systematic review of literature.* *Int Orthop.* 2020;44:609-21.
11. Higgs GB, Hanzlik JA, MacDonald DW, Gilbert JL, Rimmnac CM, Kurtz SM. *Is increased modularity associated with increased fretting and corrosion damage in metal-on-metal total hip arthroplasty devices?: a retrieval study.* *J Arthroplasty.* 2013;28(8 Suppl):2-6.

12. Brock TM, Sidaginamale R, Rushton S, et al. *Shorter, rough trunnion surfaces are associated with higher taper wear rates than longer, smooth trunnion surfaces in a contemporary large head metal-on-metal total hip arthroplasty system. J Orthop Res. 2015;33:1868-74.*
13. Mistry JB, Chughtai M, Elmallah RK, et al. *Trunnionosis in total hip arthroplasty: a review. J Orthop Traumatol. 2016;17:1-6.*
14. Del Balso C, Teeter MG, Tan SC, Lanting BA, Howard JL. *Does the additional articulation in retrieved bipolar hemiarthroplasty implants decrease trunnionosis compared to total hip arthroplasty? J Arthroplasty. 2018;33:268-72.*