



The "BioHumi" Humeral Head Osteochondral Allograft Transplantation for Reverse Hill-Sachs Lesion of the Shoulder

Jonathan D. Bryant, D.O., Paul E. Caldwell III, M.D., and Sara E. Pearson, Ph.D.

Abstract: Osteochondral defects of the shoulder due to posterior instability are less frequent than those caused by anterior instability. Although uncommon, locked posterior dislocations can create sizable osteochondral lesions of the anterior humeral head known as reverse Hill-Sachs lesions. Treatment of these defects to restore the congruent contour of the glenohumeral joint is essential to reduce recurrence of instability and prevent long-term sequelae of arthritis. Historically, nonanatomic options, such as transposition of the subscapularis tendon or lesser tuberosity into the defect and humeral rotational osteotomy, have been endorsed to treat reverse Hill-Sachs lesions. More contemporary techniques have focused on restoring not only the bony architecture but also the chondral surface using fresh osteochondral allografts. The evolution of this approach has been challenging because of the large impacted wedge-shaped defect typically encountered with a locked posterior dislocation. Many surgeons employ techniques using multiple circular grafts or customizing a nonanatomic graft to fill these defects. Given the unstable nature of these grafts, metallic screws are often placed through the chondral surface for fixation. The evolution of the "BioHumi" technique has made treatment of large reverse Hill-Sachs lesions technically simpler and more reproducible using innovative instrumentation to transplant an elliptical osteochondral allograft.

Introduction

Recognition and treatment of posterior shoulder instability are becoming more mainstream in contemporary orthopaedic literature. Unfortunately, a locked posterior shoulder dislocation with a reverse Hill-Sachs lesion is often missed and difficult to manage. Risk factors for recurrent instability include younger age at time of first instability episode, dislocation due to a seizure, large reverse Hill-Sachs lesion,

contact sports, and glenoid retroversion.^{1,2} Treatment options are often based on the size of the reverse Hill-Sachs lesion, and many authors have recommended shoulder arthroplasty for impaction fractures that involve more than 50% of the humeral head.^{3,4} The management of a reverse Hill-Sachs lesion involving less than 50% of the humeral head in younger patients is more controversial, and joint preservation techniques are favored over arthroplasty (Fig 1). Multiple surgical procedures have been described, ranging from transposition of the subscapularis tendon with or without the lesser tuberosity into the defect, disimpaction and bone grafting, rotational osteotomy of the proximal humerus, and reconstruction with an osteochondral allograft.⁴⁻¹⁰ Osteochondral allograft transplantation (OAT) was initially described for treatment of osteochondral lesions of the femoral condyle.^{11,12} The success of OAT in the knee led Gerber and Lambert¹³ to describe treatment of humeral head defects, resulting from chronic locked, posterior dislocations of the shoulder with OAT in 1996. Multiple techniques have since been described using fresh humeral head, talus, and femoral head allografts to restore healthy hyaline cartilage and subchondral bone. Studies examining outcomes of these procedures have found excellent patient satisfaction and improved functional outcome

From Orthopaedic Research of Virginia, Richmond, Virginia, U.S.A. (J.D.B., P.E.C., and S.E.P.) and Tuckahoe Orthopaedic Associates, Ltd., Richmond, Virginia, U.S.A. (P.E.C.).

The authors report the following potential conflicts of interest or sources of funding: This article was supported by grants from Orthopaedic Research of Virginia and fellowship support from Arthrex, ConMed/Linvatec, DePuy Synthes, DJO, PremiereMed LLC, and Smith & Nephew.

All ICMJE author disclosure forms are available for this article online, as supplementary material.

Received July 19, 2022; accepted August 28, 2022.

Address correspondence to Paul E. Caldwell III, M.D., 1501 Maple Ave., Suite 200 Richmond, VA 23226, U.S.A.. E-mail: fellowship@orv.com

© 2022 THE AUTHORS. Published by Elsevier Inc. on behalf of the Arthroscopy Association of North America. This is an open access article under the CC BY-NC-ND license (<http://creativecommons.org/licenses/by-nc-nd/4.0/>).

2212-6287/22943

<https://doi.org/10.1016/j.eats.2022.08.065>

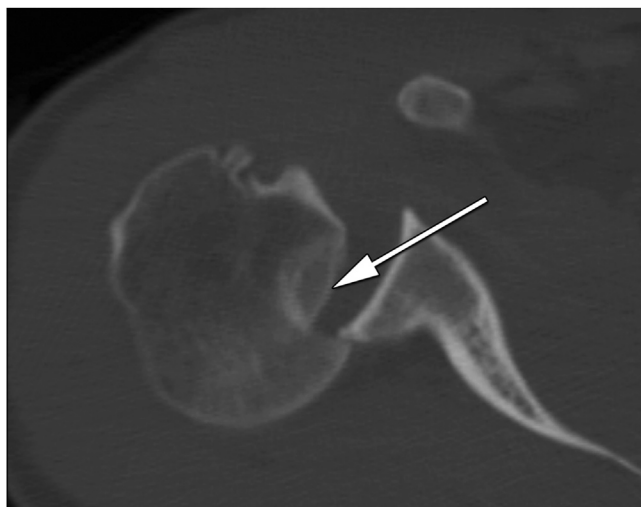


Fig 1. Demonstration of an axial cut of a computed tomography (CT) scan of a locked right shoulder posterior dislocation with a large reverse Hill-Sachs lesion of the humeral head (arrow).

scores.⁵ This traditional approach is challenging when addressing larger oblong or elliptical-shaped lesions. Treatment of larger lesions with multiple circular grafts carries the inherent risk of articular incongruity, graft loosening, paucity of allograft, need for fixation, and increased operative time. We advocate using the Arthrex BioUni OATS Instrumentation Set (Arthrex, Naples, FL) to create a single, oblong graft and present our preferred technique titled the “BioHumi”.

Surgical Technique

Our preference is to perform the procedure in the modified beach chair position (Video 1 and Table 1). Care is taken to position the patient on the edge of the bed to ensure that the elbow can be dropped off the side and the arm can be externally rotated to achieve adequate exposure of the humeral head (Table 2). We would also advocate placing a bump behind the medial border of the scapula to stabilize and elevate the scapula. We advocate a standard deltopectoral approach to the shoulder. Our preference is to perform a subscapularis tenotomy to expose the humeral head, but alternatively, a subscapularis peel or lesser tuberosity osteotomy may be used.

Once the humeral head has been exposed, the reverse Hill-Sachs lesion is evaluated for length, width, and depth, as well as the health of the surrounding cartilage (Fig 2). Reverse Hill-Sachs lesions are typically elongated, wedge-shaped osteochondral fractures, and our preference is to use the BioUni OATS Instrumentation Set (Arthrex) for larger oval defects. Standard sizing methods are employed to select the appropriate sizer/drill guide to cover the defect and match the natural curvature of the humeral head (Fig 3). Care is taken to

ensure that all sides of the sizer are flush with the intact articular surface and that the sizer contains the entire defect. A surgical marking pen is used to trace the outline of the selected sizer/drill guide onto the humeral head, and attention is then turned to preparation of the osteochondral graft (Fig 4).

Prior to mounting the graft in the OATS workstation (Arthrex), the selected sizer is placed on the proposed harvest site to ensure conformity (Fig 5). The osteochondral humeral head allograft is mounted and secured into the workstation with special attention to positioning the graft, so that the outlined donor site is level to allow the harvester to be applied in a perpendicular fashion to the graft station (Fig 6). The selected sizer is again placed on the allograft to confirm conformity, and a marking pen is again used to outline the sizer on the graft. The marking pen is also used to mark the superior aspect of the graft for orientation. The graft workstation must be placed on a secure, flat surface with an assistant stabilizing the station during the harvest. The oblong cutter is assembled to the impactor handle and gently lowered onto the graft to match the previously outlined area on the harvest location. A mallet is then used to drive the cutter into the allograft until the third laser line is flush with the surrounding cartilage. During the process of driving the cutter into the allograft, constant adjustments are made to the cutter by slightly angling the impactor handle to ensure that the cutter is advanced evenly. Our preference is to have the surgeon seated at eye level to the graft station to closely monitor the advancement of the cutter and make slight modifications, while the assistant impacts the handle.

The quick-connect distractor tool (Arthrex) is used to remove the oblong cutter from the allograft. The saw depth guide (Arthrex) is secured to the impactor handle and placed into the previous cut until all 4 hard stops on the edges are in direct contact with the cartilage. A sagittal saw blade is placed through the sagittal saw guide and advanced until it is through the humeral

Table 1. Key Steps for the “BioHumi” Osteochondral Allograft Transplantation Procedure for Reverse Hill-Sachs Lesion

Key Steps:

1. Obtaining adequate exposure with attention to positioning and surgical approach
2. Sizing the humeral head defect with elliptical and circular sizers to determine the best fit
3. Positioning of the allograft harvest surface within the graft station perpendicular to the harvester
4. Preparing the graft with pulsatile lavage to remove marrow elements and condition with autologous conditioned plasma
5. Dilating the recipient site for easy implantation
6. Ranging the shoulder after implantation to check for graft security and congruity

Table 2. Pearls and Pitfalls of the “BioHumi” Osteochondral Allograft Transplantation Procedure for Reverse Hill-Sachs Lesion

Pearls

1. Ensure the sizing of the reverse Hill-Sachs lesion is based on the intact cartilage surface.
2. Have both elliptical and circular systems available for sizing and implantation.
3. Use a sturdy secure graft station for harvest of the elliptical graft.
4. Slightly chamfer the edges of the graft with a rongeur to facilitate implantation.
5. Place a polydioxanone suture under the graft during implantation to allow for safe removal if adjustments to the graft are needed for a proper fit.

Pitfalls

1. Failure to achieve adequate surgical exposure to obtain perpendicular access to the defect for sizing and preparation must be avoided.
2. Error in selection of size and curvature can lead to poor congruity at recipient-graft interface.
3. Failure to secure the graft properly in the station can lead to loosening during the harvest.
4. Improper positioning of the graft within the graft station can lead to an uneven harvest.
5. Failure to dilate the recipient site can lead to a tight fit with incongruity of the articular surface.

head. We recommend dripping cold irrigation with a bulb syringe over the saw blade to minimize the risk of thermal necrosis to the graft. The sagittal saw attachments are removed, and the graft is contained in the sagittal saw depth guide. The distractor tool is slowly inserted to extract the graft from the sagittal saw depth guide (Fig 7). We recommend placing part of a surgical sponge into the distractor tool hole to protect the articular surface of the graft during extraction.

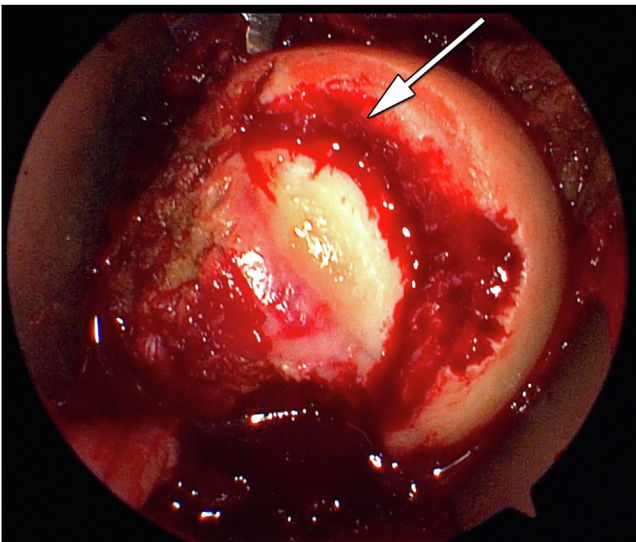


Fig 2. Demonstration of an open deltopectoral approach of a right shoulder in the beach chair position with a large reverse Hill-Sachs lesion of the humeral head (arrow) from a locked posterior shoulder dislocation.

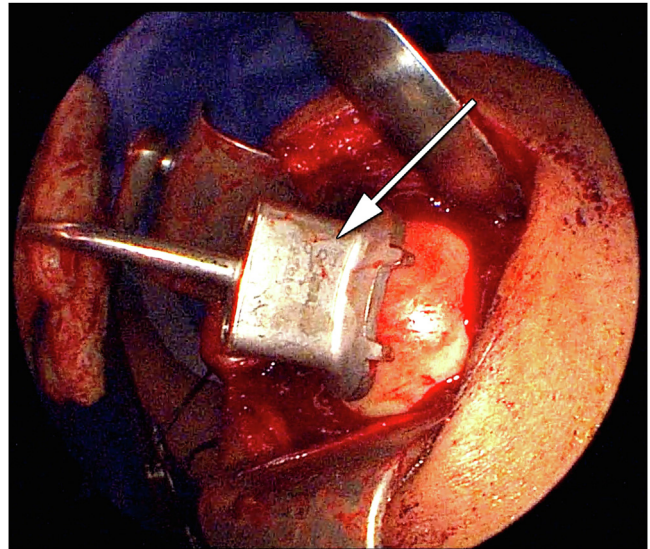


Fig 3. Demonstration of an open deltopectoral approach of a right shoulder with the patient in the beach chair position with sizing of a large reverse Hill-Sachs lesion of the humeral head (arrow) from a locked posterior dislocation in preparation for osteochondral allograft transplantation (OAT) using the BioHumi technique.

Extraction of the graft within a basin will reduce the risk of mishandling and dropping of the graft on the floor. The graft is then placed into the appropriately sized donor trial to confirm sizing. In cases where the graft does not fit perfectly in the sizer, we advocate slight adjustments to the graft with a rasp or small saw until an adequate fit is achieved. Adjustments to the graft are much easier to accomplish than alterations to the recipient site. A rongeur is used to chamfer the edges of the graft to facilitate insertion into the recipient site. Pulse irrigation is used to remove marrow elements, and the graft is soaked in autologous conditioned plasma (ACP) until implantation.

Attention is turned to preparation of the recipient site by placing the sizer/drill guide onto the previously outlined defect. The surgeon confirms that the sizer covers the entirety of the defect and that all 4 sides are flush to the healthy chondral surface. Two 4-mm drill pins are placed through the drill holes in a parallel fashion and advanced 3 centimeters. During this critical portion of the case, we recommend that the surgeon secure the guide in place to confirm position and the assistant advance the pins gently. The sizer is removed, and the drill pins are left in place. The scoring guide with the impactor handle is placed over the drill pins and impacted 2-3 mm into the cartilage surface. Great care is taken to ensure that the impactor remains parallel to the drill pins in orthogonal planes. The scoring device is removed, leaving the pins in place. The appropriately sized drill depth guide is placed on the superior drill pin, and a reamer is placed on the inferior

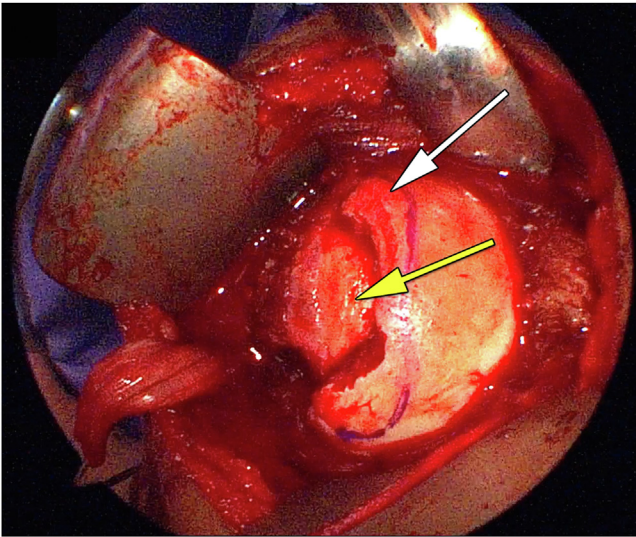


Fig 4. Demonstration of an open deltopectoral approach of a right shoulder with the patient in the beach chair position with a large reverse Hill-Sachs lesion of the humeral head (white arrow) from a locked posterior dislocation with the planned recipient site outlined (yellow arrow) after sizing in preparation for osteochondral allograft transplantation (OAT) using the BioHumi technique.

pin. The reamer is advanced until the drill depth guide prevents further insertion. The reamer and depth guide are placed on opposite pins, and the process is repeated. The box cutter is placed over the drill pins and advanced until the tabs are touching the cancellous bone and will not advance. The drill pins are removed, and the excess bone and cartilage are removed with an elevator and curette (Fig 8). The dilatator is impacted into the recipient site to confirm the appropriate size and depth.

The graft is removed from the ACP and placed into the recipient site using manual pressure (Fig 9). An impactor may be used to aid in final seating of the graft to ensure the edges are flush with the surrounding cartilage. Palpating the graft recipient interface to confirm that the graft edges are flush or slightly recessed is crucial to the allograft implantation technique. If any portion of the graft is proud, then the graft is removed, and appropriate adjustments are made to ensure proper fit. Care is taken to avoid forceful impaction of the graft to prevent potential iatrogenic chondral injury. Our preference is to place a 2-0 polydioxanone (PDS) suture across the recipient site prior to insertion of the graft. The suture may be used to remove the graft without undue force and subsequent damage if the graft-recipient site interface is too tight, and adjustments to the graft or recipient site must be made. Once the graft is well seated, the suture can be cut flush with graft edge. The shoulder is taken through a full range of motion to ensure the security and chondral continuity of the graft.

The shoulder is irrigated copiously, and the subscapularis is repaired using the Arthrex Speed Bridge System. The incision is closed in layers, and a dry, sterile dressing is applied. The patient is placed in a sling postoperatively. The patient is seen at 1 week after surgery and started in a physical therapy program to achieve full passive range of motion, while protecting the subscapularis repair. Strengthening is started at 3 months postoperatively, and return to sports is considered at 6 months if range of motion and strength goals are achieved. The graft incorporation is followed radiographically during the rehabilitative process (Fig 10).

Discussion

OAT was initially described for treatment of chondral and osteochondral defects of the femoral condyle in the knee and has gained significant support in the literature over the past several decades.^{14,15} Long-term results have demonstrated graft survival rates approaching 90% at 10 years and 75% at 15 years for isolated condylar lesions.¹⁶ Functional outcome scores and patient satisfaction have also shown excellent long-term results.¹⁷ The success of OAT in the knee has led surgeons to adopt comparable techniques in the shoulder for the treatment of traumatic bony defects, resulting from glenohumeral instability.^{10,13,18,19} Although chondral defects in the shoulder are not as common as in the knee, the indications for treatment in the shoulder have expanded to include joint restoration

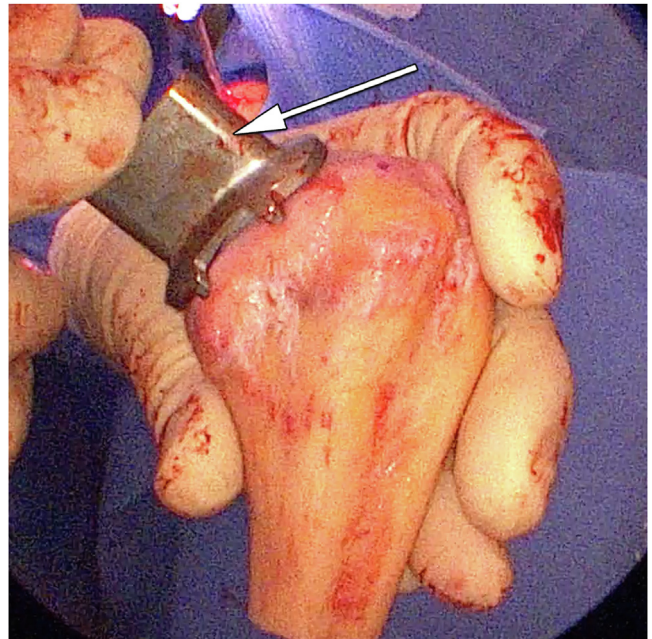


Fig 5. Demonstration of the sizer (arrow) on the proposed harvest site on a right fresh humeral osteochondral allograft in preparation for osteochondral allograft transplantation (OAT) using the BioHumi technique for a right shoulder large reverse Hill-Sachs lesion.

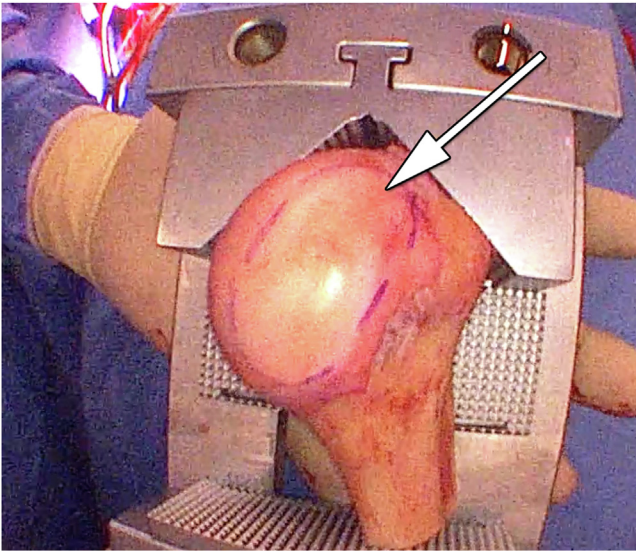


Fig 6. Demonstration of a right humeral fresh osteochondral allograft within the graft station with the proposed harvest site outlined (arrow) in preparation for osteochondral allograft transplantation (OAT) using the BioHumi technique for a right shoulder large reverse Hill-Sachs lesion.

techniques for focal, symptomatic osteochondral defects of the humeral head in healthy, active patients.

Although the literature describing outcomes of OAT in the shoulder is primarily limited to case reports and small case series,^{3,5,10,18-24} the ability to restore the normal joint contour and bony architecture with

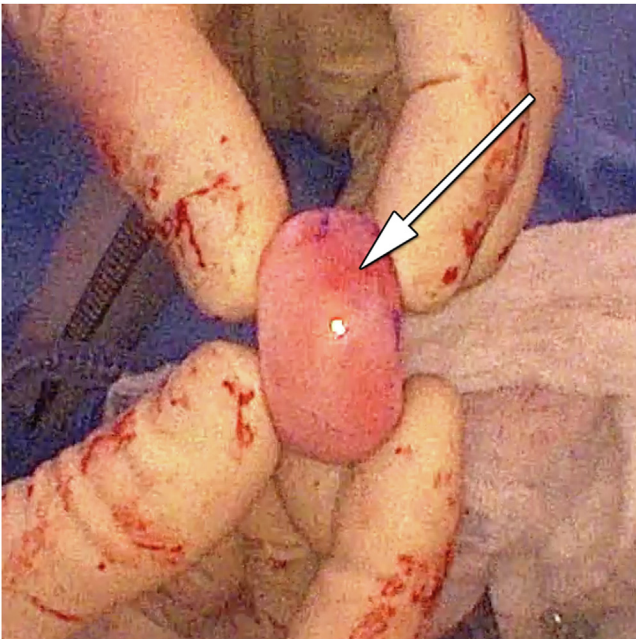


Fig 7. Demonstration of the donor elliptical graft (arrow) after harvest from the right humeral head fresh osteochondral allograft in preparation for osteochondral allograft transplantation (OAT) using the BioHumi technique for a right shoulder large reverse Hill-Sachs lesion.

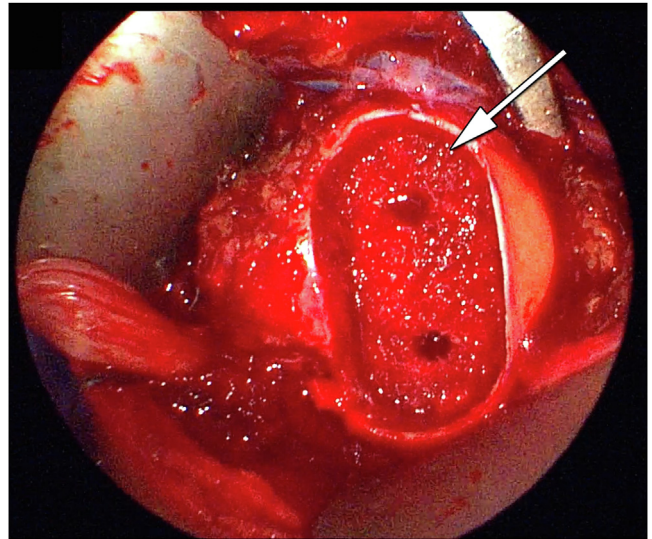


Fig 8. Demonstration of an open deltopectoral approach of a right shoulder with the patient in the beach chair position with a large reverse Hill-Sachs lesion of the humeral head from a locked posterior dislocation with the recipient site (arrow) prepared for graft implantation in preparation for osteochondral allograft transplantation (OAT) using the BioHumi technique.

hyaline cartilage and bone has shown excellent potential. A 2015 systematic review that included 12 studies with 35 patients is the largest study to date.⁵ The majority of the patients underwent OAT to treat large Hill-Sachs lesions due to shoulder instability with an average size defect of greater than 40% of the

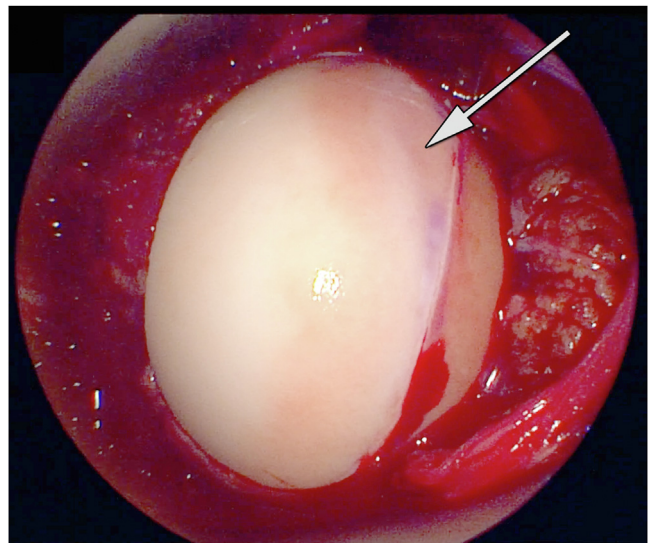


Fig 9. Demonstration of an open deltopectoral approach of a right shoulder with the patient in the beach chair position with a large reverse Hill-Sachs lesion of the humeral head from a locked posterior dislocation with final implantation of the elliptical fresh humeral head osteochondral allograft (arrow) using the BioHumi technique.

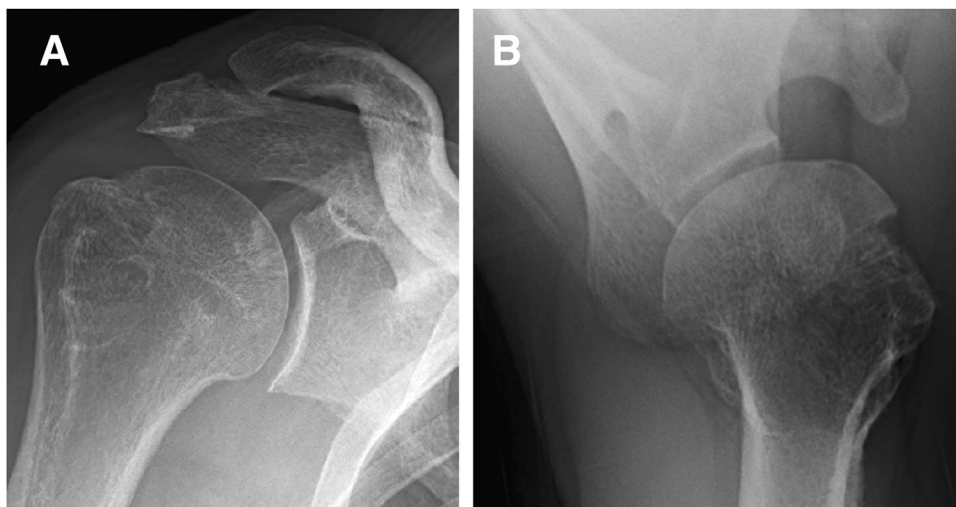


Fig 10. Demonstration of anteroposterior (A) and axillary (B) radiographs of the right shoulder 4 months after osteochondral allograft implantation using the BioHumi technique for treatment of a reverse Hill-Sachs lesion after a locked posterior dislocation.

articular surface. The authors found significant improvement in shoulder range of motion and American Shoulder and Elbow Surgeons (ASES) scores at an average follow-up of 57 months with high patient satisfaction. Graft resorption was seen in 36.2% of patients, and arthritic changes were seen in 35.7%, with 26.7% of patients requiring reoperation. Unlike our technique, all but two patients in this study received fresh-frozen osteochondral grafts. The patients who were treated with fresh grafts demonstrated no evidence of graft resorption, necrosis, or arthritis, leading the authors to conclude that fresh allografts may lead to better graft incorporation and ultimate outcomes. Fresh osteochondral allografts have been shown to have increased chondrocyte viability compared to fresh-frozen grafts,¹⁶ and we would advocate using a fresh graft for this procedure.

More recently, Riff et al.²² reported their mid-term results of fresh OAT for humeral defects in 20 patients with an average age of 25 years. They followed 90% of their patients for an average of 67 months and found that all but 2 grafts incorporated and had an overall 61% survival rate. The authors reported that 11 of the patients were satisfied and that patients who were dissatisfied underwent a concomitant glenoid surgery at the same setting. Four patients went on to subsequent shoulder arthroplasty due to complications from pain pump chondrolysis. Significant improvements were reported for the visual analog scale, Simple Shoulder Test, ASES score, and the physical component of the 12-Item Short Form Survey. This led the authors to conclude that OAT is a viable option for young patients with isolated humeral chondral injury. They cautioned against treatment of patients with bipolar disease or a history of intra-articular pain pump use.

Another recent study by Zhuo et al.²¹ reported on OAT for large Hill-Sachs lesions. They had 19 patients

with a mean age of 21.7 years. The mean size of Hill-Sachs lesion was 35.7% of the humeral head, and mean follow-up was 27.8 months. All grafts went on to radiographic union at an average of 3.47 months. Although 43.1% of the patients had graft resorption at final follow-up, there were no significant differences found between the graft resorption and nonresorption groups. Significant improvements were seen in active range of motion, ASES score, Constant-Murley score, and Rowe score, and overall satisfaction rate was 94.7%. One patient had slight pain in the operative shoulder with overhead sports, which was resolved with screw removal. Despite the high rate of graft resorption, the clinical outcomes at 2 years were very favorable.

Reports of treatment of oblong or elliptical chondral or osteochondral lesions in the humeral head using a single, elongated osteochondral graft are limited.

Table 3. Advantages and Disadvantages of the “BioHumi” Osteochondral Allograft Transplantation Procedure for Reverse Hill-Sachs Lesion

Advantages	
1.	The technique uses reproducible steps with custom instrumentation for both graft harvest and recipient site preparation.
2.	The technique is an excellent option for wedge-shaped reverse Hill-Sachs lesions.
3.	Multiple size options are available to closely match recipient site dimensions.
4.	Secure, press-fit fixation of the graft is achieved to eliminate loosening or the need for hardware fixation.
5.	The need for multiple circular grafts is alleviated, decreasing the chance of articular incongruity.
Disadvantages	
1.	Obtaining a fresh humeral osteochondral allograft may be difficult.
2.	The technique requires specialized instrumentation made by only one company.
3.	A radius of curvature match between donor and recipient is necessary for articular congruity.

Osteochondral lesions of the humeral head are seldom circular in shape, and this technique offers many advantages to restoring the osteochondral contour for larger, oblong defects, while minimizing disruption of normal surrounding cartilage (Table 3). Multiple circular grafts in a “snowman” or “Mastercard” configuration (Mastercard, Purchase, NY) have been the traditional option for treatment of longer narrow lesions in the knee. Unfortunately, this technique in the knee has been shown to be inferior to single-graft transplantation, with a reoperation rate of 44% and failure rate of 33% compared to 20% and 6% for single grafts.¹⁹ The authors concluded that multiple graft constructs demonstrate inferior clinical outcomes, graft incorporation, and graft survival due to articular incongruity and subsequent “cobblestoning” with fibrocartilage filling in the spaces between the grafts. Given the recent emphasis on the importance of subchondral bone in the treatment of chondral lesions, multiple graft constructs are less advantageous in restoring this critical foundation for long-term cartilage survival. In addition, treatment with multiple grafts adds considerable operative time and often requires graft fixation, often through the cartilage, to minimize the risk of loosening. The ability to harvest a larger, single graft is also beneficial because of the paucity of surface area available to harvest multiple grafts. Other techniques to address large humeral head defects have been described,^{3,4,7,10,13,20,21,23} but the “free-hand” nature of these techniques can be difficult to replicate, and it is challenging to adequately restore the chondral surface and subchondral bone of the humeral head. The “Elliptical BioHumi” technique for OAT of the humeral head simplifies a technically demanding procedure with a reproducible method for addressing large, oblong osteochondral defects and potentially offers improved patient outcomes.

References

1. Brzóska R, Solecki W, Deranlot J, et al. Posterior shoulder instability (ICL 15). *ESSKA Instr Course Lect B Barcelona* 2016;25:155-166.
2. Owens BD, Campbell SE, Cameron KL. Risk factors for posterior shoulder instability in young athletes. *Am J Sports Med* 2013;41:2645-2649.
3. Diklic ID, Ganic ZD, Blagojevic ZD, Nho SJ, Romeo AA. Treatment of locked chronic posterior dislocation of the shoulder by reconstruction of the defect in the humeral head with an allograft. *J Bone Jt Surg B* 2010;92:71-76.
4. Marcheggiani Muccioli GM, Rinaldi VG, Lullini G, et al. Mid-term outcomes following fresh-frozen humeral head osteochondral allograft reconstruction for reverse Hill Sachs lesion: A case series. *BMC Musculoskelet Disord* 2021;22:1-8.
5. Saltzman BM, Riboh JC, Cole BJ, Yanke AB. Humeral head reconstruction with osteochondral allograft transplantation. *Arthroscopy* 2015;31:1827-1834.
6. Ziran B, Nourbakhsh A. Proximal humerus derotational osteotomy for internal rotation instability after locked posterior shoulder dislocation: Early experience in four patients. *Patient Saf Surg* 2015;9:1-5.
7. Mastrokalos DS, Panagopoulos GN, Galanopoulos IP, Papagelopoulos PJ. Posterior shoulder dislocation with a reverse Hill–Sachs lesion treated with frozen femoral head bone allograft combined with osteochondral autograft transfer. *Knee Surg Sport Traumatol Arthrosc* 2017;25:3285-3288.
8. Miyazaki AN, Silva LA, do Val Sella G, Checchia CS, Simionato MC, Checchia SL. Articular reconstruction of the humeral head with autogenous allograft in the treatment of the osteonecrosis. *Rev Bras Ortop (English Ed.)* 2018;53:113-117.
9. Martetschläger F, Padalecki JR, Millett PJ. Modified arthroscopic McLaughlin procedure for treatment of posterior instability of the shoulder with an associated reverse Hill-Sachs lesion. *Knee Surg Sport Traumatol Arthrosc* 2013;21:1642-1646.
10. Provencher MT, Sanchez G, Schantz K, et al. Anatomic humeral head reconstruction with fresh osteochondral talus allograft for recurrent glenohumeral instability with reverse Hill-Sachs lesion. *Arthrosc Tech* 2017;6:e255-e261.
11. Garrett JC. Treatment of osteochondral defects of the distal femur with fresh osteochondral allografts: A preliminary report. *Arthroscopy* 1986;2:222-226.
12. Garrett JC. Fresh osteochondral allografts for treatment of articular defects in osteochondritis dissecans of the lateral femoral condyle in adults. *Clin Orthop Relat Res* 1994;303:33-37.
13. Gerber C, Lambert SM. Allograft reconstruction of segmental defects of the humeral head for the treatment of chronic locked posterior dislocation of the shoulder. *J Bone Joint Surg Am* 1996;78:376-382.
14. McDermott AG, Langer F, Pritzker KP, Gross AE. Fresh small-fragment osteochondral allografts: Long-term follow-up study on first 100 cases. *Clin Orthop Relat Res* 1985;197:96-102.
15. Mankin HJ, Doppelt S, Tomford W. Clinical experience with allograft implantation: The first ten years. *Clin Orthop Relat Res* 1983;174:69-86.
16. Sherman SL, Garrity J, Bauer K, Cook J, Stannard J, Bugbee W. Fresh osteochondral allograft transplantation for the knee: Current concepts. *J Am Acad Orthop Surg* 2014;22:121-133.
17. Gross AE, Shasha N, Aubin P. Long-term followup of the use of fresh osteochondral allografts for posttraumatic knee defects. *Clin Orthop Relat Res* 2005;435:79-87.
18. Nathan ST, Parikh SN. Osteoarticular allograft reconstruction for hill-sachs lesion in an adolescent. *Orthopedics* 2012;35:744-747.
19. Patrizio L, Sabetta E. Acute posterior shoulder dislocation with reverse Hill-Sachs lesion of the epiphyseal humeral head. *ISRN Surg* 2011;2011, 851051.
20. Provencher MT, LeClere LE, Ghodadra N, Solomon DJ. Postsurgical glenohumeral anchor arthropathy treated with a fresh distal tibia allograft to the glenoid and a fresh allograft to the humeral head. *J Shoulder Elb Surg* 2010;19:e6-e11.
21. Zhuo H, Xu Y, Zhu F, Pan L, Li J. Osteochondral allograft transplantation for large Hill-Sachs lesions: A retrospective

- case series with a minimum 2-year follow-up. *J Orthop Surg Res* 2019;14:344.
22. Riff AJ, Yanke AB, Shin JJ, Romeo AA, Cole BJ. Midterm results of osteochondral allograft transplantation to the humeral head. *J Shoulder Elb Surg* 2017;26:e207-e215.
 23. Dipaola MJ, Jazrawi LM, Rokito AS, et al. Management of humeral and glenoid bone loss associated with glenohumeral instability: Results with anatomical bone grafting. *Bull NYU Hosp Jt Dis* 2010;68:245-250.
 24. Martinez AA, Navarro E, Iglesias D, Domingo J, Calvo A, Carbonel I. Long-term follow-up of allograft reconstruction of segmental defects of the humeral head associated with posterior dislocation of the shoulder. *Injury* 2013;44:488-491.