

[CASE REPORT]

Amyotrophic Lateral Sclerosis after Receiving the Human Papilloma Virus Vaccine: A Case Report of a 15-year-old Girl

Ryota Hikiami¹, Hodaka Yamakado¹, Shinsui Tatsumi¹, Takashi Ayaki¹, Yuichiro Hashi¹, Hirofumi Yamashita¹, Nobukatsu Sawamoto¹, Teruyuki Tsuji², Makoto Urushitani^{1,3} and Ryosuke Takahashi¹

Abstract:

We herein report a 15-year-old girl who developed rapid progressive muscle weakness soon after the third injection of a bivalent human papilloma virus (HPV) vaccine. Although immunotherapies were performed for possible vaccine-related disorders, she died of respiratory failure 14 months after the onset of the disease. A genetic analysis identified a heterozygous p.P525L mutation of the fused in sarcoma (*FUS*) gene, and a histopathological analysis was also consistent with *FUS*-associated amyotrophic lateral sclerosis (ALS) without any evidence of neuroinflammation. We concluded the diagnosis to be *FUS*-ALS, although we cannot completely rule out the possibility that the vaccination worked as a trigger.

Key words: juvenile-onset amyotrophic lateral sclerosis, *FUS* gene, de novo mutation, human papilloma virus vaccine

(Intern Med 57: 1917-1919, 2018)

(DOI: 10.2169/internalmedicine.0285-17)

Introduction

The vaccine against a human papilloma virus (HPV) has become a hot topic in political as well as medical fields. In particular, there is a controversy over the safety of the HPV vaccine. The public report of serious adverse effects, even if they are rare and not clearly related to the vaccine, is affecting the rate of the HPV vaccine coverage in many countries and having great impact on vaccine policy in some countries such as Japan. We herein firstly reported a genetically diagnosed and pathologically proven amyotrophic lateral sclerosis (ALS) case after HPV vaccination with detailed clinical information.

Case Report

A 15-year-old girl presented with left lower limb weakness 1 week after the third injection of Cervarix[®] (GSK, London, UK), a bivalent human papilloma virus vaccine, in

October 2013. She had also noticed transient left upper limb weakness after the second injection five months earlier, in May 2013; however, the left upper limb weakness had been transient and had almost completely recovered. Her symptoms deteriorated rapidly, and three months later, she suffered from difficulty writing and standing up alone, at which point she was admitted to our neurological institute. She had generally been in good health for the first 15 years of her life, with no family history of neurological disorders. A neurological examination demonstrated proximal dominant muscle weakness and atrophy in all extremities. The cranial nerves were intact, the deep tendon reflexes were preserved, and there was no pathological reflex or fasciculation. The sensory, cognitive, autonomic, and cerebellar functions were normal. Lasègue's sign was positive.

Blood tests revealed no remarkable results for her symptoms, except for minimally elevated levels of anti-acetylcholine receptor and GalNAc-GD1a IgM receptor antibodies. A cerebrospinal fluid test showed a mild increase in the IgG index (0.77) with normal cell counts and protein

¹Department of Neurology, Kyoto University Graduate School of Medicine, Japan, ²Tsuji Clinic, Japan and ³Department of Neurology, Shiga University of Medical Science, Japan

Received: September 29, 2017; Accepted: November 13, 2017; Advance Publication by J-STAGE: February 9, 2018

Correspondence to Dr. Hodaka Yamakado, yamakado@kuhp.kyoto-u.ac.jp

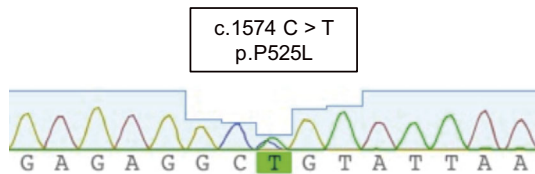


Figure 1. Sequencing chromatograms of the p.P525L mutation in the *FUS* gene. The green box shows the position of a C-to-T transition at nucleotide 1574 (c.1574 C>T).

concentrations. Electromyography and a nerve conduction study showed active and chronic denervation in all limbs and paraspinal muscles without any obvious conduction block.

Based on the clinical course and mild inflammatory changes in the cerebrospinal fluid as well as the positive Lasègue's sign, we initially suspected immune-mediated polyradiculopathy associated with vaccination and chose immunotherapy as the treatment. However, the symptoms were unresponsive to intravenous immunoglobulins, plasmapheresis, and high-dose steroids. In July 2014, she became bed-

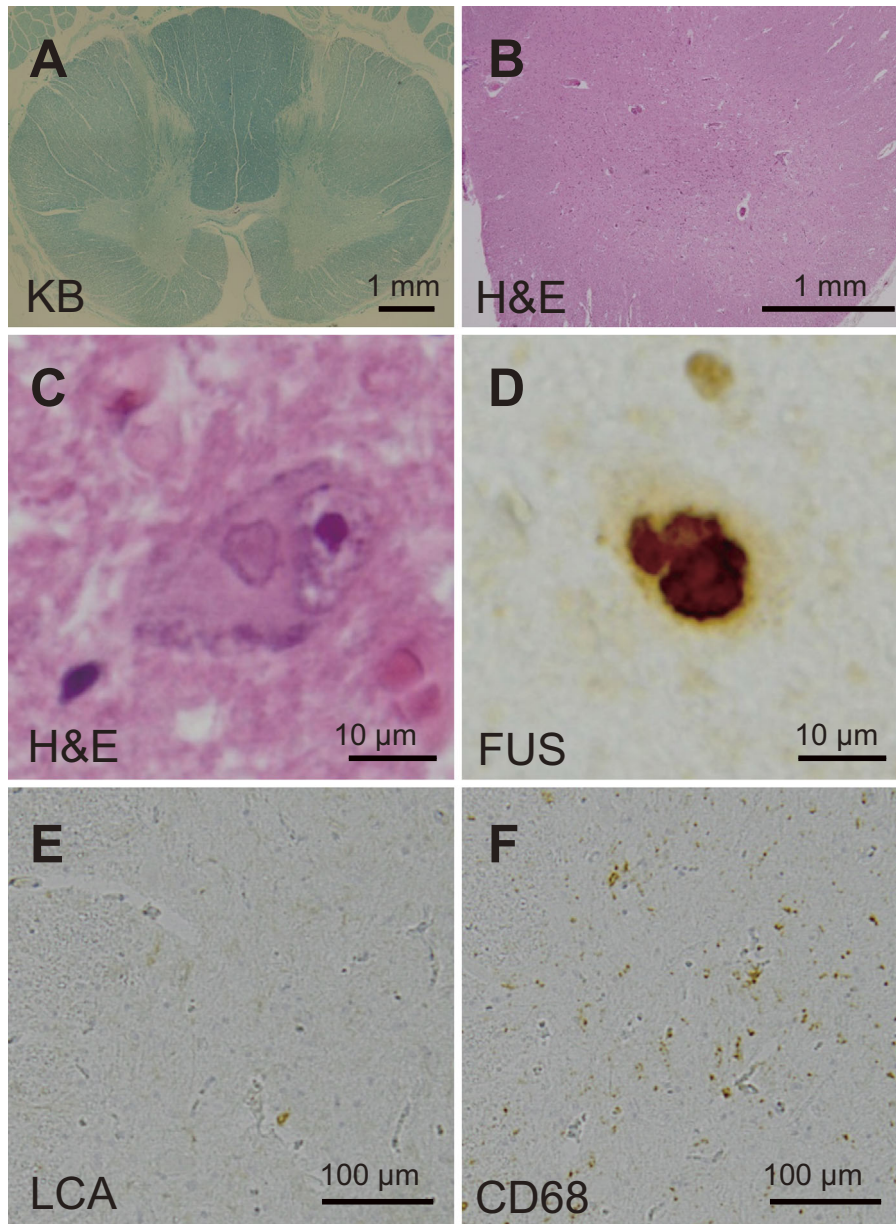


Figure 2. The histopathological analysis of the patient. (A) Kluver-Barrera's stain of the cervical spinal cord showed the extensive demyelination in the lateral column. (B) Hematoxylin and Eosin staining sections of the lumbar cord revealed marked neuronal loss in the anterior horn. (C, D) The remaining motor neurons contained basophilic and FUS-positive neuronal cytoplasmic inclusions. (E, F) Immunohistochemical staining for leukocyte common antigen and CD68 showed the mild infiltration of macrophages and scattered lymphocytes in the lumbar cord. KB: Kluver-Barrera's stain, LCA: leukocyte common antigen

ridden and dependent on noninvasive positive pressure ventilation throughout the day. Subsequently, a genetic analysis revealed a heterozygous missense mutation, c.1574 C>T; p.P525L, in the fused in sarcoma (*FUS*) gene (Fig. 1). The patient was negative for mutations of superoxide dismutase 1 (*SOD1*) and TAR DNA-binding protein 43 (*TDP-43*) genes. She ultimately died of respiratory failure in December 2014, 14 months after the second onset of the disease.

An autopsy was performed. The loss of motor neurons was marked in the spinal cord (Fig. 2A and B), moderate in the primary motor cortex, and mild in the hypoglossal and facial nerve nuclei. The remaining motor neurons contained intracytoplasmic basophilic inclusions, remarkably in the spinal cord. These basophilic inclusions were strongly positive for *FUS* but negative for TDP-43 (Fig. 2C and D) (1). Immunohistochemistry for CD68 and leukocyte common antigen demonstrated mild macrophage infiltration and scattered lymphocytes in the spinal cord, which may have been the result of a secondary reaction to the severe neuronal degeneration (Fig. 2E and F) (2, 3). No significant cell infiltration was detected in the spinal roots.

Discussion

This is the first published case report of a genetically and pathologically proven ALS with detailed clinical information, including a history of HPV vaccination. There are two other reported cases of ALS that were diagnosed after HPV vaccination (4), and nine events had been submitted to the Vaccine Adverse Event Reporting System (VAERS) of Centers for Disease Control and Prevention (CDC) as of October 25, 2017. In one case, an autopsy confirmed motor neuron disease (4). In the present case, the histopathological study revealed the *FUS* pathology and no evidence of immune-mediated inflammatory changes. The young age at onset as well as the rapid progressive course of the disease are also consistent with the previous case reports of ALS with an *FUS* P525L mutation (5, 6). Of note, approximately 50% of cases harboring this mutation have been reported to be sporadic, with a high proportion of *de novo* mutations (5, 6).

There has never been any statistical evidence linking serious conditions such as death or ALS to the adverse effects of the HPV vaccine (7). Furthermore, the World Health Organization also concluded that HPV vaccines have an excellent safety profile and reiterates its recommendation that HPV vaccines be included in national immunization programs (8). Nonetheless, concerns regarding the vaccine's adverse effects persist, and the rate of increase in HPV vaccine coverage has slowed over time. Our case demonstrated the necessity of more extensive studies and scientific validation, including autopsies, especially in cases with serious adverse effects. Without such clarifications, this case may be mistak-

enly reported as a possible case of HPV vaccine-triggered ALS.

Another issue we should consider in this case is the possibility that the HPV vaccine accelerated the ALS pathogenesis and hastened the disease onset. The HPV vaccine contains a potent toll-like receptor 4 activator as an adjuvant, and recent animal studies have shown that toll-like receptor 4 activation is involved in the pathogenesis of ALS (9, 10). Thus, at this time, it is too premature to conclude whether or not the HPV vaccine is completely safe in individuals with neurological conditions, and further investigations are needed. However, of note, these individual cases should not immediately influence ongoing vaccine policies unless enough scientific evidence for the association of neurological conditions with HPV vaccines can be demonstrated.

The authors state that they have no Conflict of Interest (COI).

References

- Mackenzie IR, Ansorge O, Strong M, et al. Pathological heterogeneity in amyotrophic lateral sclerosis with *FUS* mutations: two distinct patterns correlating with disease severity and mutation. *Acta Neuropathol* **122**: 87-98, 2011.
- Kawamata T, Akiyama H, Yamada T, McGeer PL. Immunologic reactions in amyotrophic lateral sclerosis brain and spinal cord tissue. *Am J Pathol* **140**: 691-707, 1992.
- Huang EJ, Zhang J, Geser F, et al. Extensive *FUS*-immunoreactive pathology in juvenile amyotrophic lateral sclerosis with basophilic inclusions. *Brain Pathol* **20**: 1069-1076, 2010.
- Slade BA, Leidel L, Vellozzi C, et al. Postlicensure safety surveillance for quadrivalent human papillomavirus recombinant vaccine. *JAMA* **302**: 750-757, 2009.
- Zou ZY, Cui LY, Sun Q, et al. De novo *FUS* gene mutations are associated with juvenile-onset sporadic amyotrophic lateral sclerosis in China. *Neurobiol Aging* **34**: 1312. e1-e8, 2013.
- Conte A, Lattante S, Zollino M, et al. P525L *FUS* mutation is consistently associated with a severe form of juvenile amyotrophic lateral sclerosis. *Neuromuscul Disord* **22**: 73-75, 2012.
- Stillo M, Carrillo Santistevan P, Lopalco PL. Safety of human papillomavirus vaccines: a review. *Expert Opin Drug Saf* **14**: 697-712, 2015.
- Weekly epidemiological record. WHO [Internet]. [cited 2017 Oct. 25]. Available from: <http://www.who.int/wer/2014/wer8943.pdf?ua=1>
- De Paola M, Sestito SE, Mariani A, et al. Synthetic and natural small molecule TLR4 antagonists inhibit motoneuron death in cultures from ALS mouse model. *Pharmacol Res* **103**: 180-187, 2016.
- Lee JY, Lee JD, Phipps S, Noakes PG, Woodruff TM. Absence of toll-like receptor 4 (TLR4) extends survival in the hSOD1G93A mouse model of amyotrophic lateral sclerosis. *J Neuroinflammation* **12**: 90, 2015.

The Internal Medicine is an Open Access article distributed under the Creative Commons Attribution-NonCommercial-NoDerivatives 4.0 International License. To view the details of this license, please visit (<https://creativecommons.org/licenses/by-nc-nd/4.0/>).