

Intraocular lipopolysaccharide examination for early diagnosis of *Stenotrophomonas maltophilia* endophthalmitis: a case report

Journal of International Medical Research
48(8) 1–5

© The Author(s) 2020

Article reuse guidelines:

sagepub.com/journals-permissions

DOI: 10.1177/0300060520929865

journals.sagepub.com/home/imrLi Chen , Zhuo Zai Xu and Yong Tao 

Abstract

This report describes the presence of *Stenotrophomonas maltophilia* endophthalmitis after phacoemulsification in a 66-year-old woman. The patient presented with ocular redness and pain, as well as hypopyon in the anterior chamber and reduction of visual acuity to hand motion. Intraocular fluid examination revealed a lipopolysaccharide level of >2.5 , which suggested bacterial endophthalmitis. The patient was promptly treated with intravitreal ceftazidime 2 mg and vancomycin 1 mg, as well as intravenous infusion of cefuroxime 750 mg, all administered simultaneously at 12-hour intervals. She also received topical levofloxacin eyedrops, once per hour. Subsequently, pathology culture confirmed the presence of the Gram-negative bacillus, *S. maltophilia*. The presence of lipopolysaccharide in intraocular fluid is an important early indicator of bacterial endophthalmitis, which can provide guidance for clinical treatment.

Keywords

Bacterial endophthalmitis, lipopolysaccharide, aqueous humor, *Stenotrophomonas maltophilia*, vancomycin, phacoemulsification

Date received: 16 February 2020; accepted: 6 May 2020

Introduction

Endophthalmitis following ocular surgery is the most common type of intraocular infection. Generally, the incidence of post-operative endophthalmitis ranges from 0.01% to 0.87%.¹ Endophthalmitis carries

Department of Ophthalmology, Beijing Chaoyang Hospital, affiliated with Capital Medical University, Beijing, China

Corresponding author:

Yong Tao, Department of Ophthalmology, Beijing Chaoyang Hospital, affiliated with Capital Medical University; No. 8, South Road of Worker's Stadium, Chaoyang District, Beijing 100020, China.
Email: drtaoyong@163.com



Creative Commons Non Commercial CC BY-NC: This article is distributed under the terms of the Creative Commons Attribution-NonCommercial 4.0 License (<https://creativecommons.org/licenses/by-nc/4.0/>) which permits non-commercial use, reproduction and distribution of the work without further permission provided the original work is attributed as specified on the SAGE and Open Access pages (<https://us.sagepub.com/en-us/nam/open-access-at-sage>).

a high risk for potential blinding, so patients require prompt and accurate medical treatment. Generally, it is difficult to confirm the etiological agent of endophthalmitis; thus, clinical diagnosis is subjective in that it is based upon the presence of anamnesis, systemic microbiological tests, and ophthalmological examinations.²

Lipopolysaccharide (LPS; also known as endotoxin) is the main component of the Gram-negative bacterial cell wall. LPS is released upon the death of these bacteria, which results in toxic effects on host cells.³ The most common bacterial host cells in the human body include monocytes, macrophages, and neutrophils. When these cells encounter LPS, they secrete inflammatory cytokines and chemokines, resulting in local tissue damage.⁴ In our experience, spectroscopic examination of LPS in intraocular fluid can provide an objective clinical diagnosis. This case report demonstrates rapid detection of LPS in ocular fluid can

aid in early diagnosis of patients with bacterial endophthalmitis.

Case report

In another hospital, a 66-year-old woman underwent uneventful topical clear corneal temporal phacoemulsification in the left eye. Topical povidone-iodine was applied to wash the conjunctival sac before surgery. The patient had no history of immunosuppression, autoimmune disease, or animal exposure. At 10 days postoperatively, she presented to our hospital with ocular redness and pain. Examination revealed flare grade 3+ and numerous floater in the anterior chamber, accompanied by hypopyon and reduced visual acuity. The fundal view was obscured by cloudy anterior aqueous (Figure 1). Vitreous and aqueous biopsy specimens were obtained, followed by administration of intravitreal antibiotics (ceftazidime 2 mg and vancomycin 1 mg

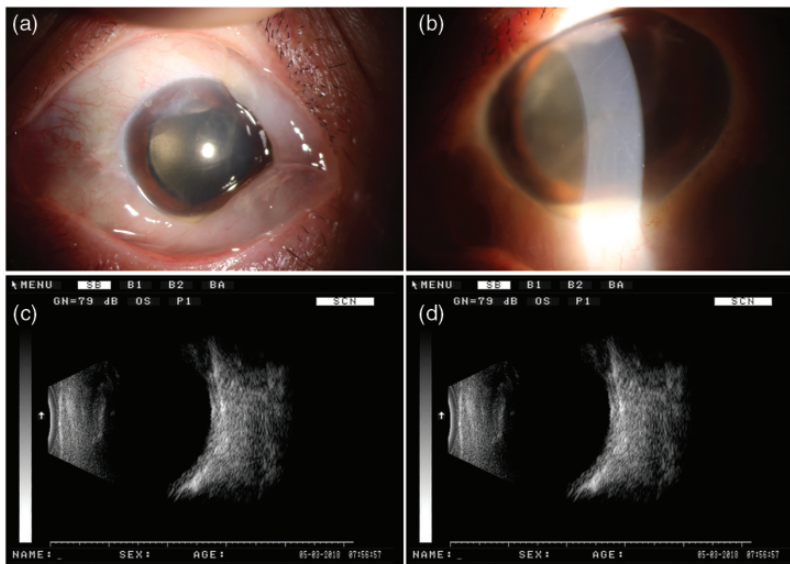


Figure 1. Preoperative images of anterior segment and B-ultrasound examination. (a, b) Clinical images of anterior segment showing corneal endothelial folds, dusty keratic precipitate, and hypopyon. (c, d) B ultrasound images showing clear vitreous.

every other day, two total treatments). Concurrent intravenous infusion of cefuroxime 750 mg was performed at 12-hour intervals; topical levofloxacin eyedrops were administered once per hour.

At 11 days postoperatively, the patient's pain was alleviated, floater cells were considerably reduced in the anterior chamber, and decimal visual acuity was improved to 0.02. Spectroscopic examination of intraocular fluid revealed LPS level of >2.5 (normal value <0.053 ; $0.053 \leq$ suspected or early infection ≤ 0.109 , positive value >0.109 ; these values were provided by the manufacturer of the kit, Zhanjiang A&C Biological Ltd, Guangdong Province, China) and interleukin (IL)-6 level of 70186.8 pg/mL; these findings were suggestive of bacterial endophthalmitis caused by Gram-negative bacteria. Thus, the patient continued treatment with ceftazidime, vancomycin, cefuroxime, and levofloxacin. At 13 days postoperatively, the patient exhibited considerably fewer floater cells in the anterior chamber and general disappearance of hypopyon. Gram staining and microscopy of aqueous biopsy specimens revealed only Gram-negative bacteria; no specific organisms were identified. At 15 days postoperatively, the Gram-negative bacillus *Stenotrophomonas maltophilia* was cultured. Subsequent antimicrobial susceptibility testing demonstrated that the isolate was susceptible to levofloxacin and minocycline. Thus, intravenous infusion of cefuroxime was continued for 7 days; topical levofloxacin eyedrops and prednisolone acetate 1% were administered four times per day. The hypopyon disappeared completely and the patient's decimal visual acuity improved to 0.3 (Figure 2). One month after the initial onset of ocular redness and pain (~ 40 days postoperatively), the patient's decimal visual acuity was 0.5; she exhibited a quiet eye and clear media. The patient provided written informed consent to publish this case report. This case

report was not required to be reviewed by the ethics review committee because it only involved discussion of a single patient and no exploratory treatment was performed.

Discussion

In our experience, the incidence of endophthalmitis has markedly increased with the growing popularity of cataract surgery and use of intravitreal injections. *S. maltophilia* is a Gram-negative bacillus, related to *Pseudomonas* sp., which is potentially pathogenic and exhibits a broad clinical spectrum. It can be isolated from water; soil; and some human, animal, or vegetable sources. *S. maltophilia* is an emerging entity associated with cluster endophthalmitis.⁵

A prior investigation of phacoemulsification-associated endophthalmitis revealed that *S. maltophilia* was present in irrigation fluid, aspiration hand pieces, and silicone aspiration tubing.⁶ Chen et al. reported the first instance of *S. maltophilia* endophthalmitis, which occurred in a patient with acquired immunodeficiency syndrome who had undergone intravitreal gancyclovir device implantation.⁷ Beri et al. reported the occurrence of post-intravitreal endophthalmitis due to contamination of a drug vial with *S. maltophilia*.⁸ Investigations of post-cataract surgery endophthalmitis have revealed that irrigation solution, autoclavable cassettes, and surgical equipment were commonly contaminated;^{6,8} these components should receive close monitoring.

The source of the infection in our patient remains unclear because the patient underwent cataract surgery in another hospital. Thus, no information was available regarding the surgical procedure or the irrigation fluids and tubing used during the operation. The only information available for analysis was the patient's intraocular fluid examination findings. Notably, the patient exhibited an aqueous humor LPS level of >2.5 and an

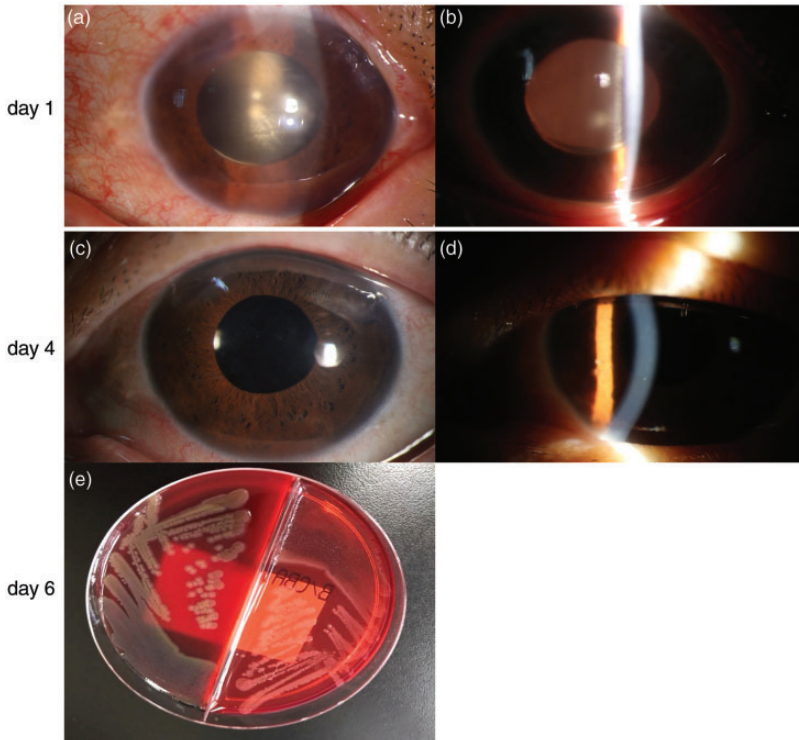


Figure 2. (a–d) Clinical images of anterior segment after medication treatment and (e) bacterial culture results of ocular specimen. After 1 day of intravitreal antibiotic treatment (ceftazidime 2 mg and vancomycin 1 mg), floater cells were substantially reduced and hypopyon was nearly absent from anterior chamber (a, b). After 3 days of antibiotic treatment, cornea was transparent and hypopyon was completely absent (c, d). After 5 days of antibiotic treatment, bacterial culture result confirmed presence of Gram-negative bacillus *Stenotrophomonas maltophilia* (e).

IL-6 level of 70186.8 pg/mL, both of which were considerably elevated. Clinical investigation of killed bacteria was previously found to cause LPS release, which led to secretion of tumor necrosis factor- α , IL-6, and IL-1 by mononuclear cells and resulted in clinical endophthalmitis.⁹ Thus, we presumed that the elevated LPS levels were indicative of bacterial endophthalmitis. At that stage of treatment, broad-spectrum antibiotics ceftazidime 2 mg and vancomycin 1 mg were administered intravitreally and cefuroxime was intravenously infused. Three days after initiation of antibiotics,

ocular symptoms were substantially alleviated, hypopyon was considerably reduced, and visual acuity was markedly improved. Five days after initiation of antibiotics, the pathology culture results confirmed that the causative agent was *S. maltophilia*. This report demonstrates that rapid detection of LPS in intraocular fluid suggested the possibility of bacterial infection, which led to timely treatment and may have rescued the patient's vision. Furthermore, we investigated the intraocular fluid LPS level in control patients with cataract (all of whom did not exhibit endophthalmitis)

Table 1. Lipopolysaccharide levels of patients with cataract who did not exhibit endophthalmitis.

Patient Number	Sex	Age (years)	LPS level	IL-6 level
1	Female	31	0.0688	n.d.
2	Male	74	<0.025	n.d.
3	Male	66	0.107	n.d.
4	Male	68	<0.025	2.6
5	Male	56	<0.025	86.5

Abbreviations: LPS, lipopolysaccharide; n.d., not detected.

and found that elevated LPS was not present in these patients (Table 1).

Conclusion

LPS detection in intraocular fluid is an important early indicator of bacterial endophthalmitis, which can provide guidance for clinical treatment. Prompt and accurate antibiotic treatment can preserve vision and achieve an excellent clinical outcome.


Declaration of conflicting interest


The authors declare that there is no conflict of interest.

Funding

This work was supported by the Beijing Chaoyang 1351 talent training program (grant no. CYXX-2017-21).

ORCID iDs

Li Chen  <https://orcid.org/0000-0002-6595-0555>

Yong Tao  <https://orcid.org/0000-0003-1443-2667>

References

- Krause L, Bechrakis NE, Heimann H, et al. Incidence and outcome of endophthalmitis over a 13-year period. *Can J Ophthalmol* 2009; 44: 88–94.
- Kelkar AS, Kelkar JA, Barve PM, et al. Post-clear corneal phacoemulsification endophthalmitis: profile and management outcomes at a tertiary eye care center in western India. *J Ophthalmic Inflamm Infect* 2016; 6: 48.
- Alexander C and Rietschel ET. Bacterial lipopolysaccharides and innate immunity. *J Endotoxin Res* 2001; 7: 167–202.
- Callegan MC, Gilmore MS, Gregory M, et al. Bacterial endophthalmitis: therapeutic challenges and host–pathogen interactions. *Prog Retin Eye Res* 2007; 26: 189–203.
- Boeke PS and Gottlieb JL. *Stenotrophomonas maltophilia* endophthalmitis 1 month after intravitreal aflibercept. *Retin Cases Brief Rep* 2019; 13: 327–328.
- Williams MA, Gramajo AL, Colombres GA, et al. *Stenotrophomonas maltophilia* endophthalmitis caused by surgical equipment contamination: an emerging nosocomial infection. *J Ophthalmic Vis Res* 2014; 9: 383–387.
- Chen S, Stroh EM, Wald K, et al. *Xanthomonas maltophilia* endophthalmitis after implantation of sustained-release ganciclovir. *Am J Ophthalmol* 1992; 114: 772–773.
- Beri S, Shandil A and Garg R. *Stenotrophomonas maltophilia*: an emerging entity for cluster endophthalmitis. *Indian J Ophthalmol* 2017; 65: 1166–1171.
- Krzywon C, Zähringer U, Kawahara K, et al. Glycosphingolipids from *Sphingomonas paucimobilis* induce monokine production in human mononuclear cells. *Infect Immun* 1995; 63: 2899–2905.