

Open Posterior Reduction and Stabilization of AO Spine C3 Sacral Fractures

Philipp Kobbe, MD,* Gregory D. Schroeder, MD,† Klaus J. Schnake, MD,‡§
Lorin M. Benneker, MD,|| Mark Lambrechts, MD,† Frank Hildebrand, MD,*
and Richard M. Sellei, MD¶

Abstract: AO Spine C3 sacral fractures are defined by separation of the spine including S1 from the pelvic ring and are usually result of a high-energy injury. Besides their high biomechanical instability and high rate of associated neurological impairment, these fractures are often extremely difficult to reduce due to severe bony impaction and dislocation. Additional difficulties in management of these fractures arise from only a thin-layer of soft-tissue coverage overlying the injured area.

Key Words: transverse sacral fracture, suicidal jumper's fracture, U-shaped sacral fracture, H-type sacral fracture, spinopelvic dissociation

(*Clin Spine Surg* 2023;36:54–58)

INDICATIONS

Open posterior reduction and stabilization for AO Spine C3 sacral fractures is indicated if

Received for publication December 19, 2021; accepted August 17, 2022. From the *Department for Orthopedics, Trauma and Reconstructive Surgery, University Hospital RWTH, Aachen, Germany; †Rothman Orthopaedic Institute at Thomas Jefferson University, Philadelphia, PA; ‡Center for Spinal and Scoliosis Surgery, Malteser Waldkrankehaus St. Marien, Erlangen, Germany; §Department of Orthopedics and Traumatology, Paracelsus Private Medical University Nuremberg, Nuremberg, Germany; ||Orthopedic Department, Sonnenhofspital, University of Bern, Bern, Switzerland; and ¶Department for Orthopedics and Trauma, Sana Klinikum Offenbach, Offenbach, Germany. This study was supported by AO Spine through the AO Spine Knowledge Forum Trauma, a focused group of international Trauma experts. AO Spine is a clinical division of the AO Foundation, which is an independent medically guided not-for-profit organization.

Schroeder has received funds to travel from AO Spine and Medtronic. The remaining authors declare no conflict of interest.

Reprints: Philipp Kobbe, MD, Department for Orthopedics, Trauma and Reconstructive Surgery, University Hospital RWTH, Aachen 52070, Germany (e-mail: pkobbe@ukaachen.de).

Supplemental Digital Content is available for this article. Direct URL citations appear in the printed text and are provided in the HTML and PDF versions of this article on the journal's website, www.jspinaldisorders.com.

Copyright © 2022 The Author(s). Published by Wolters Kluwer Health, Inc. This is an open access article distributed under the terms of the Creative Commons Attribution-Non Commercial-No Derivatives License 4.0 (CCBY-NC-ND), where it is permissible to download and share the work provided it is properly cited. The work cannot be changed in any way or used commercially without permission from the journal.

- Insufficient closed reduction is achieved after hyperlordotic/distracting maneuvers.
- Spinal canal/nerve root decompression is required.

CONTRAINDICATIONS

- Severely contused or crushed soft-tissue of the lumbosacral junction may present a contraindication to this procedure in neurologically intact patients.^{1–3} In this case, open reduction and stabilization should be postponed until the soft-tissues are adequately restored to allow for postoperative incisional closure.

OPERATIVE ROOM SETUP

Instruments/materials required:

- Standard spinal instrumentation.
- Polyaxial or monoaxial pedicle screw/rod system with ilium screws (length > 70 mm, diameter > 7.5 mm).
- A measure of 6.5 or 7.0 mm cannulated screw system for SI/transiliac screws.
- Schanz screw system.
- Intraoperative fluoroscopy.
- Radiolucent OR table.
- Cell saver.

POSITIONING

The patient is positioned prone on a standard radiolucent operating table. Positioning should consider the type of sacral dislocation. Predominantly, these fractures have a kyphotic deformity benefiting from a hyperlordotic positioning of the lumbosacral junction. This may be achieved by allowing a sagging abdomen or by v-shaped flexion of the OR table. Additional, femoral traction with distal femoral pins may ease later reduction.

Intraoperative imaging should include the ability to obtain inlet, outlet, and lateral pelvis views. Draping is performed with access to the following landmarks: the posterior iliac crest, the spinal process of L4, and the upper end of the gluteal cleft.

SURGICAL TECHNIQUE

Incision and Exposure

Careful soft-tissue handling is mandatory in posterior open fracture reduction and stabilization, because wound

healing problems present a major complication of this procedure, especially in patients requiring long-term ICU treatment.

In general, a midline incision, starting from L4 to S2, is performed. The length of the incision may vary according to the length of the planned instrumentation and the degree and location of the decompression. After sharp dissection of the epidermis, electrocautery is used to dissect the lumbosacral fascia on both sides of the spinous processes. This is followed by cautious subperiosteal elevation of the lumbosacral musculature to expose the posterior aspect of the sacrum. The musculature and even the fascia may, however, already be extensively traumatized due to the injury. In this instance, the soft tissues may be bluntly dissected.

In cases with severe soft-tissue injury, the surgical approach has to be adapted either to a percutaneous or a limited open approach.⁴ In short, limited open approaches allow for minimal detachment of the erector spinae musculature insertion from the pelvis, leading to a reduction in soft-tissue complications. At the site of the iliac screw entry point, the lumbosacral fascia is sharply dissected from the pelvic rim to safely place and countersink the iliac screw, which can then be followed by blunt mobilization of the erector spinae musculature in a medial to lateral fashion. The final construct is later tunneled under the mobilized muscle. This limited open approach helps to reduce interference with the musculature blood supply and reduces later soft-tissue complications; however it also limits visualization of the fracture and the reduction technique.

Special Considerations

For adequate fracture reduction and stabilization, it is important to understand the main characteristic of these fractures. In AO Spine C3 sacral fractures, the spine and proximal sacrum, including S1, is dissociated from the pelvis. Thus, for mechanical stability the S1 requires reattachment to the pelvis. Although this may be achieved

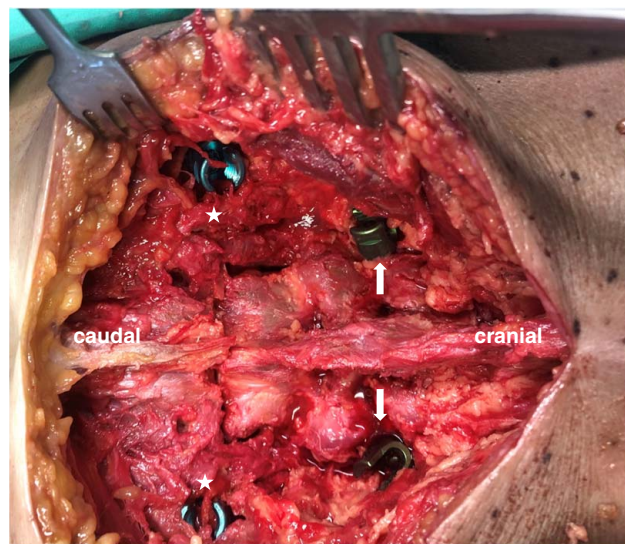


FIGURE 1. Intraoperative situs with an AO C3 sacral fracture (U-type). Ilium (white asterisk) and L5-pedicle (white arrow) screws are already placed. full color online

through closed reduction and percutaneous iliosacral screw placement, this is often biomechanically insufficient, because the sacrum is unable to distribute load throughout the caudal lumbar spine and pelvis as is normally achieved with spinopelvic L5 to ilium stabilization.

Screw Placement

L5 pedicle and ilium screws should be placed before decompression and/or reduction because a decompressed dural sac is endangered during pedicle screw placement and these screws can provide support for fracture reduction. Once the entry point at L5 is identified, the screw path is prepared with an awl and a monoaxial or polyaxial

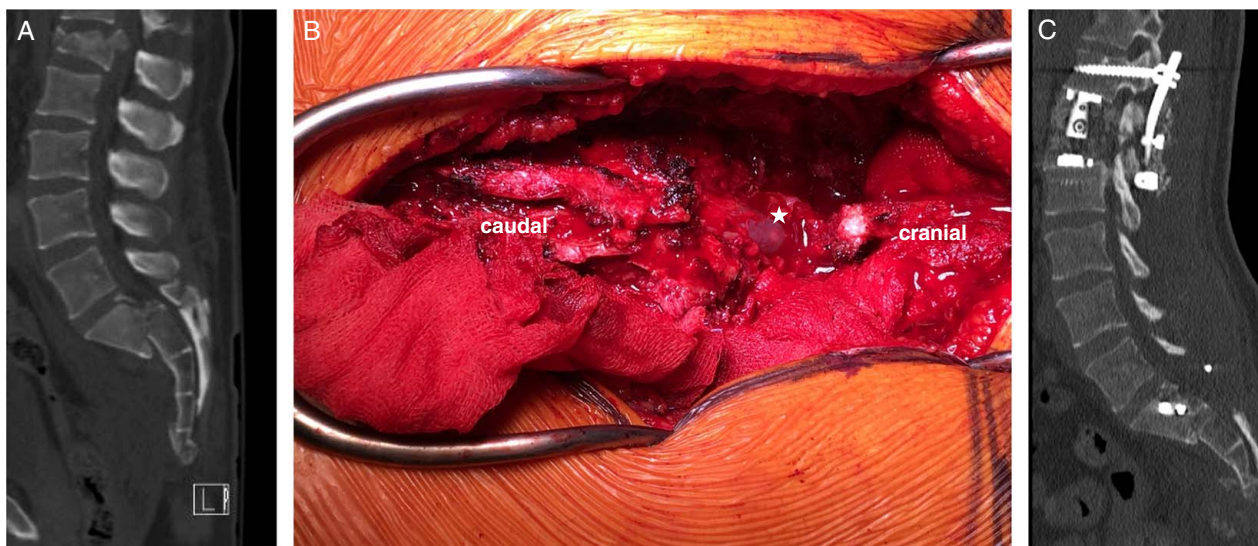


FIGURE 2. A, Computed tomography scan showing an impacted AO C3 sacral fracture with obstruction of the spinal canal and clinically neurological impairment. B, Intraoperative situs showing the decompressed dural sac (white asterisk). C, Postoperative computed tomography scan showing posterior decompression and reduction of the AO C3 sacral fracture. full color online

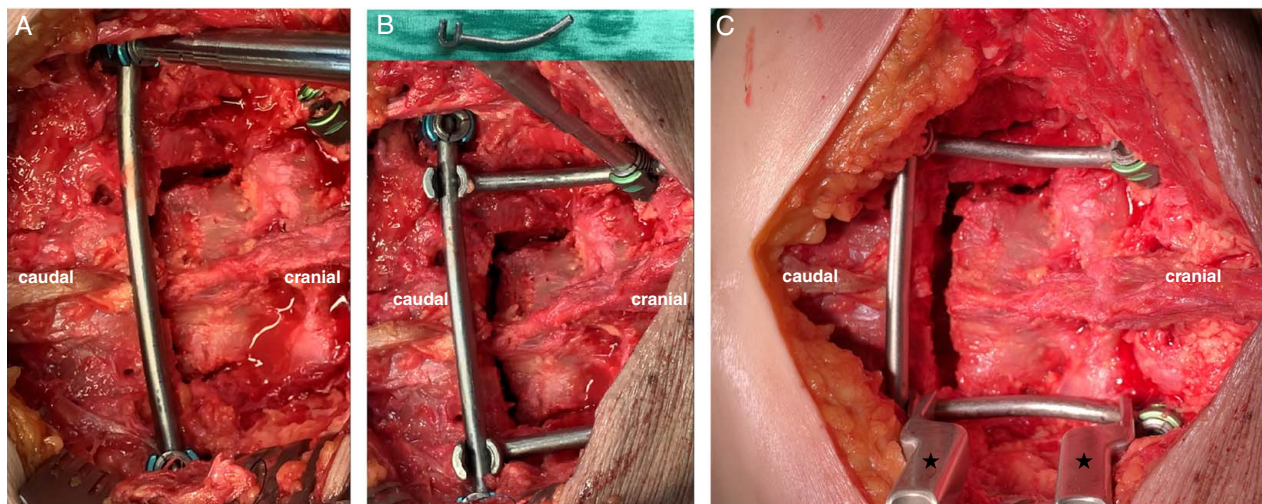


FIGURE 3. A, Connection of both ilium screws with a conventional rod giving high rotational stability for the final construct. B, Attachment of the ilium screws to the transverse rod with lordotic contoured connection-rods. C, Careful distraction with a distraction device (black asterisk) showing deimpaction and partly reduction of the fracture. full color online

pedicle screw is inserted. The same procedure is carried out for the ilium screw with a desired screw length of at least 80 mm in order to move the lumbosacral pivot point as anterior as possible. Before screw insertion, a small part of the ilium crest is resected to allow screw head countersinking and to avoid soft tissue irritation (Fig. 1).

If there is concern for insufficient fixation points, then more cranial (eg, L4 pedicle screw) and caudal (eg, second ilium screw) fixation levels can be added. Screw placement can be facilitated by navigation, but it must always be taken into account that navigation cannot detect segmental movements below or above the reference clamp during surgical manipulation. This risk exists especially when using navigation for highly unstable injuries.

Neural Decompression

AO Spine C3 sacral fractures have a high likelihood of neurological impairment. The computed tomography

(CT)-scan helps to decide whether an indirect decompression by reduction, an isolated decompression of sacral nerve roots, or a decompression of the dural sac is indicated. Sacral nerve root decompression can usually be achieved by removing bony fragments from the comminuted fracture zone, whereas dural sac decompression requires laminectomy followed by fracture reduction (Fig. 2).

Reduction

Due to the high-energy mechanism of injury, AO Spine C3 sacral fractures are often accompanied by displacement. In general, these fractures show a kyphotic impaction between S1 and S2, requiring distraction and a lordotic maneuver for reduction (Video, Supplemental Digital Content 1, <http://links.lww.com/CLINSPINE/A249>).

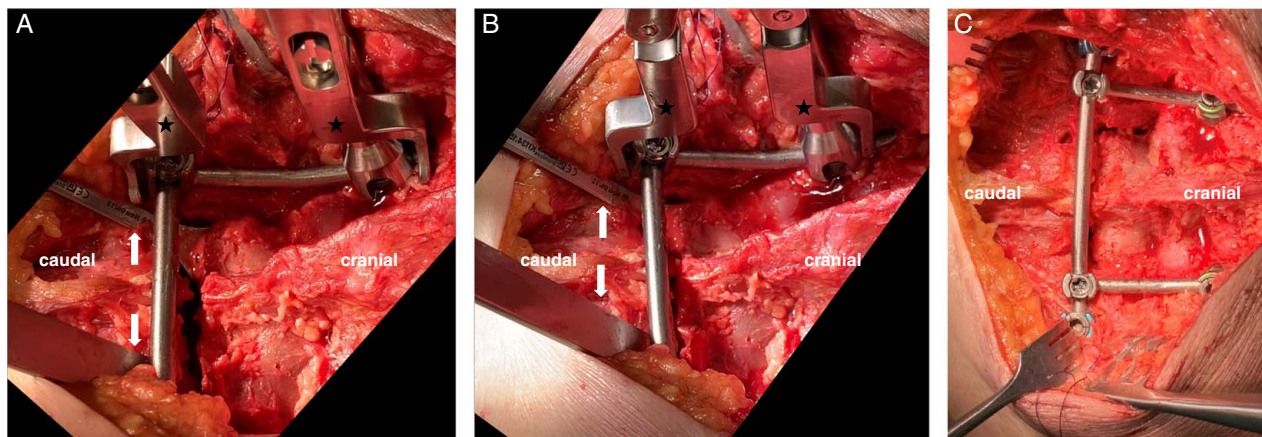


FIGURE 4. A, Careful compression with a compression device (black asterisk). Two Cobb raspatories (white arrow) are carefully inserted just below the lamina and serve as hypomochlion during compression in order to prevent kyphotic dislocation. B, Closure of the fracture after compression. C, Final fracture reduction and retention. full color online

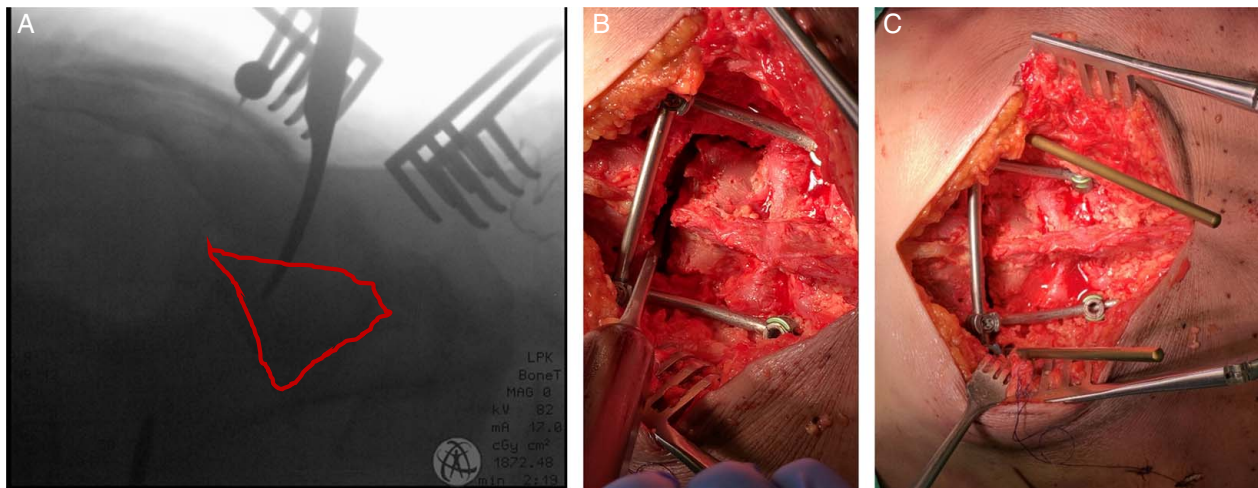


FIGURE 5. A, Insertion of a Cobb raspatorium through the fracture in order to manipulation the fragments. In addition, a ball spike pusher is used. B, Intraoperative situs with the Cobb raspatorium inserted. C, Insertion of additional Schanz screws in the ileum in order to allow manipulation of the pelvis. [full color online](#)

The first step during reduction is to unimpact the fracture zone which requires distraction/restoration of length. Several tools like bilateral femoral traction with distal femoral pins or the AO-distractor with inserted Schanz screws in the L5-pedicles and the ilium have been described; we prefer to use the already placed L5-pedicle and ilium screws connected with rods to perform a distraction maneuver (Fig. 3). Once distracted, the fracture has to be cleaned of hematoma and bony fragments which may hinder further reduction and may compromise sacral nerve roots. The final lordotic maneuver can be achieved by compression of the lordotic contoured rods (Fig. 4) and may be supported by additional leg-raise or tilting the pelvis with help of additional Schanz screws.

In case there is continued dislocation of the distal sacrum, a more aggressive reduction maneuver may be necessary. Therefore, a Cobb raspatorium is inserted through the fracture to manipulate and reduce the

dislocation (Fig. 5). This may require sacral laminectomy to mobilize and protect the dural sac. Ball spike pushers and inserted Schanz screws may help to reduce the remaining translation, which is controlled by lateral fluoroscopy. Depending on the fracture line, ilium screws may be radiographically overlapping the fracture and may cause misinterpretation of the final reduction.

Following, adequate reduction, the final construct is tightened. The construct shown here offers rotational stability due to the rod connecting both ilium screws (Fig. 6). In case another connection is preferred, at least one transverse stabilizer should be attached to avoid rotational deformity.

Transiliac Screw Placement

Following reduction, the mechanical stability of the spinopelvic construct can be further increased by fixation of the separated S1 with the ilium. This can be achieved either with a long transiliac S1 or with shorter S1-SI screws on each side; both resulting in a triangular stabilization.^{5,6} Due to better screw purchase, we prefer transiliac S1 screws. However, this requires adequate fracture reduction and exclusion of a dysmorphic sacrum. Ideally, the guide-wire appears as a dot in lateral fluoroscopy just below the iliac terminal line. Guide-wire positioning is verified in inlet-views and outlet-views. The final length of the inserted screw is checked in inlet-obturator view (Fig. 7).

In case of a dysmorphic sacrum transiliac S2 screws may be an option depending on the fracture morphology. Only if the S2 is separated from the pelvis this type of screw will increase mechanical stability.

Wound Closure

After insertion of a drain, closure of the wound is initiated by gentle repositioning of the erector spinae muscles and reattachment of the superior origin of the gluteus maximus. Due to the high infection rate the local

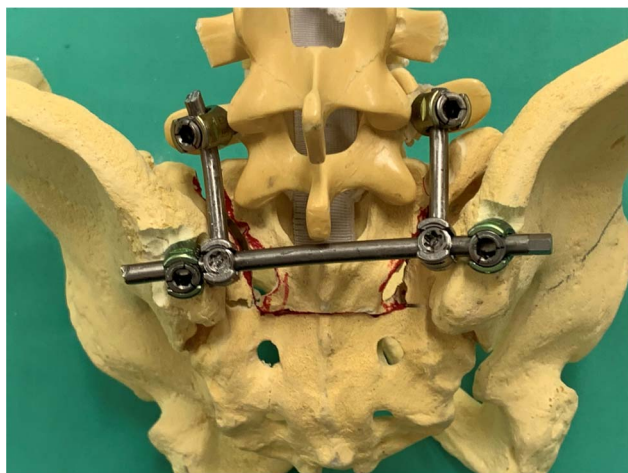


FIGURE 6. Final spinopelvic construct. [full color online](#)

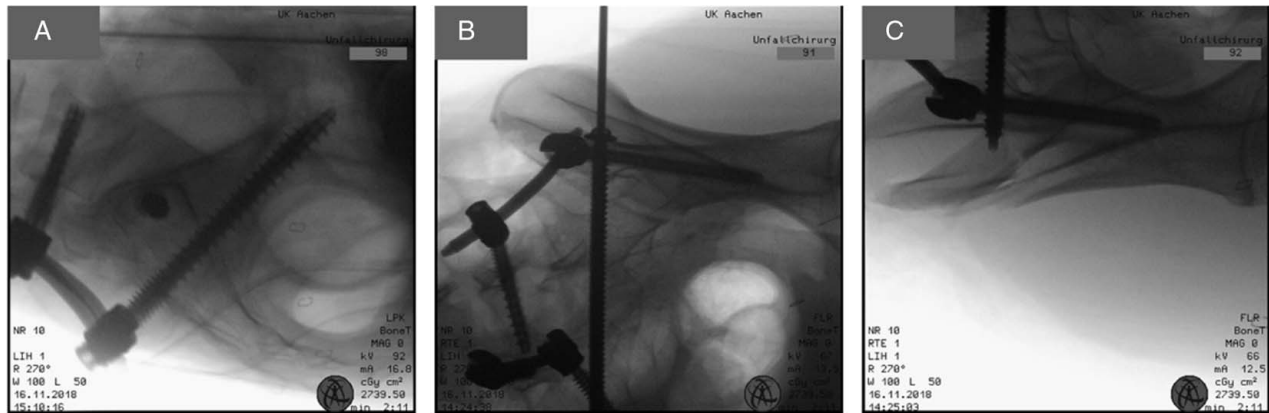


FIGURE 7. Insertion of a transiliac S1 screw. A, Screw appearing as a dot in the lateral view below the terminal line. B, Inlet-obturator view to verify screw/washer contact to the lateral iliac wing. C, Inlet-obturator view of the other side to verify screw length and penetration of the cortex of the contralateral side.

application of 1–2 g vancomycin under and over the fascia might be an option. If possible, the fascia should be closed followed by suture of the subcutaneous tissues and skin in layers. Dressing with padding of the incision, especially for ICU patients with expected prolonged supine positioning, is advantageous.

Postoperative Protocol

Wound problems are not seldom in this region. It is crucial to avoid infection with gastrointestinal bacteria. Therefore, a precise postoperative wound plan is necessary and the intraoperative wound dressing should be watertight. Ideally, wound inspections are possible through a transparent wound dressing avoiding unnecessary changes of the wound dressing with the risk of smear infection. Prophylaxis for deep vein thrombosis and pulmonary embolus is crucial unless contraindicated. Physical therapy should begin as soon as possible to enable the patient to independently transfer to a (wheel)chair. Full weight-bearing is allowed between 8 and 12 weeks but is dependent on several factors (eg, patient's body weight, degree of initial dislocation, intraoperative bone quality, stiffness of final construct). Hardware removal, usually after 6–9 months, is an option after CT-confirmed fracture healing.

Complications

- Unsatisfying reduction.
- Wound infection.

- Nonunion.
- Neurological impairment.
- Deep vein thrombosis.

Pearls and Pitfalls

- Preoperative study of the CT-scan to understand the direction of required manipulation for adequate reduction.
- Countersink ilium screws to avoid soft-tissue irritation.
- Gentle soft-tissue handling.
- Be aware of the reduction potential of a pedicle screw rod system.

REFERENCES

1. Roy-Camille R, Saillant G, Gagna G, et al. Transverse fracture of the upper sacrum. Suicidal jumper's fracture. *Spine*. 1985;10:838–845.
2. Gribnau AJ, Van Hensbroek PB, Haverlag R, et al. U-shaped sacral fractures: surgical treatment and quality of life. *Injury*. 2009;40:1040–1048.
3. Schildhauer TA, Bellabarba C, Nork SE, et al. Decompression and lumbopelvic fixation for sacral fracture-dislocations with spino-pelvic dissociation. *J Orthop Trauma*. 2006;20:447–457.
4. Keel MJ, Benneker LM, Siebenbrock KA, et al. Less invasive lumbopelvic stabilization of posterior pelvic ring instability: technique and preliminary results. *J Trauma*. 2011;71:E62–E70.
5. Schildhauer TA, Josten C, Muhr G. Triangular osteosynthesis of vertically unstable sacrum fractures: a new concept allowing early weight-bearing. *J Orthop Trauma*. 2006;20(suppl):S44–S51.
6. Schildhauer TA, Ledoux WR, Chapman JR, et al. Triangular osteosynthesis and iliosacral screw fixation for unstable sacral fractures: a cadaveric and biomechanical evaluation under cyclic loads. *J Orthop Trauma*. 2003;17:22–31.