

# Posterior Glenohumeral Capsular Reconstruction With Modified McLaughlin for Chronic Locked Posterior Dislocation



Graeme Matthewson, M.D., MS.c (C)., and  
Ivan H. Wong, M.D., F.R.C.S.C., M.A.cM., Dip. Sports Med

**Abstract:** Posterior instability is relatively rare when compared with anterior instability but can comprise up to 40% of operatively treated instability cases. Posterior dislocations are much rarer and are classically due to trauma, seizure, or electric shock. Due to a lack of an obvious deformity and an internally rotated and adducted arm position, posterior shoulder dislocations often are missed on initial presentation. In the management of posterior dislocations, considerations need to be made in regard to bony and soft-tissue pathology. In the setting of soft-tissue deficiency, previous options included nonoperative management primarily consisting of bracing and activity modification as well as arthroplasty options that do not rely on the capsulolabral complex for stability. In this paper, we present a technique for treating a chronic posterior shoulder dislocation with an associated large reverse Hill–Sachs deformity. In this setting, a revision labral repair and capsulodesis is generally not possible due to insufficient capsulolabral tissues. Here, we present the technique for an arthroscopic posterior capsule reconstruction using an acellular dermal allograft as well as a McLaughlin procedure for the treatment of a reverse Hill–Sachs lesion.

Posterior instability is rare in comparison with anterior instability and accounts for approximately 10% of all shoulder instability cases<sup>1,2</sup> and <4% of all shoulder dislocations<sup>3</sup>; however, they comprise up to 40% of operatively treated instability cases among a young military population.<sup>4</sup> Unlike anterior instability, it is quite rare for posterior instability to develop following an acute dislocation.<sup>5</sup> Rather, instability develops following repetitive subluxation events during posterior-loaded sporting activities such as weightlifting, football linemen positions, as well as the military

population due to repetitive combative and exercise-related activities.<sup>4</sup> Those at increased risk for posterior shoulder instability include male intercollegiate athletes as a group as well as men and women participating in wrestling and football.<sup>6</sup> Posterior dislocations of the glenohumeral joint are much rarer; however, they can lead to considerably worse outcomes due to the secondary pathology. The etiology of posterior dislocations in a review performed by Xu et al.<sup>3</sup> includes trauma (59%), seizure (40%), and electric shock (1%).

The presenting complaints of a patient suffering from posterior instability are generally related to pain and weakness rather than frank instability<sup>7</sup> and often is missed on initial examination, a “diagnostic trap” as per McLaughlin.<sup>8</sup> In posterior dislocation, due to the lack of obvious deformity and an internally rotated and adducted position of comfort, up to 50% of shoulder dislocations are missed on initial evaluation,<sup>9</sup> and a delay in appropriate treatment can last up to 10 years.<sup>3</sup> Treatment of posterior shoulder dislocations lies in prompt recognition, which requires a high index of suspicion and expeditious reduction and stabilization. Secondary pathology related to a chronic dislocation includes degeneration of the posterior capsulolabral complex as well as a large reverse Hill–Sachs lesions.<sup>10</sup> In this setting, there can be insufficient tissue for

From the Pan Am Clinic, University of Manitoba, Winnipeg, Manitoba (G.M.); and Division of Orthopaedic Surgery, Department of Surgery, Faculty of Medicine, Dalhousie University (I.W.), Halifax, Nova Scotia, Canada.

The authors report that they have no conflicts of interest in the authorship and publication of this article. Full ICMJE author disclosure forms are available for this article online, as [supplementary material](#).

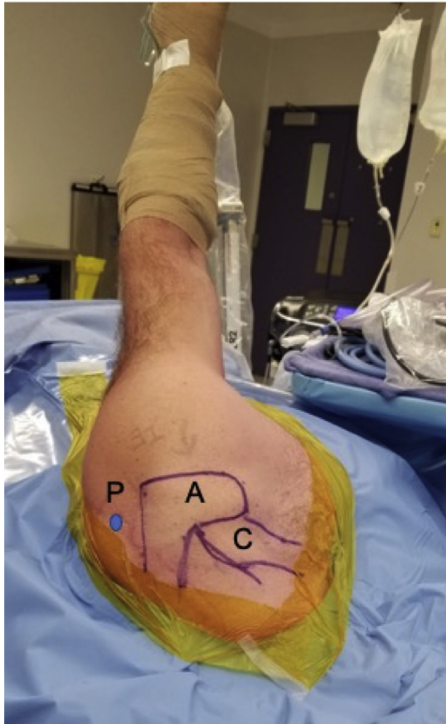Received May 24, 2019; accepted August 12, 2019.

Address correspondence to Dr. Ivan H. Wong, Division of Orthopaedic Surgery, Department of Surgery, Faculty of Medicine, Dalhousie University, Halifax, NS, Canada B3H2E1. E-mail: [iw@drivanwong.com](mailto:iw@drivanwong.com)

© 2019 by the Arthroscopy Association of North America. Published by Elsevier. This is an open access article under the CC BY-NC-ND license (<http://creativecommons.org/licenses/by-nc-nd/4.0/>).

2212-6287/19671

<https://doi.org/10.1016/j.eats.2019.08.004>



**Fig 1.** Picture of a patient placed in the lateral decubitus position, left shoulder, with the use of a bean bag positioner and SPIDER limb positioner. The bony landmarks of the borders of the acromion, clavicle, acromioclavicular joint, and scapular spine are marked as well as the posterior portal 1 cm inferior to the posterolateral corner. (A, acromion; C, clavicle; P, portal site marked in blue.)

posterior labral repair or capsular plication, which leaves the surgeon with few options outside of arthroplasty to treat this difficult condition. In the setting of a chronic posterior dislocation, the surgeon must consider all aspects of stability, including glenoid and humeral bone loss, as well as the quality and quantity of remaining soft tissues such as the glenoid labrum and posterior capsule. The purpose of this technical paper is

to describe our preferred approach to the treatment of a chronically posteriorly dislocated shoulder with capsular insufficiency and a large reverse Hill–Sachs lesion.

## Surgical Technique

### Preoperative Assessment

The patient is first seen in clinic and a focused history and physical examination is performed. Issues surrounding the most recent dislocation event including duration of dislocation, mechanism of injury, and previous episodes of instability are documented. Pain to the posterior aspect of the shoulder rather than instability is the most common complaint of patients with recurrent instability.<sup>3,11,12</sup> Patients with a chronically dislocated shoulder complain of persistent pain and commonly present with a posterior deformity of the humeral head with a flattening at the anterior aspect of the shoulder and oftentimes a fixed internal rotation deformity with limited abduction.<sup>13</sup> As compared with an acute dislocation, chronic posterior dislocations can have an increased range of motion (ROM), due to subtle motion that wears away the contact area between the humeral head and glenoid. Due to the restricted ROM, these patients often will have limited ability for physical examination and the aforementioned ROM deficits. In all cases of recurrent instability, there should be a note made of the Beighton criteria<sup>14</sup> of generalized ligamentous laxity, as this can influence prognosis and treatment decisions. Initial imaging for a suspected posterior dislocation should begin with plain radiographs and, if indeterminate, should progress to computed tomography (CT) imaging. In the setting of recurrent dislocations, a CT image should be taken regardless to ascertain the degree of humeral and glenoid bone loss. A 3-dimensional replica of the patient's shoulder is then printed from the CT reconstructions to aid in pre- and intraoperative planning. In a chronically

**Table 1.** Pearls and Pitfalls of the Technique

Pearls	Pitfalls
Use of a 3-dimensional model for preoperative planning and graft measurement	Suture tangling
Use of a leading stitch to aid in graft shuttling	Suture management and retrieval
Superior marking on the graft to aid in proper orientation of the graft intra-articularly	Graft orientation and twisting
Suture management	Failure to recognize and address significant glenoid bone loss
<ul style="list-style-type: none"> <li>• Place the humeral anchors first and pass the suture ends extra-articularly to aid in graft shuttling and orientation</li> <li>• Place and secure glenoid anchors in a sequential manner from inferior to avoid suture tangling and maintain adequate visualization</li> </ul>	

**Table 2.** Advantages and Disadvantages of the Technique

Advantages	Disadvantages
Posterior Capsular Reconstruction	
Minimally invasive technique	Advanced technique
Alternative option to arthroplasty in the young and active patient	Steep learning curve
Does not limit future procedures such as arthroplasty	Graft tangling
Restores humeral head concentricity	
Cadaver tissue with the potential for less attenuation in collagen disorders	No long-term outcomes
McLaughlin	
Creates an extra-articular defect (nonengaging lesion)	Subscapularis tears with failure
Not limited by graft resorption/incorporation (boney procedures)	

dislocated shoulder, operative intervention should occur on an urgent basis.

### Anesthesia and Patient Position

After the patient is brought to the room, they are placed on the operative table on a bean bag positioner and antibiotic prophylaxis is given followed by anesthesia. The patient is then placed in the lateral decubitus position, with 30° of posterior angulation to align the glenoid with the floor. Following anesthesia, a closed reduction is performed before portal placement. The operative shoulder and axilla are then prepped and draped in sterile fashion. The patient's arm is then placed in 60° of abduction, and traction is applied with the use of a SPIDER Limb Positioner (Smith & Nephew, London, England).

Once prepped, the bony landmarks of the shoulder are marked out including the borders of the acromion, clavicle, acromioclavicular joint, and scapular spine (Fig 1). The posterior portal is also marked in a position 1 cm inferior to the posterolateral corner of the acromion with the anterior superior and anterolateral portals to be determined arthroscopically (Fig 1).

### Diagnostic Arthroscopy and Debridement

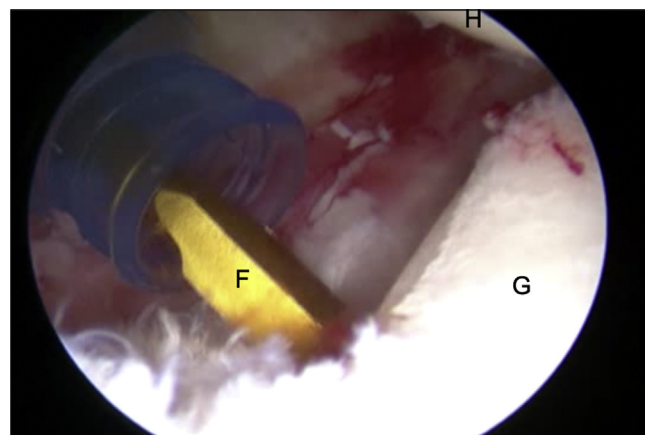
The complete surgical technique can be seen in Video 1. The pitfalls and pearls are summarized in Table 1 and the advantages and disadvantages are summarized in Table 2. A diagnostic arthroscopy is completed in standard fashion from the posterior portal. In particular, attention is paid to the capsulolabral complex, posterior glenoid rim, as well as any humeral defects or "reverse" Hill–Sachs lesions. In addition, the rotator cuff tendons, biceps tendon, cartilage of the humeral head, and glenoid are examined for any tearing or signs of degeneration. Following this, the anterior superior and anterior inferior portals are then made with an outside-in technique, allowing for examination of the posterior labrum and capsular structures through the anterior superior portal. A large 10 × 40-mm PassPort Cannula (Arthrex, Naples, FL) is then placed in the posterior portal to allow passage of the graft intra-articularly.

In the case of a chronic dislocation, the capsulolabral components are quite scarred down medially on the

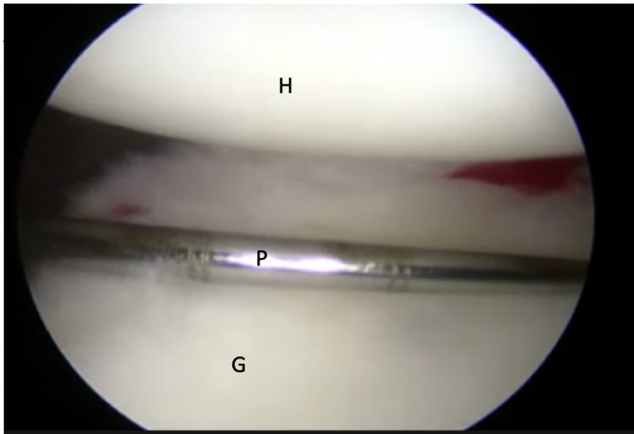
glenoid neck and have to be addressed from the posterior portal (Fig 2) while viewing from the lateral portal. A Liberator (Linvatec) is used to lift and free the labrum and posterior capsule from the posterior glenoid, where it is often scarred down. The posterior labrum tissue is then assessed and repaired if possible, but in the case of a chronic dislocation, there typically is no viable tissue to repair. The posterior glenoid is then decorticated, and a bleeding bone bed is prepared using a shaver or burr followed by decortication of the humeral head neck junction using a curette, for eventual placement of the graft. The glenoid face is then measured from the posterior portal using a measurement probe and the diameter is assessed for adequate bone stock (Fig 3). With the shoulder in neutral rotation and 60° of abduction, the distance from the posterior glenoid to the humeral head neck junction is measured and compared with previous measurements obtained from the preoperative model.

### Graft Preparation

The Allopatch allograft acellular human dermal matrix (MTF Biologics; CONMED, Largo, FL) is prepared on the back table. Based on previous measurements from the CT-reconstructed model as well as those confirmed intraoperatively, a custom graft is cut to size.



**Fig 2.** Posterior glenoid (G) debridement with the use of a Freer Elevator (F) (Sklar Instruments, West Chester, PA), patient in lateral decubitus position, left shoulder, viewing from the anterosuperior portal. (H, humerus.)

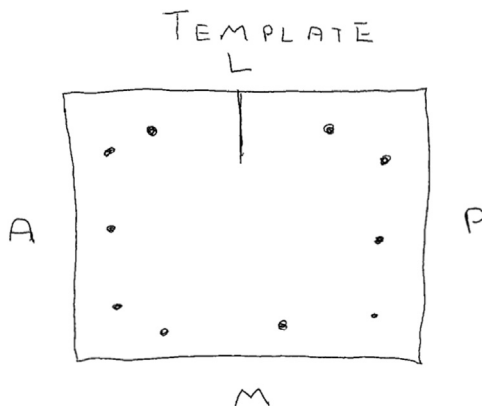


**Fig 3.** Glenoid (G) measurement using a calibrated probe (P) from the posterior portal viewing from the anterosuperior portal. (H, humerus.)

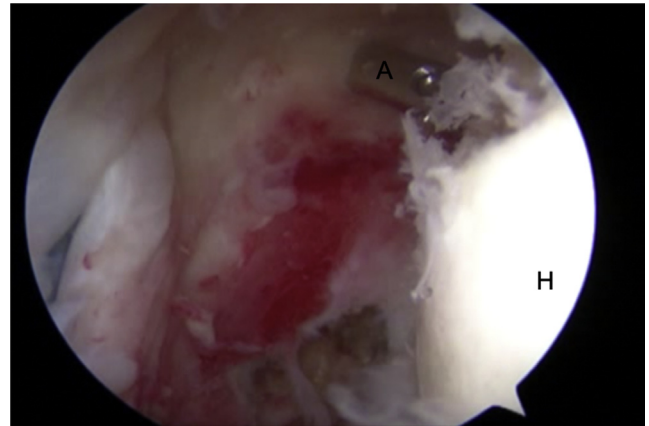
Suture markings are then created on the graft with 2 sites marked on the humeral side and 3 marked on the glenoid side (Fig 4). These markings will be seen intra-articularly and thus are placed on the nonhealing (dull side) side of the graft. A line is drawn on the superior aspect of the graft to help with intra-articular orientation. The graft is stored in saline before introduction into the shoulder joint.

#### Anchor Placement and Graft Passage

In total, 5 suture anchors are used for graft fixation. First, while viewing from the anterosuperior portal, 2 double-loaded Q-Fix all suture anchors (Smith & Nephew) are placed (Fig 5). The inferior humeral anchor is inserted via a percutaneous technique, whereas the superior anchor is passed through the posterior cannula. The suture limbs are then retrieved through the posterior cannula, leaving one suture limb to aid in graft shuttling through the percutaneous opening. The corresponding sutures are then passed through the humeral side of the graft from inferior to superior




**Fig 4.** Road map diagram of the Allopatch configuration. (A, anterior side; L, lateral [humeral] side; M, medial [glenoid] side; P, posterior side.)



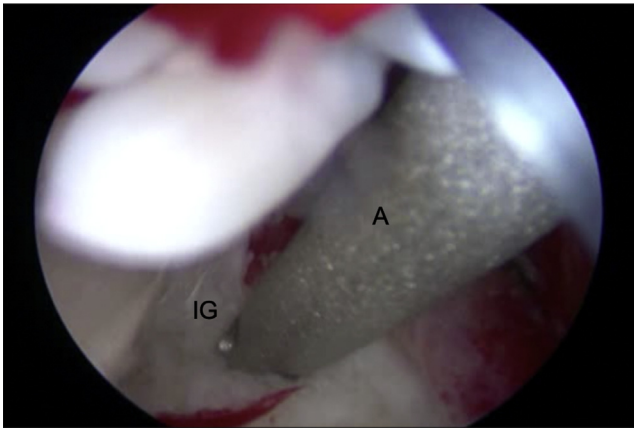
**Fig 5.** Percutaneous placement of the inferior humeral anchor (A) into the humerus (H) posteriorly, patient in lateral decubitus position, left shoulder, viewing from the posterior portal.

(superior = marked, nonhealing side). A leading suture is placed through the graft and secured using a STIK knot and the end is passed through the joint from posterior to anterior to aid in graft shuttling (Fig 6). Next, the most inferior glenoid anchor is placed using a single loaded Q-FIX anchor (Smith & Nephew) (Fig 7). Due to the posterior positioning of the humeral head, the inferior anchor is placed from the anterior cannula and the suture limbs are left anteriorly.

Next, the graft is introduced into the joint by placing tension on the humeral sutures using a double-pulley technique and pulling on the leading suture while pushing the graft in with a suture grasper (Fig 8). Once the graft is intra-articular and in proper orientation, the humeral side is reduced using a double-pulley technique and tied down using a REVO knot (Fig 9). The remaining sutures from the humeral anchors are then



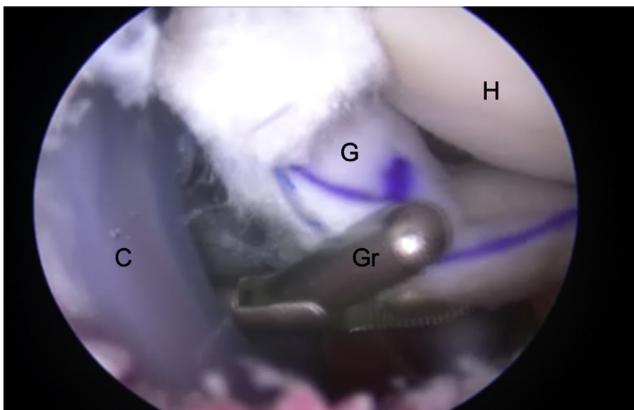
**Fig 6.** Passing of the shuttling suture from the posterior cannula (left) to the anterior cannula (right) in the left shoulder, patient in lateral decubitus position, viewing from the anterosuperior portal. Arrow indicates the direction of suture shuttling. (G, glenoid; Gr, grasper; H, humerus; SM, suture manipulator.)



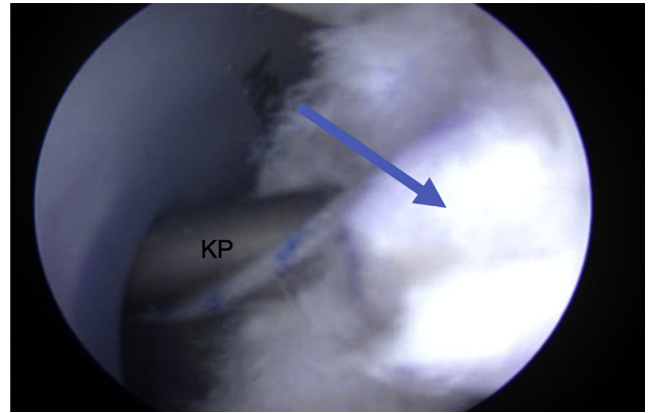
**Fig 7.** Placement of the suture anchor (A) into the inferior glenoid (IG) from the anterior cannula while viewing from the anterosuperior portal.

tied down to secure the inferior aspect of the graft on the humerus.

The graft is then fixed onto the glenoid. From the posterior cannula, a SPECTRUM suture passer medium crescent (CONMED) is used to penetrate the graft through the most inferior glenoid marking (Fig 10). This suture shuttle is used to retrieve the suture limb from the inferior glenoid Q-FIX anchor that was previously placed. A sliding SMC knot is then used to reduce and secure the graft to the anchor (Fig 11). Next, the middle and superior glenoid anchors are placed at the 9- and 11-o'clock positions from the posterior cannula. Suture limbs are passed through the graft using the SPECTRUM suture passer and sequentially tied as described previously. Once complete, the reconstruction is inspected for proper tension and efficacy as evidenced by proper balancing and concentric reduction of the humeral head on the glenoid (Fig 12).



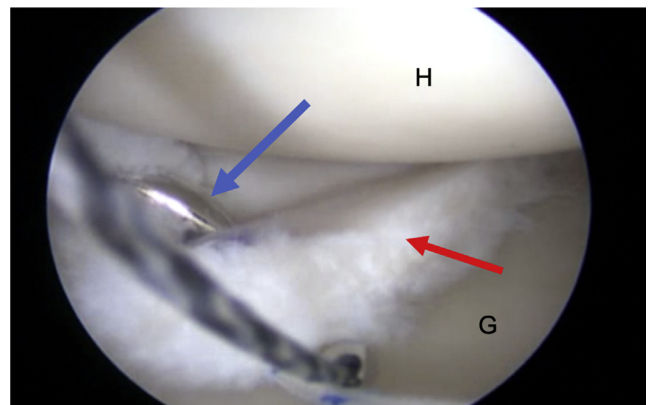
**Fig 8.** Introduction of the graft (G) into the glenohumeral joint by use of a grasper (Gr), and shuttling sutures, viewing from the anterosuperior portal, left shoulder, patient in lateral decubitus position. (C, posterior cannula; H, humerus.)



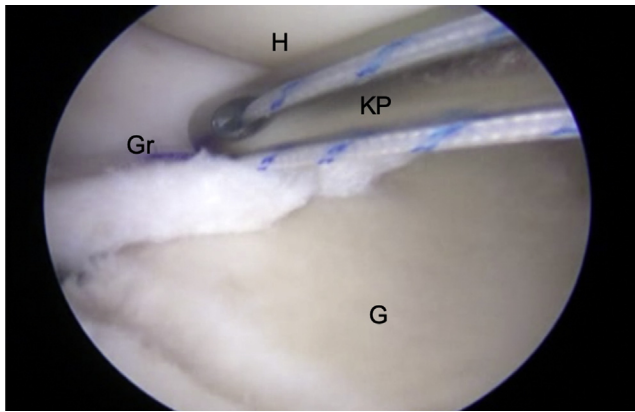
**Fig 9.** Tying of the superior humeral anchor knot (arrow), for initial fixation of the graft to the humerus once it has been brought intra-articularly, viewing from the anterosuperior portal, left shoulder, patient in lateral decubitus position. (KP, Knot Pusher.)

### McLaughlin Procedure

Next, attention is turned to the humeral-sided bone loss. Due to the posterior dislocation, a significant anterior humeral defect may be identified in this setting. From the anterior cannula, the defect should then be debrided of any soft tissue and roughened using a burr or shaver to stimulate a bleeding bone bed. A double-loaded Q-FIX anchor is then placed in the center of the defect (Fig 13). A BirdBeak suture grasper (Arthrex) is then used to penetrate the subscapularis inferiorly and superiorly and a single limb of one suture is brought through each of these sites (Fig 14). Next, a looped suture grasper is used to retrieve the other limb of the inferior anchor and brought superiorly around the subscapularis tendon and tied down using a sliding knot (Fig 15), followed by 3 half hitches, ensuring a reduction of the inferior aspect of the subscapularis into the humeral defect. The same is then performed with



**Fig 10.** SPECTRUM suture passer (blue arrow) penetrating the inferior glenoid anchor site on the allograft (red arrow). SPECTRUM is passed through the posterior cannula while viewing from the anterosuperior portal. (G, glenoid; H, humerus.)



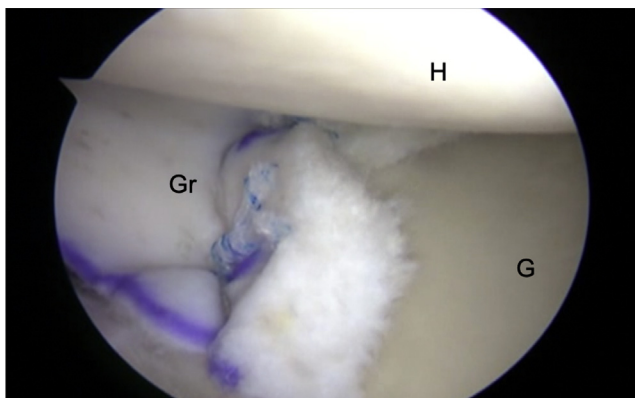
**Fig 11.** Reduction and fixation of the graft to the inferior glenoid (G) using a sliding knot (SMC knot). Tying from the anterior cannula while viewing from the anterosuperior portal, left shoulder, patient in the lateral decubitus position. (Gr, graft; H, humerus; KP, Knot Pusher.)

the superior suture, ensuring full coverage and stability of the humeral defect.

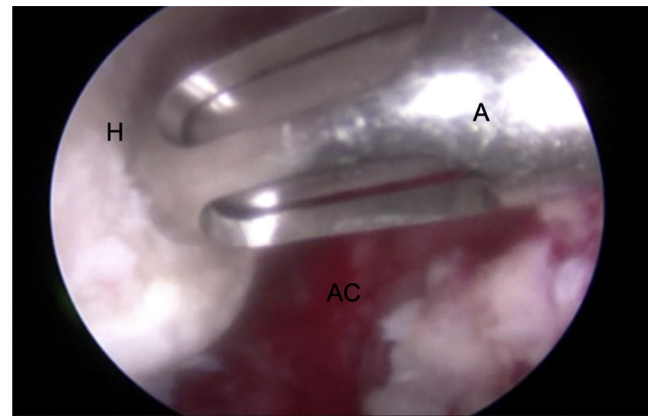
The final product is inspected to ensure concentric reduction of the humeral head on the glenoid with secure soft-tissue support anteriorly and posteriorly. Stability of the shoulder is then tested, particularly posterior translation in neutral, internal, and external rotation prior to arthroscope removal and closure.

### Rehabilitation

Following the procedure, the patient is placed into a sling with an abduction pillow to protect the posterior repair. In this setting, we would not initiate pendulum exercises until the 4-week mark, as patients with this condition tend to suffer issues with hyperlaxity rather than stiffness. At the 6-week mark, the patient may begin to wean themselves from the sling and initiate passive and active assisted ROM exercises. At the 12-week mark, the patient may move on to



**Fig 12.** Posterior capsular reconstruction completed with graft (Gr) anchored to the glenoid (G) and the humerus (H), viewing from the anterosuperior portal, left shoulder, patient in the lateral decubitus position.

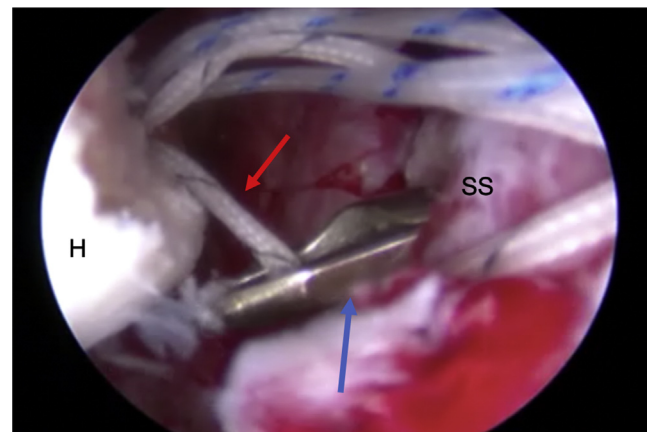


**Fig 13.** Humeral anchor (A) being inserted into the center of the reverse Hill–Sachs defect (H) while viewing from the anterosuperior portal, left shoulder, patient in the lateral decubitus position. (AC, anterior capsule.)

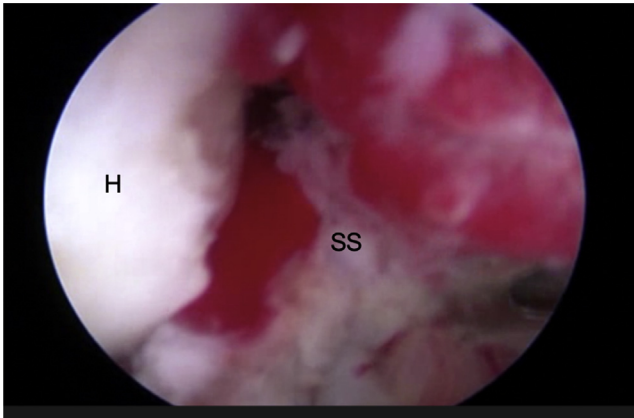
strengthening exercises with TheraBand (TheraBand, Akron, OH) and closed-chained exercises and may progress to more significant strengthening at the 16-week mark. At the 6-month mark, the patient may begin a return to play routine or may begin to wean themselves back into a labor type of job and activity as tolerated.

### Discussion

In this paper, we describe the surgical technique for addressing the chronic posteriorly dislocated shoulder with capsular insufficiency and a large reverse Hill–Sachs defect. Although the shoulder is the most commonly dislocated joint in the body, the majority of these are anterior dislocations, with only 2% to 4% occurring posteriorly.<sup>11</sup> In addition, it has been reported that in 40% to 90% of cases, these chronic dislocations also are accompanied by significant bone loss of the



**Fig 14.** BirdBeak suture passer (blue arrow) penetrating the subscapularis (SS) to retrieve suture limb of humeral anchor (red arrow), viewing from the anterosuperior portal, left shoulder, patient in the lateral decubitus position. (H, humerus.)



**Fig 15.** Subscapularis (SS) being reduced into the reverse Hill–Sachs defect (H) on the humerus, viewing from the anterosuperior portal, left shoulder, patient in the lateral decubitus position.

anteromedial humeral head (also known as a “reverse Hill–Sachs lesion”).<sup>12,15</sup> In a systematic review performed by Xu et al.,<sup>3</sup> they found that 150 of 205 patients (73.2%) had a missed diagnosis on initial presentation. This highlights the importance of obtaining an axillary lateral radiograph on initial imaging studies, as these images were not obtained in 147 of 150 patients. Once identified, prompt identification and reduction should be performed; however, in the setting of a locked posterior dislocation with a substantial humeral defect, this may not be possible by closed means.

The use of an acellular dermal allograft has been described previously for the reconstruction of the superior capsule in chronic massive rotator cuff tears, for the reconstruction of the anterior capsule for failed anterior shoulder instability,<sup>16–18</sup> and more recently for the reconstruction of the posterior capsule in a patient with Ehlers–Danlos syndrome.<sup>19</sup> This technique gives the surgeon another option before arthroplasty for capsulolabral repair in the setting of deficient or absent tissue. The use of these grafts spares the patient the morbidity of a donor-site harvest as well as can be used in conditions in which the native collagen is abnormal or deficient, such as in Ehlers–Danlos syndrome.<sup>19</sup> The reconstruction of the posterior capsule results in centering of the humeral head and a robust check rein for posterior translation.

In the setting of significant bone loss of the humeral head, even with the posterior capsule reconstructed, there is still some concern of the large humeral defect engaging with the dermal construct, leading to increased forces transmitted to the graft and failure of healing and eventual graft failure. Using a technique similar to Krackhardt et al.,<sup>20</sup> we recommend performing a modified McLaughlin procedure in which the subscapularis tendon is tenodesed to the center of the reverse Hill–Sachs lesion, essentially converting it to an extra-articular defect. Although this procedure may

result in decreased external rotation of the shoulder due to subscapularis tethering/shortening, this should not come as a functional deficit in this particular patient population, whose issue is generally too much rotation and should remain in a functional range.

The result of this technique is a well-centered shoulder with sufficient soft tissue preventing excess posterior translation and with a nonengaging, extra-articular humeral lesion. Performing this procedure in an arthroscopic fashion spares the patient from the morbidity of open dissection, disruption of the subscapularis tendon, and scar tissue formation and may be performed in a revision setting following failure of posterior capsular plication and labral repair. The goal of this treatment is to provide the patient with a reasonable level of function following a disabling condition, prevention of further dislocation as well as delaying the need for shoulder arthroplasty. Limitations of this technique include the learning curve associated with suture management and graft tangling, insertion of the graft, as well as increased operative time due to the technical demands of the procedure.

## Conclusions

Posterior capsular reconstruction with an acellular human allograft in addition to the modified McLaughlin technique is an acceptable procedure in the setting of a chronic posterior shoulder dislocation with significant soft tissue and bone loss. This procedure can be used as an alternative to fusion or arthroplasty in a young population in whom other soft-tissue procedures are limited.

## References

- Owens BD, Duffey ML, Nelson BJ, DeBerardino TM, Taylor DC, Mountcastle SB. The incidence and characteristics of shoulder instability at the United States Military Academy. *Am J Sports Med* 2007;35:1168–1173.
- Bottoni CR, Franks BR, Moore JH, DeBerardino TM, Taylor DC, Arciero RA. Operative stabilization of posterior shoulder instability. *Am J Sports Med* 2005;33:996–1002.
- Xu W, Huang L-X, Guo JJ, Jiang D-H, Zhang Y, Yang H-L. Neglected posterior dislocation of the shoulder: A systematic literature review. *J Orthop Transl* 2015;3:89–94.
- Antosh IJ, Tokish JM, Owens BD. Posterior shoulder instability. *Sports Health* 2016;8:520–526.
- Tannenbaum E, Sekiya JK. Evaluation and management of posterior shoulder instability. *Sports Health* 2011;3:253–263.
- Lanzi JT, Chandler PJ, Cameron KL, Bader JM, Owens BD. Epidemiology of posterior glenohumeral instability in a young athletic population. *Am J Sports Med* 2017;45:3315–3321.
- Millett PJ, Clavert P, Hatch GFR, Warner JJP. Recurrent posterior shoulder instability. *J Am Acad Orthop Surg* 2006;14:464–476.
- McLaughlin HL. Posterior dislocation of the shoulder. *J Bone Joint Surg Am* 1952;24A:584–590.

9. Kammel KR, Leber EH. Posterior shoulder dislocations. In: *StatPearls [Internet]. Treasure Island (FL). StatPearls Publishing, 2019 [cited 2019 May 8]. Available at: <http://www.ncbi.nlm.nih.gov/books/NBK441919/>. Accessed May 8, 2019.*
10. Guehring M, Lambert S, Stoeckle U, Ziegler P. Posterior shoulder dislocation with associated reverse Hill-Sachs lesion: Treatment options and functional outcome after a 5-year follow up. *BMC Musculoskelet Disord* 2017;18:442.
11. Jacobs RC, Meredyth NA, Michelson JD. Posterior shoulder dislocations. *BMJ* 2015;350:h75-h75.
12. Shams A, El-Sayed M, Gamal O, ElSawy M, Azzam W. Modified technique for reconstructing reverse Hill–Sachs lesion in locked chronic posterior shoulder dislocation. *Eur J Orthop Surg Traumatol* 2016;26:843-849.
13. Cooper A. On the dislocations of the os humeri upon the dorsum scapulae, and upon fractures near the shoulder joint. *Guy's Hosp Rep* 1839;4:265-284.
14. Beighton P, Solomon L, Soskolne CL. Articular mobility in an African population. *Ann Rheum Dis* 1973;32:413-418.
15. Altan E, Senaran H, Acar MA, Aydin K, Ozbaydar MU. Mozaicplasty technique for treatment of reverse Hill-Sachs lesion. *Tech Shoulder Elbow Surg* 2013;14:1.
16. Mihata T, Lee TQ, Watanabe C, et al. Clinical results of arthroscopic superior capsule reconstruction for irreparable rotator cuff tears. *Arthroscopy* 2013;29:459-470.
17. Petri M, Warth RJ, Horan MP, Greenspoon JA, Millett PJ. Outcomes after open revision repair of massive rotator cuff tears with biologic patch augmentation. *Arthroscopy* 2016;32:1752-1760.
18. Pogorzelski J, Hussain ZB, Lebus GF, Fritz EM, Millett PJ. Anterior capsular reconstruction for irreparable subscapularis tears. *Arthrosc Tech* 2017;6:e951-e958.
19. Karpshyn J, Gordey EE, Coady CM, Wong IH. Posterior glenohumeral capsular reconstruction using an acellular dermal allograft. *Arthrosc Tech* 2018;7:e739-e745.
20. Krackhardt T, Schewe B, Albrecht D, Weise K. Arthroscopic fixation of the subscapularis tendon in the reverse Hill-Sachs lesion for traumatic unidirectional posterior dislocation of the shoulder. *Arthroscopy* 2006;22:227.e1-227.e6.