

# Outcome of low level lasers versus ultrasonic therapy in de Quervain's tenosynovitis

Renu Sharma, Aditya N Aggarwal, Shuchi Bhatt<sup>1</sup>, Sudhir Kumar, SK Bhargava<sup>1</sup>

## ABSTRACT

**Background:** de Quervain's tenosynovitis is an inflammation of abductor pollicis longus (APL) and extensor pollicis brevis (EPB) muscle tendon sheaths at the level of radial styloid process. Its conservative management includes nonsteroidal anti-inflammatory drugs, wrist and thumb immobilization, ultrasonic therapy (US Th.) and low level laser therapy (LLLT). Literature is scanty on comparative efficacy of US Th. and LLLT for its management. This prospective study evaluates outcome of US Th. versus LLLT in de Quervain's disease.

**Materials and Methods:** Thirty patients clinically diagnosed de Quervains tenosynovitis were included in the study and randomly assigned to two groups. The average age was 36 years (range: 21-45 years). One group was given LLLT and the other US Th. for a total of 7 exposures on alternate days. The clinical criteria used were Finkelstein's test, tenderness over radial styloid (Ritchie's tenderness scale), grip strength, pain (visual analog scale [VAS]) and radiological criteria was ultrasonographic assessment of change in thickness of APL and EPB tendon sheath. They were measured before commencement and at the end of seven sessions of therapy, as per standard procedure.

**Results:** Significant improvement was seen within both groups in the following outcome measures assessed: Ritchie's tenderness scale, grip strength and VAS. Finkelstein's test was not significantly improved in either groups. Ultrasonographic measurement of tendon sheath diameters, the mediolateral (ML), and anteroposterior (AP) diameters was not found to be significantly different in the US Th. group and the laser therapy group after treatment. On comparing both the groups, no statistically significant difference was found. However, looking at the mean values, the grip strength and VAS showed better improvement in the US Th. group as compared to the laser therapy group.

**Key words:** de Quervains tenosynovitis, low level lasers, ultrasonic therapy

**MeSH terms:** Tenosynovitis, laser therapy, ultrasonic therapy

## INTRODUCTION

de Quervains' tenosynovitis (inflammation of abductor pollicis longus [APL] and extensor pollicis brevis [EPB] muscle tendon sheath) is a repetitive strain injury or a cumulative trauma disorder.<sup>1</sup> It is commonly managed nonoperatively by non-steroidal anti-inflammatory drugs, wrist and thumb immobilization, ultrasonic therapy (US Th.), and low level laser therapy (LLLT).<sup>2-4</sup> US Th. is a

therapeutic modality widely used for management of various soft tissue and musculoskeletal disorders although its mechanism of action is not clearly understood.<sup>5-8</sup> Its efficacy has been questioned in the past.<sup>9</sup> Most of the reviews and meta-analysis conducted on US Th. are lacking in specific information regarding the description of randomization methods, an ultrasound apparatus, sham ultrasound, mode of delivery, size of the ultrasound head, treatment time and dropouts.<sup>9-12</sup> Well-designed research studies are required to justify the use of ultrasound, especially *in vivo*.

Lasers have been used for photobiomodulation.<sup>13</sup> The available literature gives conflicting results regarding the efficacy of this modality in management of soft tissue disorders<sup>14-17</sup> and lack of descriptive information, further makes analysis difficult. LLLT is effective in the management of de Quervains tenosynovitis<sup>2</sup> as demonstrated ultrasonographically. However, studies on comparative efficacy of LLLT and US Th. in management of soft tissue disorders are not many.<sup>18</sup> This study assessed and compared the efficacy of US Th. and laser therapy in de Quervain's tenosynovitis.

Departments of Orthopaedics and <sup>1</sup>Radiology, University College of Medical Sciences and Guru Teg Bahadur Hospital, New Delhi, India

**Address for correspondence:** Mrs. Renu Sharma, 171, Gagan Vihar, New Delhi - 110 051, India. E-mail: shandilyarenusharma@rediffmail.com

Access this article online	
Quick Response Code:	Website: www.ijoonline.com
	DOI: 10.4103/0019-5413.164050

## MATERIALS AND METHODS

Thirty consecutive patients attending the Orthopaedics Out Patient Department, having clinically diagnosed de Quervain's tenosynovitis, on the basis of positive Finkelsteins test,<sup>19</sup> were included in this prospective study. There were 28 females and 2 male patients. The average age was 36.6 years (range 21-45 years). The dominant/non dominant extremity was recorded. The clinical diagnosis was further confirmed by ultrasonography. X-Rays of the wrist joint were done to exclude any underlying bony pathology. Patients with no prior history of any treatment for de Quervain's tenosynovitis (operative or nonoperative) for at least 3 months were included in the study. A written, informed consent for participation in the study was obtained from all patients. The study was approved by the Institutional Ethical Committee.

Patients who had a history of cervical spondylosis with or without radiating pain, hypertension, diabetes mellitus, fractures of upper extremity or any other chronic condition like rheumatoid arthritis were excluded from study.

The patients included in the study were randomly divided in two groups, one group ( $n = 15$ ) received US Th. and the other group ( $n = 15$ ) received LLLT.

A high resolution real time sonography of the wrist was performed using ultrasound machine (HDI 5000, SONO CT, Philips Electronics Hong Kong Limited, Wanchai, Hong Kong). A high frequency (5-12 MHz) linear phased array probe with a broadband facility was used for ultrasonographic assessment of the patients by a radiologist. The other outcome measures were done by a physiotherapist.

A standard mercury Sphygmomanometer was used for measuring grip strength<sup>20</sup> (Elite, India).

A class 3 B (IEC 825) solid state Ga - As-Al infrared laser (Endolaser 476, Enraf Nonius, Holland) with a pencil probe (wavelength 830 nm, power 30-40 mw, beam diameter 4 mm, 1 mm at 10 mm from the probe, angle of divergence 2.5°) was used for treatment. The laser probe and the part to be treated were cleaned with 70% alcohol to remove any oil and dirt from the skin surface for better penetration. Protective goggles were worn by patients and therapist.

A 3 MHz ultrasonic generator (Medilap, Delhi, India) was used for ultrasonic therapy. An aquasonic gel was used as a coupling medium.

The following outcome measures were used namely Finkelstein's test, tenderness over radial styloid (Ritchie's

tenderness scale), grip strength, pain as assessed by visual analog scale (VAS) and ultrasonographic assessment of change in thickness of APL and EPB tendon sheaths. All the outcome measures were done before commencement and after the end of seven sessions of therapy. The clinical diagnosis was done by the orthopedician, ultrasonographic assessment by the radiologist and the remaining outcome measures and application of therapy were done by the physiotherapist. Finkelstein's test which involves grasping the patient's thumb and quickly moving the hand ulnarward<sup>19</sup> was performed. Tenderness elicited over the tip of the radial styloid process was taken as a positive test.<sup>19</sup>

Tenderness on pressure over the radial styloid was graded by Ritchie's tenderness scale.<sup>21</sup> The grades were Grade I - Tolerable pain, Grade II - Patient winces on pressure and Grade III - Patient winces and withdraws hand.

Grip strength<sup>20</sup> was measured by a standard mercury sphygmomanometer with the arm cuff inflated to 30 mm Hg. The elbow and arm were supported on a table and the elbow flexed to 90°. The cuff was then pressed in the cylindrical grasp. The elevation of the mercury column was recorded 3 times. The average of three readings was taken. Clinically, the improvement was assessed subjectively by the patient, using a 11-point VAS<sup>22</sup> (0 = no pain, 10 = severe pain). The clinical tests were repeated before reducing the dosage of laser/ultrasound therapy if improvement was observed.

Ultrasonographic assessment was done to measure combined thickness of the APL and EPB sheaths. The patients were examined in sitting position with both forearms placed in mid-prone position in the patient's lap/thigh. The scans were optimized by selecting the superficial musculoskeletal settings for the system. Abundant jelly was placed over the radial side of the wrist and both transverse and longitudinal scanning was performed. The scanned area extended from few centimeters proximal to the radial styloid up to the insertion of the tendons of the first compartment (distal end of the proximal phalanx). The transverse scans were obtained for the measurement of the tendon sheath at the level of the radial styloid. The probe was placed perpendicular to the styloid process without applying any pressure. The scan was done, and findings/measurement recorded for both the sides (symptomatic and asymptomatic). The anteroposterior (AP) and mediolateral (ML) dimensions taken bilaterally, by placing the electronic calipers at the maximum AP and ML dimensions of the tendon sheath, before the commencement and after the treatment. The radiologist was blinded to the patient allocation, mode of intervention

and clinical evaluation of the patients. The physiotherapist was blinded to the ultrasonographic measurements taken before and after treatment. The patients were given US Th./ LLLT for a total of 7 exposures on alternate days by the standard exposure procedures.

The LLLT was applied twice per session. Once the probe was held stationary, in contact with skin (at radial styloid) and the second time in scanning mode (along tendon sheath approximately an inch long) (exposure time for 1 min 40 s, energy in joules: 3 J/cm<sup>2</sup>, continuous 100%, spot size on skin (with diameter): 2.5 cm (area = 4.910 cm<sup>2</sup>).<sup>23</sup> The area to be treated was divided into a grid of 1 cm squares, and optimum anti-inflammatory dosage of 3 J/cm<sup>2</sup> continuous output of 100% was used. The dose was reduced to 2 J/cm<sup>2</sup> when VAS reduced by 50% approximately. Testing of optical output was performed regularly before and after the end of treatment.

For ultrasonic therapy, the pulsed mode was used to expose the area over the radial styloid, (1:1 pulse ratio; 5 ms on and 5 ms off). A space averaged intensity of 0.8 W/cm<sup>2</sup> (depth of lesion 0.5 cm approximately) for a period of 3 min was delivered.

Neither oral or injectable steroids nor non-steroidal antiinflammatory drugs were administered to any of these patients. Precautions regarding avoidance of forceful movements of the thumb were explained to the patients.

### Statistical analysis

Due to small sample size and high variability, nonparametric tests have been applied to obtain the within group and between group comparisons. The McNemar–Bowker test was used for comparing the subjective variables between two groups, that is, tenderness (Ritchie's tenderness scale and Finkelsteins' test).

## RESULTS

The difference in the age ( $P = 0.539$ ), as well as the duration of symptoms ( $P = 0.174$ ) in LLLT and US Th. groups were not statistically significant implying that the groups were comparable as regards to age and duration of symptoms [Table 1]. Of the thirty patients taken up for the study, the left side was involved in 19 (59%), and the right side (dominant extremity) was involved only in 13 patients. Bilateral involvement was seen in two patients. However only the more affected extremity was included in the study.

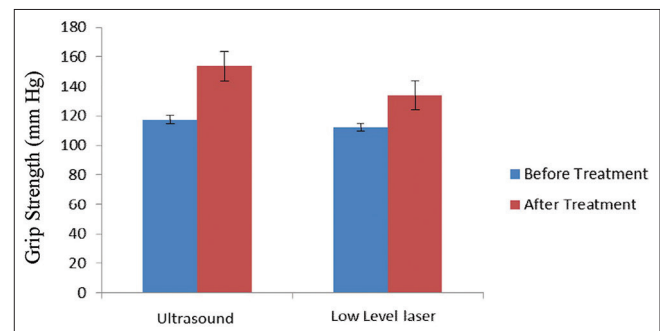
The tenderness (Ritchie's Tenderness Scale) was found significantly improved in the US Th. ( $P = 0.007$ ) and

LLLT group ( $P = 0.012$ ) (as per the Bonferroni criteria, the threshold critical  $P$  value is considered as  $<0.013$  since there are four comparisons in total). Finkelstein's test conducted before and after treatment was not statistically significant in both the groups, that is, LLLT and US Th. Grip strength for both the groups, before and after the treatment values were significantly different from each other within the groups [Figure 1], but not between the groups [Table 2]. Visual analog scale when compared between groups, the change was not found statistically significant though within groups it was found significant [Table 3].

In the study, one subject (case no. 18) gave a VAS and Ritchie's tenderness scale reading of zero after treatment. Finkelsteins Test was found to be negative. She was given US Th. The ultrasonographic measurement showed decrease of 0.07 cm in the AP and 0.04 cm in the ML diameter of the tendons. Six subjects had grade 1 (minimal pain) on VAS scale after treatment. Four of them belonged to LLLT group, and the remaining 2 were from the US Th. group. In the study, there were six subjects who had a post-treatment VAS of 10 or 9, indicating no improvement. Of these, 4 were from the US Th. group and 2 from LLLT group. The Ritchie's tenderness scale and VAS showed a statistically significant correlation ( $P < 0.001$ ) as assessed by Spearmans' nonparametric correlation test in all the patients.

On ultrasonographic measurements of tendon sheath diameters, the difference in AP and ML diameters before and after treatment was not found to be statistically significant within groups as well as on comparison between groups [Tables 4, 5 and Figure 2].

On comparison of the unaffected side ML and AP diameters with before and after treatment values, they were found to be statistically significant within groups except in US Th. group (unaffected side vs. posttreatment) [Tables 4 and 5]. However, looking at the mean values, the grip strength and



**Figure 1:** A bar diagram showing grip strength values before and after treatment in ultrasonic therapy and low level laser therapy group

**Table 1: Mean age and duration of symptoms, distribution of sex and extremity involved**

Demographic data	US Th. (n=15)				LLLT (n=15)				P (Mann-Whitney U-test)	Significance
	Mean	SD	Median	IQR	Mean	SD	Median	IQR		
Extremity Involved (right/left)	8/7				5/10					
Sex (female/male)	15/0				13/2					
Age (years)	35.80	6.805	32	30-43	37.40	7.557	38	30-45	0.539	Not significant
Duration of symptoms (months)	2.70	1.579	2.0	1.50-4.50	3.43	1.580	3.0	2.0-4.50	0.174	Not significant

US Th.=Ultrasonic therapy, LLLT=Low level laser therapy, n=Number of subjects, IQR=Interquartile range, SD=Standard deviation

**Table 2: Grip strength**

Grip strength	US Th. (n=15)				LLLT (n=15)				P (Mann-Whitney U-test)	Significance
	Mean	SD	Median	IQR	Mean	SD	Median	IQR		
Before treatment	117.59	60.591	115	80-161	112.07	42.749	106	84-140	0.838	Not significant
After treatment	153.63	70.835	150	90-207	133.93	49.750	130	100-170	0.567	Not significant
P (sign-test)	0.007				0.003					
Significance	Significant				Significant					

US Th.=Ultrasonic therapy, LLLT=Low level laser therapy, n=Number of subjects, IQR=Interquartile range, SD=Standard deviation

**Table 3: VAS for pain**

VAS	US Th. (n=15)				LLLT (n=15)				P (Mann-Whitney U-test)	Significance
	Mean	SD	Median	IQR	Mean	SD	Median	IQR		
Before treatment	9.12	1.495	10	9-10	8.80	1.656	10	7-10	0.567	Not significant
After treatment	4.18	3.005	4	2-7	4.27	3.535	3	1-7	0.713	Not significant
P (sign-test)	0.000				0.001					
Significance	Significant				Significant					

US Th.=Ultrasonic therapy, LLLT=Low level laser therapy, n=Number of subjects, IQR=Interquartile range, SD=Standard deviation, VAS=Visual analog scale

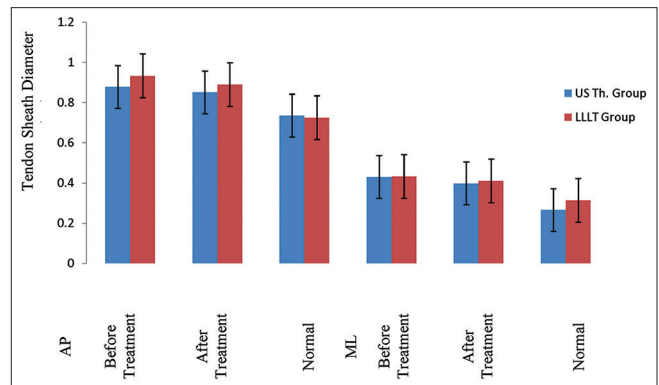
VAS showed better improvement in the US Th. group as compared to the LLLT group. The results imply that US Th. is slightly more effective than laser therapy [Figures 3-5].

## DISCUSSION

de Quervains tenosynovitis is more commonly seen in perimenopausal<sup>24</sup> and women of childbearing age<sup>25</sup> and hence the age range taken, that is, 20–45 years. Women are seen to have a significantly higher rate of occurrence of de Quervains tenosynovitis as compared to men.<sup>24</sup> There were only 2 male patients in this study.

Faithful and Lamb<sup>26</sup> observed that the nondominant hand is generally more affected. The greater involvement of the nondominant extremity in our patients, who do all kinds of manual work, associates well with the findings of Gousheh *et al.*<sup>27</sup> They found that occupation has no relationship to occurrence of de Quervains tenosynovitis on the dominant side.

It is a known fact that US Th. and LLLT cause a decrease in pain.<sup>28-30</sup> Ritchie's tenderness scale showed a decrease in 25 patients implying improvement. VAS too showed an improvement in 25 patients and the change was found to be statistically significant. The remaining 5 patients did not show any improvement from their pretherapy VAS. However there was no deterioration of VAS also in these patients



**Figure 2:** A bar diagram showing mean values of tendon sheath diameters in both the groups before and after treatment on the involved side and normal side

following the intervention. Ultrasonic therapy and LLLT both produce similar bio stimulatory effects,<sup>30</sup> suggesting that in theory, both modalities reduce inflammation and promote healing and should be useful in the management of tenosynovitis.

Sharma *et al.*<sup>2</sup> showed that LLLT was effective in reducing the tendon sheath diameters. However, the reduction in diameter was found to be statistically significant only in the ML dimension. Other parameters such as grip strength, tenderness (Ritchie's tenderness scale), and VAS also showed an improvement. The study used a dose of 3 J/cm<sup>2</sup> which was similar to our study.

**Table 4: AP tendon sheath diameters**

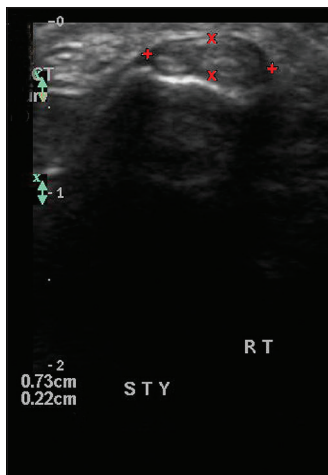AP diameter (cm)	US Th. (n=15)				LLLT (n=15)				P (Mann-Whitney U-test)	Significance
	Mean	SD	Median	IQR	Mean	SD	Median	IQR		
Unaffected side	0.7362	0.14021	0.6900	0.6350-0.8200	0.7260	0.12569	0.7000	0.6600-0.8400	0.786	Not significant
Before treatment	0.8788	0.13067	0.8700	0.7700-1.000	0.9340	0.13902	0.9000	0.8200-1.0000	0.367	Not significant
After treatment	0.8518	0.13626	0.8400	0.7800-0.8900	0.8900	0.09914	0.8900	0.8900-0.9800	0.250	Not significant
P (Friedmans test)	0.003				0.000					
Significance by sign test applying Bonferroni correction	Unaffected side versus before treatment (significant, P=0.003)				Unaffected side versus before treatment (significant, P<0.001)					
	Unaffected side versus after treatment (not significant, P=0.039)				Unaffected side versus after treatment (significant, P<0.001)					
	Before versus after treatment (not significant, P=0.424)				Before versus after treatment (not significant, P=0.180)					

US Th.=Ultrasonic therapy, LLLT=Low level laser therapy, n=Number of subjects, IQR=Interquartile range, SD=Standard deviation, AP=Antero posterior

**Table 5: ML tendon sheath diameters**

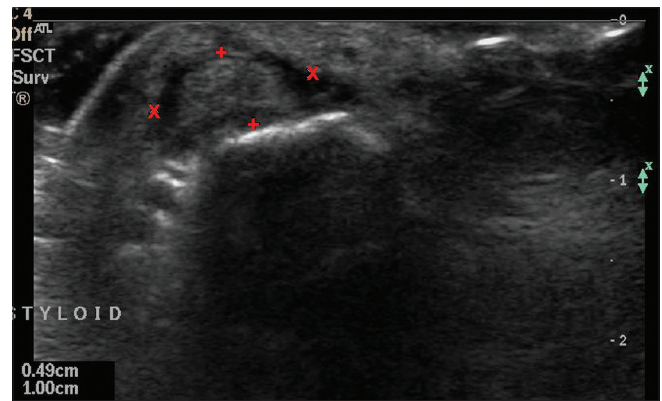
ML diameter (cm)	US Th. (n=15)				LLLT (n=15)				P (Mann-Whitney U-test)	Significance
	Mean	SD	Median	IQR	Mean	SD	Median	IQR		
Unaffected side	0.2662	0.04253	0.2500	0.2350-0.2900	0.3140	0.06080	0.3000	0.2600-0.3700	0.786	Not significant
Before treatment	0.4306	0.12577	0.4400	0.3200-0.4900	0.4333	0.06366	0.4300	0.3800-0.4900	0.367	Not significant
After treatment	0.3990	0.1413	0.3500	0.2700-0.5000	0.4110	0.0758	0.4100	0.3600-0.4600	0.250	Not significant
P (Friedmans test)	0.0000				0.0000					
Significance by sign test applying Bonferroni correction	Unaffected side versus before treatment (significant, P<0.001)				Unaffected side versus before treatment (significant, P<0.001)					
	Unaffected side versus after treatment (significant, P<0.001)				Unaffected side versus after treatment (significant, P<0.001)					
	Before versus after treatment (not significant, P=0.424)				Before versus after treatment (not significant, P=0.180)					

US Th.=Ultrasonic therapy, LLLT=Low level laser therapy, n=Number of subjects, IQR=Interquartile range, SD=Standard deviation, ML=Medio-lateral



**Figure 3:** Ultrasonographic scan showing tendon sheath diameter (abductor pollicis longus and extensor pollicis brevis) on normal side (right)

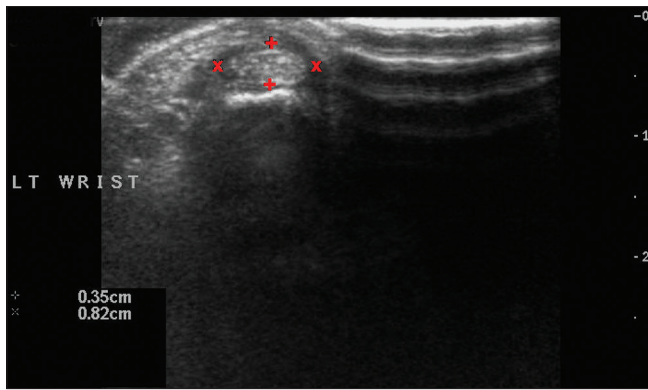
A pilot study on the effect of LLLT and eccentric exercise in Achilles tendinopathy was conducted by Tumilty *et al.*<sup>31</sup> Twenty patients were randomized into a laser or placebo group. All patients, therapists, and investigators were blinded to the allocation. The patients given eccentric exercise were irradiated 3 times/week for 4 weeks with either active or placebo laser at standardized points over the affected tendons. An 810 nm LLLT was used. They used a dose of 3 J per point, lased at 6 points, that is, 18 J per session. The outcome measures used were Victorian Institute of Sport



**Figure 4:** Ultrasonographic scan showing tendon sheath diameter (abductor pollicis longus and extensor pollicis brevis) on the involved side (left) before treatment

Assessment – A questionnaire, pain and isokinetic strength. Patients were measured before treatment and at 4 and 12 weeks. Significant improvements at 4 and 12 weeks were found within groups in all outcome measures except isokinetic strength in the placebo group at 4 weeks.

Stergioulas<sup>32</sup> studied the effect of LLLT and plyometric exercises in the treatment of tennis elbow. The laser used was a 904 nm GaAs laser, The dose used was 2–4 J/cm<sup>2</sup> (two sessions per week). Outcome measures used were grip strength, VAS and weight test. All the parameters



**Figure 5:** Ultrasonographic scan showing tendon sheath diameter (abductor pollicis longus and extensor pollicis brevis) on the involved side (left) after treatment

showed improvement at the end of 8 weeks in the laser with plyometric exercise group as compared to the placebo group. In our study, we have used a dose of 3 J/cm<sup>2</sup> (continuous) and similar improvements in all the parameters were seen in the LLLT group too.

An experimental study by Correa *et al.*<sup>33</sup> also showed that LLLT (GaAs 904 nm) reduces inflammatory cell migration in mice with lipopolysaccharide-induced peritonitis. The doses used were 3 J/cm<sup>2</sup>, 7.5 J/cm<sup>2</sup> and 15 J/cm<sup>2</sup> respectively. The 3 J/cm<sup>2</sup>, exposure group showed best results at 24 h.

Various reviews (Cochrane databases, Medline and EMBASE) conducted to study the efficacy of US Th. in musculoskeletal and soft tissue disorders, found little evidence to support its use in these disorders.<sup>10,11</sup> An RCT conducted by Kurtais Gürsel *et al.*<sup>8</sup> also suggested that US Th. gives no additional benefit when applied in addition to other physiotherapeutic interventions in the management of soft tissue disorders of the shoulder. Absence of sufficient evidence of biophysical effects of US Th. further fails to provide a scientific foundation for its clinical use.

To the best of our knowledge, no study in indexed English literature has addressed the use of US Th. in de Quervains tenosynovitis. The *in vitro* evidence for the efficacy of US Th. is known.<sup>34</sup> Further research is indicated to achieve the results *in vivo* too.

Pulsed US Th. was used in the present study as it is preferred for soft tissue repair. The frequency of 3 MHz was used as the target tissue was superficial. A low intensity of 0.8 W/cm<sup>2</sup> with pulse ratio of 1:1 was used as the area exposed was bony. The area treated was very small 2 cm approximately in diameter and treated for 3 min. A study conducted by Saunders<sup>18</sup> compares US Th. versus LLLT in the treatment of supraspinatus tendinosis.

Measurements were taken before and after treatment for muscle weakness secondary to pain (Pain analog scale), disability, and tenderness. The treatments were given for 3 weeks. They found that LLLT is the treatment of choice in supraspinatus tendinosis. Ultrasound also improved symptoms but was not significantly different from the controls who received advice only. In our study, both LLLT and US Th. showed an improvement in de Quervains tenosynovitis. The US Th. group showed marginally better improvement as compared to LLLT with the respective dosages used.

The various parameters showing improvement are probably due to a reduction in the diameter of the tendon sheaths resulting in greater ease of motion and hence decrease in pain. US Th. and laser both have resulted in improvement in tendon sheath diameters and tenderness (Ritchie's tenderness scale) causing improvements in grip strength and VAS. This implies a reduction in inflammation and promotion of healing. The subjects who do not show any improvement may have had a thickened retinaculum. During the ultrasonographic evaluation, the thickening in the extensor retinaculum was observed in seventeen patients. This fact has not been commented on in any of the earlier ultrasonographic studies<sup>35</sup> on de Quervains tenosynovitis though surgically it has been observed. This finding may have clinical implications as regards choice of treatment and prognosis. It also implies that the retinaculum thickness should also be measured. Further studies with more patients and long term followup would be desirable. The response to treatment and its relationship to a thickened retinaculum need further study.

The medial part of the tendon is the deepest, and the laser effects may have been diminished due to attenuation in the tissue, which may be the probable explanation for the lesser response seen in the case of LLLT. Furthermore, the mode of delivery, that is, scanning rather than skin contact was used for the second application. This may have reduced the actual dosage received at the target tissue. The better results in US Th. may be because of major areas of the tendon receiving therapy being exposed for maximum period of the treatment time, thus receiving optimum dosage required. No other studies have used this dosage to the best of our knowledge.

### Limitations of the study

One of the limitations of the current study was that sample size is small. Further study with differential ultrasonographic measurements of the extensor retinaculum and tendon sheath thickness in de Quervains tenosynovitis and its relation to the response to treatment should be conducted. Another limitation of the current study is that the followup

is small (14 days). Hence larger randomized control trials with a longer followup is required.

## REFERENCES

- Ahuja NK, Chung KC. Fritz de Quervain, MD (1868-1940): Stenosing tendovaginitis at the radial styloid process. *J Hand Surg Am* 2004;29:1164-70.
- Sharma R, Thukral A, Kumar S, Bhargava SK. Effect of low level lasers in de Quervain's tenosynovitis. Prospective study with ultrasonographic assessment. *Physiotherapy* 2002;88:730-4.
- Bjordal JM, Couppé C, Chow RT, Tunér J, Ljunggren EA. A systematic review of low level laser therapy with location-specific doses for pain from chronic joint disorders. *Aust J Physiother* 2003;49:107-16.
- Byl NN, McKenzie A, Wong T, West J, Hunt TK. Incisional wound healing: A controlled study of low and high dose ultrasound. *J Orthop Sports Phys Ther* 1993;18:619-28.
- Haker E, Lundeberg T. Pulsed ultrasound treatment in lateral epicondylalgia. *Scand J Rehabil Med* 1991;23:115-8.
- Gan BS, Huys S, Sherebrin MH, Scilley CG. The effects of ultrasound treatment on flexor tendon healing in the chicken limb. *J Hand Surg Br* 1995;20:809-14.
- Pienimäki TT, Tarvainen TK, Siira PT, Vanharanta H. Progressive strengthening and stretching exercises and ultrasound for chronic lateral epicondylitis. *Physiotherapy* 1996;82:522-30.
- Kurtais Gürsel Y, Ulus Y, Bilgiç A, Dinçer G, van der Heijden GJ. Adding ultrasound in the management of soft tissue disorders of the shoulder: A randomized placebo-controlled trial. *Phys Ther* 2004;84:336-43.
- Gam AN, Johannsen F. Ultrasound therapy in musculoskeletal disorders: A meta-analysis. *Pain* 1995;63:85-91.
- van der Windt DA, van der Heijden GJ, van den Berg SG, ter Riet G, de Winter AF, Bouter LM. Ultrasound therapy for musculoskeletal disorders: A systematic review. *Pain* 1999;81:257-71.
- Robertson VJ, Baker KG. A review of therapeutic ultrasound: Effectiveness studies. *Phys Ther* 2001;81:1339-50.
- Baker KG, Robertson VJ, Duck FA. A review of therapeutic ultrasound: Biophysical effects. *Phys Ther* 2001;81:1351-8.
- Baxter GD. Low intensity laser therapy. In: Kitchen S, Bazin S, editors. *Electrotherapy: Evidence Based Practice*. 11<sup>th</sup> ed. London: Churchill Livingstone; 2002. p. 171-90.
- Basford JR. Low intensity laser therapy: Still not an established clinical tool. *Lasers Surg Med* 1995;16:331-42.
- Beckerman H, de Bie RA, Bouter LM, De Cuyper HJ, Oostendorp RA. The efficacy of laser therapy for musculoskeletal and skin disorders: A criteria-based meta-analysis of randomized clinical trials. *Phys Ther* 1992;72:483-91.
- De Bie R, Verhagen A, Lenssen T, de Vet R, Van den Wildenberg F. Oral presentation: Efficacy of 904 nm laser therapy in musculoskeletal disorder: A systematic review. In: *The Cochrane Library*. Chichester: John Wiley and sons; 1996.
- Tunér J, Hode L. It's all in the parameters: A critical analysis of some well-known negative studies on low-level laser therapy. *J Clin Laser Med Surg* 1998;16:245-8.
- Saunders L. Laser versus ultrasound in the treatment of supraspinatus tendinosis. *Physiotherapy* 2003;89:365-73.
- Kutsumi K, Amadio PC, Zhao C, Zobitz ME, Tanaka T, An KN. Finkelstein's test: A biomechanical analysis. *J Hand Surg Am* 2005;30:130-5.
- Quin CE, Mason RM, Knowelden J. Clinical assessment of rapidly acting agents in rheumatoid arthritis. *Br Med J* 1950;2:810-3.
- Ritchie DM, Boyle JA, McInnes JM, Jasani MK, Dalakas TG, Grieveson P, *et al.* Clinical studies with an articular index for the assessment of joint tenderness in patients with rheumatoid arthritis. *Q J Med* 1968;37:393-406.
- Price DD, Bush FM, Long S, Harkins SW. A comparison of pain measurement characteristics of mechanical visual analogue and simple numerical rating scales. *Pain* 1994;56:217-26.
- World Association of Laser Therapy website. Recommended dosage. Available from: <http://www.walt.nu/dose/index.html>. [Last revised on 2005 Aug].
- Wolf JM, Sturdivant RX, Owens BD. Incidence of de Quervain's tenosynovitis in a young, active population. *J Hand Surg Am* 2009;34:112-5.
- Johnson CA. Occurrence of de Quervain's disease in postpartum woman. *J Fam Pract* 1991;32:324-7.
- Faithfull DK, Lamb DW. De Quervain's disease – A clinical review. *Hand* 1971;3:23-30.
- Gousheh J, Yavari M, Arasteh E. Division of the first dorsal compartment of the hand into two separated canals: Rule or exception? *Arch Iran Med* 2009;12:52-4.
- de Quervain F. On the nature and treatment of stenosing tendovaginitis on the styloid process of the radius. (Translated article: Muenchener Medizinische Wochenschrift 1912, 59, 5-6). *J Hand Surg Br* 2005;30:392-4.
- Mardiman S, Wessel J, Fisher B. The effect of the ultrasound on the mechanical pain threshold of healthy subjects. *Physiotherapy* 1995;81:718-23.
- Low J, Read A. Therapeutic ultrasound. In: Low J, Read A, editors. *Electrotherapy Explained. Principles Practice*. 3<sup>rd</sup> ed. Linacre House, Jordan Hill, Oxford: Butterworth Heinemann; 2003. p. 133.
- Tumilty S, Munn J, Abbott JH, McDonough S, Hurley DA, Baxter GD. Laser therapy in the treatment of achilles tendinopathy: A pilot study. *Photomed Laser Surg* 2008;26:25-30.
- Stergioulas A. Effects of low-level laser and plyometric exercises in the treatment of lateral epicondylitis. *Photomed Laser Surg* 2007;25:205-13.
- Correa F, Lopes Martins RA, Correa JC, Iversen VV, Joenson J, Bjordal JM. Low-level laser therapy (GaAs lambda=904 nm) reduces inflammatory cell migration in mice with lipopolysaccharide-induced peritonitis. *Photomed Laser Surg* 2007;25:245-9.
- Young S, Bolton P, Dyson M, Harvey W, Diamantopoulos C. Macrophage responsiveness to light therapy. *Lasers Surg Med* 1989;9:497-505.
- Diop AN, Ba-Diop S, Sane JC, Tomolet Alfidja A, Sy MH, Boyer L, *et al.* Role of US in the management of de Quervain's tenosynovitis: Review of 22 cases. *J Radiol* 2008;89:1081-4.

**How to cite this article:** Sharma R, Aggarwal AN, Bhatt S, Kumar S, Bhargava S. Outcome of low level lasers versus ultrasonic therapy in de Quervain's tenosynovitis. *Indian J Orthop* 2015;49:542-8.

**Source of Support:** Nil, **Conflict of Interest:** None.