

Return to Sport and Athletic Function in an Active Population After Primary Arthroscopic Labral Reconstruction of the Hip

David R. Maldonado,* MD, Sarah L. Chen,[†] BA, Mitchell J. Yelton,* BS, Philip J. Rosinsky,* MD, Rafael Walker-Santiago,[‡] MD, Jacob Shapira,* MD, Ajay C. Lall,*[§] MD, MS, and Benjamin G. Domb,*^{||} MD

Investigation performed at the American Hip Research Foundation, Des Plaines, Illinois, USA

Background: Labral reconstruction has been advocated as an alternative to debridement for the treatment of irreparable labral tears, showing favorable short-term results. However, literature is scarce regarding outcomes and return to sport in the nonelite athletic population.

Purpose: To report minimum 1-year clinical outcomes and the rate of return to sport in athletic patients who underwent primary hip arthroscopy with labral reconstruction in the setting of femoroacetabular impingement syndrome and irreparable labral tears.

Study Design: Case series; Level of evidence, 4.

Methods: Data were prospectively collected and retrospectively analyzed for patients who underwent an arthroscopic labral reconstruction between August 2012 and December 2017. Patients were included if they identified as an athlete (high school, college, recreational, or amateur); had follow-up on the following patient-reported outcomes (PROs): modified Harris Hip Score (mHHS), Nonarthritic Hip Score (NAHS), Hip Outcome Score–Sport Specific Subscale (HOS-SSS), and visual analog scale (VAS); and completed a return-to-sport survey at 1 year postoperatively. Patients were excluded if they underwent any previous ipsilateral hip surgery, had dysplasia, or had prior hip conditions. The proportions of patients who achieved the minimal clinically important difference (MCID) and patient acceptable symptomatic state (PASS) for mHHS and HOS-SSS were calculated. Statistical significance was set at $P = .05$.

Results: There were 32 (14 females) athletes who underwent primary arthroscopic labral reconstruction during the study period. The mean age and body mass index of the group were 40.3 years (range, 15.5–58.7 years) and 27.9 kg/m² (range, 19.6–40.1 kg/m²), respectively. The mean follow-up was 26.4 months (range, 12–64.2 months). All patients demonstrated significant improvement in mHHS, NAHS, HOS-SSS, and VAS ($P < .001$) at latest follow-up. Additionally, 84.4% achieved MCID and 81.3% achieved PASS for mHHS, and 87.5% achieved MCID and 75% achieved PASS for HOS-SSS. VAS pain scores decreased from 4.4 to 1.8, and the satisfaction with surgery was 7.9 out of 10. The rate of return to sport was 78%.

Conclusion: At minimum 1-year follow-up, primary arthroscopic labral reconstruction, in the setting of femoroacetabular impingement syndrome and irreparable labral tears, was associated with significant improvement in PROs in athletic populations. Return to sport within 1 year of surgery was 78%.

Keywords: labral tear; labral reconstruction; femoroacetabular impingement; return to sport

Labral restoration has become the gold standard treatment for labral tears and femoroacetabular impingement (FAI) syndrome in hip arthroscopy.²⁸ Compared with debridement, labral refixation leads to superior short-term, midterm, and long-term outcomes.^{7,15–17,28} However, labral refixation or “repair” requires good tissue quality to restore

the “suction-seal” effect.^{15,16} Historically, labral debridement has been the alternative treatment of choice when the condition of the labrum is not amenable to refixation.^{5,11} Recently, restoring the labral seal mechanism via labral reconstruction has emerged as a viable option as a result of new technology and innovative surgical techniques.^{8,35,38}

Arthroscopic labral reconstruction is not only complex but also a relatively new procedure.^{15,16,29,37,41,44} Limited literature is available on short- and midterm outcomes after hip labral reconstruction.^{3,25,43} Particularly, outcomes and rates

The Orthopaedic Journal of Sports Medicine, 8(2), 2325967119900767
DOI: 10.1177/2325967119900767
© The Author(s) 2020

This open-access article is published and distributed under the Creative Commons Attribution - NonCommercial - No Derivatives License (<https://creativecommons.org/licenses/by-nc-nd/4.0/>), which permits the noncommercial use, distribution, and reproduction of the article in any medium, provided the original author and source are credited. You may not alter, transform, or build upon this article without the permission of the Author(s). For article reuse guidelines, please visit SAGE’s website at <http://www.sagepub.com/journals-permissions>.

of return to sport in athletic patients who undergo labral reconstruction warrant further investigation. In their cohort of 21 male patients, Boykin et al³ reported an 81% rate of return to sport after arthroscopic labral reconstruction with iliotibial band autograft. However, their cohort comprised only male elite athletes; thus, their results may not be generalizable to all athletes who undergo labral reconstruction.

The purpose of this study was to report minimum 1-year clinical outcomes and the return-to-sport rate in athletic patients who underwent primary hip arthroscopy with labral reconstruction in the setting of FAI and irreparable labral tears. The authors hypothesized that athletes who underwent primary hip arthroscopy with labral reconstruction would demonstrate favorable patient-reported outcomes (PROs) at minimum 1-year follow-up and exhibit a favorable rate of return to sport within 1 year of surgery.

METHODS

Patient Selection Criteria

Data were prospectively collected and retrospectively analyzed for patients who underwent hip arthroscopy by the senior surgeon (B.G.D.) between August 2012 and December 2017. Patients were deemed eligible if they had undergone primary labral reconstruction during their arthroscopy and if they indicated participation in sports at a nonelite level (high school, college, recreational, or amateur) within the year before surgery. To isolate the effect of labral reconstruction on ability to return to sport, patients were excluded if, in the sports survey, they reported not attempting to return to sport after surgery due to loss of interest, lifestyle changes, or other reasons unrelated to the hip. Additionally, patients were excluded if they had undergone any previous surgery on the ipsilateral hip; had a prior hip condition including Legg-Calve-Perthes disease; had any inflammatory, connective tissue (Ehler-Danlos syndrome), or neoplastic (pigmented villonodular synovitis) condition; or had dysplasia (lateral center-edge angle $\leq 18^\circ$).²⁶ Patients were included if they had minimum 1-year follow-up on the following PROs—modified Harris Hip Score (mHHS),¹ Nonarthritic Hip Score (NAHS),¹² and Hip Outcome Score—Sport Specific Subscale (HOS-SSS)²⁷—

and completed a return-to-sport survey at a minimum 1 year postoperatively. Additionally, for further analysis, the study cohort was split into 2 groups: those who returned to sport and those who did not return to sport after surgery. The patient selection process is depicted in Figure 1.

The return-to-sport survey identified an athlete's sport, highest level of participation within 1 year before surgery, and current level of participation in the respective sport. Pain was measured on a visual analog scale (VAS) from 0 to 10, with 10 being the most pain⁹; patient satisfaction with the surgery results was measured on a 0- to 10-point scale, with 10 indicating the most satisfaction with the surgical results. In addition, the proportions of patients who surpassed the literature values for the minimal clinically important difference (MCID) and patient acceptable symptomatic state (PASS) for mHHS and HOS-SSS were recorded.²³

All patients participated in the American Hip Institute Hip Preservation Registry. Although the present study represents a unique analysis, data on some patients in this study have been reported in other studies. All data collection received institutional review board approval.

Imaging Protocol

The patient population underwent a preoperative and postoperative radiographic evaluation that included upright and supine anteroposterior pelvic, modified Dunn, and false-profile views. Measurements were made using GE Healthcare's Picture Archiving and Communication System, and the Tönnis grade for osteoarthritis was assessed via the method described by Domb et al.¹⁴ Using the supine anteroposterior pelvic view, evaluators measured the lateral center-edge angle per the method described by Wiberg⁴⁵ and measured the Tönnis angle (acetabular inclination) using the method described by Jessel et al.²¹ Alpha angle was measured on the modified Dunn view according to the method described by Nötzli et al,³⁰ and the anterior center-edge angle was measured on the false profile view as described by Lequesne and de Seze.²² Preoperatively, magnetic resonance imaging or magnetic resonance arthrogram was performed on all patients.

||Address correspondence to Benjamin G. Domb, MD, 999 E Touhy Ave, Suite 450, Des Plaines, IL 60018, USA (email: DrDomb@americanhipinstitute.org).

*American Hip Institute Research Foundation, Des Plaines, Illinois, USA.

†Sidney Kimmel Medical College, Philadelphia, Pennsylvania, USA.

‡Missouri Orthopedic Institute, Columbia, Missouri, USA.

§American Hip Institute, Des Plaines, Illinois, USA.

Final revision submitted October 8, 2019; accepted October 18, 2019.

One or more of the authors has declared the following potential conflict of interest or source of funding: D.R.M. has received hospitality payments from Arthrex, Stryker, and Smith & Nephew. P.J.R. has received hospitality payments from Arthrex, Stryker, and Smith & Nephew. R.W.-S. has received educational support from DePuy and Encore Medical and hospitality payments from Acumed, Arthrex, Globus Medical, Stryker, and Smith & Nephew. J.S. has received hospitality payments from Arthrex, Stryker, and Smith & Nephew. A.C.L. has received research support from Arthrex and Stryker, educational support from Midwest and Smith & Nephew, consulting fees from Arthrex and Graymont Medical, and hospitality payments from Smith & Nephew, Stryker, and Zimmer Biomet. B.G.D. has ownership interests in Hinsdale Orthopaedics, the American Hip Institute, SCD#3, North Shore Surgical Suites, and Munster Specialty Surgery Center; has received research support from Arthrex, ATI, the Kauffman Foundation, and Pacira Pharmaceuticals; has received consulting fees from Adventist Hinsdale Hospital, Arthrex, MAKO Surgical, Medacta, Pacira Pharmaceuticals, and Stryker; has received educational support from Arthrex, Breg, and Midwest; has received speaking fees from Arthrex and Pacira Pharmaceuticals; and receives royalties from Arthrex, DJO Global, MAKO Surgical, Stryker, and Orthomerica. AOSSM checks author disclosures against the Open Payments Database (OPD). AOSSM has not conducted an independent investigation on the OPD and disclaims any liability or responsibility relating thereto.

Ethical approval for this study was obtained from Advocate Health Care Institutional Review Board (ID: 5276).

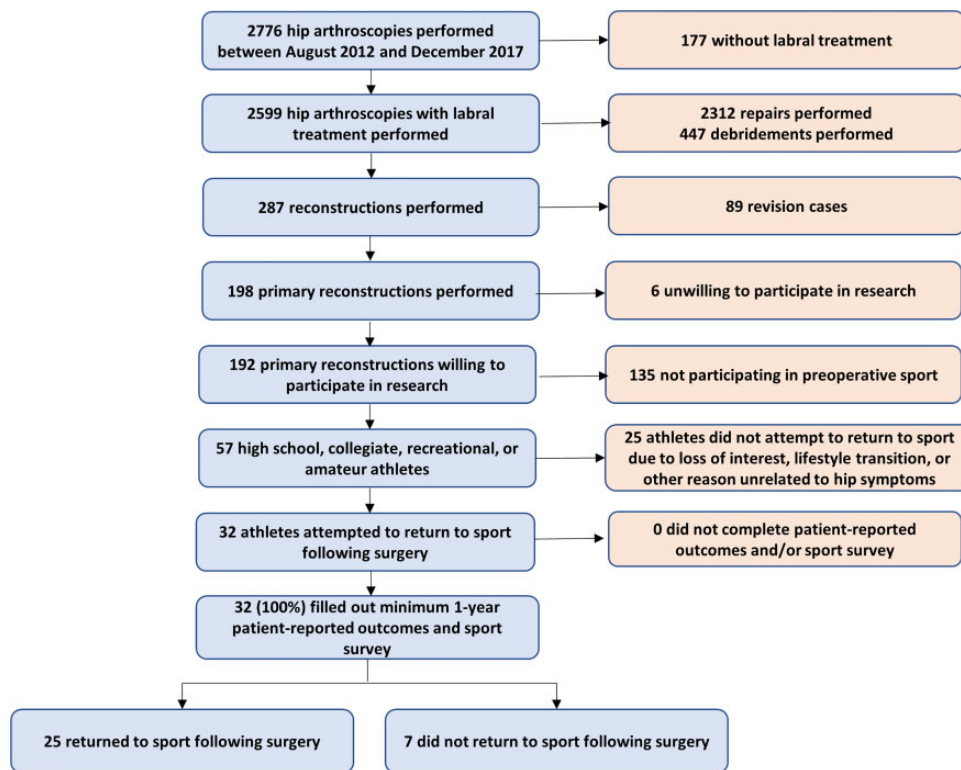


Figure 1. Flowchart illustrating the patient selection process.

Surgical Indications for Hip Arthroscopy

All patients in this study attempted nonoperative treatment including physical therapy, activity modification, and anti-inflammatory medications for at least 3 months before undergoing surgical management of their symptoms.

Surgical Technique

During the study period, all surgical procedures were performed by the senior surgeon. As preparation for the procedure, patients were placed in the modified supine position and were prepared and draped in a sterile fashion. The senior surgeon established 3 portals—midanterior, anterolateral, and distal lateral—and performed a capsulotomy to access the hip joint. Diagnostic arthroscopy was performed in all cases. Articular cartilage damage was assessed using the Outerbridge,³² Seldes,³⁹ and acetabular labrum articular disruption (ALAD)⁶ classification systems. Ligamentum teres tears and other intra-articular abnormalities were evaluated and treated.

The decision of whether to repair or reconstruct the labrum was made intraoperatively by the senior surgeon. Patients were considered for labral reconstruction if segmental labral defects and/or nonviable labral tissues were found during diagnostic arthroscopy.^{16,41} Labral reconstructions were performed with an autograft from the ipsilateral hamstring tendon from the knee or a hamstring allograft as described by Redmond et al.³⁷ At the beginning of the study period, the senior surgeon used hamstring

autografts; however, to decrease the risk of donor site morbidity, the protocol changed to hamstring allografts. The diseased part of the labrum was debrided with a 5-mm shaver, and acetabular rim trimming was then performed until the surface of the bone was revealed. The graft was prepared with FiberLoop stitches (Arthrex), which were passed 3 or 4 times at each end before being cut at approximately 2 mm past the defect on each side. The anterior end of the graft was secured by a 2.9-mm PushLock anchor (Arthrex), and the posterior end of the graft was secured with a SutureTak anchor (Arthrex). The middle graft section was anchored anteriorly to posterolaterally with Knotless SutureTak anchors (Arthrex).

Rehabilitation

All patients used crutches, were placed in a DonJoy hip brace (DJO Global), and were restricted to 20 lb (9 kg) weightbearing and 0° to 90° of motion for 6 weeks postoperatively. Patients also used a continuous passive motion machine and began a physical therapy regimen at 6 weeks postoperatively. Patients were prescribed 4 weeks of 32 mg naproxen twice daily.

Statistical Analysis

Statistical analysis was performed with Microsoft Excel and the Real Statistics Resource Pack add-in. Pre- and postoperative outcomes were compared by use of a paired *t* test, and the threshold of statistical significance was set at

TABLE 1
Patient Demographics^a

	Results
No. of patients	32
Age at surgery, y	40.3 (15.5-58.7)
Male sex, n (%)	18 (56)
Body mass index, kg/m ²	27.9 (19.6-40.1)
Duration of symptoms, mo	29.0 (2.8-107.8)
Follow-up time, mo	26.4 (12.0-64.2)
Lateral center-edge angle, deg	32.4 ± 6.6
Anterior center-edge angle, deg	32.0 ± 7.4
Alpha angle, deg	64.6 ± 15.5
Tönnis angle, deg	2.7 ± 3.3

^aValues are expressed as mean (range) or mean ± SD, unless otherwise noted.

P = .05. Normality was assessed via the Shapiro-Wilk test, and variance was assessed with the *F* test. Demographic differences between the groups who did and did not return to sport were assessed with the Mann-Whitney *U* test.

RESULTS

Patient Demographics

Our patient population included 32 high school, college, recreational, and amateur athletes who underwent primary labral reconstruction. There were 2 baseball players, 4 cyclists, 3 dancers, 1 hockey player, 2 martial artists, 11 runners, 3 golfers, 1 soccer player, 1 swimmer, 1 tennis player, 1 equestrian, 1 skier, and 1 weightlifter. The group consisted of 18 males and 14 females, and the mean age and body mass index of the group were 40.3 years (range, 15.5-58.7 years) and 27.9 kg/m² (range, 19.6-40.1 kg/m²), respectively. The mean follow-up time was 26.4 months (range, 12-64.2 months). Additional patient demographics are shown in Table 1.

Intraoperative Findings and Surgical Procedures

Intraoperative findings and surgical procedures are delineated in Tables 2 and 3, respectively. No significant difference was noted in intraoperative findings or procedures performed in the patients who did and those who did not return to sport after surgery. In both groups, the most common intraoperative findings were Seldes tear types 1 and 2, ALAD grade 3, and femoral head Outerbridge grade 0. All patients in both groups underwent an acetabuloplasty and femoroplasty, with approximately 50% of both groups undergoing a capsular repair.

Patient-Reported Outcomes

On average, patients demonstrated statistically significant improvements in mHHS, NAHS, HOS-SSS, and VAS scores (*P* < .001) at latest follow-up (Table 4). No significant differences were found in preoperative and postoperative mHHS, NAHS, and HOS-SSS scores between the patients who did and those who did not return to sport after surgery

TABLE 2
Intraoperative Findings^a

	Returned to Sport	Did Not Return	<i>P</i>
Seldes			>.999
1	—	0	
2	9 (36)	2 (29)	
1 and 2	16 (64)	5 (71)	
Acetabular labrum articular disruption			.402
0	—	—	
1	5 (20)	2 (29)	
2	6 (24)	1 (14)	
3	14 (56)	3 (43)	
4	—	1 (14)	
Outerbridge (acetabulum)			.785
0	1 (4)	—	
1	5 (20)	2 (29)	
2	5 (20)	1 (14)	
3	11 (44)	2 (29)	
4	3 (12)	2 (29)	
Outerbridge (femoral head)			.536
0	23 (92)	6 (86)	
1	—	—	
2	—	—	
3	1 (4)	1 (14)	
4	1 (4)	—	
Ligamentum teres percentile class (Domb)			.185
0: 0%	16 (64)	3 (43)	
1: 0% to <50%	4 (16)	—	
2: 50% to <100%	4 (16)	4 (57)	
3: 100%	1 (4)	—	
Ligamentum teres Villar class			.599
0: No tear	16 (64)	3 (43)	
1: Complete tear	1 (4)	—	
2: Partial tear	3 (12)	1 (14)	
3: Degenerative tear	5 (20)	3 (43)	

^aValues are expressed as n (%) of patients. Dashes indicate not applicable.

TABLE 3
Surgical Procedures^a

	Returned to Sport	Did Not Return	<i>P</i> Value
Labral treatment			
Reconstruction	25 (100)	7 (100)	
Capsular treatment			.810
Repair	13 (52)	4 (57)	
Release	12 (48)	3 (43)	
Acetabuloplasty	25 (100)	7 (100)	>.999
Femoroplasty	25 (100)	7 (100)	>.999
Acetabular microfracture	2 (8)	1 (14)	.614
Femoral head microfracture	—	—	>.999
Ligamentum teres debridement	4 (16)	3 (43)	.316
Iliopsoas fractional lengthening	4 (16)	4 (57)	.084
Trochanteric bursectomy	6 (24)	—	.296
Gluteus medius repair	4 (16)	—	.552

^aValues are expressed as n (%) of patients. Dashes indicate not applicable.

TABLE 4
Pre- and Postoperative Outcomes^a

Outcome	Preoperative	Postoperative	Delta	P Value
mHHS	64.3 (58.9 to 69.8)	86.2 (80.0 to 92.4)	21.9 (-14 to 50)	<.001
NAHS	66.6 (60.5 to 72.7)	87.7 (81.2 to 94.2)	21.1 (-11.3 to 52.5)	<.001
HOS-SSS	47.6 (38.6 to 56.7)	78.9 (67.4 to 90.4)	28.3 (-30.6 to 77.8)	<.001
VAS	4.4 (3.7 to 5.1)	1.8 (1.1 to 2.5)	-2.6 (-8 to 2.6)	<.001
Satisfaction	—	7.9 (7.0 to 8.8)	—	—

^aOutcome scores are expressed as mean (95% CI). HOS-SSS, Hip Outcome Score–Sport Specific Subscale; mHHS, modified Harris Hip Score; NAHS, Nonarthritic Hip Score; satisfaction, satisfaction with surgery results (0-10); VAS, visual analog pain scale (0-10).

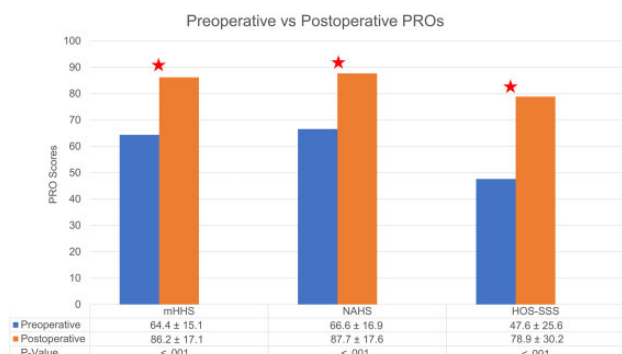


Figure 2. Preoperative outcome scores (expressed as mean ± SD). Stars indicate statistical significance ($P < .05$). HOS-SSS, Hip Outcome Score–Sport Specific Subscale; mHHS, modified Harris Hip Score; NAHS, Nonarthritic Hip Score; PROs, patient-reported outcomes.

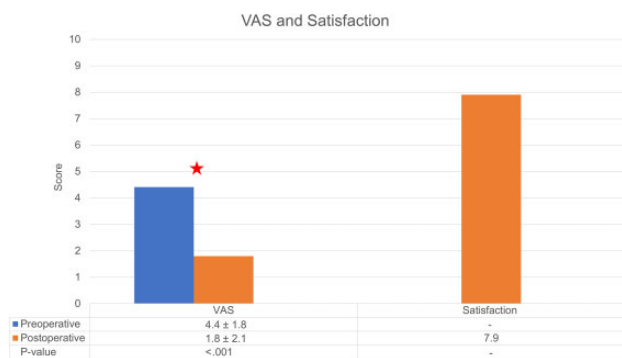


Figure 3. Postoperative outcome scores (expressed as mean ± SD). Star indicates statistical significance ($P < .05$). VAS, visual analog scale.

(Figures 2 and 3). For mHHS, 27 of 32 (84.4%) patients achieved MCID and 26 of 32 (81.3%) patients achieved PASS. For HOS-SSS, 28 of 32 (87.5%) patients achieved MCID and 24 of 32 (75%) patients achieved PASS. For the entire cohort, VAS pain scores decreased from 4.4 to 1.8, and the satisfaction with surgery was 7.9 out of 10.

Return to Sport

Of the 32 athletes who were analyzed, 25 (78%) returned to sport and 13 (40.6%) successfully returned to sport at the

TABLE 5
1-Year Postoperative Level Compared With Preoperative Performance Level^a

Postoperative Level	Results
Lower	12 (37.5)
Same	8 (25.0)
Higher	5 (15.6)
Not participating at all	7 (21.9)

^aValues are expressed as n (%) of patients.

same or higher level within 1 year of their labral reconstruction (Table 5). We noted that 5 (15.6%) athletes were performing at a higher level at 1 year postoperatively compared with their respective preoperative level. We found that 7 (21.9%) athletes were not participating at all in their preoperative sport at 1 year postoperatively. All 7 patients who did not return to sport postoperatively cited hip symptoms as their primary reason for not returning to sport. The patients who did not return to sport still demonstrated significant improvement in all PROs ($P < .05$).

DISCUSSION

The present study demonstrated that primary arthroscopic labral reconstruction in the context of irreparable tears or nonviable labral tissue and FAI led to significant improvement in multiple PROs at a minimum 1-year follow-up (mHHS, NAHS, HOS-SSS, and VAS). To provide clinical context, 84% and 81% of patients achieved MCID and PASS, respectively, for mHHS, and 88% and 75% achieved MCID and PASS, respectively, for HOS-SSS. In addition, the rate of return to sport was 78%, with 40.6% of patients returning to the same or higher level within 1 year of surgery.

Boykin et al³ published favorable outcomes and a satisfactory rate of return to sport after arthroscopic labral reconstruction. In a cohort of 21 athletes, the authors found a significant improvement in HHS (from 67 to 84; $P = .026$) and HOS-SSS (from 56 to 77; $P = .009$). However, their cohort was entirely composed of male “elite” athletes, which makes their results difficult to generalize to all athletic patients. The current study included both female and male patients with varying athletic levels; thus, our results can

be extended to a broad athletic population that may undergo labral reconstruction.

In addition, Boykin et al³ reported a significant, high rate of return to sport (85.7%), with 81% (17/21) of their patients returning to a similar postoperative level at short-term follow-up. The definitions of successful return to sport and postoperative level of performance were not entirely delineated for their patient population, and current literature advocates a strict definition of return to prevent overestimating return to sport.²⁰ The rate of return to sport in the present study (78%) was lower, yet still favorable. An athlete's decision-making process for returning to sport after surgery is often multifaceted. In addition to hip symptoms, dedication to sport and economic factors can influence return to sport in elite athletes.¹³

We believe that labral repair is the gold standard for labral tear treatment, as studies have shown excellent outcomes and high rates of return to sport after labral repair.^{19,24,31,33,34,40} However, in cases of irreparable, nonviable, or calcified labra, labral reconstruction has recently emerged as a viable procedure. Literature shows that in these cases, labral reconstruction can restore labral function and is preferred over debridement or excision.^{2,8,15,25} We believe that favorable results after labral reconstruction can be extended to athletic patients.

Systematic labral reconstruction in the primary setting has been advocated; however, this has been cautiously implemented, particularly in the athletic population.^{42,47} Although both labral repair and labral reconstruction lead to favorable PROs, long-term data on outcomes and return to sport are overwhelmingly more available for patients who undergo labral repair. Literature shows favorable VAS, patient satisfaction, and return to sport after labral repair.^{4,19,31,33} Furthermore, labral reconstruction is among the most challenging procedures in hip arthroscopy, as evidenced by the handful of surgeons currently performing labral reconstructions.^{18,35,36,44,46}

This study has several strengths. Currently, literature is lacking on clinical outcomes and rate of return to sports after primary hip arthroscopy with labral reconstruction in the setting of FAI and irreparable labra. To our knowledge, this study is one of the first to report athletic function and return to sport after arthroscopic primary labral reconstruction. The use of multiple validated functional hip outcome scores specific to nonarthritic hips increases the validity and generalizability of our results. Additionally, the return-to-sport analysis in the current study is very detailed, as we reported postoperative athletic level compared with preoperative athletic level and the reasons patients engaged in a lower athletic level postoperatively. Moreover, we addressed the understanding that statistical significance does not necessarily equal clinical significance by analyzing the proportion of patients who achieved PASS and MCID for mHHS and HOS-SSS.

Limitations

The findings of the current study highlight some limitations that must be acknowledged. First, this was a nonrandomized study with no control group. As such, confounding

variables may have influenced our results. Second, the retrospective nature introduces some bias. Third, this study included a single high-volume hip preservation surgeon, which may limit the generalizability of the results, especially since hip arthroscopy and particularly labral reconstruction have been recognized as procedures with steep learning curves.¹⁰ Fourth, the labral treatment decision algorithm is based on the senior author's expertise, which may introduce bias. Fifth, some patients who had surgery during this study period did not allow their surgical data to be used in research and statistical analysis, and this omission could have influenced the results. Sixth, our analysis included only patients who indicated participation in sports 1 year prior to surgery. Some athletes who were unable to participate in sports before surgery due to hip pain may have been excluded from analysis, which could have influenced our results and conclusion. Seventh, as this study analyzes short-term follow-up, long-term studies are needed to assess the durability of the results.

CONCLUSION

At minimum 1-year follow-up, primary arthroscopic labral reconstruction, in the setting of FAI and irreparable labral tears, was associated with significant improvement in PROs in an athletic population. The rate of return to sport within 1 year of surgery was 78%.

REFERENCES

- Aprato A, Jayasekera N, Villar RN. Does the modified Harris Hip Score reflect patient satisfaction after hip arthroscopy? *Am J Sports Med.* 2012;40(11):2557-2560.
- Ayeni OR, Alradwan H, de Sa D, Philippon MJ. The hip labrum reconstruction: indications and outcomes—a systematic review. *Knee Surg Sports Traumatol Arthrosc.* 2014;22(4):737-743.
- Boykin RE, Patterson D, Briggs KK, Dee A, Philippon MJ. Results of arthroscopic labral reconstruction of the hip in elite athletes. *Am J Sports Med.* 2013;41(10):2296-2301.
- Byrd JWT, Jones KS. Hip arthroscopy in athletes: 10-year follow-up. *Am J Sports Med.* 2009;37(11):2140-2143.
- Byrd JWT, Jones KS. Prospective analysis of hip arthroscopy with 10-year followup. *Clin Orthop Relat Res.* 2010;468(3):741-746.
- Callaghan JJ, Rosenberg AG, Rubash HE. *The Adult Hip.* Baltimore, MD: Lippincott Williams & Wilkins; 1998.
- Cetinkaya S, Toker B, Ozden VE, Dikmen G, Taser O. Arthroscopic labral repair versus labral debridement in patients with femoroacetabular impingement: a minimum 2.5 year follow-up study. *Hip Int.* 2016; 26(1):20-24.
- Chandrasekaran S, Darwish N, Mu BH, et al. Arthroscopic reconstruction of the irreparable acetabular labrum: a match-controlled study. *Arthroscopy.* 2019;35(2):480-488.
- Chandrasekaran S, Gui C, Walsh JP, Lodhia P, Suarez-Ahedo C, Domb BG. Correlation between changes in visual analog scale and patient-reported outcome scores and patient satisfaction after hip arthroscopic surgery. *Orthop J Sports Med.* 2017;5(9): 2325967117724772.
- Chen AW, Steffes MJ, Laseter JR, et al. The education and training of future hip preservation surgeons: aggregate recommendations of high-volume surgeons. *J Hip Preserv Surg.* 2018;5(3):307-311.
- Chen AW, Yuen LC, Ortiz-Declet V, Litrenta J, Maldonado DR, Domb BG. Selective debridement with labral preservation using narrow

- indications in the hip: minimum 5-year outcomes with a matched-pair labral repair control group. *Am J Sports Med.* 2018;46(2):297-304.
12. Christensen CP, Althausen PL, Mittleman MA, Lee J, McCarthy JC. The nonarthritic hip score: reliable and validated. *Clin Orthop Relat Res.* 2003;406:75-83.
 13. Christian RA, Lubbe RJ, Chun DS, Selley RS, Terry MA, Hsu WK. Prognosis following hip arthroscopy varies in professional athletes based on sport. *Arthroscopy.* 2019;35(3):837-842.e1.
 14. Domb BG, Chaharbakshi EO, Rybalko D, Close MR, Litrenta J, Perets I. Outcomes of hip arthroscopic surgery in patients with Tönnis grade 1 osteoarthritis at a minimum 5-year follow-up: a matched-pair comparison with a Tönnis grade 0 control group. *Am J Sports Med.* 2017;45(10):2294-2302.
 15. Domb BG, El Bitar YF, Stake CE, Trenga AP, Jackson TJ, Lindner D. Arthroscopic labral reconstruction is superior to segmental resection for irreparable labral tears in the hip: a matched-pair controlled study with minimum 2-year follow-up. *Am J Sports Med.* 2014;42(1):122-130.
 16. Domb BG, Hartigan DE, Perets I. Decision making for labral treatment in the hip: repair versus débridement versus reconstruction. *J Am Acad Orthop Surg.* 2017;25(3):e53-e62.
 17. Domb BG, Yuen LC, Ortiz-Declet V, Litrenta J, Perets I, Chen AW. Arthroscopic labral base repair in the hip: 5-year minimum clinical outcomes. *Am J Sports Med.* 2017;45(12):2882-2890.
 18. Eijnsman L, Philippon MJ. Arthroscopic labral reconstruction in the hip using iliotibial band autograft. *Oper Tech Sports Med.* 2011;19(2):134-139.
 19. Frank RM, Ukwuani G, Clapp I, Chahla J, Nho SJ. High rate of return to cycling after hip arthroscopy for femoroacetabular impingement syndrome. *Sports Health.* 2018;10(3):259-265.
 20. Ishøi L, Thorborg K, Kraemer O, Hölmich P. Return to sport and performance after hip arthroscopy for femoroacetabular impingement in 18- to 30-year-old athletes: a cross-sectional cohort study of 189 athletes. *Am J Sports Med.* 2018;46(11):2578-2587.
 21. Jessel RH, Zurakowski D, Zilkens C, Burstein D, Gray ML, Kim Y-J. Radiographic and patient factors associated with pre-radiographic osteoarthritis in hip dysplasia. *J Bone Joint Surg Am.* 2009;91(5):1120-1129.
 22. Lequesne M, de Seze. False profile of the pelvis: a new radiographic incidence for the study of the hip: its use in dysplasias and different coxopathies [in French]. *Rev Rhum Mal Osteoartic.* 1961;28:643-652.
 23. Levy DM, Kuhns BD, Chahal J, Philippon MJ, Kelly BT, Nho SJ. Hip arthroscopy outcomes with respect to patient acceptable symptomatic state and minimal clinically important difference. *Arthroscopy.* 2016;32(9):1877-1886.
 24. Levy DM, Kuhns BD, Frank RM, et al. High rate of return to running for athletes after hip arthroscopy for the treatment of femoroacetabular impingement and capsular plication. *Am J Sports Med.* 2017;45(1):127-134.
 25. Locks R, Bolia IK, Utsunomiya H, Briggs KK, Philippon MJ. Revision hip arthroscopy after labral reconstruction using iliotibial band autograft: surgical findings and comparison of outcomes with labral reconstructions not requiring revision. *Arthroscopy.* 2018;34(4):1244-1250.
 26. Maldonado DR, LaReau JM, Perets I, et al. Outcomes of hip arthroscopy with concomitant periacetabular osteotomy, minimum 5-year follow-up. *Arthroscopy.* 2019;35(3):826-834.
 27. Martin RL, Philippon MJ. Evidence of validity for the hip outcome score in hip arthroscopy. *Arthroscopy.* 2007;23(8):822-826.
 28. Menge TJ, Briggs KK, Dornan GJ, McNamara SC, Philippon MJ. Survivorship and outcomes 10 years following hip arthroscopy for femoroacetabular impingement: labral debridement compared with labral repair. *J Bone Joint Surg Am.* 2017;99(12):997-1004.
 29. Mook WR, Briggs KK, Philippon MJ. Evidence and approach for management of labral deficiency: the role for labral reconstruction. *Sports Med Arthrosc Rev.* 2015;23(4):205-212.
 30. Nötzli HP, Wyss TF, Stoecklin CH, Schmid MR, Treiber K, Hodler J. The contour of the femoral head-neck junction as a predictor for the risk of anterior impingement. *J Bone Joint Surg Br.* 2002;84(4):556-560.
 31. Ortiz-Declet V, Yuen LC, Maldonado DR, Schwarzman G, Laseter JR, Domb BG. Return to play among golfers undergoing hip arthroscopy: short- to mid-term follow-up. *Orthopedics.* 2018;41(4):e545-e549.
 32. Outerbridge RE. The etiology of chondromalacia patellae. *J Bone Joint Surg Br.* 1961;43-B:752-757.
 33. Perets I, Craig MJ, Mu BH, Maldonado DR, Litrenta JM, Domb BG. Midterm outcomes and return to sports among athletes undergoing hip arthroscopy. *Am J Sports Med.* 2018;46(7):1661-1667.
 34. Perets I, Hartigan DE, Chaharbakshi EO, Ashberg L, Mu B, Domb BG. Clinical outcomes and return to sport in competitive athletes undergoing arthroscopic iliopsoas fractional lengthening compared with a matched control group without iliopsoas fractional lengthening. *Arthroscopy.* 2018;34(2):456-463.
 35. Perets I, Hartigan DE, Chaharbakshi EO, Walsh JP, Close MR, Domb BG. Circumferential labral reconstruction using the knotless pull-through technique-surgical technique. *Arthrosc Tech.* 2017;6(3):e695-e698.
 36. Philippon MJ, Briggs KK, Hay CJ, Kuppersmith DA, Dewing CB, Huang MJ. Arthroscopic labral reconstruction in the hip using iliotibial band autograft: technique and early outcomes. *Arthroscopy.* 2010;26(6):750-756.
 37. Redmond JM, Cregar WM, Martin TJ, Vemula SP, Gupta A, Domb BG. Arthroscopic labral reconstruction of the hip using semitendinosus allograft. *Arthrosc Tech.* 2015;4(4):e323-e329.
 38. Scanaliato JP, Christensen DL, Salfitti C, Herzog MM, Wolff AB. Primary circumferential acetabular labral reconstruction: achieving outcomes similar to primary labral repair despite more challenging patient characteristics. *Am J Sports Med.* 2018;46(9):2079-2088.
 39. Seldes RM, Tan V, Hunt J, Katz M, Winiarsky R, Fitzgerald RH. Anatomy, histologic features, and vascularity of the adult acetabular labrum. *Clin Orthop Relat Res.* 2001;382:232-240.
 40. Weber AE, Kuhns BD, Cvetanovich GL, Grzybowski JS, Salata MJ, Nho SJ. Amateur and recreational athletes return to sport at a high rate following hip arthroscopy for femoroacetabular impingement. *Arthroscopy.* 2017;33(4):748-755.
 41. White BJ, Herzog MM. Labral reconstruction: when to perform and how. *Front Surg.* 2015;2:27.
 42. White BJ, Patterson J, Herzog MM. Bilateral hip arthroscopy: direct comparison of primary acetabular labral repair and primary acetabular labral reconstruction. *Arthroscopy.* 2018;34(2):433-440.
 43. White BJ, Patterson J, Herzog MM. Revision arthroscopic acetabular labral treatment: repair or reconstruct? *Arthroscopy.* 2016;32(12):2513-2520.
 44. White BJ, Stapleford AB, Hawkes TK, Finger MJ, Herzog MM. Allograft use in arthroscopic labral reconstruction of the hip with front-to-back fixation technique: minimum 2-year follow-up. *Arthroscopy.* 2016;32(1):26-32.
 45. Wiberg G. Shelf operation in congenital dysplasia of the acetabulum and in subluxation and dislocation of the hip. *J Bone Joint Surg Am.* 1953;35-A(1):65-80.
 46. Wolff AB, Grossman J. Management of the acetabular labrum. *Clin Sports Med.* 2016;35(3):345-360.
 47. Youm T. Editorial commentary: Wanted dead or alive: primary allograft labral reconstruction of the hip is as successful, if not more successful, than primary labral repair. *Arthroscopy.* 2018;34(2):441-443.