

Utility of Immunohistochemistry and Western Blot in Profiling Clinically Suspected Cases of Congenital Muscular Dystrophy

Radhika Mhatre, Deepha Sekar, Jessiena Ponmalar, Madhu Nagappa¹, Preethish-Kumar Veeramani¹, Kiran Polavarapu¹, Seena Vengalil¹, Nalini Atchayaram¹, Gayathri Narayanappa

Departments of Neuropathology and ¹Neurology, National Institute of Mental Health and Neurosciences, Bengaluru, India

Abstract

Objective: Immunocharacterization of congenital muscular dystrophy (CMD) to determine the frequency of various subtypes in a large Indian Cohort. **Materials and Methods:** This retrospective (2014-2017) study was carried on muscle biopsies of clinically suspected cases of CMD with histological evidence of dystrophy/myopathic features. Immunohistochemistry (IHC) to antibodies against laminin ($\alpha 2$, $\alpha 5$, $\beta 1$, $\gamma 1$), Collagen-VI (A1,2,3), and Western blot (WB) for α -dystroglycan and POMT1 was performed. **Results:** The study included 57 cases, of which 15 cases (26.3%) had mean age at presentation of 3.5 years, M: F = 1.5:1, elevated creatinine kinase (CK) (mean 1657 U/L), global developmental delay, multiple contractures, abnormal facies, white matter hyperintensities and showed laminin- $\alpha 2$ deficiency (Merosin deficient CMD). In addition, secondary reduction in laminin- $\beta 1$, over-expression of laminin- $\alpha 5$, and preserved laminin- $\gamma 1$ was noted. Ullrich CMD constituted 11/57 cases (19.2%) with mean age at presentation of 5.3 years, M: F = 1.2:1 and normal CK. They presented with proximal muscle weakness, soft velvety palms and soles, contractures, and joint hyperextensibility. Collagen-VI (A1,2,3) showed either complete ($n = 3$) or sarcolemmal specific ($n = 8$) loss of staining. Out of the remaining 31 cases, WB for α -dystroglycan was performed in 17 cases which showed deficiency in seven (12.3%). Three of these in addition revealed secondary partial loss of laminin- $\alpha 2$. WB for POMT1 showed deficiency in a single case clinically diagnosed Walker-Warburg syndrome, who presented with seizures and classical features of pachygyria, lissencephaly, and cerebellar cyst on MRI. Twenty-four cases (42.2%) remained uncharacterized and need genetic evaluation. **Conclusion:** The study helped in characterizing 57.8% of the proband. Immunotyping helps to direct mutational analysis for targeted genes and offers a potential route for prenatal diagnosis.

Keywords: α -dystroglycan, CMD, collagen VI, IHC, laminin, POMT1, WB

INTRODUCTION

Congenital muscular dystrophy (CMD) is a group of heterogenous inherited disorders presenting with weakness and hypotonia since birth or early infancy, due to defects in varied proteins of the sarcolemma, extracellular matrix, proteins involved in glycosylation, or those located within endoplasmic reticulum and nuclear envelope. Most have autosomal recessive inheritance with the exception of some de novo dominant collagen VI CMD and de novo lamin A/C mutations.^[1] Data on incidence and prevalence of CMD is sparse due to limited availability of molecular testing and the use of varied classification systems in the past. Study from north-east Italy found an incidence of 4.6×10^{-5} and point prevalence of 0.7×10^{-5} ,^[2] whereas another study from western Sweden found an incidence of 2.6×10^{-5} and point prevalence of 2.5×10^{-5} .^[3] Distinct subtypes of CMD have been identified based on molecular testing with geographic variation between different subtypes.^[4-6] Although histopathology shows features of muscular dystrophy, final subclassification requires genetic confirmation. Immunohistochemistry and Western blot analysis are helpful in resource limited set-up and helps to guide appropriate targeted genetic testing. Precise genetic diagnosis of CMD is important for phenotype-genotype correlation, genetic counseling, prenatal diagnosis, prognosis and management, clinical trials, and possible future treatments.^[6,7]

MATERIALS AND METHODS

This retrospective study (2014-2017) was carried in clinically suspected cases of CMD, which on histology showed features compatible with muscular dystrophy or myopathic features. Demographic details (age, gender, onset-age), clinical features, family history, serum creatinine kinase (CK), and brain MRI findings were obtained from case records.

Histology and enzyme histochemistry

Fresh frozen muscle biopsy sections (6 μ m) were subjected to a battery of stains [Hematoxylin and eosin (HE), modified Gomori trichrome (MGT), nicotinamide adenine

Address for correspondence: Dr. Gayathri Narayanappa,
Department of Neuropathology, NIMHANS, Hosur Road,
Bengaluru - 560 029, Karnataka, India.
E-mail: gayathri.narayanappa@gmail.com

Submitted: 09-Jan-2020 **Revised:** 27-Jan-2020 **Accepted:** 08-Feb-2020

Published: 24-Jul-2020

This is an open access journal, and articles are distributed under the terms of the Creative Commons Attribution-NonCommercial-ShareAlike 4.0 License, which allows others to remix, tweak, and build upon the work non-commercially, as long as appropriate credit is given and the new creations are licensed under the identical terms.

For reprints contact: reprints@medknow.com

DOI: 10.4103/aian.AIAN_18_20

dinucleotide tetrazolium reductase (NADH-Tr), succinic dehydrogenase (SDH), cytochrome-C oxidase combined with succinic dehydrogenase (COX-SDH), adenosine triphosphatase (ATPase) at pH 9.4 and 4.6]. Small portion of the biopsy was subjected to routine paraffin embedding and stained with Masson's trichrome to assess the endomysial fibrosis.

Immunohistochemistry (IHC)

Immunostaining to antibodies against Laminin α 2 (1:5000, 5H2, MAB1922, Merck Millipore), Laminin α 5 (1:5000, 4C7, MAB1924, Merck Millipore), Laminin β 1 (1:5000, 4E10, MAB1921P, Merck Millipore), Laminin γ 1 (1:5000, 2E8, MAB1920, Merck Millipore), Collagen Type VI Antibody (1:5000, VI-26, MAB3303, Merck Millipore), and Collagen Type VI Antibody (1:5000, 3C4, MAB1944, Merck Millipore) was performed. Wherever required in case of clinical suspicion to rule out other muscular dystrophies, staining with respective monoclonal antibodies [dystrophin 1 (1:50, DY4/6D3, NCL-DYS1, Novocastra), dystrophin 2 (1:20, Dy8/6C5, NCL-DYS2, Novocastra), dystrophin 3 (1:10, DY10/12B2, NCL-DYS3, Novocastra), alpha-sarcoglycan (1:50, AD1/20A6, NCL-L-a-SARC, Novocastra), beta-sarcoglycan (1:10, BETASARC1/5B1, NCL-L-b-SARC, Novocastra), gamma-sarcoglycan (1:150, 35DAG/21B5, NCL-g-SARC, Novocastra), delta-sarcoglycan (1:50, NCL-d-SARC, DELTASARC/12C1, Novocastra), dysferlin (1:50, HAM3/17B2, NCL-Hamlet-2, Novocastra), Emerin (1:50, 4G5, NCL-EMERIN, Novocastra), and lamin A/C (1:50, NCL-LAM-A/C, Novocastra)] was performed.

The normal immunolabeling to the panel of antibodies is as follows:^[1]

1. anti-Laminin α 2: Sarcolemma (basal lamina) of muscle fibers
2. anti-Laminin α 5: Limited to blood vessels. Expressed on sarcolemma of fetal and immature muscle fibers. No expression on sarcolemma of mature fibers as it gets downregulated during development
3. anti-Laminin β 1: Sarcolemma of muscle fibers and blood vessels
4. anti-Laminin γ 1: Sarcolemma of muscle fibers and blood vessels. Till date no defects in laminin γ 1 have been identified and it is, therefore, useful for assessing the integrity of the basal lamina
5. anti-Collagen Type VI: Sarcolemma of muscle fibers along with the endomysial and perimysial collagen.

Western blot (WB)

10-mg of flash frozen muscle tissue minced in extraction buffer was subjected to probe sonication and supernatant was collected. 10 μ l of solubilized protein was run on 10% sodium dodecyl sulfate-polyacrylamide gel electrophoresis (SDS-PAGE). Coomassie brilliant blue (CBB) staining was performed for myosin which is a loading control. Following semidry transfer onto polyvinylidene difluoride membrane, the blot

was incubated with primary antibody to α -dystroglycan (1:4000, I1H6C4, 05-593, Merck millipore). While for POMT1 antibody (1:500, Rabbit polyclonal, sc-98908, Santa Cruz), the transfer was onto nitrocellulose membrane. Membranes were washed and incubated with appropriate HRP tagged secondary antibody. Following incubation, membranes were washed with buffer and the immune reaction was visualized by enhanced chemiluminescence (ECL) kit.

RESULTS

Of the 2248 muscle biopsies received between 2014 and 2017, 612 (27.2%) were diagnosed as muscular dystrophy. Among these, 57 cases (9.3%) clinically suspected to be congenital muscular dystrophy were included in the study. All 57 cases were initially subjected to immunohistochemistry. Fifteen cases (26.3%) were characterized as Merosin deficient CMD and 11 cases (19.2%) as Ullrich CMD. Thirty-one cases remained uncharacterized. WB was performed on fresh frozen muscle tissue available in 17/31 cases. Deficiency of α -dystroglycan was noted in 7/17 cases (12.3%), with an additional deficiency of POMT1 in a single case. This case was subclassified as Walker-Warburg syndrome based on the clinical features. The remaining 24 cases (42.2%) were uncharacterized [Table 1].

Merosin deficient CMD

Fifteen cases confirmed as merosin deficient presented with age ranging from 10 months–10 years (mean: 3.7 years) with M:F ratio of 1.5:1. All had elevated CK levels (mean: 1657 U/L, range: 442–2557 U/L). They presented with motor delay since birth, hypotonia, proximal weakness, bifacial weakness, and multiple contractures. In addition, 8 cases had myopathic facies with low set ears, high arched palate, open mouth, and malocclusion of teeth. History of similar illness in the sibling was recorded in 2 cases. MRI available in eight cases showed white matter hyperintensities in all. On histology, the biopsy showed features compatible with muscular dystrophy with significant endomysial fibrosis. IHC revealed complete absence of laminin α 2 in all cases, overexpression of laminin α 5 on the sarcolemma in 7 cases, and reduced or patchy labeling of laminin β 1 on the sarcolemma but retained on blood vessels in 6 cases. Laminin γ 1 and Collagen VI showed preserved expression [Figure 1].

Ullrich CMD

There were 11 cases with collagen VI deficiency. Mean age at presentation was 5.3 years (range: 3–9 years), M:F ratio was 1.2:1. CK was normal in all. They presented with hypotonia and muscle weakness since early childhood, multiple joint contractures early in life (7/11), and distal joint hyperextensibility (9/11). Prominent calcaneum (4/11), soft velvety palms and soles with fine reticular pattern (9/11), rounded myopathic face (5/11), and torticollis (1/11) were other features. MRI available in 2 cases was normal. There was history of similar illness in 2 cases, with siblings affected. IHC revealed two patterns of deficiency. While majority (8/11) of

Table 1: Clinical characteristics and immunotyping of cases with congenital muscular dystrophy

Parameter	Merosin deficient CMD (n=15, 26.3%)	Ullrich CMD (n=11, 19.2%)	α -Dystroglycanopathy (n=7, 12.3%)	Uncharacterized (n=24, 42.2%)
Mean age at presentation	3.7 years	5.3 years	6.3 years	7.2 years
M: F ratio	1.5:1	1.2:1	1.3:1	1.6:1
Mean creatinine kinase	1657 U/L	Normal	2371 U/L	1233 U/L
MRI *	White matter hyperintensities-8/8	Normal-2/2	pachygyria, lissencephaly, and cerebellar cyst-1/1 (WWS)	White matter hyperintensities-3/3
Positive family history *	2/3	2/2	NA	2/6
Hypotonia	15	11	7	22
Motor delay	14	9	4	17
Myopathic facies	8	5	4	10
Soft velvety palms & soles	0	9	4	8
Multiple contractures	11	7	6	19
Distal joint hyperextensibility	1	9	1	12
Prominent calcaneum	2	4	3	5
Seizures	0	0	1	0
Laminin α 2	Complete loss-15	Preserved	Reduced-3 Preserved-4	Preserved
Laminin α 5	Overexpression-7	Limited to blood vessels	Limited to blood vessels	Limited to blood vessels-22 Overexpression-2
Laminin β 1	Reduced-6	Preserved	Preserved	Preserved
Laminin γ 1	Preserved	Preserved	Preserved	Preserved
Collagen VI (A1,2,3)	Preserved	Complete loss-8 Sarcolemmal specific loss-3	Preserved	Preserved
α -DG			Absent-5 Reduced-2	Preserved
POMT1			Absent-1 (WWS)	Preserved

* Denominator indicates the total number in which data was available, DG: Dystroglycan, CMD: Congenital muscular dystrophy, NA: Not available, WWS—Walker–Warburg syndrome

the cases showed complete loss of expression of collagen VI in all the fibers, a minority of the cases (3/11) had sarcolemmal specific loss with retained expression in endomysial and perimysial collagen. The laminin α 2, β 1, and γ 1 was preserved and laminin α 5 was restricted to labeling the blood vessels only (normal pattern) [Figure 2].

α -Dystroglycanopathy

α -dystroglycan deficiency was noted in 7/17 uncharacterized cases. Among the seven cases, complete absence was noted in five cases while reduced expression in two cases. Mean age at presentation was 6.3 years (range: 2–14 years) and M:F ratio was 1.3:1. CK levels ranged between 242 and 6987 U/L. They presented with global developmental delay, facial weakness, difficulty in standing and walking, myopathic facies, and joint contractures. In addition, three cases showed partial or secondary reduced expression of laminin α 2 [Figure 3]. MRI was available in a single case which showed reduced α -dystroglycan and POMT1 deficiency on WB. The findings of this case with POMT1 deficiency are described below.

POMT1 deficiency

A 14-year-old male presented with hypotonia, seizures, and scanning speech. On examination, he had divergent squint, low set ears, flattened nasal bridge, hypertelorism, and thickened lips. MRI revealed pachygyria, lissencephaly, and cerebellar cyst. Based on the clinical phenotype, the diagnosis of

Walker–Warburg syndrome was considered and muscle biopsy submitted for diagnosis showed normal labeling of laminins and collagen VI, while loss of POMT1 on WB [Figure 3].

Uncharacterized cases

Twenty-four cases (42.2%) remained uncharacterized on IHC and WB. They presented with hypotonia, motor developmental delay, facial and limb weakness, contractures, myopathic facies, and CK levels ranging from 66–4058 U/L. MRI findings available in 3 cases showed white matter hyperintensities.

DISCUSSION

Our study of 57 cases of CMD over 4 years was based on IHC and WB. Among these, 33 cases accounting for 57.8% were subtyped. Merosin deficient CMD (26.3%) was the commonest, followed by Ullrich CMD (19.2%) and α -dystroglycanopathy (12.3%). In a clinical and molecular study of 440 CMD cases over 13 years from United Kingdom, the most common CMD was merosin deficient (37.35%), followed by α -dystroglycanopathy (26.5%) and Ullrich CMD (15.7%),^[6] while in Japanese population, Fukuyama CMD due to founder mutation was the most common, followed by collagen VI deficiency.^[4,5] A large cohort of 101 CMD cases from Australia with diverse ethnicity subtyped 45% of cases based on immunofluorescence and found α -dystroglycanopathy (25%) to be the commonest, followed

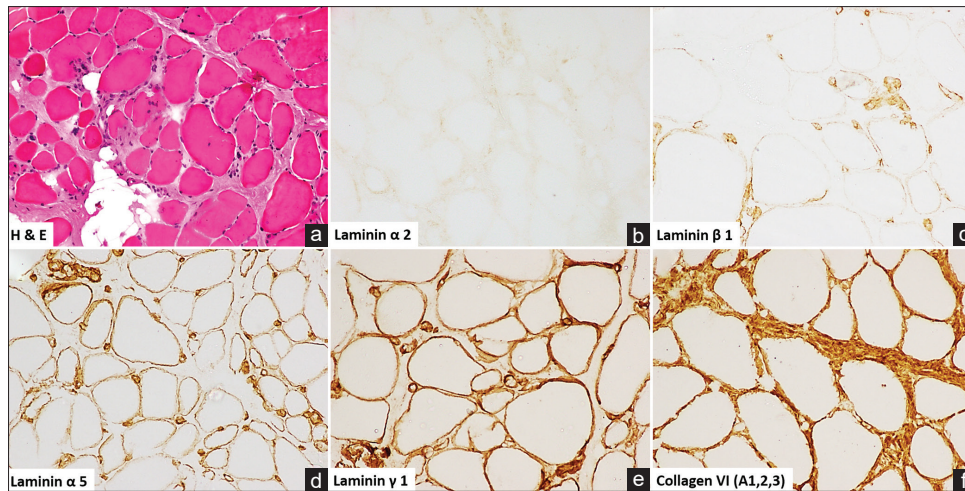


Figure 1: Merosin deficient CMD: H and E showing features of muscular dystrophy with variation in fiber size, rounding of fibers, and increased endomysial collagen (a). Complete loss of expression of laminin $\alpha 2$ (b), secondary reduction of laminin $\beta 1$ (c), overexpression of laminin $\alpha 5$ (d), preserved expression of laminin $\gamma 1$ (e), and collagen VI (A1,2,3) (f)

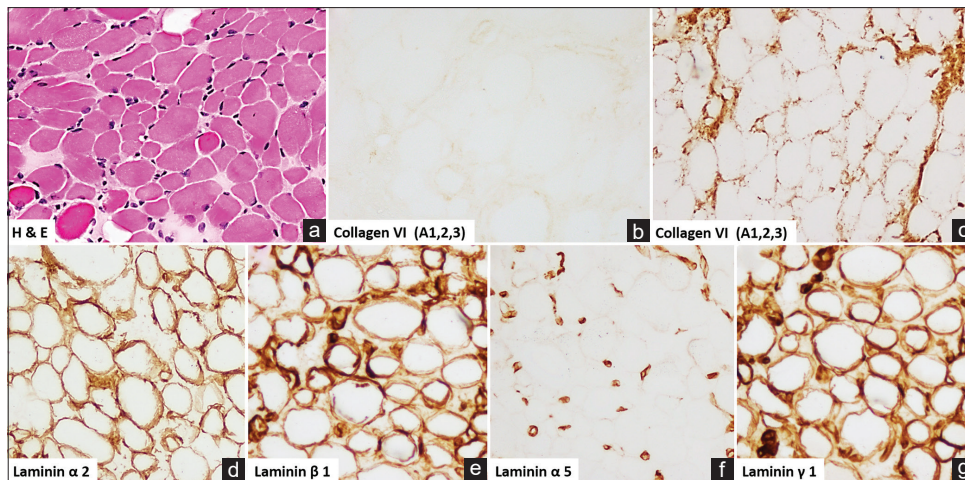


Figure 2: Ullrich CMD: H and E showing features of muscular dystrophy (a). Two patterns of collagen VI (A1,2,3) labeling: complete loss of staining (b) and sarcolemmal specific loss (c) were seen, while preserved expression of laminin $\alpha 2$ (d) and laminin $\beta 1$ (e), laminin $\alpha 5$ limited to blood vessels (f), and preserved expression of laminin $\gamma 1$ (g) was noted

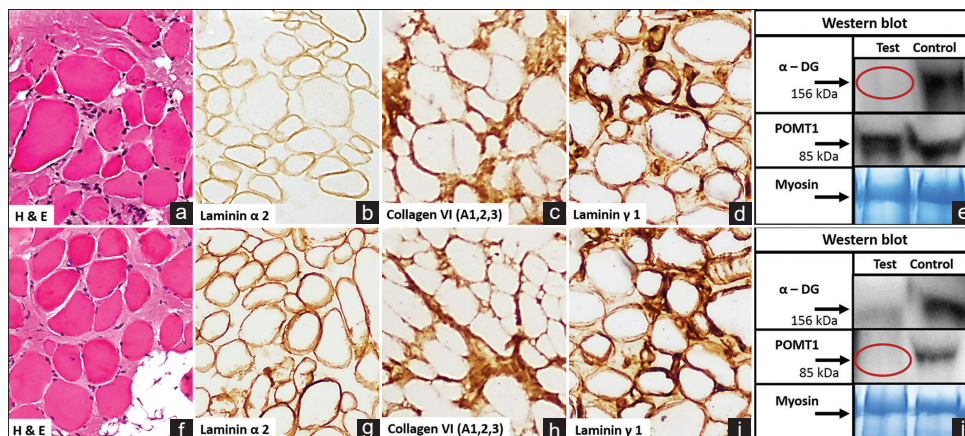


Figure 3: α -Dystroglycanopathy (a-e): H and E showing features of muscular dystrophy (a). Partial loss/reduced expression of laminin $\alpha 2$ (b). Preserved expression on collagen VI (A1,2,3) (c) and laminin $\gamma 1$ (d). Western blot (e) showing absence of band at 156 kDa in test on staining with primary antibody for α -dystroglycan (α -DG). Walker-Warburg syndrome (f-j): H and E showing features of muscular dystrophy (f). Preserved expression of laminin $\alpha 2$ (g), collagen VI (A1,2,3) (h), and laminin $\gamma 1$ (i). Western blot (j) showing absence of band at 85 kDa to POMT1 and reduced α -dystroglycan (α -DG; 156 kDa) expression

by Ullrich CMD (12%) and merosin deficiency (8%).^[8] A study based only on IHC, in 56 cases over 10 years from our Institute found Ullrich CMD in 13, Merosin deficient CMD in 9, and α -dystroglycanopathy in 3 cases, remaining being uncharacterized.^[9] The cohort included in this study is different from the previous study carried out by us.

Merosin deficient CMD

It is caused by deficiency of laminin $\alpha 2$ due to mutation in *LAMA2* gene, an integral component of basement membrane and plays an important role in cell to extracellular matrix communication.^[10] Laminins are heterotrimers composed of α , β , and γ chains. Most abundant trimer in muscle is merosin composed of $\alpha 2$ - $\beta 1$ - $\gamma 1$ chains, also known as laminin 211.^[11] All our cases showed complete deficiency of laminin $\alpha 2$. No partial deficiency was seen although described in other studies.^[9,11,12] Laminin $\alpha 5$ is developmentally regulated, presents on immature fibers, and is down-regulated as the fiber matures. We found overexpression of laminin $\alpha 5$ in all the cases suggesting a failure of switch from $\alpha 5$ chain to $\alpha 2$ chain as described in the literature.^[11] In addition, reduced and patchy labeling of laminin $\beta 1$ with preserved intensity on blood vessels was seen in 6/15 cases. Similar finding of reduced laminin $\beta 1$ was observed by Sewry *et al.* in 5/12 merosin deficient cases.^[13] Secondary reduction in laminin $\beta 1$ has also been described in Bethlem myopathy, autosomal dominant Emery–Dreifuss muscular dystrophy, facioscapulohumeral muscular dystrophy and due to mutation in *FKRP* gene in limb girdle muscular dystrophy. Secondary reduction in laminin $\beta 2$ a component of laminin 221 has also been reported in merosin deficient CMD.^[11] While skeletal muscle tissue is preferred for diagnosis of laminin $\alpha 2$ deficiency, skin biopsies have also been used.^[14] Chorionic villus samples are used for prenatal diagnosis.^[15]

All cases in our cohort had classical presentation with hypotonia and muscle weakness since birth. Two cases had feeding difficulties and recurrent respiratory tract infections. Development of multiple contractures involving the elbow, hip, knee, and ankle joint was the most common feature. None of them could stand or walk independently. Intelligence was normal and serum CK was elevated in all. These findings were consistent with other studies.^[8,14,16] MRI done in 8 cases showed white matter hyperintensities. Abnormalities in white matter after the age of 6 months are attributed to abnormal myelination rather than demyelination.^[11] None of the cases with merosin deficiency in our cohort showed structural anomalies in brain.

Collagen VI myopathy

It is caused by defects in the genes encoding collagen VI (*COL6A1*, *COL6A2*, *COL6A3*). Collagen VI present in the extracellular matrix is involved in building the basement membrane of myofibers and plays a critical role in maintaining its structural integrity.^[17,18] While Ullrich CMD is severe autosomal recessive phenotype, Bethlem myopathy is milder and autosomal dominant. In addition, autosomal dominant Ullrich CMD and autosomal recessive Bethlem myopathy

have also been reported.^[1,6] All cases diagnosed as Ullrich CMD presented with hypotonia and weakness early in life, myopathic facies, contractures, prominent calcaneum, distal joint laxity, and specific skin features of soft velvety palms and soles. IHC to collagen VI showed either complete loss (8/11) or sarcolemmal-specific loss (3/11) as described in other studies.^[19,20] Laminins $\alpha 2$, $\beta 1$, $\gamma 1$ showed preserved expression, and laminin $\alpha 5$ was limited to blood vessels.

α -Dystroglycanopathy

This form of CMD has varied clinical presentation with involvement of the brain and eyes, with or without mental retardation. It results from mutations in *POMT1*, *POMT2*, *POMGnT1*, *Fukutin*, *FKRP*, *LARGE*, *ISPD*, *GMPPB*, *B3GALNT2* encoding the glycosyltransferases, responsible for the post translational modification of proteins.^[6] Structural abnormalities described in α -dystroglycanopathies include type 2 lissencephaly, agyria, pachygyria, cerebellar cysts, and hydrocephalus. Eye involvement range from congenial myopia, glaucoma, cataracts, retinal dysplasia to microphthalmia.^[11] In our series, we had 7 cases with deficiency of α -dystroglycan diagnosed on WB. IHC showed secondary reduction of laminin $\alpha 2$ in 3/7 cases as described earlier. They presented with motor delay and elevated CK. The severe cases were unable to sit and developed respiratory insufficiency while the milder phenotypes achieved standing and walking with support. Early contractures were seen in majority of the cases. None of them had ocular features.

POMT1 deficiency

POMT1 is involved in O-linked mannosylation of α -dystroglycan. The single case of POMT1 deficiency presented with seizures. MRI revealed pachygyria, lissencephaly, and cerebellar cyst. No ocular abnormalities were present. Immunohistochemically, there was normal labeling to laminins and collagen VI. Unlike muscle eye brain disease, secondary reduction of laminin $\alpha 2$ is not seen in Walker–Warburg syndrome and could be a useful diagnostic feature.^[21] Thus, based on clinical features and immunotyping, this case was classified as Walker–Warburg syndrome.

Uncharacterized cases of CMD

Due to limited number of antibodies used, 42.2% cases with clinical phenotype of CMD remained unclassified. Rigid spine with muscular dystrophy (RSMD1) is a form of CMD caused by recessive mutations in the gene for *SEPN1* which encodes for Selenoprotein, localising to endoplasmic reticulum.^[11] Although our cohort included 2 cases with spinal rigidity within the uncharacterized group, they did not show the characteristic minicores on oxidative stains (NADH-TR, SDH, COX-SDH) by enzyme histochemistry as seen in RSMD1. Nonetheless, these uncharacterized cases could benefit from genetic testing.

CONCLUSION

The present study is one of the largest cohorts subtyping CMD in India. IHC and WB helped in characterizing 57.8% of the

proband. Merosin deficient CMD was the most common followed by Ullrich CMD. One case of POMT1 deficiency was seen. Characterization of cases enables prenatal diagnosis and genetic counseling. It also helps to direct mutational analysis for targeted genes.

Financial support and sponsorship

Nil.

Conflicts of interest

There are no conflicts of interest.

REFERENCES

- Dubowitz V, Sewry CA, Oldfors A. Congenital muscular dystrophies and associated disorders. In: Dubowitz V, Sewry CA, Oldfors A, editors. *Muscle biopsy: A practical approach*, 4th ed. London: Elsevier; 2013. p. 302-30.
- Mostacciolo ML, Miorin M, Martinello F, Angelini C, Perini P, Trevisan CP. Genetic epidemiology of congenital muscular dystrophy in a sample from north-east Italy. *Hum Genet* 1996;97:277-9.
- Darin N, Tulinius M. Neuromuscular disorders in childhood: A descriptive epidemiological study from western Sweden. *Neuromuscul Disord* 2000;10:1-9.
- Matsumoto H, Hayashi YK, Kim DS, Ogawa M, Murakami T, Noguchi S, *et al.* Congenital muscular dystrophy with glycosylation defects of alpha-dystroglycan in Japan. *Neuromuscul Disord* 2005;15:342-8.
- Okada M, Kawahara G, Noguchi S, Sugie K, Murayama K, Nonaka I, *et al.* Primary collagen VI deficiency is the second most common congenital muscular dystrophy in Japan. *Neurology* 2007;69:1035-42.
- Sframeli M, Sarkozy A, Bertoli M, Astrea G, Hudson J, Scoto M. Congenital muscular dystrophies in the UK population: Clinical and molecular spectrum of a large cohort diagnosed over a 12-year period. *Neuromuscul Disord* 2017;27:793-803.
- Bertini E, D'Amico A, Gualandi F, Petrini S. Congenital muscular dystrophies: A brief review. *Semin Pediatr Neurol* 2011;18:277-88.
- Peat RA, Smith JM, Compton AG, Baker NL, Pace RA, Burkin DJ. Diagnosis and etiology of congenital muscular dystrophy. *Neurology* 2008;71:312-21.
- Nagappa M, Atchayaram N, Narayanappa G. A large series of immunohistochemically confirmed cases of congenital muscular dystrophy seen over a period of one decade. *Neurol India* 2013;61:481-7.
- Holmberg J, Durbeej M. Laminin-211 in skeletal muscle function. *Cell Adh Migr* 2013;7:111-21.
- Herrmann R, Straub V, Meyer K, Kahn T, Wagner M, Voit T. Congenital muscular dystrophy with laminin alpha 2 chain deficiency: Identification of a new intermediate phenotype and correlation of clinical findings to muscle immunohistochemistry. *Eur J Pediatr* 1996;155:968-76.
- Tan E, Topaloglu H, Sewry C, Zorlu Y, Naom I, Erdem S, *et al.* Late onset muscular dystrophy with cerebral white matter changes due to partial merosin deficiency. *Neuromuscul Disord* 1997;7:85-9.
- Sewry CA, Philpot J, Mahony D, Wilson LA, Muntoni F, Dubowitz V. Expression of laminin subunits in congenital muscular dystrophy. *Neuromuscul Disord* 1995;5:307-16.
- Marbini A, Bellanova MF, Ferrari A, Lodesani M, Gemignani F. Immunohistochemical study of merosin-negative congenital muscular dystrophy: Laminin a2 deficiency in skin biopsy. *Acta Neuropathol* 1997;94:103-8.
- Fadiloglu E, Ozten G, Unal C, Talim B, Topaloglu H, Beksac MS. Prenatal diagnosis of merosin-deficient muscular dystrophy. *Fetal Pediatr Pathol* 2018;37:418-23.
- Manole E, Alexianu M. Merosin-deficient congenital muscular dystrophy: Neuropathology case reports. *J Cell Mol Med* 2000;4:289-96.
- Cescon M, Gattazzo F, Chen P, Bonaldo P. Collagen VI at a glance. *J Cell Sci* 2015;128:3525-31.
- Reed UC, Ferreira LG, Liu EC, Resende MB, Carvalho MS, Marie SK, *et al.* Ullrich congenital muscular dystrophy and Bethlem myopathy: Clinical and genetic heterogeneity. *Arq Neuropsiquiatr* 2005;63:785-90.
- Kawahara G, Okada M, Morone N, Moreno C, Nonaka I, Noguchi S, *et al.* A heterozygous COL 6A1 glycine substitution that influences cell attachment in fibroblasts causes sarcolemmal-specific collagen VI deficiency (SSCD). *Neuromuscul Disord* 2006;16:84-5.
- Nalini A, Gayathri N, Santosh V. Ullrich congenital muscular dystrophy: Report of nine cases from India. *Neurol India* 2009;57:41-5.
- Voit T, Sewry CA, Meyer K, Herrmann R, Straub V, Muntoni F, *et al.* Preserved merosin M-chain (or laminin-alpha 2) expression in skeletal muscle distinguishes Walker-Warburg syndrome from Fukuyama muscular dystrophy and merosin-deficient congenital muscular dystrophy. *Neuropediatrics* 1995;26:148-55.