

Evolution in Surgical Management of Breast Cancer-related Lymphedema: The MD Anderson Cancer Center Experience

Edward I. Chang, MD, FACS
 Mark V. Schaverien, MD, MBChB,
 MSc, MED
 Summer E. Hanson, MD, PhD,
 FACS
 Carrie K. Chu, MD, FACS
 Matthew M. Hanasono, MD, FACS

Introduction: Lymphedema is a lifelong, debilitating condition that plagues a large portion of patients who have undergone multimodality therapy for breast cancer. With the increasing experience in supermicrosurgical treatment of lymphedema, reconstructive surgeons have made a tremendous impact in improving the quality of life of patients suffering from breast cancer related lymphedema.

Methods: Historical review of our evolution in treatment and management of breast cancer related lymphedema and implementation of our new algorithm. Retrospective review of patients who have undergone both the lymphovenous bypass and vascularized lymph node transfer with autologous breast reconstruction.

Results: The combined Breast Reconstruction Including Lymphovenous bypass and Inguinal to Axillary Node Transfer (BRILIANT) demonstrates promising outcomes. Thirty-eight patients (average age: 52.9 years, average BMI: 32.6 kg/m²) who have undergone the BRILIANT approach have all demonstrated improvements in their lymphedema. With an average follow-up of 19.1 months, no patients suffered a post-operative cellulitis, and 81.6% of patients also demonstrated a volume reduction.

Conclusion: Our new algorithm combining breast reconstruction with lymphedema surgery represents an evolution in our approach to treatment of breast cancer related lymphedema has demonstrated promising results with long-term outcomes. (*Plast Reconstr Surg Glob Open* 2020;8:e2674; doi: [10.1097/GOX.0000000000002674](https://doi.org/10.1097/GOX.0000000000002674); Published online 25 March 2020.)

INTRODUCTION

In the industrialized world, the most common etiology for lymphedema is the treatment for cancer. Studies have demonstrated repeatedly that the combination of a regional nodal dissection coupled with chemotherapy and radiation significantly increases the risks of developing in lymphedema.¹⁻³ In particular, patients who have undergone multimodality therapy for breast cancer can be at exceedingly high risk, where more than a third will develop lymphedema in their lifetime. Historical approaches to treating lymphedema were reductive and aimed to remove fluid and bulk from the affected arm; however, debulking procedures like liposuction have

generally produced limited temporary benefits although others have demonstrated more durable results.^{4,5}

With the emerging technology and familiarity with super microsurgery, the field of lymphedema surgery witnessed profound advancements with the evolution of physiologic procedures aimed to improve the drainage of lymphatic fluid from the arm. The two approaches are the lymphaticovenular bypass or anastomosis (LVA) and the vascularized lymph node transfer (VLNT), both of which have proved to be effective means in improving symptoms in patients suffering from lymphedema.⁶⁻⁹ The LVA approach relies on detection of patent lymphatic channels that can be anastomosed to a recipient venule, effectively shunting fluid from the obstructed arm into the systemic circulation.¹⁰ However, the anastomosis is only feasible in patients with earlier stage lymphedema when lymphatic vessels are still present.

However, when patients present with more severe, advanced stages of lymphedema where the lymphatic

Department of Plastic Surgery, University of Texas MD Anderson Cancer Center, Houston, Tex.

Received for publication November 4, 2019; accepted December 18, 2019.

Copyright © 2020 The Authors. Published by Wolters Kluwer Health, Inc. on behalf of The American Society of Plastic Surgeons. This is an open-access article distributed under the terms of the [Creative Commons Attribution-Non Commercial-No Derivatives License 4.0 \(CCBY-NC-ND\)](https://creativecommons.org/licenses/by-nc-nd/4.0/), where it is permissible to download and share the work provided it is properly cited. The work cannot be changed in any way or used commercially without permission from the journal.

DOI: [10.1097/GOX.0000000000002674](https://doi.org/10.1097/GOX.0000000000002674)

Disclosures: The authors have no commercial associations or financial disclosures that might pose or create a conflict of interest with information presented in this article at the time of the study. EIC was previously a speaker for Novadaq Inc., but no funding was received for the work presented in this article.

channels have become sclerosed and fibrotic, performing a VLNT is the only physiologic option available. While the precise mechanism of action is an area of debate, animal studies have demonstrated lymphangiogenesis from the transplanted lymph nodes.¹¹ Similarly, while a number of different donor sites have been described for VLNT, the efficacy of each donor site seems comparable and the greatest distinction remains in evaluating the differences in donor site morbidity.^{12,13} However, for patients who present for treatment of breast cancer-related lymphedema (BCRL), the present study aims to describe our modified algorithm.

Preoperative Evaluation

All patients presenting for super microsurgical treatment of BCRL should undergo a thorough history and physical. The history should clearly include the patient's breast cancer treatment including pathologic diagnosis, surgery, the number of lymph nodes removed, history of adjuvant therapies including chemotherapy and radiation, and also hormonal therapy. Regarding the patient's lymphedema, the initial consultation should document the duration and onset of symptoms, hand and upper extremity dominance, any history of prior infections and cellulitis episodes, and the management of their lymphedema in terms of compression garments, decongestive therapy, massage, pneumatic compression pumps, and manual lymphatic drainage.

The physical examination should evaluate the mastectomy skin and extent of the radiation damage. The skin should be palpated for pliability and softness, and the axilla should also be evaluated for any tethering, cording, and hollowing from the axillary dissection. The abdomen should be evaluated for adequate tissue to serve as a donor site for autologous tissue reconstruction, and the presence of any scars and incisions from prior surgeries should be noted. The arm should be evaluated thoroughly to discern the severity of lymphedema and can be classified based on a number of different scales. The physical examination should document whether the entire arm or only portions of the arm are affected. A thorough neurovascular exam should also be performed. The presence of significant fibrosis and woodiness, pitting edema, signs of infection, range of motion, and a Stemmer's sign should also be noted. Ideally, objective measurements of the arm should also be performed which varies based on surgeon preference and available resources. At the authors' institution, patients have a baseline perometer measurement to determine the volume differential between the affected and unaffected arm as well as an L-Dex which provides an objective reference comparing the amount of fat and fluid distribution in the affected extremity. Other objective measurements that can be performed include circumferential measurements along the length of the extremity, bioimpedance, or imaging studies to be discussed in the next section.

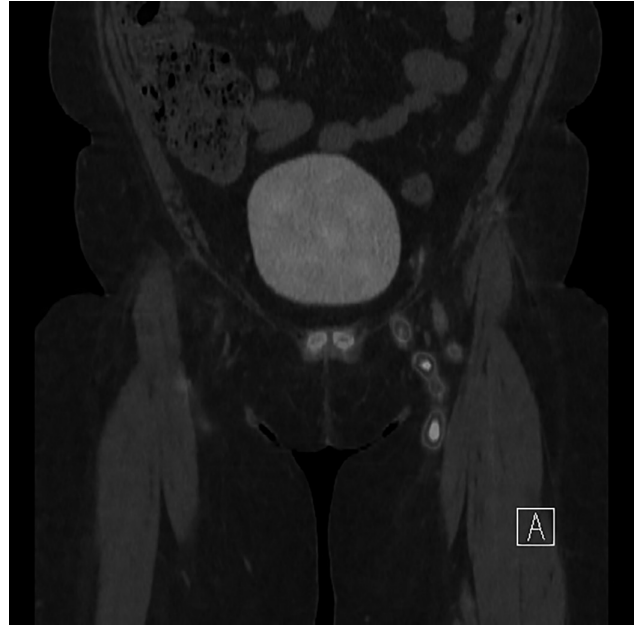


Fig. 1. Preoperative lymphoscintigraphy demonstrating location of the sentinel nodes draining bilateral lower extremities. The location of the sentinel nodes dictates the laterality for the inguinal node harvest.

Preoperative Imaging Studies

All patients should have preoperative lymphoscintigraphy with SPECT/CT scan and intraoperative reverse lymph node mapping to identify the sentinel nodes in the groin to be preserved during the inguinal lymph node harvest (Fig. 1). This is critical to limit the risk of iatrogenic lymphedema of the leg following harvest of the inguinal nodes. A CT angiogram can be performed to delineate the perforators and vascular anatomy of the deep inferior epigastric vessels; however, this is at the discretion of the reconstructive super microsurgeon.¹⁴ The ability to perform a simultaneous LVA is best determined using indocyanine green (ICG) lymphangiography with either the photodynamic eye (Hamamatsu Inc., Japan) or Spy Phi (Stryker Inc., Kalamazoo), which can be performed in the clinic or at the time of surgery. In general, only channels that are obstructed should be bypassed, and lymphatic vessels that are draining should not be violated. While some supermicrosurgeons recommend preoperative MR lymphangiography, this often requires specialized protocols and is not routinely performed at the authors' institution.

Surgical Technique

The LVA can be performed at the start of the operation, after completion of the DIEP and VLNT transfer, or simultaneously using a 2-team approach. Following injection of ICG (~0.1 mL) into the web spaces and on the radial and ulnar aspect of the volar forearm, the lymphatic channels are visualized and marked. We have since incorporated the use of the Vein Finder to identify recipient veins adjacent to the lymphatic channels. Channels that are flowing and not obstructed are preserved, and only those that are obstructed demonstrating dermal backflow are explored. Isosulfan blue is then injected distal to where

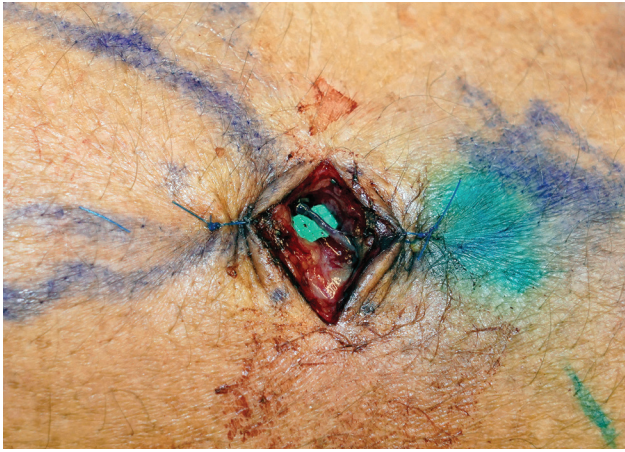


Fig. 2. LVA performed between a lymphatic vessel and recipient venule in an end-to-end fashion. Confirmation of patency and flow is confirmed with drainage from the lymphatic channel into the venule.

the lymphatic and vein are localized before making the skin incision to aid in identification of the lymphatics. The lymphatic vessel and recipient vein are dissected under the operative microscope (Mitaka Inc.), and the anastomosis is completed using 11-0 nylon sutures. Patency is always confirmed with drainage of isosulfan blue, ICG, or lymphatic fluid from the lymphatic into the vein (Fig. 2).

The DIEP flap harvest is based on surgeon preference, but the inguinal lymph nodes are centered on the superficial inferior epigastric vessels or the superficial circumflex iliac vessels.^{14,15} We typically perform the lymphoscintigraphy the day before surgery allowing us to use the Neoprobe to identify and preserve the sentinel nodes draining the lower extremities; however, isosulfan blue can also be injected at the start of the case to aid in avoiding the sentinel nodes in the groin. The nodes should not be visualized during the dissection and are perfused by a wide-based adipofascial pedicle in continuity with the DIEP flap (Fig. 3). Once the lymph nodes have been included in the flap, the superficial vessels can be skeletonized and dissected more proximally for length and

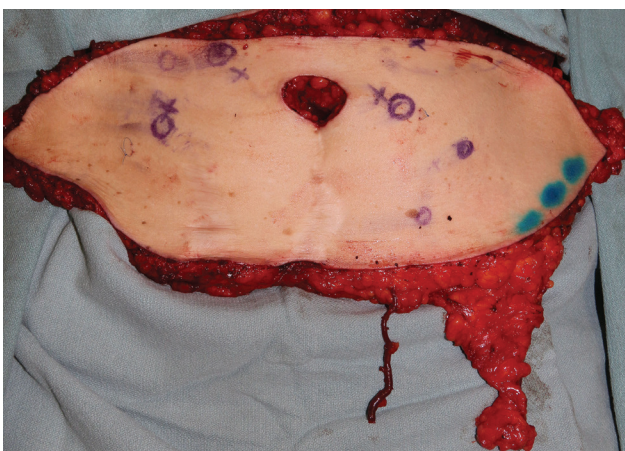


Fig. 3. Free DIEP flap harvested with the inguinal nodes.

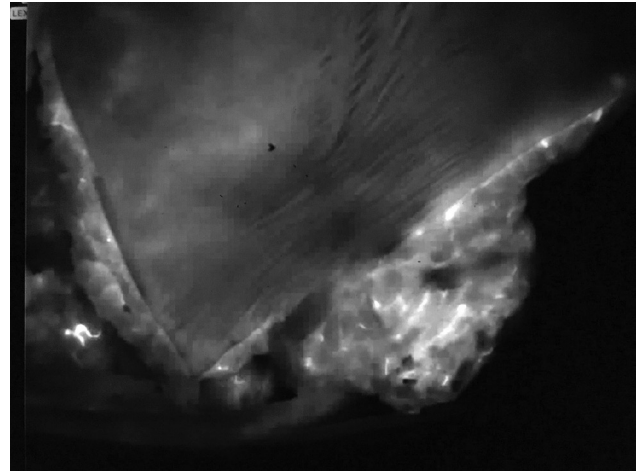


Fig. 4. The perfusion of the lymph nodes harvested with the DIEP is always evaluated with the use of ICG to determine whether an additional arterial, venous, or both anastomoses are necessary.

caliber should an additional arterial or venous anastomosis be needed to maintain the viability of the lymph nodes. The authors routinely use ICG angiography both to confirm adequate perfusion of the DIEP flap to limit the risks of fat necrosis, as well as the lymph nodes to determine whether additional anastomoses are needed (Fig. 4).

The internal mammary vessels are always used as the recipient vessels for the deep inferior epigastric system, and the thoracodorsal vessels are preserved in case of a total flap loss. If an additional arterial or venous anastomosis is needed, the authors prefer to use a branch of the thoracodorsal system, such as the serratus branch, but the lateral thoracic vessels or another branch of the subscapular system can also serve as recipient vessels. If additional venous outflow is needed, one of the venae comitantes of the thoracodorsal system can be sacrificed as a recipient vein which still allows the ability to harvest a latissimus dorsi flap in the salvage setting. Whether or not any additional anastomoses are needed remains an area of tremendous debate; however, likely an additional venous anastomosis is more critical than an additional arterial anastomosis.

Outcomes

The combined approach to addressing BCRL was recently implemented at the authors' institution and has demonstrated promising results superior to either approach alone. The Breast Reconstruction Including Lymphaticovenular anastomosis and Inguinal to Axillary Node Transfer (BRILIANT) now represents the standard of care where patients suffering from BCRL who are also seeking breast reconstruction can obtain an autologous breast reconstruction while also gaining some improvement in their lymphedema in a single operation. Overall, 38 patients (average age: 52.9 years, average BMI: 32.6 kg/m²) have undergone the combined approach with a minimum of 12-month follow-up and demonstrated promising results. Thirty-seven patients had chemotherapy and an axillary dissection, and 36 patients had adjuvant radiation. ICG lymphatic staging based on the MD Anderson

classification system demonstrated 15 patients with stage 2 lymphedema, 18 with stage 3, 4 with stage 4, and 1 patient with stage 5 lymphedema. On average, 1.53 bypasses were performed (range: 1–4), and no patients developed lymphedema of the donor site. While a validated patient-reported outcomes metric was not performed, all patients reported a subjective improvement in their lymphedema following the BRILIANT approach. Fourteen patients had prior episodes of cellulitis; however, no patients suffered an episode of cellulitis following treatment. With a mean follow-up of 19.1 months, all patients demonstrated improvement in the lymphedema symptoms, and 31 patients (81.6%) had a volume reduction following treatment.

DISCUSSION

Historically, treatment for lymphedema was based entirely on ICG lymphangiography, which allowed classification of a patient’s lymphedema using the classification system previously described.¹⁰ While a number of different staging systems are available, the authors prefer the ICG staging as this has traditionally dictated the surgical management. Descriptive staging systems such as those proposed by the International Society of Lymphedema, Campisi, and Koshima fail to guide management. An arm that is mildly swollen may only be a stage 1 based on clinical exam and International Society of Lymphedema staging, but lymphatic channels may not be visualized precluding

patients from undergoing a LVA. Conversely, ICG mapping may demonstrate a combination of stardust, diffuse, and linear patterns rather than a single ICG pattern. The system the authors have proposed combines the findings and permits an algorithmic approach to surgical management.¹⁶ Patients with early stage lymphedema (stage 1 or 2) were previously treated with LVA while those with more advanced stages (stage 3 or 4) were treated using a VLNT.

However, the authors’ current approach has evolved, particularly in patients also interested in autologous breast reconstruction. In these patients, the authors believe reconstruction using an abdominal based flap coupled to the inguinal lymph nodes along with a simultaneous LVA offers patients the potential of undergoing one operation to reconstruct their breast and treat their lymphedema. The authors have introduced the combined Breast Reconstruction Including LVA and an Inguinal to Axillary Node Transfer (BRILIANT) approach which provides an aesthetic, durable autologous breast reconstruction and maximizes the treatment for lymphedema in a single operation (Fig. 5). Whether or not an additional set of anastomoses are needed to perfuse the lymph nodes remains an area of considerable debate. The authors recommend using ICG angiography to confirm adequate perfusion of the nodes, and if there are signs of poor perfusion or compromised outflow, then an additional arterial or venous anastomosis or both is warranted. The superficial system should always be harvested in the

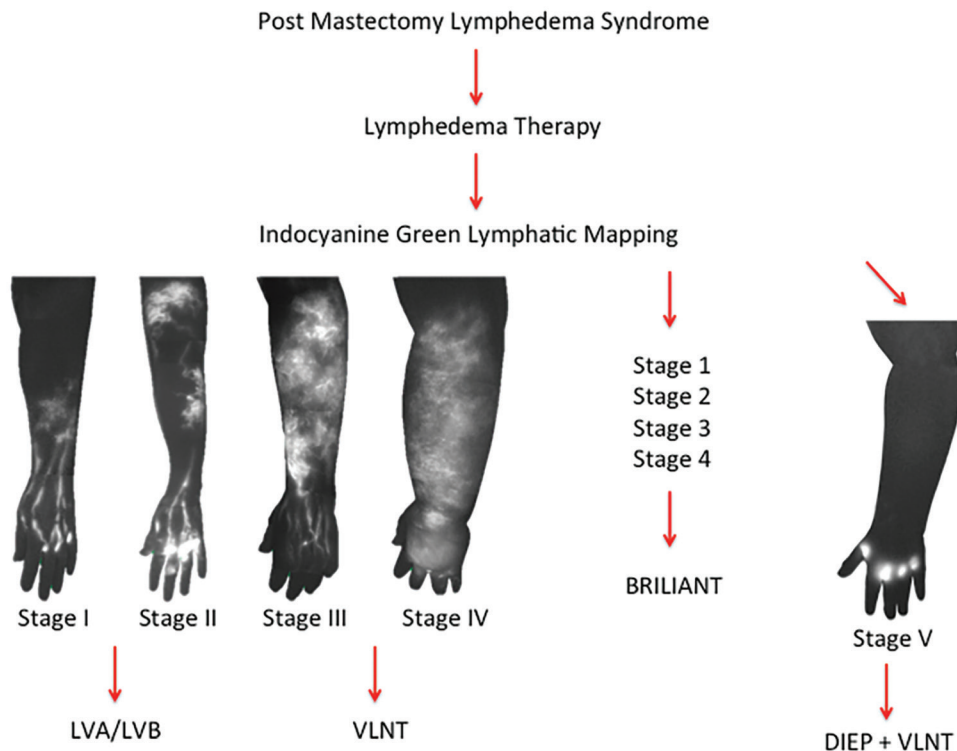


Fig. 5. The evolution of the algorithmic approach for patients with BCRL who are also interested in breast reconstruction. In patients who are not candidates for a DIEP flap breast reconstruction with BCRL, we have also adopted the combined approach of performing VLNT with lymphaticovenular anastomosis.

setting that an additional anastomosis is needed; however, we do not routinely perform more additional anastomoses which again is dictated based on the ICG findings.

Whether there is a true benefit in combining both techniques for lymphedema surgery remains to be elucidated. The 2 techniques have both been proven to be an effective means in improving a patient's lymphedema, but no study exists describing simultaneous DIEP, LVA, and VLNT.¹⁷ The 2 techniques work via independent mechanisms, and therefore, we hypothesized there is a synergistic effect where the LVA allows immediate drainage from the affected arm, while the VLNT provides a delayed benefit. The process of lymphangiogenesis typically requires months or even a year before any benefit is seen. Thus, by performing both the LVA and VLNT together, patients may recognize an immediate improvement, followed by a second wave of improvement once the lymph nodes become functional. There have also been reports of delayed failure or thrombosis of LVA which further supports the rationale for performing a VLNT simultaneously to offer the most optimal long-term outcomes.^{18,19}

In patients suffering from lymphedema with breast conservation or in patients who develop lymphedema following an abdominal free flap breast reconstruction, we have also adopted the combined LVA and VLNT approach with the use of the entire spectrum of lymph node donor sites. We generally do not recommend proceeding with an inguinal lymph node transfer in patients who have already had a prior DIEP flap as the dissection may have injured the perfusion to the lymph nodes or the superficial circumflex iliac pedicle. Early results have demonstrated excellent results, albeit performing a LVA or VLNT alone has also proven remarkably effective. Nonetheless, while we have previously described the efficacy of our technique in transferring the superficial inguinal nodes with a DIEP flap, our algorithm has evolved, and our early experience does demonstrate some compelling outcomes. Certainly, larger numbers and longer follow-up are needed, but the BRILIANT approach has now become the standard of care at the authors' institution.

CONCLUSIONS

For patients who have undergone a mastectomy and are suffering from BCRL, the combined free DIEP flap coupled to vascularized inguinal nodes and a lymphaticovenular anastomosis offers patients the dual benefit of an autologous breast reconstruction while improving their lymphedema in one operation.

Edward I. Chang, MD, FACS

Department of Plastic Reconstructive Surgery
MD Anderson Cancer Center
1400 Pressler Drive, 19.500
Houston, TX 77030

E-mail: eichang@mdanderson.org

REFERENCES

1. DiSipio T, Rye S, Newman B, et al. Incidence of unilateral arm lymphoedema after breast cancer: a systematic review and meta-analysis. *Lancet Oncol.* 2013;14:500–515.
2. Asdourian MS, Swaroop MN, Sayegh HE, et al. Association between precautionary behaviors and breast cancer-related lymphedema in patients undergoing bilateral surgery. *J Clin Oncol.* 2017;35:3934–3941.
3. Rockson SG. Lymphedema after breast cancer treatment. *N Engl J Med.* 2018;379:1937–1944.
4. Greene AK, Voss SD, MacLellan RA. Liposuction for swelling in patients with lymphedema. *N Engl J Med.* 2017;377:1788–1789.
5. Schaverien MV, Munnoch DA, Brorson H. Liposuction treatment of lymphedema. *Semin Plast Surg.* 2018;32:42–47.
6. Garza RM, Chang DW. Lymphovenous bypass for the treatment of lymphedema. *J Surg Oncol.* 2018;118:743–749.
7. Chang EI, Skoracki RJ, Chang DW. Lymphovenous anastomosis bypass surgery. *Semin Plast Surg.* 2018;32:22–27.
8. Gould DJ, Mehrara BJ, Neligan P, et al. Lymph node transplantation for the treatment of lymphedema. *J Surg Oncol.* 2018;118:736–742.
9. Silva AK, Chang DW. Vascularized lymph node transfer and lymphovenous bypass: novel treatment strategies for symptomatic lymphedema. *J Surg Oncol.* 2016;113:932–939.
10. Chang DW, Suami H, Skoracki R. A prospective analysis of 100 consecutive lymphovenous bypass cases for treatment of extremity lymphedema. *Plast Reconstr Surg.* 2013;132:1305–1314.
11. Patel KM, Lin CY, Cheng MH. From theory to evidence: long-term evaluation of the mechanism of action and flap integration of distal vascularized lymph node transfers. *J Reconstr Microsurg.* 2015;31:26–30.
12. Scaglioni MF, Arvanitakis M, Chen YC, et al. Comprehensive review of vascularized lymph node transfers for lymphedema: outcomes and complications. *Microsurgery.* 2018;38:222–229.
13. Ciudad P, Manrique OJ, Date S, et al. A head-to-head comparison among donor site morbidity after vascularized lymph node transfer: pearls and pitfalls of a 6-year single center experience. *J Surg Oncol.* 2017;115:37–42.
14. Nguyen AT, Chang EI, Suami H, et al. An algorithmic approach to simultaneous vascularized lymph node transfer with microvascular breast reconstruction. *Ann Surg Oncol.* 2015;22:2919–2924.
15. Chang EI, Masià J, Smith ML. Combining autologous breast reconstruction and vascularized lymph node transfer. *Semin Plast Surg.* 2018;32:36–41.
16. Nguyen AT, Suami H, Hanasono MM, et al. Long-term outcomes of the minimally invasive free vascularized omental lymphatic flap for the treatment of lymphedema. *J Surg Oncol.* 2017;115:84–89.
17. Basta MN, Gao LL, Wu LC. Operative treatment of peripheral lymphedema: a systematic meta-analysis of the efficacy and safety of lymphovenous microsurgery and tissue transplantation. *Plast Reconstr Surg.* 2014;133:905–913.
18. Tourani SS, Taylor GI, Ashton MW. Long-term patency of lymphovenous anastomoses: a systematic review. *Plast Reconstr Surg.* 2016;138:492–498.
19. Winters H, Tielemans HJP, Verhulst AC, et al. The long-term patency of lymphaticovenular anastomosis in breast cancer-related lymphedema. *Ann Plast Surg.* 2019;82:196–200.