



Since January 2020 Elsevier has created a COVID-19 resource centre with free information in English and Mandarin on the novel coronavirus COVID-19. The COVID-19 resource centre is hosted on Elsevier Connect, the company's public news and information website.

Elsevier hereby grants permission to make all its COVID-19-related research that is available on the COVID-19 resource centre - including this research content - immediately available in PubMed Central and other publicly funded repositories, such as the WHO COVID database with rights for unrestricted research re-use and analyses in any form or by any means with acknowledgement of the original source. These permissions are granted for free by Elsevier for as long as the COVID-19 resource centre remains active.

● Session IV

EFFECTS OF INTRAVENOUSLY INFUSED FLUOSOL-DA 20% IN RATS

LAURIE WEST, B.A., NORMA MCINTOSH, PH.D., SIMONA GENDLER, M.D.,
CHRISTINE SEYMOUR, B.S. AND CHARLENE WISDOM, PH.D.

Alpha Therapeutic Corporation, 5555 Valley Boulevard, Los Angeles, CA 90032

Rats were injected with a fractionated 50 ml/kg dose of Fluosol®-DA 20% with and without exposure to 100% oxygen. Animals were killed at 24, 43, 92, and 183 days post-treatment and samples taken for hematological, hepatic enzyme, histological, and perfluorochemical analyses. There were no significant differences in hemograms or hepatic enzyme findings between treatment and control groups. Differences in organ weights and histology were a result of perfluorochemical (PFC) accumulation in the tissues of treated animals. All changes were reversible. There were no effects from breathing high oxygen levels in either treatment or control animals.

Perfluorochemical (PFC) emulsion, Fluosol®-DA 20%, Histology, Hematology, Perfluorochemical content, Hepatic enzymes, Rat.

INTRODUCTION

Oxygen has been recognized as a powerful radiosensitizing agent. In solid tumors, areas of vascular insufficiency and necrosis may cause some cells to be chronically hypoxic and, consequently, resistant to radiation. Chemical radiosensitizers have been used in attempts to enhance radiation effects on the hypoxic cell fraction with limited clinical success.^{1,2}

Teicher and Rose¹¹ and Rockwell¹⁰ have shown that administration of Fluosol-DA 20%*, an oxygen carrying perfluorochemical (PFC) emulsion, and oxygen (95% O₂/5% CO₂) to tumor-bearing mice prior to and during radiation significantly delayed tumor re-growth. However, a clinical treatment course may require multiple Fluosol infusions. This study was designed to assess the possible effects of multiple Fluosol doses on the reticuloendothelial system (RES) and compare the effects of multiple infusions with previous work using single bolus doses.

METHODS AND MATERIALS

Male Sprague-Dawley rats† (<150 gm) were divided into four groups (n=20 per group): control, room air (CRA); control, oxygen 100% O₂ (COX); Fluosol, room air (FRA); and Fluosol, oxygen 100% O₂ (FOX). Treatment animals received a total of 50 ml/kg (10gm PFC/kg body weight) of Fluosol in 10 ml/kg bolus doses via the tail vein on treatment days 1, 3, 8, 10, and 15. Control

animals were not injected. COX and FOX animals received 100% oxygen for three hours daily on the first 13 weekday treatment days. Animals (n=4) from each group were killed by exsanguination at 24, 43, 92 and 183 days post-treatment. Blood samples obtained at death were analyzed for SGOT, SGPT, alkaline phosphatase, hemoglobin, and red and white cell levels. Tissue samples were obtained from the lung, liver, and spleen, and histological analyses were performed using weighed samples fixed in formalin. PFC's were extracted from tissues (Yamanouchi, *et al.*¹⁴) and quantitated on a gas chromatograph‡ using known perfluorotripropylamine (FTPA) and perfluorodecalin (FDC) standards. Serum from randomly selected animals was screened for antibodies to murine pneumonia virus, corona virus, sendai virus, and mycoplasma.

RESULTS

Only slight differences were noted between treatment and control liver enzyme and hemogram values. Alkaline phosphatase levels were somewhat lower ($p < 0.05$) in the FOX group (154.5 ± 18.8 IU/L) (mean \pm Standard deviation), than in the COX group (200.6 ± 35.7 IU/L) at 43 days post-treatment and were similarly lower (102.4 ± 13.3 IU/L) than CRA (140.6 ± 28.5 IU/L), or COX (144.6 ± 16.0 IU/L) groups at 92 days post-treatment. A difference ($p < 0.05$) in SGOT levels between CRA (96.1 ± 22.3 IU/L) and FOX (62.0 ± 13.5 IU/L) groups was

Presented at the Chemical Modifiers of Cancer Treatment Conference, Clearwater, Florida, October 20-24, 1985.
Reprint requests to: Laurie West, B.A.
Accepted for publication 25 February 1986.

* Fluosol®-DA 20%, Green Cross Corporation, Osaka, Japan.
† Charles River Breeding Farms, Portage, ME.
‡ 5880A gas chromatograph, Hewlett Packard, Palo Alto, CA.

seen at 43 days post-treatment. There were no differences between treatment and control SGPT values.

White blood cell counts for FRA and FOX ($16.1\text{--}17.0 \times 10^3/\text{mm}^3$ at 43 days and $14.6\text{--}16.7 \times 10^3/\text{mm}^3$ at 92 days post-treatment) were slightly elevated ($p < 0.05$) over CRA and COX values ($11.1 \times 10^3/\text{mm}^3$ for controls at 43 days and $10.2\text{--}12.0 \times 10^3/\text{mm}^3$ at 92 days post-treatment). The reason for this elevation is unknown, but counts resolved with no observable effects on the animals. Serology results showed only low level mycoplasma titers in some animals from both treatment and control groups.

PFC analysis revealed marked FTPA and FDC accumulation in the spleen and liver of FRA and FOX animals at 24 days post-treatment (Table 1). PFC accumulation was most pronounced in the spleen, with 146.41 ± 30.79 mg/gm of FTPA and 152.40 ± 33.01 mg/gm of FDC recovered from FOX animals and similar PFC amounts recovered from FRA animals at 24 days post-treatment. Less than 1.5 mg/gm of total PFC's was recovered from lung tissues. The PFC content of tissues decreased over time, with FDC clearing more rapidly than FTPA in all organs. At the end of the study, measurable FDC (0.15 mg/gm) remained only in spleen. FTPA was recovered from both spleen ($61.63\text{--}94.76$ mg/gm) and liver ($4.55\text{--}4.75$ mg/gm) at 183 days post-treatment. However, both FDC and FTPA clearance was essentially complete from lung tissues by six months post-treatment.

Light microscopic examination revealed no tissue damage although, foamy macrophages, indicative of

Fluosol accumulation in the cell, were observed in the RES of the spleen and liver in Fluosol treated animals. In the spleen, there was marked accumulation of foamy macrophages throughout the red pulp at 24 days post-treatment (Fig. 1); accumulation was also observed in the lymphoid germinal follicles of some samples. These changes remained prominent at 43 days post-treatment, but by 183 days, there remained only mild to moderate focal accumulation of foamy macrophage in the red pulp and no accumulation in the germinal centers (Fig. 2). At 24 days post-treatment, the livers of animals in both treatment groups contained moderate numbers of large foamy Kupffer cells and enlarged foamy hepatocytes (Fig. 3) reflecting the accumulation of Fluosol in these cells. These cells decreased in number gradually until only scattered foamy cells were observed by 183 days post-treatment (Fig. 4). Scattered foamy macrophages were observed in the alveoli and interstitium of lung tissues from treatment animals at 24 days, but by 183 days post-treatment, only occasional foamy cells were observed. Control tissue samples were histologically normal, except for evidence of mycoplasmosis observed in the lungs of some control and treatment animals.

Whole body weights increased and relative organ weights decreased over time for all groups, reflecting the growth of the animals. There were no differences in whole body weights between FRA animals and control animals during the study. However, in the FOX group, weight gain was depressed ($p < 0.05$) both at 24 days (0.9 times

Table 1. Perfluorochemical content of tissues

Group*	24 days post-treatment	43 days post-treatment	92 days post-treatment	183 days post-treatment
Perfluorotripropylamine content (mg/gm)				
Liver				
FRA	26.03 ± 4.07	14.99 ± 3.60	13.72 ± 4.85	4.55 ± 2.24
FOX	24.68 ± 5.52	14.16 ± 5.35	11.36 ± 0.29	4.75 ± 1.64
Spleen				
FRA	119.66 ± 47.88	131.15 ± 38.23	133.20 ± 24.16	61.63 ± 35.65
FOX	146.41 ± 30.79	133.14 ± 18.78	158.91 ± 38.40	94.76 ± 33.11
Lung				
FRA	1.48 ± 1.12	0.48 ± 0.33	0.08 ± 0.16	0.06 ± 0.17
FOX	0.92 ± 0.41	0.57 ± 0.45	0.36 ± 0.27	0
Perfluorodecalin content (mg/gm)				
Liver				
FRA	15.88 ± 3.40	2.20 ± 0.72	0.18 ± 0.23	0
FOX	13.61 ± 3.09	1.95 ± 0.78	0.10 ± 0.11	0
Spleen				
FRA	119.71 ± 50.97	54.60 ± 20.23	7.95 ± 3.29	0.15 ± 0.32
FOX	152.40 ± 33.01	54.54 ± 21.02	7.94 ± 3.32	0.15 ± 0.23
Lung				
FRA	0.88 ± 0.69	0	0	0
FOX	0.47 ± 0.28	0.07 ± 0.09	0	0

* FRA = Fluosol, room air; FOX = Fluosol, oxygen.

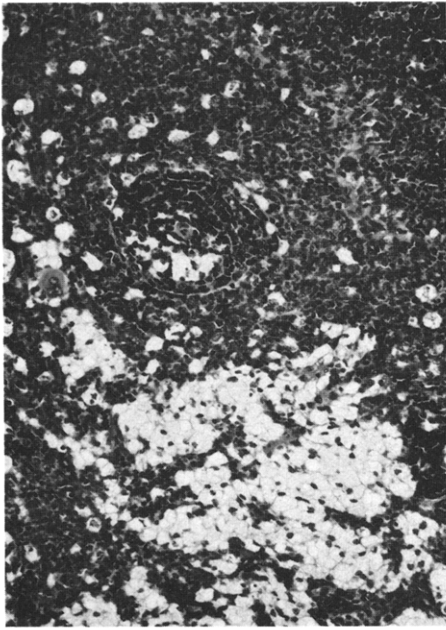


Fig. 1. Spleen of FOX animal at 24 days (H & E stains, 250×).

control) and 92 days (0.8 times control) post-treatment, but had returned to control levels by the termination of the study. The etiology of this weight change was not examined. As expected, both liver and spleen weights were initially elevated after Fluosol treatment (Table 2). Animals receiving Fluosol had relative liver weights about 1.6 and 1.7 times the relative weights of their corresponding controls at 24 days post-treatment ($p < 0.05$). In the spleen, increases of 2.0 and 2.1 times over control weights were observed for the FRA and FOX groups, respectively ($p < 0.05$). These differences resolved gradually over time

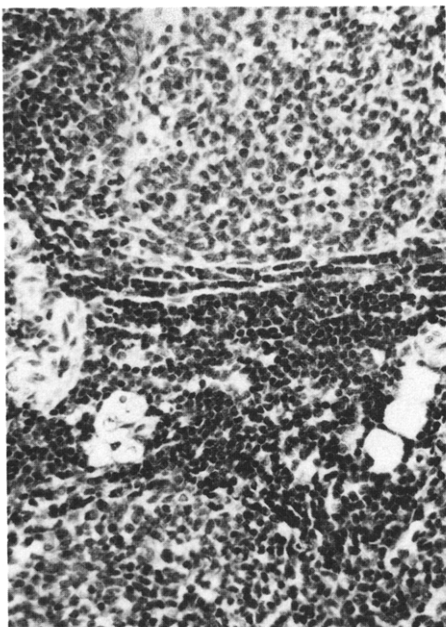


Fig. 2. Spleen of FOX animal at 183 days (H & E stains, 250×).

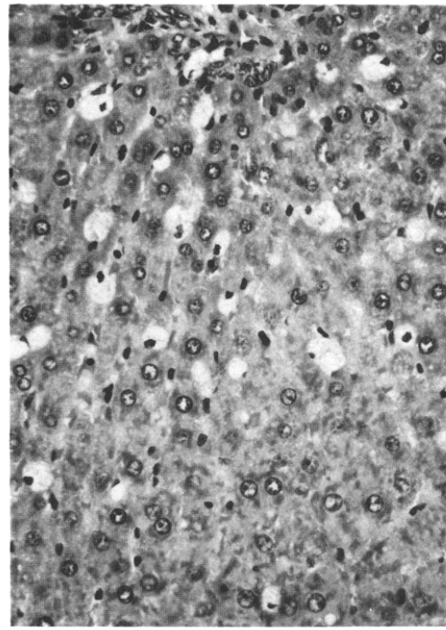


Fig. 3. Liver of FOX animal at 24 days (H & E stains, 250×).

and were almost completely normalized at 183 days post-treatment. There were no differences in organ weights, attributable to the inspiration of high oxygen, in either control or treatment groups. No differences in lung weights were observed between treatment and control groups.

DISCUSSION

Administration of Fluosol in multiple doses to a total of 50 ml/kg resulted in no markedly adverse effects in the animals tested. Both perfluorochemical and histological analyses confirmed that PFC's were taken up by the RES,

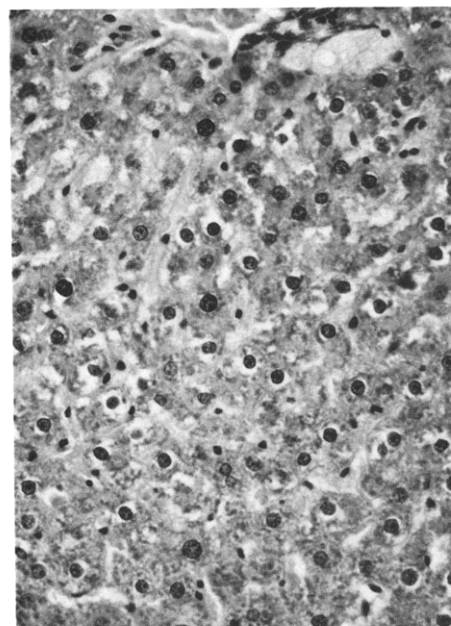


Fig. 4. Liver of FOX animal at 183 days (H & E stains, 250×).

Table 2. Relative organ weights (% of whole body weight)*

Group†	24 days post-treatment	43 days post-treatment	92 days post-treatment	183 days post-treatment
Liver				
CRA	4.46 ± 0.36	4.36 ± 0.34	3.68 ± 0.40	3.45 ± 0.40
COX	4.58 ± 0.33	3.86 ± 0.08	3.78 ± 0.21	3.67 ± 0.30
FRA	6.99 ± 0.71‡	5.93 ± 0.54‡	4.62 ± 0.55‡	3.69 ± 0.48
FOX	6.70 ± 1.04‡§	6.34 ± 0.71‡§	4.62 ± 0.29‡§	3.63 ± 0.18
Spleen				
CRA	0.21 ± 0.02	0.15 ± 0.02	0.14 ± 0.01	0.13 ± 0.01
COX	0.21 ± 0.01	0.17 ± 0.02	0.15 ± 0.01	0.13 ± 0.01
FRA	0.41 ± 0.06‡	0.42 ± 0.07‡	0.24 ± 0.03‡	0.31 ± 0.2‡
FOX	0.44 ± 0.08‡§	0.39 ± 0.10‡§	0.24 ± 0.04‡§	0.17 ± 0.03
Lung				
CRA	0.54 ± 0.26	0.55 ± 0.08	0.35 ± 0.03	0.34 ± 0.06
COX	0.54 ± 0.01	0.43 ± 0.01	0.39 ± 0.07	0.33 ± 0.04
FRA	0.62 ± 0.14	0.55 ± 0.27	0.41 ± 0.11	0.33 ± 0.06
FOX	0.51 ± 0.08	0.42 ± 0.06	0.39 ± 0.01	0.36 ± 0.10

* FRA animals compared to CRA animals only. FOX animals compared to both CRA and COX animals.

† CRA = control, room air; COX = control, oxygen; FRA = Fluosol, room air; FOX = Fluosol, oxygen.

‡ $p < 0.05$ compared to room air control.

§ $p < 0.05$ compared to oxygen breathing control.

as previously reported.^{5,6} Histological examination confirmed the accumulation of the PFC-containing foamy macrophages without other structural or inflammatory changes. Previous light and electron microscopic studies in rats,^{5,9} rabbits,⁶ dogs,⁵ and monkeys⁵ injected with perfluorochemical emulsions have also documented PFC-containing macrophages in the RES without damage to tissue architecture. The PFC content of liver and spleen decreased over time and organ weights normalized; correspondingly fewer macrophages were observed as this clearance took place. In this study, the clearance of PFC's from organs is similar to that reported by Lutz,² using a single 10 gm/kg PFC dose. However, the rate of clearance appears more prolonged here than in studies using an exchange transfusion model.⁵ The more rapid clearance of FDC from all organs, observed here and in previous studies,⁵ reflects the difference in elimination rate constants for the two PFCs.⁵ Only slight PFC accumulation was noted in the lung and the small numbers of foamy macrophages observed there also decreased over time. PFC's are eliminated from the body primarily by expiration through the lungs.⁷ In this study, although, some PFC was detected in the lungs, no structural damage due to PFC transport was observed.

Hemograms, serology, and hepatic enzyme values were not affected by Fluosol administration. The few differences observed in hepatic enzymes were attributable to random variation in individual animals, indicating that no liver dysfunction resulted from Fluosol infusion. Transient alterations in SGOT, SGPT, alkaline phosphatase, and WBC counts have been observed^{3,4} in both pre-clinical and clinical studies, but were not attributed to a pathological response. Metzner and Lutz³ reported transient elevations in hepatic enzymes after administration of

Fluosol at 14 gm PFC/kg. However, the rapid return of these enzymes to control levels suggested that there was no organ damage or marked dysfunction.

A depression in whole body weight gain was observed in the FOX group as compared to the CRA and COX groups at 24 and 92 days post-treatment. The data obtained in this study do not suggest an explanation for this difference; however, we surmise that extra handling of the animals in the FOX group during the study contributed to this depression in weight gain. Goodman *et al.*¹ reported a five-fold increase in spleen weight and a two-fold increase in liver weight, following multiple infusions of Fluosol to 10 gm PFC/kg total dose. Our data show 1.6–1.7 and 2.0–2.1 fold increases in liver and spleen weights, respectively. The reason for this difference in observed spleen weights is not known; however, other studies have also failed to show comparable splenic enlargement at similar Fluosol doses.^{2,13}

Increases in spleen and liver weights observed in treated animals reflect PFC storage in these organs. In agreement with previous work,^{2,13} the total weight gain in liver and spleen observed in this study exceeds the amount of PFC's retained in these organs. This gain has been attributed to either hyperplasia² or hypertrophy; the data reported here do not permit elucidation of the mechanism of weight gain in these organs. In another study, no changes in fibroid tissue were observed in the liver or lung within one year following multiple doses of Fluosol to a total of 22 gm PFC/kg of body weight.⁸

The results reported in this study indicate that Fluosol has no marked detrimental effects at this dosage level and suggest that effects following multiple injections to 10 gm PFC/kg (50 ml/kg) are similar to results obtained for bolus injections of Fluosol to 50 ml/kg.

REFERENCES

1. Goodman, R., Moore, R., Davis, M., Stokes, D., Yuhas, J.: Perfluorochemical emulsions in cancer therapy: preliminary observations on presently available formulations. *Int. J. Radiat. Oncol. Biol. Phys.* **10**: 1421–1424, 1984.
2. Lutz, J., Metzner, P., Kunz, E., Heine, W.-D.: Cellular Responses after use of perfluorochemical blood substitutes. In *Oxygen Carrying Colloidal Blood Substitutes*, R. Frey, H. Beisbarth, K. Stasseck (Eds.). Munich, W. Zuckscherdt Verlag. 1982, pp. 73–81.
3. Metzner, P., Lutz, J.: Changes in enzyme activities after treatment with perfluorochemicals. In *Oxygen Carrying Colloidal Blood Substitutes*, R. Frey, H. Beisbarth, K. Stasseck (Eds.). Munich, W. Zuckscherdt Verlag. 1982, pp. 82–85.
4. Mitsuno, T., Ohyanagi, H., Naito, R.: Clinical studies of a perfluorochemical whole blood substitute (Fluosol-DA); Summary of 186 cases. *Ann. Surg.* **195**: 60–69, 1982.
5. Naito, R., Yokoyama, K.: *Perfluorochemical Blood Substitutes, FC-43 Emulsion, Fluosol®-DA, 20% and 35%*, Technical Information Series Number 5, Osaka, Japan, The Green Cross Corporation, 1981.
6. Nanney, L., Fink, L.M., Virmani, R.: Morphologic changes in infused liver, spleen, lung, and kidney of rabbits. *Arch. Pathol. Lab. Med.* **108**: 631–637, 1984.
7. Ohyanagi, H., Mitsuno, T.: Biophysiological effects of perfluorochemicals as artificial blood. *Proceedings of the Xth International Congress for Nutrition: Symposium on Perfluorochemical Artificial Blood*, Kyoto. Osaka, Japan, Igakushobo Med. Pub. 1975, 21–54.
8. Pfannkuch, F., Schnoy, N.: Long-term observations of PFC storage in organs of rats after various dosages. In *Advances in Blood Substitute Research*, Geyer and Bolin (Eds.). NY, Alan R. Liss, Inc. 1983, pp. 209–219.
9. Pfannkuch, F., Schnoy, N., Ohlschlegel, C., Wilson, C.: Comparative morphological studies in animal experiments after parenteral use of Fluosol®-43, -DA 20%, and -DA 35%. In *Oxygen Carrying Colloidal Blood Substitutes*, R. Frey, H. Beisbarth, K. Stasseck (Eds.). Munich, W. Zuckscherdt Verlag. 1982, pp. 61–67.
10. Rockwell, S.: Use of a perfluorochemical emulsion to improve oxygenation in solid tumor. *Int. J. Radiat. Oncol. Biol. Phys.* **11**: 97–103, 1985.
11. Teicher, B.A., Rose, C.M.: Perfluorochemical emulsions can increase tumor radiosensitivity. *Science* **223**: 934–936, 1984.
12. Wasserman, T.H., Coleman, C.N., Urtasun, R., Phillips, T.L., Strong, J.: Final report: Phase I trial of Desmethylmisonidazole (DMN)—An hypoxic cell sensitizer. *Int. J. Radiat. Oncol. Biol. Phys.* **8** (Suppl I): 76, 1982.
13. Wisdom, C., Teicher, B.A., Howard, E., McIntosh, N.L.: Multiple dose effects of Fluosol®-DA 20% I.V. infusion in rodents. *Radiation Research Society 33rd Meeting*, May 5, 1985, Los Angeles, California.
14. Yamanouchi, K., Murashima, R., Yokoyama, K.: Determination of perfluorochemicals in organs and body fluids by gas chromatography. *Chem. Pharm. Bull.* **23**: 1363–1367, 1975.