

This article is licensed under a Creative Commons Attribution-NonCommercial NoDerivatives 4.0 International License.

Apatinib Monotherapy or Combination Therapy for Non-Small Cell Lung Cancer Patients With Brain Metastases

Jianping Xu, Xiaoyan Liu, Sheng Yang, and Yuankai Shi

Department of Medical Oncology, Cancer Hospital, Chinese Academy of Medical Sciences and Peking Union Medical College, Beijing, P.R. China

Apatinib, an oral small molecular receptor tyrosine kinase inhibitor (TKI) developed first in China, exerts anti-angiogenic and antineoplastic function through selectively binding and inhibiting vascular endothelial growth factor receptor 2 (VEGFR-2). In this study, we aimed to explore the efficacy and safety profile of apatinib monotherapy, or combined with chemotherapy or endothelial growth factor receptor (EGFR)-TKI in heavily pretreated non-small cell lung cancer (NSCLC) patients with brain metastases. We performed a retrospective analysis for relapsed NSCLC patients with brain metastases from our institute, who received apatinib (250 mg or 500 mg p.o. qd) monotherapy, or combination with EGFR-TKI or chemotherapy as second or more line systemic therapy until disease progression or unacceptable toxicity occurred. The objective response rate (ORR), disease control rate (DCR), median progression-free survival (mPFS), median overall survival (mOS), and safety were analyzed. A total of 26 eligible patients were included: 24 patients diagnosed with adenocarcinoma, 2 with squamous carcinoma, and 14 patients harboring EGFR sensitizing mutations. The mPFS and mOS were 4.93 (range, 0.27–32.91; 95% CI 3.64–6.22) and 14.70 (range, 0.27–32.91; 95% CI 0.27–43.60) months for the whole group. The ORR and DCR were 7.7% (2/26) and 69.2% (18/26) for the entire lesions, and 7.7% (2/26) and 79.6% (20/26) for brain metastases, respectively. Compared with patients who received apatinib monotherapy, patients who received apatinib combination treatment had more favorable mPFS (11.77 vs. 2.27 months, $p < 0.05$) and mOS (24.03 vs. 6.07 months, $p < 0.05$). Treatment-related toxicities were tolerable including grade 1/2 hypertension, hand-and-foot syndrome, fatigue, nausea, liver dysfunction, myelosuppression, skin rash, and palpitation. In conclusion, apatinib exhibited high activity and good tolerance for NSCLC patients with brain metastasis, and it might become a potential choice for metastatic brain tumors in NSCLC patients.

Key words: Apatinib; Non-small cell lung cancer (NSCLC); Brain metastases; VEGFR-2

INTRODUCTION

Lung cancer has been the most common malignancy worldwide especially in China with the highest incidence and mortality^{1,2}. Non-small cell lung cancer (NSCLC) accounts for approximately 85% of all lung cancer cases^{1,2}. NSCLC has poor prognosis with a low 5-year survival rate, especially at the advanced stage of the disease, due to relapse, resistance, and metastasis^{1,2}. More than 10% of NSCLC patients present with brain metastasis at their initial diagnosis, and 30% to 40% of NSCLC patients develop brain metastasis during the treatment course of the disease^{3,4}. Although local treatments such as surgical resection, stereotactic radiosurgery (SRS), or whole brain radiotherapy can prolong the overall survival (OS) of NSCLC patients with brain metastases⁵, there are

still some limitations including limiting further systemic chemotherapy.

With the advent of precision targeted therapy and immune checkpoint inhibitors, the prognosis of advanced NSCLC patients has improved greatly^{6,7}. VEGF/VEGFR signal transduction has been recognized as a prominent pathway responsible for pathological angiogenesis⁸. Previous studies have demonstrated that bevacizumab combined with chemotherapy significantly improved the prognosis and inhibited the brain metastasis development in NSCLC patients, and EGFR TKI therapy was also effective for NSCLC patients with brain metastases⁹⁻¹¹. Apatinib, a novel receptor tyrosine kinase inhibitor selectively targeting the intracellular ATP-binding site of VEGFR-2, exhibited high antivascular

Address correspondence to Yuankai Shi, Department of Medical Oncology, Cancer Hospital, Chinese Academy of Medical Sciences and Peking Union Medical College; Beijing Key Laboratory of Clinical Study on Anticancer Molecular Targeted Drugs, No.17 Panjiayuan Nanli, Chaoyang District Beijing 100021, P.R. China. Tel: +86 10 87788293; Fax: +86 10 87778740; E-mail: syuankai@picam.ac.cn or syuankaipumc@126.com

and anticancer activities both in preclinical and clinical settings¹². Previous studies have reported that apatinib was efficacious in treating relapsed or drug-resistant NSCLC and also in NSCLC patients with brain metastasis^{13–16}.

In this retrospective study, we aimed to explore the efficacy and safety profile of apatinib monotherapy, or combined with chemotherapy or EGFR-TKI for treatment of brain metastases in patients with advanced drug-resistant NSCLC.

MATERIAL AND METHODS

Patients

Eligible patients who were diagnosed with NSCLC with brain metastases at our institute and received apatinib monodrug or combination treatment as second or more lines of systemic therapies were included in this study. The clinical variables were collected including gender, age, Eastern Cooperative Oncology Group (ECOG) performance status (PS), initial dosage, treatment regimens, response, survival date, etc. This study was approved by the ethics committee of the Cancer Institute and Hospital, Chinese Academy of Medical Sciences, and conducted in accordance with the Declaration of Helsinki. All patients who received treatment of apatinib combined with TKI or chemotherapy signed an informed consent.

Efficacy and Safety Assessments

Treatment responses were assessed according to the Response Evaluation Criteria in Solid Tumors (RECIST1.1). The objective response rate (ORR) was calculated as complete response (CR)+partial response (PR). The disease control rate (DCR) was calculated as CR+PR+stable disease (SD). Progression-free survival (PFS) was defined as the time from treatment initiation until the first sign of disease progression or death from any cause. OS was defined as the duration from the first day of the treatment to the date of death as a result of any cause. Patients who were alive at the time of this analysis were censored at the date last known to be alive. Toxicities were evaluated according to the National Cancer Institute–Common Toxicity Criteria for Adverse Events version 4.0.

Statistical Analyses

The Kaplan–Meier method was used to estimate the impact of the duration of apatinib administration upon survival, followed by the log-rank test to determine the statistical significance. The research goal mentioned above was achieved by analyses with SPSS 19.0 (IBM, Armonk, NY, USA).

RESULTS

Patients

A total of 26 patients were enrolled between October 2015 and April 2019. Patients' characteristics are summarized in Table 1. The median age was 56 years (range: 43–70), and the ratio of males to females was 12:14. An extremely high prevalence of adenocarcinoma (24/26, 92.4%) was observed. Among the 26 eligible patients, 14 cases were harboring EGFR-sensitizing mutations (including 6 patients with exon 19 deletions, 7 patients with exon 21 mutations, and 1 patient with simultaneous exon 21 mutations and exon 20 T790M mutations), 7 patients were EGFR-wild types, and the remaining 5 patients did not receive molecular test (3 adenocarcinoma and 2 squamous carcinoma). All patients were relapsed NSCLC among which 14 cases had failed two lines and 12 patients had failed three or more lines of prior systemic treatment.

Treatments

All patients received apatinib, and the initial dosage were 250 mg qd in 16 patients and 500 mg qd in

Table 1. Patient Characteristics

Characteristics	N (%)
Gender	
Male	12 (46.2%)
Female	14 (53.8%)
Age	
Median (range)	56 (43–70)
ECOG score	
0	3 (11.5%)
1	7 (26.9%)
2	14 (53.8%)
3	2 (7.7%)
Pathological type	
Adenocarcinoma	24 (92.3%)
Squamous carcinoma	2 (7.7%)
Gene mutation	
EGFR-sensitizing mutation	14 (53.8%)
Wild type	7 (26.9%)
Unknown	5 (19.2%)
Extracranial metastases	
Positive	6 (23.1%)
Negative	16 (61.5%)
Prior systemic treatment	
2	8 (30.7%)
≥3	18 (69.2%)
Brain radiation	
Yes	16 (61.5%)
No	10 (38.5%)
Apatinib treatment	
Monodrug	12 (46.2%)
Combined with EGFR-TKI	10 (38.5%)
Combined with chemotherapy	4 (15.3%)

Table 2. Treatment Response ($N=26$)

Response	The Entire Lesions [N (%)]	Brain Metastases [N (%)]
Complete response	0	0
Partial response	2 (7.7%)	2 (7.7%)
Stable disease	16 (61.5%)	18 (69.2%)
Progressive disease	8 (30.8%)	6 (23.1%)
Objective response rate	2 (7.7%)	2 (7.7%)
Disease control rate	18 (69.2%)	20 (76.9%)

10 patients. Twelve patients received apatinib monotherapy, and 14 patients received apatinib combination treatment including EGFR-TKI ($n=10$) and chemotherapy ($n=4$). Sixteen (61.5%) patients received brain radiation while receiving apatinib therapy.

Efficacy

Until the last follow-up in April 2019, 11 patients died, and 15 patients were still alive. The ORR and DCR were 7.7% (2/26) and 69.2% (18/26) for the entire lesions, and 7.7% (2/26) and 79.6% (20/26) for brain metastases, respectively (Table 2). The mPFS and mOS were 4.93 (95% CI 3.64–6.22) and 14.70 (95% CI 0.27–43.60) months for all patients (Fig. 1).

Compared with mono-apatinib, apatinib combination treatment with EGFR-TKI or chemotherapy had higher ORR (14.3% vs. 0, $p<0.05$) and DCR (92.9% vs. 23.1%, $p<0.05$). Patients who received apatinib combination treatment also had longer mPFS (11.77 vs. 2.27 months, $p<0.05$) and mOS (24.03 vs. 6.07 months, $p<0.05$) (Fig. 2).

Among the 14 patients harboring EGFR-sensitizing mutations, 4 received mono-apatinib and 10 patients

received apatinib combined with EGFR-TKI. For patients receiving monotherapy, the ORR and DCR were 0% and 25%, respectively. For patients receiving combination therapy, the ORR and DCR were 25% and 100%, respectively. For the 10 patients who received combination treatment, no statistical significance was found between cases with EGFR exon 19 deletion mutations and cases with EGFR exon 21 mutations with regard to both survival (mPFS, 27.90 vs. 11.77 months, $p=0.097$; mOS, not reached) and treatment response (ORR, 25% vs. 25%; DCR, 100% vs. 100%).

For the 14 patients who had failed two lines of systemic therapies, the ORR and DCR were 16.7% and 75%, respectively. For the 12 patients who had failed ≥ 3 lines of treatment, the ORR and DCR were 0% and 61.5%, respectively.

In addition, we established multivariate model containing variables (age, sex, ECOG score, gene mutation, and apatinib treatment) (Table 3). In multivariate analysis, only the mode of apatinib treatment (combination or monotherapy) was associated with a significantly longer PFS [hazard ratio (HR)=7.446; 95% CI=2.11–9.65;

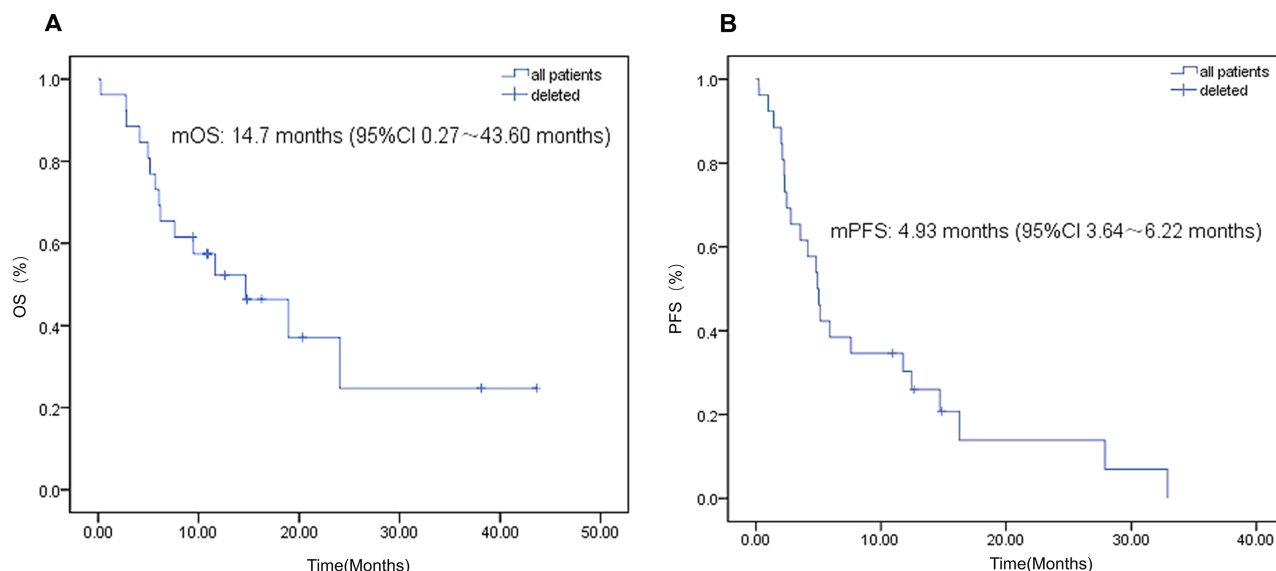


Figure 1. Kaplan–Meier overall survival (OS) and progression-free survival (PFS) curves. (A) OS. (B) PFS.

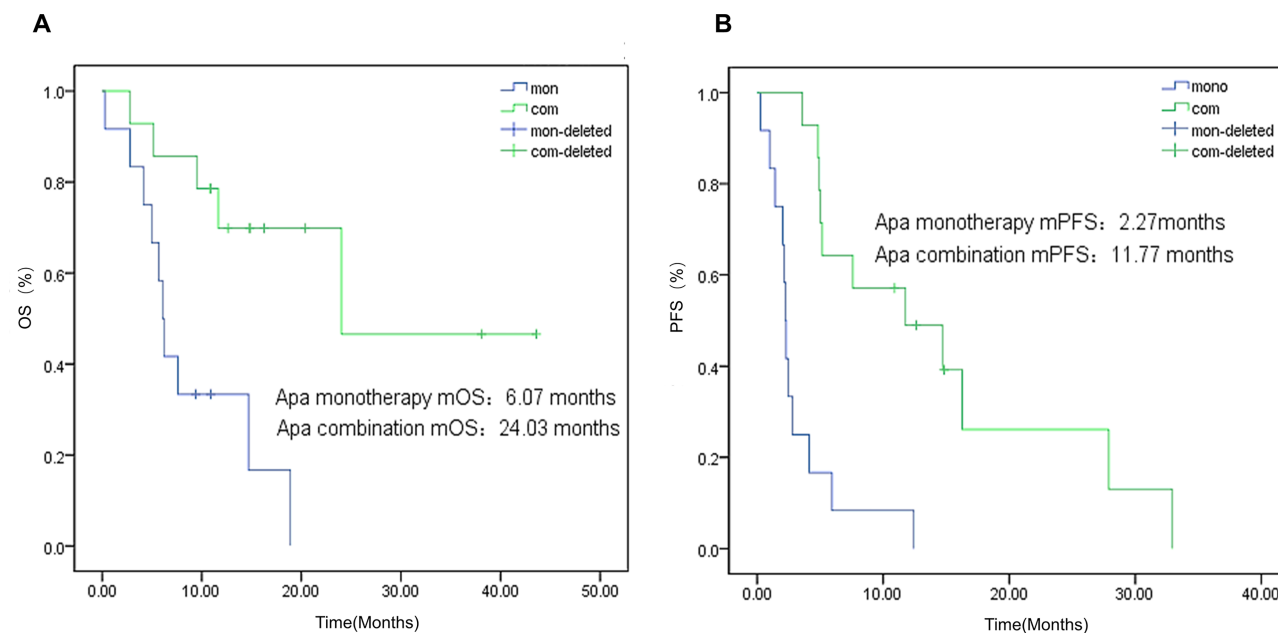


Figure 2. Kaplan–Meier overall survival (OS) and progression-free survival (PFS) curves between apatinib monotherapy and combination. (A) OS. (B) PFS.

$p=0.001$] and longer OS [hazard ratio (HR)=8.571; 95% CI=5.83–9.22; $p=0.006$].

Adverse Events

Treatment-related AEs are summarized in Table 4. The most common AEs were grade 1/2 hypertension (14/26, 53.8%), hand-and-foot syndrome (12/26, 46.2%), fatigue (12/26, 46.2%) and nausea (9/26, 34.6%), followed by nausea (9/26, 34.6%), liver dysfunction (7/26, 26.9%), myelosuppression (3/26, 11.5%), skin rash (5/26, 19.2%), and palpitation (2/26, 7.7%). All these AEs were manageable, and no grade 3/4 AEs were observed.

DISCUSSION

In this retrospective study, we observed a high DCR of 79.6%, mPFS of 4.93 months, and mOS of 14.70 months in NSCLC patients with brain metastases. Especially when treated with apatinib combined with EGFR-KTI or

chemotherapy, a DCR of 92.9%, mPFS of 11.7 months and mOS of 24.03 months were achieved, indicating the promising efficacy of apatinib combination therapy for NSCLC patients with brain metastases.

Apatinib is a novel receptor tyrosine kinase inhibitor selectively targeting the intracellular ATP-binding site of VEGFR-2 and exhibiting highly antivasculature and anticancer activities¹². Several trials have confirmed that apatinib was efficacious in treating relapsed or drug-resistant NSCLC after multiple lines of treatments^{13–15}. In addition, our previous study had reported that four NSCLC patients with brain metastasis achieved stable disease after receiving apatinib therapy¹⁶.

Blockade of VEGF has been demonstrated in pre-clinical settings to promote vascular normalization and inhibit angiogenesis in treating brain metastases^{9,11,17}. In those studies, brain metastases were sensitive to apatinib monodrug or combination with chemotherapy or

Table 3. Multivariate Cox Proportional Hazard Models of Prognostic Parameters for Progression-Free Survival and Overall Survival

Variable	Progression-Free Survival		Overall Survival	
	<i>p</i> Value	HR (95% CI)	<i>p</i> Value	HR (95% CI)
Gender	0.533	1.269 (0.32–1.88)	0.958	0.984 (0.24–2.23)
Mutation type	0.705	0.835 (0.11–2.14)	0.825	0.914 (0.03–1.19)
Treatment (mono or combined)	0.006	8.571 (5.83–9.22)	0.001	7.446 (2.11–9.65)
ECOG	0.413	0.766 (0.59–0.99)	0.985	0.995 (0.46–1.62)
Treatment lines	0.651	1.357 (0.87–2.12)	0.596	1.357 (0.88–3.27)
Age	0.176	1.056 (0.91–1.88)	0.146	1.053 (0.45–3.11)

Table 4. Treatment-Related Adverse Events

Adverse Event	N (%)
Hypertension	14 (53.8%)
Hand-and-foot syndrome	12 (46.2%)
Fatigue	12 (46.2%)
Nausea	9 (34.6%)
Liver dysfunction	7 (26.9%)
Skin rash	5 (19.2%)
Myelosuppression	3 (11.5%)
Palpitation	2 (7.7%)

EGFR-TKI. At present, only a few clinical studies have specifically focused on anti-VEGF therapy in lung cancer with brain metastases. For example, in the phase II BRAIN study, first-line bevacizumab combined with carboplatin and paclitaxel yielded an ORR of 61.2% in intracranial lesions, a mPFS of 6.7 months, and mOS of 16 months, and second-line bevacizumab combined with erlotinib achieved ORR of 12.5% in intracranial lesions, a mPFS of 6.3 months, and mOS of 12 months in NSCLC with brain metastases⁹. In another trial, PFS was 9.1 months and mOS was 9.6 months for patients with NSCLC with brain metastasis who received first-line bevacizumab combined with cisplatin and gemcitabine¹⁸. In addition, small molecular VEGFR-TKIs including sorafenib and sunitinib showed efficacy in treating brain metastases in patients with renal cancer^{19,20}. In our study, in patients relapsed after two or more line treatments, apatinib combination therapy achieved better outcomes with ORR of 14.3%, DCR of 92.9%, mPFS of 11.7 months, and mOS of 24.03 months in intracranial lesions in NSCLC patients.

In a previous study, in heavily pretreated patients with advanced nonsquamous NSCLC, docetaxel showed mOS of 9.4 months and mPFS of 4.2 months²¹. In addition, data from randomized trials in patients with advanced NSCLC and pretreated central nervous system metastases showed mOS of 3.86–7.33 months with docetaxel therapy²². In phase III OAK study, in patients with and without a history of asymptomatic, treated brain metastases, there was mOS of 9.3 and 11.9 months in the docetaxel arm, respectively²³. In contrast to our finding, the mOS of apatinib monotherapy was 6.07 months, which was lower than the use of docetaxel as a historical control; however, the mOS of the patients receiving apatinib combination therapy was 24.03 months, which was better when compared with docetaxel as a historical control. This outcome showed that apatinib combination with EGFR-TKI or chemotherapy might be used for NSCLC patients with brain metastasis. In addition, multivariate analysis showed that only the mode of apatinib treatment (combination or monotherapy) was associated with a significantly longer mPFS and

mOS, which indicated that the mode of apatinib treatment was an independent factor associated with the mPFS and mOS of patient when other variables were considered. Intriguingly, we observed that EGFR mutation was not an independent factor in our multivariate analysis, though 50% of patients were EGFR mutant and that over 30% utilized EGFR TKI combination. Certainly, these results should be verified in a large prospective clinical trial.

IMpower150 study showed that the addition of atezolizumab to bevacizumab plus chemotherapy as first-line treatment for nonsquamous metastatic NSCLC significantly improved the PFS and OS, regardless of EGFR genetic alteration status²⁴. In our study, we observed that apatinib in combination with EGFR-TKI for EGFR-mutant NSCLC achieved an ORR of 25% and DCR of 100%, which was higher than that of monotherapy. In addition, a phase IB clinical trial showed that camrelizumab (a clinically available anti-PD-1 monoclonal antibody) plus low-dose apatinib achieved a promising ORR of 55.6% (5/9) in patients with pretreated NSCLC²⁵. Camrelizumab combined with apatinib had also showed promising antitumor activity in hepatocellular carcinoma^{26,27}. Therefore, it is very necessary to investigate whether apatinib combination with PD-1 inhibitor such as camrelizumab can indeed induce promising antitumor activity in EGFR-mutant NSCLC in our future study.

There is a growing body of evidence that the microenvironment in which tumors grow affects their biology, as well as the efficacy of therapeutic agent²⁸. However, the host microenvironment differs between primary and metastatic sites. In an animal model with breast cancer, cranial metastases showed more angiogenesis and exhibited higher vascular permeability than the primary tumor²⁸. This may explain our result that two patients in the study had brain metastases shrinking but primary lung lesions growing. The contradictory responses between primary and metastatic tumors have also been reported in breast cancer^{29,30}.

Preclinical studies have demonstrated that apatinib may be vital in reversing the drug resistance of EGFR-TKI¹⁴. Reinmuth and his colleagues reported that EGFR gene mutations may be linked to increased VEGF expression in comparison with EGFR wild type³¹. Further studies revealed that activation of the EGFR pathway increases the production of tumor-derived VEGF by activating downstream ERK and PI3K signal pathways³². In addition, Naumov et al. reported that acquired resistance to EGFR-TKIs was associated with a significant increase in VEGFR expression³³. Recent JO25567 and NEJ026 studies showed that the addition of anti-VEGF therapy to first-line EGFR-TKI improved ORR and PFS for patients with EGFR-sensitizing mutations^{34,35}. Noteworthy, in our study, second-line apatinib combined with EGFR-TKI yielded an ORR and DCR of 25% and 100% for NSCLC

patients harboring EGFR sensitizing mutations who failed first-line EGFR-TKI, suggesting that apatinib may reverse the drug resistance of EGFR-TKI.

In this study, apatinib was well tolerated in all patients, and no grade 3/4 AEs were observed. Cerebral hemorrhage is one of the most common side effects in patients who receive antivasular therapies^{36,37}. However, no cerebral hemorrhage and no other severe AEs were documented in all enrolled patients. Besides, prior studies of bevacizumab showed that antivasular therapies lead to hemorrhage events in squamous lung cancer, especially in hollow lesions adjacent to blood vessels¹⁰. In this study, no hemorrhage event occurred in two patients with squamous lung cancer who received apatinib treatment.

Our study was limited by its retrospective nature and small sample size. Patients in the study were heavily pretreated and lacked effective predictors for response. Prospective phase 3 clinical trials would be needed to confirm the clinical efficacy of apatinib treatment, especially combination therapy in NSCLC patients with brain metastases.

ACKNOWLEDGMENTS: We would like to thank all of the patients for their willingness to be part of this clinical study. We would also like to thank Cunnan Dong and Guoliang Chen for the writing and revision. The authors declare no conflicts of interest.

REFERENCES

- Chen W, Zheng R, Baade PD, Zhang S, Zeng H, Bray F, Jemal A, Yu XQ, He J. Cancer statistics in China, 2015. *CA Cancer J Clin*. 2016;66(2):115–32.
- Siegel RL, Miller KD, Jemal A. Cancer statistics, 2019. *CA Cancer J Clin*. 2019;69(1):7–34.
- Nussbaum ES, Djalilian HR, Cho KH, Hall WA. Brain metastases. Histology, multiplicity, surgery, and survival. *Cancer* 1996;78(8):1781–8.
- Zimm S, Wampler GL, Stablein D, Hazra T, Young HF. Intracerebral metastases in solid-tumor patients: Natural history and results of treatment. *Cancer* 1981;48(2):384–94.
- Won YK, Lee JY, Kang YN, Jang JS, Kang JH, Jung SL, Sung SY, Jo IY, Park HH, Lee DS, Chang JH, Lee YH, Kim YS. Stereotactic radiosurgery for brain metastasis in non-small cell lung cancer. *Radiat Oncol J*. 2015;33(3):207–16.
- Vargas AJ, Harris CC. Biomarker development in the precision medicine era: Lung cancer as a case study. *Nat Rev Cancer* 2016;16(8):525–37.
- Reck M, Heigener D, Reinmuth N. Immunotherapy for small-cell lung cancer: Emerging evidence. *Future Oncol*. 2016;12(7):931–43.
- McMahon G. VEGF receptor signaling in tumor angiogenesis. *Oncologist* 2000;5(Suppl 1):3–10.
- Besse B, Le Moulec S, Mazieres J, Senellart H, Barlesi F, Chouaid C, Dansin E, Berard H, Falchero L, Gervais R, Robinet G, Ruppert AM, Schott R, Lena H, Clement-Duchene C, Quantin X, Souquet PJ, Tredaniel J, Moro-Sibilot D, Perol M, Madroszyk AC, Soria JC. Bevacizumab in patients with nonsquamous non-small cell lung cancer and asymptomatic, untreated brain metastases (BRAIN): A nonrandomized, phase II study. *Clin Cancer Res*. 2015; 21(8):1896–903.
- Greillier L, Tomasini P, Barlesi F. Bevacizumab in the treatment of nonsquamous non-small cell lung cancer: Clinical trial evidence and experience. *Ther Adv Respir Dis*. 2016; 10(5):485–91.
- Ilhan-Mutlu A, Osswald M, Liao Y, Gommel M, Reck M, Miles D, Mariani P, Gianni L, Lutiger B, Nendel V, Srock S, Perez-Moreno P, Thorsen F, von Baumgarten L, Preusser M, Wick W, Winkler F. Bevacizumab prevents brain metastases formation in lung adenocarcinoma. *Mol Cancer Ther*. 2016;15(4):702–10.
- Li J, Qin S, Xu J, Xiong J, Wu C, Bai Y, Liu W, Tong J, Liu Y, Xu R, Wang Z, Wang Q, Ouyang X, Yang Y, Ba Y, Liang J, Lin X, Luo D, Zheng R, Wang X, Sun G, Wang L, Zheng L, Guo H, Wu J, Xu N, Yang J, Zhang H, Cheng Y, Wang N, Chen L, Fan Z, Sun P, Yu H. Randomized, double-blind, placebo-controlled phase III trial of apatinib in patients with chemotherapy-refractory advanced or metastatic adenocarcinoma of the stomach or gastroesophageal junction. *J Clin Oncol*. 2016;34(13):1448–54.
- Ding L, Li QJ, You KY, Jiang ZM, Yao HR. The use of apatinib in treating non-small-cell lung cancer: Case report and review of literature. *Medicine (Baltimore)* 2016;95(20): e3598.
- Li F, Zhu T, Cao B, Wang J, Liang L. Apatinib enhances antitumour activity of EGFR-TKIs in non-small cell lung cancer with EGFR-TKI resistance. *Eur J Cancer* 2017;84:184–92.
- Wu F, Zhang S, Xiong A, Gao G, Li W, Cai W, Su C, Chen X, Zhou F, Zhao J, Ren S, Zhou C. A phase II clinical trial of apatinib in pretreated advanced non-squamous non-small-cell lung cancer. *Clin Lung Cancer* 2018;19(6): e831–42.
- Xu J, Liu X, Yang S, Zhang X, Shi Y. Clinical response to apatinib monotherapy in advanced non-small cell lung cancer. *Asia Pac J Clin Oncol*. 2018;14(3):264–9.
- Pishko GL, Muldoon LL, Pagel MA, Schwartz DL, Neuwelt EA. Vascular endothelial growth factor blockade alters magnetic resonance imaging biomarkers of vascular function and decreases barrier permeability in a rat model of lung cancer brain metastasis. *Fluids Barriers CNS* 2015;12:5.
- Zustovich F, Ferro A, Lombardi G, Farina P, Zagonel V. Bevacizumab-based therapy for patients with brain metastases from non-small-cell lung cancer: Preliminary results. *Chemotherapy* 2014;60(5–6):294–9.
- Koutras AK, Krikelis D, Alexandrou N, Starakis I, Kalofonos HP. Brain metastasis in renal cell cancer responding to sunitinib. *Anticancer Res*. 2007;27(6C):4255–7.
- Shen Y, Ruan M, Luo Q, Yu Y, Lu H, Zhu R, Chen L. Brain metastasis from follicular thyroid carcinoma: Treatment with sorafenib. *Thyroid* 2012;22(8):856–60.
- Borghaei H, Paz-Ares L, Horn L, Spigel DR, Steins M, Ready NE, Chow LQ, Vokes EE, Felip E, Holgado E, Barlesi F, Kohlhaufl M, Arrieta O, Burgio MA, Fayette J, Lena H, Poddubskaya E, Gerber DE, Gettinger SN, Rudin CM, Rizvi N, Crino L, Blumenschein GR Jr, Antonia SJ, Dorange C, Harbison CT, Graf Finckenstein F, Brahmer JR. Nivolumab versus docetaxel in advanced nonsquamous non-small-cell lung cancer. *N Engl J Med*. 2015;373(17):1627–39.
- Goldman JW, Crino L, Vokes EE, Holgado E, Reckamp KL, Pluzanski A, Spigel DR, Kohlhaufl M, Garassino

- MC, Chow LQM, Gettinger SN, Gerber DE, Havel L, Ramalingam SS, Dy GK, Geese WJ, Li A, Blackwood-Chirchir A, Healey DI, Brahmer JR. Nivolumab (nivo) in patients (pts) with advanced (adv) NSCLC and central nervous system (CNS) metastases (mets). *J Thorac Oncol*. 2016;34(15_suppl):9038.
23. Gadgeel SM, Lukas RV, Goldschmidt J, Conkling P, Park K, Cortinovis D, de Marinis F, Rittmeyer A, Patel JD, von Pawel J, O'Hear C, Lai C, Hu S, Ballinger M, Sandler A, Gandhi M, Fehrenbacher L. Atezolizumab in patients with advanced non-small cell lung cancer and history of asymptomatic, treated brain metastases: Exploratory analyses of the phase III OAK study. *Lung Cancer* 2019;128:105–12.
24. Socinski MA, Jotte RM, Cappuzzo F, Orlandi F, Stroyakovskiy D, Nogami N, Rodriguez-Abreu D, Moro-Sibilot D, Thomas CA, Barlesi F, Finley G, Kelsch C, Lee A, Coleman S, Deng Y, Shen Y, Kowanetz M, Lopez-Chavez A, Sandler A, Reck M, Group IMS. Atezolizumab for first-line treatment of metastatic nonsquamous NSCLC. *N Engl J Med*. 2018;378(24):2288–301.
25. Zhao S, Ren S, Jiang T, Zhu B, Li X, Zhao C, Jia Y, Shi J, Zhang L, Liu X, Qiao M, Chen X, Su C, Yu H, Zhou C, Zhang J, Camidge DR, Hirsch FR. Low-dose apatinib optimizes tumor microenvironment and potentiates antitumor effect of PD-1/PD-L1 blockade in lung cancer. *Cancer Immunol Res*. 2019;7(4):630–43.
26. Zhang X, Zhou Y, Hu K, Li Z, Wang Z, Huang Y. Complete response of early stage hepatocellular carcinoma in a patient treated with combination therapy of camrelizumab (SHR-1210) and apatinib. *Dig Liver Dis*. 2019;51(10):1488–90.
27. Xu J, Zhang Y, Jia R, Yue C, Chang L, Liu R, Zhang G, Zhao C, Zhang Y, Chen C, Wang Y, Yi X, Hu Z, Zou J, Wang Q. Anti-PD-1 antibody SHR-1210 combined with apatinib for advanced hepatocellular carcinoma, gastric, or esophagogastric junction cancer: An open-label, dose escalation and expansion study. *Clin Cancer Res*. 2019;25(2):515–23.
28. Monsky WL, Mouta Carreira C, Tsuzuki Y, Gohongi T, Fukumura D, Jain RK. Role of host microenvironment in angiogenesis and microvascular functions in human breast cancer xenografts: Mammary fat pad versus cranial tumors. *Clin Cancer Res*. 2002;8(4):1008–13.
29. Brufsky AM, Hurvitz S, Perez E, Swamy R, Valero V, O'Neill V, Rugo HS. RIBBON-2: A randomized, double-blind, placebo-controlled, phase III trial evaluating the efficacy and safety of bevacizumab in combination with chemotherapy for second-line treatment of human epidermal growth factor receptor 2-negative metastatic breast cancer. *J Clin Oncol*. 2011;29(32):4286–93.
30. Robert NJ, Dieras V, Glaspy J, Brufsky AM, Bondarenko I, Lipatov ON, Perez EA, Yardley DA, Chan SY, Zhou X, Phan SC, O'Shaughnessy J. RIBBON-1: Randomized, double-blind, placebo-controlled, phase III trial of chemotherapy with or without bevacizumab for first-line treatment of human epidermal growth factor receptor 2-negative, locally recurrent or metastatic breast cancer. *J Clin Oncol*. 2011;29(10):1252–60.
31. Reinmuth N, Jauch A, Xu EC, Muley T, Granzow M, Hoffmann H, Dienemann H, Herpel E, Schnabel PA, Herth FJ, Gottschling S, Lahm H, Steins M, Thomas M, Meister M. Correlation of EGFR mutations with chromosomal alterations and expression of EGFR, ErbB3 and VEGF in tumor samples of lung adenocarcinoma patients. *Lung Cancer* 2008;62(2):193–201.
32. Larsen AK, Ouare D, El Ouadrani K, Petitprez A. Targeting EGFR and VEGF(R) pathway cross-talk in tumor survival and angiogenesis. *Pharmacol Ther*. 2011;131(1):80–90.
33. Naumov GN, Nilsson MB, Cascone T, Briggs A, Straume O, Akslen LA, Lifshits E, Byers LA, Xu L, Wu HK, Janne P, Kobayashi S, Halmos B, Tenen D, Tang XM, Engelman J, Yeap B, Folkman J, Johnson BE, Heymach JV. Combined vascular endothelial growth factor receptor and epidermal growth factor receptor (EGFR) blockade inhibits tumor growth in xenograft models of EGFR inhibitor resistance. *Clin Cancer Res*. 2009;15(10):3484–94.
34. Reck M, von Pawel J, Zatloukal P, Ramlau R, Gorbounova V, Hirsh V, Leigh N, Mezger J, Archer V, Moore N, Manegold C. Phase III trial of cisplatin plus gemcitabine with either placebo or bevacizumab as first-line therapy for nonsquamous non-small-cell lung cancer: AVAil. *J Clin Oncol*. 2009;27(8):1227–34.
35. Seto T, Kato T, Nishio M, Goto K, Atagi S, Hosomi Y, Yamamoto N, Hida T, Maemondo M, Nakagawa K, Nagase S, Okamoto I, Yamanaka T, Tajima K, Harada R, Fukuoka M, Yamamoto N. Erlotinib alone or with bevacizumab as first-line therapy in patients with advanced non-squamous non-small-cell lung cancer harbouring EGFR mutations (JO25567): An open-label, randomised, multicentre, phase 2 study. *Lancet Oncol*. 2014;15(11):1236–44.
36. Buttigliero C, Bertaglia V, Novello S. Anti-angiogenic therapies for central nervous system metastases from non-small cell lung cancer. *Transl Lung Cancer Res*. 2016;5(6):610–27.
37. Crino L, Dansin E, Garrido P, Griesinger F, Laskin J, Pavlakis N, Stroiakovski D, Thatcher N, Tsai CM, Wu YL, Zhou C. Safety and efficacy of first-line bevacizumab-based therapy in advanced non-squamous non-small-cell lung cancer (SAiL, MO19390): A phase 4 study. *Lancet Oncol*. 2010;11(8):733–40.