




## CLINICAL ARTICLE

# Surgical Transepicondylar Axis Is Not a Reliable Reference when there Was Lateral Femoral Bowing

LiMing Liu, MM , Kai Lei, MM , Lin Guo, MD, PhD , Xin Chen, MA, PengFei Yang, MD, DeJie Fu, MD, Ran Xiong, MD, Liu Yang, MD, PhD

Center for Joint Surgery, Southwest Hospital, Third Military Medical University, Chongqing, China

**Objective:** The surgical transepicondylar axis (sTEA) is believed to be a consistent reference for femoral rotation axis, and the reliability of its orientation seriously affects the accuracy and outcome of total knee arthroplasty (TKA). This study was designed to investigate the relationship between the orientation of sTEA and femoral bowing angle (FBA) and posterior condylar line (PCL) using three-dimensional (3D) computed tomography (CT) reconstruction models to verify its reliability.

**Methods:** This study retrospectively collected lower extremity images of 443 southern Chinese osteoarthritic patients (347 women, 96 men; 234 left, 209 right; mean age  $66.5 \pm 9.3$  years) from August 2016 to June 2018. The hip-knee-ankle angle (HKA) was measured on anteroposterior weight-bearing full lower extremity standing radiographs. Measurements on 3D CT models of the femurs included lateral angle between the femoral mechanical axis and sTEA coronal angle, angle between sTEA and distal joint line (distal condylar axis angle, DCA); angle between sTEA and PCL (sTEA axial angle); angle between anatomical axis of proximal femur and anatomical axis of distal femur in the plane they form (actual FBA) and its projection on the coronal (lateral FBA) and sagittal (anterior FBA) planes. The correlations between sTEA coronal angle, sTEA axial angle and actual FBA, lateral FBA, anterior FBA, HKA, DCA were explored using the Spearman correlation test.

**Results:** The mean value of actual FBA is  $(14.4 \pm 3.6)^\circ$ , of lateral FBA is  $(6.0 \pm 4.0)^\circ$ , and of anterior FBA is  $(12.7 \pm 3.0)^\circ$ . The mean value of sTEA coronal angle is  $(88.7 \pm 3.6)^\circ$ , of sTEA axial angle is  $(2.1 \pm 2.8)^\circ$ . The sTEA coronal angle was positively correlated with actual FBA ( $r = 0.320, P < 0.01$ ), lateral FBA ( $r = 0.448, P < 0.01$ ), anterior FBA ( $r = 0.113, P < 0.05$ ), HKA ( $r = 0.482, P < 0.01$ ) and DCA ( $r = 0.486, P < 0.01$ ). The sTEA axial angle was positively correlated with DCA ( $r = 0.168, P < 0.01$ ), but not significantly correlated with all FBAs and HKA (NS).

**Conclusion:** The sTEA cannot be used as a stable reference when there was an obvious femoral bowing deformity. As the lateral femoral bowing increases, the orientation of sTEA becomes more varus, no matter the knee is varus or valgus.

**Key words:** Computed tomography; Femoral bowing angle; Knee; Surgical transepicondylar axis; Total knee arthroplasty

## Introduction

Malalignment and malrotation of femoral components cause dissatisfaction after total knee arthroplasty (TKA).<sup>1,2</sup> Surgical transepicondylar axis (sTEA) is the line between the most prominent of lateral condyle and the most concave of medial condyle,<sup>3,4</sup> which is believed to be close to

the true femoral rotating axis.<sup>5,6</sup> In the axial plane, sTEA is considered a reliable axial reference for cutting the posterior condyle and rotating the femoral component compared to other osseous landmarks.<sup>7</sup> In the coronal plane, sTEA is perpendicular to the femoral mechanical axis.<sup>6,7</sup> This feature does not change even in osteoarthritic (OA) knees.<sup>7</sup>

**Address for correspondence:** Lin Guo MD, PhD, Center for Joint Surgery, Southwest Hospital, Third Military Medical University (Army Medical University), No. 30 Gaotanyan Street, Shapingba District, Chongqing, China 400038 Tel: 86-23-68765290; Fax: 86-23-68765293; Email: [guolin6212@163.com](mailto:guolin6212@163.com)

LiMing Liu and Kai Lei contributed to the work equally and should be regarded as co-first authors.

Trial registration number: ChiCTR1800019263. Date of registration: 2018/11/2

Received 23 March 2022; accepted 13 September 2022

Therefore, sTEA is often used in the coronal plane to assess the perpendicular position of the femoral component to femoral mechanical axis, especially in patients with large bone defects or in TKA revision cases.<sup>8</sup> It is also noted that sTEA is influenced by the lower extremity alignment, with both varus and valgus alignment resulting in a change in the orientation of sTEA in the coronal plane.<sup>9</sup>

Femoral bowing is the most common femoral deformity in female Asian population, and could be classified as anterior bowing and lateral bowing.<sup>10</sup> Femoral bowing could affect surgical technique<sup>11,12</sup> and lower extremity alignment<sup>13,14</sup> during TKA, and it is closely related to the development of OA.<sup>15</sup> Nejima *et al.* indicated that the orientation of sTEA in

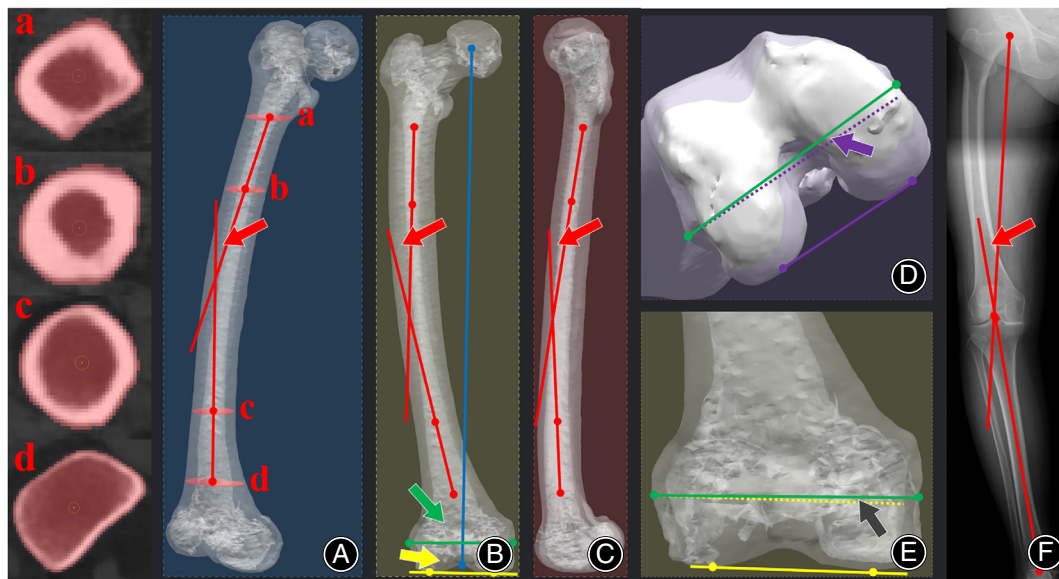
the coronal plane was influenced by lateral femoral bowing in OA patients with varus knees after a study of 82 knees using two-dimensional (2D) computed tomography (CT).<sup>8</sup> Three-dimensional (3D) CT could localize the orientation of sTEA more accurately than 2D CT.<sup>16</sup> But to our knowledge, there was no study that has yet explored the effect of femoral bowing on the coronal and axial orientation of sTEA in 3D CT reconstruction models in both varus and valgus knees.

The purposes of this study were: (i) to investigate the relationship between femoral shaft bowing and the coronal orientation of sTEA in patients with knee OA using 3D CT reconstruction models; and (ii) to investigate whether the axial orientation of sTEA also was affected by femoral bowing. It was hypothesized that the orientation of sTEA in the coronal plane would change to varus as the lateral femoral bowing increased, while the orientation of sTEA in the axial plane would also be affected, which would create an uneven medial narrow flexion gap.

### Material and Methods

A total of 534 knees of 534 southern Chinese patients who underwent TKA from August 2016 to June 2018 were retrospectively enrolled. The inclusion criteria were: (i) knee OA (Grade 3 or Grade 4); and (ii) patients already

TABLE 1 Patient demographic characteristics	
Characteristics	Means $\pm$ SD (range)
Age (years)	66.5 $\pm$ 9.3 (31–89)
Side (left/right)	234/209
Sex (male/female)	96/347
Height (cm)	156.6 $\pm$ 6.6 (135–179)
Weight (kg)	62.5 $\pm$ 10.4 (40–120)
BMI (kg/m <sup>2</sup> )	25.5 $\pm$ 3.7 (16.6–40.0)



**Fig. 1** Measurements of anatomical parameters on 3D CT models and radiographs. (A) The geometric center points of the cross-section of the femoral shaft below the level of the lesser trochanter; (B) The geometric center points of the cross-section 5 cm distal to the lesser trochanter; (C) The geometric center points of the cross-section 10 cm proximal to the knee joint line; (D) The geometric center points of the cross-section 5 cm proximal to the knee joint line; (A) Actual femoral bowing angle (FBA): the angle between the line connecting a and b and the line connecting c and d on the plane defined by the two lines (the blue plane); (B) lateral FBA (the red arrow), sTEA coronal angle (the green arrow), mechanical lateral distal femoral angle (mL DFA) (the yellow arrow) on a coronal projection of the 3D CT model; (C) anterior FBA on a sagittal projection of the 3D CT model; (D) sTEA axial angle on a axial projection of the 3D CT model (the purple arrow); (E) distal condylar axis angle (DCA) on a coronal projection of the 3D CT model (the black arrow); (F) hip-knee-ankle angle (HKA) on an anteroposterior radiograph; the green line: surgical transepicondylar axis (sTEA); the blue line: femoral mechanical axis; the yellow line: joint line; the purple line: posterior condyle line; the yellow plane: the coronal plane; the red plane: the sagittal plane; the purple plane: the axial plane.

received anteroposterior weight-bearing full lower extremity standing radiographic examination and full lower extremity CT scan before TKA. The exclusion criteria were: (i) history of femoral or tibial fracture (nine in femur and seven in tibia); (ii) previous surgical treatment (32 knees); (iii) flexion deformity  $>10^\circ$  (25 knees); and (iv) poor quality of image data (18 knees).

Finally, 443 knees from 443 patients were included (Table 1). The radiographs (Siemens DR Ysio Max, Kassel, Germany) and CT images (Siemens Somatom Definition Flash, Kassel, Germany) were available for all included patients and obtained as described by Akamatsu *et al.*<sup>17</sup> The study protocol was approved by the Ethics Committee of The First Hospital Affiliated to Army Medical University, PLA (KY201861), and the informed consent was waived by the review board.

### Measurement on Radiographs

The hip-knee-ankle angle (HKA), the angle between the mechanical axes of the femur and tibia, was measured using AutoCAD (P.46.0.0 AutoCAD, Mill Valley, CA, USA) on anteroposterior weight-bearing full lower extremity standing radiographs, with positive values representing varus alignment. HKA greater than  $3^\circ$  for varus knees, HKA less than  $-3^\circ$  for valgus knees, HKA from  $-3^\circ$  to  $3^\circ$  for neutral knees.

### Measurement on 3D CT Reconstruction Models

#### Measurement Method

For CT images, Mimics 19.0 (Materialise, Leuven, Belgium) was used to map the relevant landmarks with coronal plane, sagittal plane, axial plane and 3D view, and 3D reconstruction of the femur was performed; the results were imported into CATIA 5.20 (Dassault Systèmes, Paris, France) to fit the

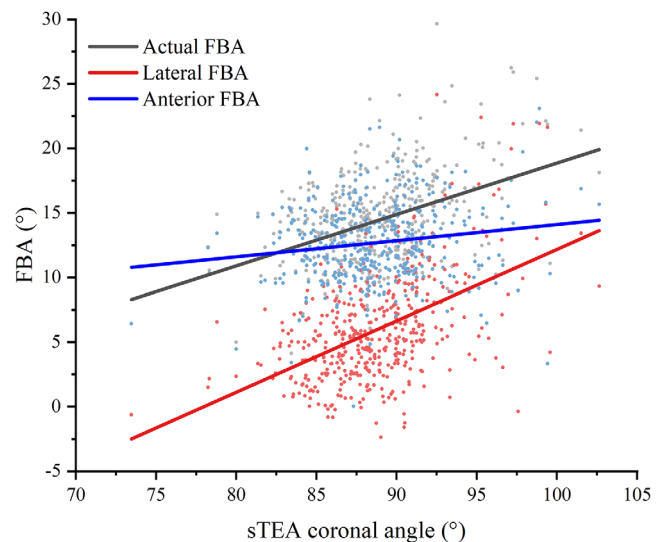
relevant landmarks and femoral head; each landmark was connected with NX 12 (Siemens, Kassel, Germany) and relevant data were measured.

### Definition of Anatomical Parameters

The coronal plane was defined as the plane formed by the femoral mechanical axis and the sTEA. The sagittal plane was the plane perpendicular to the femoral coronal plane through the femoral mechanical axis. The axial plane was the plane perpendicular to the mechanical axis. The femoral mechanical axis was the line between the center point of the femoral head and the apex of the femoral intercondylar notch. The joint line was the tangent line of the most distal apexes of two condyles. The posterior condyle line was the tangent line of the most posterior apexes of two posterior condyles. According to previous studies,<sup>3</sup> the angle between the anatomical axis of the proximal femur and the anatomical axis of the distal femur in the plane they formed was the actual femoral bowing angle (FBA; Fig. 1). The projection of the actual FBA in the coronal plane was the lateral FBA, a positive value representing lateral bowing. The projection in the sagittal plane was the anterior FBA, a positive value representing anterior bowing. The projection of the angle between the sTEA and the posterior condyle line on the axial plane was the sTEA axial angle, a positive value representing the opening of the angle facing medial. The projection of the lateral angle between the femoral mechanical axis and the sTEA on the coronal plane was the sTEA coronal angle. The projection of the lateral angle between the femoral

TABLE 2 Patient radiographic data and 3D CT model data	
Parameters ( $^\circ$ )	Means $\pm$ SD (range)
Actual FBA	14.4 $\pm$ 3.6 (2.6–31.3)
Lateral FBA	6.0 $\pm$ 4.0 (–2.4–24.2)
Anterior FBA	12.7 $\pm$ 3.0 (0.0–23.1)
HKA	8.9 $\pm$ 9.8 (–27.5–38.5)
DCA	0.1 $\pm$ 2.8 (–10.3–9.5)
mLDFA	88.6 $\pm$ 3.3 (75.8–102.1)
sTEA coronal angle	88.7 $\pm$ 3.6 (73.4–102.6)
sTEA axial angle	2.1 $\pm$ 2.8 (–8.3–10.8)

Abbreviations: Actual FBA, the femoral bowing angle in its forming plane; Anterior FBA, the projection of actual FBA on the sagittal plane; DCA, distal condylar axis angle; HKA, hip-knee-ankle angle; Lateral FBA, the projection of actual FBA on the coronal plane; mLDFA, mechanical lateral distal femoral angle; sTEA axial angle, the projection of the angle between the sTEA and the posterior condyle line on the axial plane; sTEA coronal angle, the projection of the lateral angle between the femoral mechanical axis and sTEA on the coronal plane.



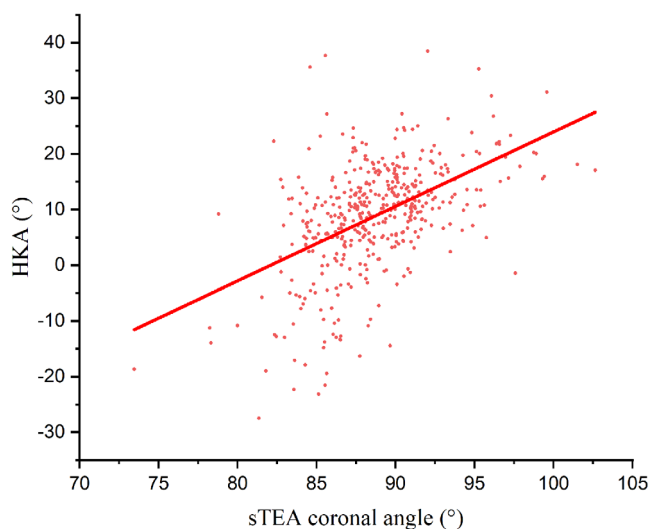
**Fig. 2** Correlation between sTEA coronal angle and FBA. sTEA coronal angle: the projection of the lateral angle between the femoral mechanical axis and sTEA on the coronal plane; Actual FBA: the femoral bowing angle in its forming plane; Anterior FBA: the projection of actual FBA on the sagittal plane; Lateral FBA: the projection of actual FBA on the coronal plane.

mechanical axis and the joint line on the coronal plane was the mechanical lateral distal femoral angle (mLDFA). The projection of the angle between the sTEA and the joint line on the coronal plane was the distal condylar axis angle (DCA), a positive value representing the opening of the angle facing medial.

To ensure the reproducibility of the measurement results, all variables were blindly measured twice by each of the three professionals (two experienced surgeons and one engineer from the 3D printing studio).

### Statistical Analysis

SPSS 22.0 (IBM, Armonk, NY, USA) was used for all statistical analyses. Descriptive statistics were presented in the form of the mean, and standard deviation. The Shapiro–Wilk



**Fig. 3** Correlation between sTEA coronal angle and HKA. sTEA coronal angle: the projection of the lateral angle between the femoral mechanical axis and sTEA on the coronal plane; HKA, hip-knee-ankle angle.

method was used to test whether the data were Gaussian distributed. Independent-samples *t* tests were performed when the data demonstrated a normal distribution; otherwise, the two independent samples Wilcoxon test was used. Pearson correlation test was carried out when the data demonstrated Gaussian distribution, otherwise the Spearman correlation test was employed. The intra-group correlation coefficients (ICCs) were used to evaluate the consistency of the inter- and intra-observer measurements. All tests were 2-tailed, and  $P < 0.05$  was considered statistically significant.

### Results

#### Consistency of Measurement Results

The ICCs for the sTEA axial angle and the sTEA coronal angle were greater than 0.7, and the ICCs for the remaining anatomical parameters were greater than 0.8.

#### Measurement Results of Imaging Data

The mean values of the measured data on radiographs and 3D CT models were shown in Table 2. The range of variation of the sTEA coronal angle and the sTEA axial angle was great, even more than 20°.

#### Correlation between Femoral Bowing Angle and the Orientation of Surgical Transepicondylar Axis

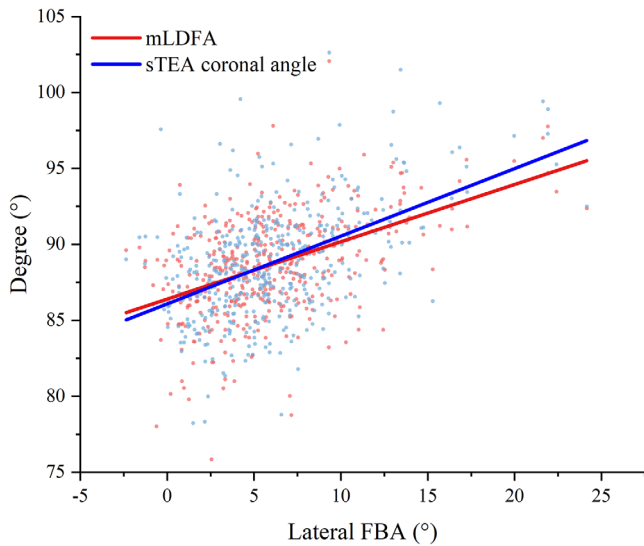
Overall, the sTEA coronal angle was positively correlated with lateral FBA (Fig. 2), HKA (Fig. 3) and DCA. The sTEA axial angle in the female was positively correlated with DCA, but not significantly correlated with all FBAs and HKA (Table 3). The mLDFA was also positively correlated with lateral FBA ( $r = 0.426$ ,  $P < 0.01$ ), but the correlation was less than the sTEA coronal angle (Fig. 4).

**TABLE 3** Correlation between sTEA coronal angle and sTEA axial angle and FBA, HKA and DCA

	sTEA coronal angle						sTEA axial angle					
	Total		Male		Female		Total		Male		Female	
	<i>r</i>	<i>P</i>	<i>r</i>	<i>P</i>	<i>r</i>	<i>P</i>	<i>r</i>	<i>P</i>	<i>r</i>	<i>P</i>	<i>r</i>	<i>P</i>
Actual FBA	<b>0.320</b>	<b>&lt;0.001</b>	0.179	0.080	<b>0.369</b>	<b>&lt;0.001</b>	0.010	0.839	-0.111	0.281	0.043	0.426
Lateral FBA	<b>0.448</b>	<b>&lt;0.001</b>	<b>0.354</b>	<b>&lt;0.001</b>	<b>0.465</b>	<b>&lt;0.001</b>	-0.022	0.646	-0.195	0.057	0.019	0.721
Anterior FBA	<b>0.113</b>	<b>0.017</b>	0.035	0.734	<b>0.154</b>	<b>0.004</b>	0.027	0.572	-0.053	0.605	0.042	0.434
HKA	<b>0.482</b>	<b>&lt;0.001</b>	<b>0.263</b>	<b>0.009</b>	<b>0.534</b>	<b>&lt;0.001</b>	-0.001	0.975	0.011	0.918	-0.004	0.937
DCA	<b>0.486</b>	<b>&lt;0.001</b>	<b>0.594</b>	<b>&lt;0.001</b>	<b>0.448</b>	<b>&lt;0.001</b>	<b>0.168</b>	<b>&lt;0.001</b>	0.116	0.262	<b>0.184</b>	<b>0.001</b>

Abbreviations: Actual FBA, the femoral bowing angle in its forming plane; Anterior FBA, the projection of actual FBA on the sagittal plane; DCA, distal condylar axis angle; HKA, hip-knee-ankle angle; Lateral FBA, the projection of actual FBA on the coronal plane; sTEA axial angle, the projection of the angle between the sTEA and the posterior condyle line on the axial plane, and *P*-value in bold signify a statistically significant difference; sTEA coronal angle, the projection of the lateral angle between the femoral mechanical axis and sTEA on the coronal plane.





**Fig. 4** Correlation between sTEA coronal angle, mL DFA and lateral FBA. sTEA coronal angle: the projection of the lateral angle between the femoral mechanical axis and sTEA on the coronal plane; Lateral FBA, femoral bowing angle on the coronal plane; mL DFA, mechanical lateral distal femoral angle.

TABLE 4 Correlation between sTEA coronal angle and FBAs						
Correlation with sTEA coronal angle	Varus group (360 knees)		Neutral group (32 knees)		Valgus group (51 knees)	
	<i>r</i>	<i>P</i>	<i>r</i>	<i>P</i>	<i>r</i>	<i>P</i>
Actual FBA	0.311	<b>0.000</b>	0.156	0.393	0.275	0.051
Lateral FBA	0.466	<b>0.000</b>	0.026	0.888	0.371	<b>0.007</b>
Anterior FBA	0.070	<b>0.000</b>	0.171	0.348	0.106	0.460

Abbreviations: Actual FBA, the femoral bowing angle in its forming plane; Anterior FBA, the projection of actual FBA on the sagittal plane. Numbers in parentheses represent the sample size. *P*-values in bold signify a statistically significant difference; Lateral FBA, the projection of actual FBA on the coronal plane; sTEA coronal angle, the lateral angle between the femoral mechanical axis and sTEA.

#### Effect of Lower Extremity Alignment on the Correlation between Surgical Transepicondylar Axis Coronal Angle and Femoral Bowing Angle

After grouping by HKA, in the varus group, the sTEA coronal angle was positively correlated with all FBAs; in the neutral group ( $P < 0.01$ ), the sTEA coronal angle was not correlated with all FBAs; and in the valgus group ( $P > 0.05$ ), the sTEA coronal angle was only positively correlated with lateral FBA ( $P < 0.01$ , Table 4).

#### Discussion

The most important finding of this study was that sTEA coronal angle increased with the increasing of lateral

FBA in both varus and valgus knees. And sTEA coronal angle correlated positively with varus lower extremity alignment. Although sTEA axial angle was not significantly correlated with femoral bowing and lower extremity alignment, it was indirectly influenced by lateral FBA in the female population.

#### Surgical Transepicondylar Axis Coronal Angle Was Positively Correlated with Lateral Femoral Bowing Angle

The sTEA has long been considered the closest reference axis to knee flexion-extension axis that can be used in clinical practice.<sup>5,7</sup> The orientation of sTEA in coronal plane is believed to be perpendicular to mechanical axis,<sup>6,7</sup> which makes sTEA play an important role in the treatment of patients with bone defects and TKA revisions since the availability of original anatomical landmarks is limited.<sup>8</sup> Kobayashi *et al.*<sup>7</sup> indicated that sTEA was perpendicular to femoral mechanical axis in the coronal plane after a study of 60 Japanese OA knees. However, they did not clarify the lower extremity alignment and femoral bowing of the patients, which are very common in Asian populations and may have an effect on the coronal orientation of sTEA.<sup>8,13</sup> This study found that the sTEA coronal angle was widely distributed and was influenced by femoral bowing, especially lateral femoral bowing. The sTEA coronal angle increased mainly with the increase of lateral FBA, the anterior FBA also contributed but very little. This phenomenon was seen in all knees of this study, whether varus or valgus. Nejima *et al.*<sup>8</sup> studied 82 Japanese OA patients with varus knees and noted that the coronal orientation of sTEA became more varus as lateral FBA increased, which was consistent with the results of this study. The positive correlation between HKA and sTEA coronal angle was also verified in the present study, in which the effect of lateral FBA played an important role.<sup>9</sup> This demonstrates that sTEA is not a stable coronal reference axis and that the orientation of sTEA will become varus when the lateral FBA is great and valgus when the lateral FBA is small.<sup>8</sup>

The present study reached the same conclusion as Zhang *et al.*<sup>9</sup> that the coronal orientation of sTEA was strongly correlated with the coronal orientation of femoral joint line. Interestingly, this study also found that lateral FBA, although it also had an effect on joint line orientation,<sup>18</sup> had less effect than on sTEA. When in the standing position, the orientation of the knee flexion and extension axis should be parallel to the floor.<sup>8</sup> Greater lateral FBA changes this relationship, making it varus. But the orientation of joint line seems to be partially corrected, even if this correction is not enough to resist the effect of the lateral FBA. The positive correlation between sTEA coronal angle and DCA also proves the existence of this correction.

**Lateral Femoral Bowing Angle also Had an Indirect Effect on the Surgical Transepicondylar Axis Axial Angle**

The orientation of sTEA in the axial plane is moreover considered to be an important reference axis for the rotational resection of femoral posterior condyle in TKA,<sup>19,20</sup> which is closely related to patellofemoral kinematics, component sizing, and symmetric medial and lateral flexion gap balance.<sup>16,19</sup> The present study also found a wide distribution of sTEA axial angle with a mean value of 2.1°, which was smaller than the results of previous studies.<sup>7,21</sup> The sTEA axial angle does not correlate significantly with FBAs and HKA. However, it is interesting to note that, similar to the sTEA coronal angle, sTEA axial angle in the female population also shows a positive correlation with DCA. This might be because greater lateral FBA makes the orientation of the coronal sTEA deviate varus, and in order to correct this deviation, the femoral medial condyle becomes greater, allowing the orientation of the joint line to be partially corrected while affecting the orientation of the axial sTEA, which needs to be confirmed by further studies. The male population did not show this phenomenon, which may be related to the small sample size of this study. This demonstrates that the orientation of coronal sTEA becomes more varus in patients with great lateral FBA, while the increase of the sTEA axial angle should also be concerned.

**Strengths and Limitations**

This study is the first to investigate the correlation between the orientation of sTEA and femoral bowing in a southern Chinese OA population using CT 3D models, and scientifically verified that sTEA is not able to be used as a reliable reference for TKA. However, there are several limitations in this study. First, the subjects of this study were OA patients, and its findings may not be applicable to the healthy population, future studies could be conducted on the healthy

population. Second, all samples were obtained from southern Chinese, thus the results may not be applicable to other ethnicities, and future studies could be conducted on other ethnic populations. Third, 85% of the subjects in this study had varus knees and fewer had valgus knees, which may affect the accuracy of the results and more patients with valgus knees should be collected in the future to continue to validate the findings of this study.

**Conclusion**

In this study, it was found that as the lateral femoral bowing increased, the orientation of the sTEA became more varus in the coronal plane. In addition, in the female population, the axial orientation of sTEA was also affected by lateral FBA, which might result in rotation of the femoral component in TKA even if the accurate bone cut was performed. This indicates that sTEA cannot be used as a stable reference in TKA when the patient has a significant lateral femoral bowing.

**Author Contributions**

**L**in Guo contributed mainly to the study conception and design. Material preparation and data collection were performed by LiMing Liu, Kai Lei, Pengfei Yang, Dejie Fu and Ran Xiong, data analysis was performed by LiMing Liu and Kai Lei, English language editing was performed by Xin Chen. The first draft of the manuscript was written by LiMing Liu and all authors commented on previous versions of the manuscript, Liu Yang provided important comments. All authors read and approved the final manuscript.

**Funding Information**

**T**his study was funded by National Key R&D Program of China (2021YFC2401300) and National Natural Science Foundation of China (82002357).

**REFERENCES**

1. Lei K, Liu LM, Xiang Y, Chen X, et al. Clinical value of CT-based patient-specific 3D preoperative design combined with conventional instruments in primary total knee arthroplasty: a propensity score-matched analysis. *J Orthop Surg Res.* 2020;15:591.
2. Oh SM, Bin SI, Kim JY, Lee BS, Kim JM. Impact of preoperative varus deformity on postoperative mechanical alignment and long-term results of "mechanical" aligned total knee arthroplasty. *Orthop Traumatol Surg Res.* 2019;105:1061–6.
3. Liu L, Lei K, Chen X, Fu D, Yang P, Yang L, et al. Proximal external femoral torsion increases lateral femoral shaft bowing: a study based on 3D CT reconstruction models. *Knee Surg Sports Traumatol Arthrosc.* 2021. <https://doi.org/10.1007/s00167-021-06753-y>
4. Lu Y, Ren X, Liu B, Xu P, Hao Y. Tibiofemoral rotation alignment in the normal knee joints among Chinese adults: a CT analysis. *BMC Musculoskelet Disord.* 2020;21:323.
5. Kobayashi H, Akamatsu Y, Kumagai K, Kusayama Y, Aratake M, Saito T. Is the surgical epicondylar axis the center of rotation in the osteoarthritic knee? *J Arthroplasty.* 2015;30:479–83.
6. Sato T, Mochizuki T. Three-dimensional morphology of the distal femur based on surgical epicondylar axis in the normal elderly population. *Knee.* 2021;30:125–33.
7. Kobayashi H, Akamatsu Y, Kumagai K et al. The surgical epicondylar axis is a consistent reference of the distal femur in the coronal and axial planes. *Knee Surg Sports Traumatol Arthrosc.* 2014;22:2947–53.
8. Nejima S, Kumagai K, Kobayashi H et al. Coronal shaft bowing of the femur affects varus inclination of the surgical transepicondylar axis in varus knee osteoarthritis. *Knee Surg Sports Traumatol Arthrosc.* 2020;29:814–9. <https://doi.org/10.1007/s00167-020-06025-1>
9. Zhang Y, Wang X, Shao Y, Xia Q. The orientation of the surgical epicondylar axis varies in varus and non-varus knees in the coronal plane. *Knee Surg Sports Traumatol Arthrosc.* 2018;26:2580–6.
10. Shimosawa H, Nagura T, Harato K et al. Variation of three-dimensional femoral bowing and its relation to physical status and bone mineral density: a study with CT. *Surg Radiol Anat.* 2019;41:1489–95.
11. Palanisami D, Iyyampillai G, Shanmugam S, Natesan R, Rajasekaran S. Individualised distal femoral cut improves femoral component placement and limb alignment during total knee replacement in knees with moderate and severe varus deformity. *Int Orthop.* 2016;40:2049–54.
12. Liu L, Lei K, Chen X, Fan H, Yang L, Guo L. Is valgus cut angle based on radiographic measurements in total knee arthroplasty really inaccurate? A comparison of two- and three-dimensional measurements. *J Knee Surg.* 2021. <https://doi.org/10.1055/s-0041-1728785>
13. Kim C, Bin SI, Kim JM, Lee BS, Park JG, Yoon GW. Postoperative alignment but not femoral coronal bowing is a significant longevity factor after total knee arthroplasty. *Orthop Traumatol Surg Res.* 2020;106:435–42.
14. Ko JH, Han CD, Shin KH et al. Femur bowing could be a risk factor for implant flexion in conventional total knee arthroplasty and notching in navigated total knee arthroplasty. *Knee Surg Sports Traumatol Arthrosc.* 2016;24:2476–82.
15. Matsumoto T, Hashimura M, Takayama K et al. A radiographic analysis of alignment of the lower extremities—initiation and progression of varus-type knee osteoarthritis. *Osteoarthr Cartil.* 2015;23:217–23.

- 16.** De Valk EJ, Noorduyn JC, Mutsaerts EL. How to assess femoral and tibial component rotation after total knee arthroplasty with computed tomography: a systematic review. *Knee Surg Sports Traumatol Arthrosc.* 2016;24:3517–28.
- 17.** Akamatsu Y, Kobayashi H, Kusayama Y, Kumagai K, Saito T. Femoral shaft bowing in the coronal and sagittal planes on reconstructed computed tomography in women with medial compartment knee osteoarthritis: a comparison with radiograph and its predictive factors. *Arch Orthop Trauma Surg.* 2016;136:1227–32.
- 18.** Lu Y, Zheng Z, Chen W, Lv H, Lv J, Zhang Y. Dynamic deformation of femur during medial compartment knee osteoarthritis. *PLoS One.* 2019;20:12.
- 19.** Chalmers BP, Kolin DA, Mayman DJ *et al.* Three degrees external to the posterior condylar Axis has little relevance in femoral component rotation: a computed tomography-based total knee arthroplasty simulation study. *J Arthroplasty.* 2021;36:S380-5.
- 20.** Blakeney W, Beaulieu Y, Puliero B, Kiss MO, Vendittoli PA. Bone resection for mechanically aligned total knee arthroplasty creates frequent gap modifications and imbalances. *Knee Surg Sports Traumatol Arthrosc.* 2020; 28:1532–41.
- 21.** Nishikawa M, Owaki H, Kaneshiro S, Fuji T. Preoperative morphometric differences in the distal femur are based on skeletal size in Japanese patients undergoing total knee arthroplasty. *Knee Surg Sports Traumatol Arthrosc.* 2014; 22:2962–8.