Since January 2020 Elsevier has created a COVID-19 resource centre with free information in English and Mandarin on the novel coronavirus COVID-19. The COVID-19 resource centre is hosted on Elsevier Connect, the company's public news and information website.

Elsevier hereby grants permission to make all its COVID-19-related research that is available on the COVID-19 resource centre - including this research content - immediately available in PubMed Central and other publicly funded repositories, such as the WHO COVID database with rights for unrestricted research re-use and analyses in any form or by any means with acknowledgement of the original source. These permissions are granted for free by Elsevier for as long as the COVID-19 resource centre remains active.

CHAPTER

43

# Nervous System Complications of Systemic Viral Infections

JOHN E. GREENLEE

PATHOGENESIS OF VIRAL CNS INFECTIONS
VIRAL MENINGITIS
Enteroviruses
Herpes Simplex Virus Type 2
Varicella Zoster Virus
Less Common Causes of Viral Meningitis
Human Immunodeficiency Virus
Approach to Patients with Viral Meningitis
VIRAL ENCEPHALITIS
Herpes Simplex Virus
Varicella Zoster Virus
West Nile Virus
Other Arthropod-Borne Viruses
Rabies Virus
Other Viruses
Viral Encephalitis in Immunocompromised Patients
Progressive Multifocal Leukoencephalopathy
Approach to Patients with Viral Encephalitis
PRION DISEASES
POSTINFECTIOUS COMPLICATIONS OF CNS VIRAL INFECTION
Postinfectious Encephalomyelitis
Acute Hemorrhagic Leukoencephalitis
Transverse Myelitis
Approach to Patients with Postinfectious Neurologic Injury

Invasion of the central nervous system (CNS) by viruses typically produces a meningoencephalitis in which either meningitis or encephalitis may predominate. Viruses may also infect cranial or spinal blood vessels leading to ischemic injury. Systemic or CNS infection by viruses or other infectious agents may elicit a host immune response that is cross-reactive with components of neural tissue, resulting in encephalomyelitis, transverse myelitis, injury to peripheral nerves, or optic neuritis.

## PATHOGENESIS OF VIRAL CNS INFECTIONS

Before a virus can infect the CNS, it must first breach the cutaneous or mucosal barriers that protect the patient from the outside environment and then penetrate the blood–brain barrier to gain access to susceptible cells in the meninges, brain, or spinal cord. At each step, the virus must infect specific cell populations and produce progeny virus in order to continue the infection. Viruses can enter the body through ingestion, as in enterovirus infections, by the respiratory route, as in influenza or chicken pox, by inoculation across skin, as in arthropod-borne encephalitides or rabies, or across mucosal membranes, as in human immunodeficiency virus (HIV) infection. Virtually all viruses capable of infecting the CNS do so via hematogenous spread; exceptions are the rabies virus and herpes simplex viruses types 1 and 2 (HSV-1, HSV-2), all of which travel from the periphery to the CNS within peripheral nerves. Varicella zoster virus (VZV) is transported within nerves during reactivated infection.

Infection at the cellular level may occur through several mechanisms. Herpesviruses are taken into the cell following fusion of the viral envelope to the host cell.[1] The human polyomavirus, JC virus (JCV), the etiologic agent of progressive multifocal leukoencephalopathy (PML), reacts with serotonin and other receptors in this process.[2] Alphaviruses, such as St. Louis encephalitis virus, recognize cell surface laminin and heparan molecules.[3] Viral replication within the host cell may result in various outcomes including lytic infection with cell death; productive infection with budding of viruses across

**Aminoff's Neurology and General Medicine, Fifth Edition.**
Published by Elsevier Inc.

the cell membrane without death of the host cell; or persistent infection, with the virus remaining latent over time.[2,4] Classic examples of viruses causing latent infection include HSV-1, HSV-2, and VZV, all of which persist in sensory ganglia and may reactivate to cause several syndromes including cutaneous lesions and CNS disease.[4]

Host response to viral infections initially involves innate immune responses and natural killer cells. Resolution of infection, however, involves both production of antibody and development of specific T-cell–mediated immune responses. Antibody is required to control and clear enteroviruses, and failure of antibody response may result in progressive enteroviral encephalitis. In contrast, immune control of West Nile virus (WNV) involves both B and T cells.[5,6] Failure of host T-cell response is a major factor in the pathogenesis of PML, as is alteration in CNS T-cell immune surveillance following treatment with the immunomodulatory drug natalizumab in disorders such as multiple sclerosis.[2,7] $CD8^+$ T cells are important in maintaining HSV and VZV in their latent states and in controlling both primary and reactivated infection.[4] In general, the host immune response is protective, although the inflammatory process that results may augment cerebral edema; however, CNS or systemic infections may also elicit an immune response cross-reactive with antigens to the central or peripheral nervous system, leading to postinfectious neurologic injury.

## VIRAL MENINGITIS

Acute viral meningitis is most commonly a disease of children and young adults and is the most frequent CNS complication of viral infection.[8] Viral meningitis accounts for an estimated 400,000 hospitalizations yearly in the United States. Major causative agents in Western countries are enteroviruses (accounting for up to 77% of cases), HSV-2 (10 to 20% of cases), and VZV (10 to 20% of cases) (Table 43-1).[8–12] A minority of cases are caused by WNV or other arthropod-borne agents, HIV, HSV-1, lymphocytic choriomeningitis virus (LCMV), or other agents.[13–16] In northern Europe, cases may be associated with tick-borne encephalitis virus and in southern Europe with Toscana virus.[16,17] In Asia, Japanese encephalitis virus is a common etiologic agent.[18] In 35 to 50 percent of cases, no agent is identified.[9,16]

The clinical presentation of viral meningitis in adults is similar to that of bacterial meningitis, although patients usually are less acutely ill (Table 43-2). Onset of meningeal symptoms may be preceded by fever and other symptoms of systemic illness, but viral meningitis often is of abrupt onset with severe headache and nuchal rigidity.[8] Although headache is most commonly the presenting symptom, it may be not be evident in infants and may be less prominent in young children and immunosuppressed individuals. Patients may exhibit photophobia, nausea, vomiting, and, in some cases, irritability and lethargy. Progression to obtundation or coma is rare without accompanying encephalitis. Some patients may have other evidence of systemic viral infection such as pharyngitis or rash, but abnormalities on general physical examination are often absent. Meningeal signs are typically less severe than in bacterial meningitis and may be subtle. The neurologic examination otherwise is usually unremarkable, and the presence of focal neurologic signs should raise concern that some other process is present.[8]

### Enteroviruses

Enteroviruses are unenveloped single-stranded RNA viruses forming a genus in the family picornavirus. They account for 70 to 80 percent of cases of viral meningitis in which an agent is identified.[8,19] Enteroviruses survive well in water and sewage, are transmitted by fecal-oral or hand-mouth routes, and replicate initially in the gastrointestinal tract. Enteroviruses were previously subdivided into three groups: polioviruses, echoviruses, and coxsackieviruses. Newer isolated enteroviruses have been assigned numbers (e.g., enterovirus 71 or EV 71). Coxsackievirus A9 and echoviruses E7, E9, E11, E19, and E30 have accounted for 70 percent of all cultured isolates from cerebrospinal fluid (CSF) in cases of enteroviral meningitis. Polioviruses have been largely eradicated, persisting only in Nigeria, Pakistan, and Afghanistan. Other enteroviruses have a worldwide distribution, and although cases of enteroviral meningitis occur throughout the year, infection is most likely to occur during summer and early fall months when conditions of sanitation are most lax. Acute enterovirus infection is usually asymptomatic or may result in mild gastroenteritis or pharyngitis; less than 5 percent of patients will develop meningitis or encephalitis.[19]

Enteroviral CNS infection typically causes meningitis rather than encephalitis, with fever, headache, and stiff neck.[19] These symptoms commonly last for 1 to 3 weeks in older children and adults. In occasional patients, enteroviruses may cause encephalitis or rarely a paralytic disease similar to polioviruses (see below) and may cause protracted, atypical infection in immunocompromised patients.

## Herpes Simplex Virus Type 2

HSV-2 is a double-stranded DNA virus that is universal in human populations. HSV-2 is usually transmitted sexually, with antiviral antibodies first appearing in adolescence or early adult life. Following acute infection, the virus persists predominantly in spinal sensory ganglia and is subject to periodic reactivation, often without cutaneous or mucosal signs of infection.[20] HSV-2 accounts for up to 10 to 20 percent of isolates in adults with viral meningitis and is roughly twice as common among women.[20,21] HSV-2 as a cause of viral meningitis should be considered particularly in young, sexually active adults.[21] Older data suggested that up to 36 percent of women and 11 percent of men had headache, fever, or nuchal rigidity at the time of their first attack of genital herpes.[21,22] Some patients with HSV-2 meningitis following genital herpes may have focal lumbosacral symptoms including urinary retention suggesting nerve root infection, and the virus may also be associated with myelitis.[20,21] HSV-2 DNA can frequently be detected in CSF by amplification using the polymerase chain reaction (PCR).[21] Approximately 20 percent of individuals with acute HSV-2 meningitis may subsequently develop recurrent episodes of meningitis (Mollaret meningitis).[21] Many individuals with recurrent meningitis have no history of genital herpes and lack genital lesions during attacks of meningitis.

Patients with HSV-2 meningitis usually recover without treatment. Although successful treatment with acyclovir has been described in individual cases, the efficacy of antiviral therapy in acute or recurrent HSV-2 meningitis is uncertain.[23,24] In a recent trial, suppressive treatment with valacyclovir did not prohibit recurrence of HSV-2 meningitis.[25]

## Varicella Zoster Virus

VZV is a herpesvirus typically associated with chicken pox during acute infection and with cutaneous zoster (shingles) during reactivated infection. Like HSV-2, VZV is thought to account for 10 to 20 percent of identified cases of viral meningitis.[8–12] Meningitis may occur during either primary or reactivated infection and may do so in the absence of rash.[26–30] In contrast to many other viruses, VZV meningitis may result in significant CSF hypoglychorrachia and may be accompanied by a CSF pleocytosis characterized by atypical lymphocytes.[29,30] As with HSV-2 meningitis, most immunocompetent patients with VZV meningitis recover without treatment. VZV infection may produce a wide variety of other neurologic conditions, which are discussed in greater detail later.

## Less Common Causes of Viral Meningitis

The arthropod-borne agents—WNV, St. Louis encephalitis virus, California encephalitis virus, Powassan virus, and Colorado tick fever virus—are most commonly associated with encephalitis, but may also cause meningitis. WNV, St. Louis encephalitis virus, and California encephalitis virus are transmitted by mosquitoes and tend to be more common in summer and early autumn months. The tick-borne agents Powassan virus and Colorado tick fever virus can cause a rash and most frequently occur during spring and early summer months. An important consideration in patients with suspected Colorado tick fever is the tick-borne rickettsial illness Rocky Mountain spotted fever, which also has a peak incidence in spring and summer, usually has a rash, and requires antibiotic treatment.[31]

LCMV is an arenavirus whose natural host is mice but which can cause meningitis and, less frequently, encephalitis in humans. The virus is present in mouse urine and is acquired by the respiratory route. At one time, it was thought to account for roughly 4 percent of diagnosed cases of viral meningitis, but in recent years it has become much less common, for unknown reasons.[15,32] LCMV infections are classically most common in autumn and winter. Occasional outbreaks of infection have been associated with exposure to mice in animal facilities or to pet hamsters or guinea pigs.[15] The meningitis associated with LCMV may be accompanied by low CSF glucose levels, which may persist in cases of prolonged recovery over weeks to months.[33] In neonates, LCMV may cause a fatal systemic and CNS infection.[34] Outbreaks of severe infection with high mortality have also been reported in which LCMV

**TABLE 43-1 ■ Major Viral Agents Associated With Human Neurologic Disease**

| Viruses | Genus (Family) | Animal Reservoir | Transmission | Geographic Location | Peak Season[a] | Neurologic Syndromes | Acute Diagnosis[b,c] | Treatment |
|---|---|---|---|---|---|---|---|---|
| *Major Viruses in North America and Europe* | | | | | | | | |
| Coxsackieviruses<br>Echoviruses<br>Enterovirus 71 and other numbered enteroviruses | Enteroviruses (Picornaviridae) | No | Fecal-oral spread | Worldwide | Summer to early autumn | Meningitis<br>(Encephalitis)[d]<br>(Poliomyelitis) | CSF PCR | Supportive (Pleconaril)[e] |
| Herpes simplex virus type 1 (HSV-1) | Herpesviruses (Herpesviridae) | No | Human contact | Worldwide | No seasonal distribution | Encephalitis | CSF PCR | Acyclovir |
| Herpes simplex virus type 2 (HSV-2)[f] | Herpesviruses (Herpesviridae) | No | Human contact | Worldwide | No seasonal distribution | Meningitis<br>Recurrent meningitis<br>Myelitis | CSF PCR | Acyclovir[g] |
| Varicella zoster virus | Herpesviruses (Herpesviridae) | No | Respiratory or human contact | Worldwide | No seasonal distribution | Shingles<br>Post-herpetic neuralgia<br>Meningitis<br>Vasculitis involving brain, spinal cord, eye, peripheral nervous system<br>(Encephalitis) | CSF PCR (acute infection)<br>CSF IgM and IgG (reactivated infection) | Acyclovir<br>Valacyclovir[g] |
| Cytomegalovirus[h] | Herpesviruses (Herpesviridae) | No | Human contact | Worldwide | No seasonal distribution | Encephalitis (infants or immunocompromised patients) | CSF PCR | Gancyclovir (Foscarnet) |
| Human herpesvirus 6[i] | Herpesviruses (Herpesviridae) | No | Human contact | Worldwide | No seasonal distribution | Meningitis<br>Encephalitis | CSF PCR | Gancyclovir, Foscarnet |
| West Nile virus | Togaviruses (Flaviviridae) | Birds, esp. crows, jays, magpies | Mosquito sp.<br>Organ transplantation | USA excepting Alaska and Hawaii[j] | Summer to early autumn | Meningitis<br>Encephalitis<br>Poliomyelitis | CSF IgM | Supportive |
| St. Louis encephalitis virus | Togaviruses (Flaviviridae) | Small mammals | Mosquito sp. | USA excepting Alaska and Hawaii | Summer to early autumn | Meningitis<br>Encephalitis | CSF IgM | Supportive |
| Eastern equine encephalitis virus | Alphavirus (Togaviridae) | Salt marsh and other birds | Mosquito sp. | Atlantic seabord, Gulf coast, upper Midwest | Summer to early autumn | Meningitis<br>Encephalitis | CSF IgM<br>(PCR) | Supportive |
| California/ LaCrosse virus[i] | (Bunyaviridae) | Small mammals | Mosquito sp. | USA, esp. Midwestern and mid-Atlantic states | Summer to early autumn | Meningitis<br>Encephalitis | CSF IgM | Supportive |
| Colorado tick fever | Orbivirus (Reoviridae) | Small mammals | Tick sp. | Western USA (esp. mountain states), western Canada | Spring to mid-summer | Meningitis<br>Encephalitis | PCR<br>CSF IgM | Supportive |
| Lymphocytic choriomeningitis virus (LCMV)[k] | Arenavirus (Arenaviridae) | Mice (hamsters) | Aerosol | Worldwide | Autumn to winter | Meningitis<br>Encephalitis | PCR<br>CSF IgM<br>Serum and CSF IgM and IgG | Supportive |

| | | | | | | | | |
|---|---|---|---|---|---|---|---|---|
| (HIV1, HIV2) | Human immunodeficiency virus (Retroviridae) | None | Intimate sexual contact; IV drug abuse | Worldwide | No seasonal distribution | Meningitis acutely | PCR<br>Serology | Antiretroviral treatment |
| JC virus[h] | Polyoma virus (Polyomaviridae) | None | Unknown | Worldwide | No seasonal distribution | PML | PCR | Supportive [l] |
| *Viruses Which Are Uncommon in North America but May Occur in Individuals Exposed in Endemic Areas* | | | | | | | | |
| Mumps virus[m] | Rubalavirus (Paramyxoviridae) | None | Respiratory spread | Worldwide | January to May | Meningitis<br>Encephalitis | CSF PCR | Supportive |
| Toscana virus | Phlebovirus (Bunyaviridae) | Reservoir in nature unknown | Sand fly | Italy, other Mediterranean countries | May to September | Meningitis (Encephalitis) | CSF PCR | Supportive |
| Japanese encephalitis virus | Flavivirus (Flaviviridae) | Pigs, wild birds (herons) | Mosquito sp. | Southeast Asia and Far East | Following wet season: varies by country | Encephalitis | CSF IgM | Supportive |
| Nipah virus | Henipavirus (Paramyxoviridae) | Pteropid fuit bats | Consumption of food contaminated with infected bat saliva or urine<br>Human-to-human | India, Bangladesh, Southeast Asia, Indonesia, Australia | No seasonal distribution | Encephalitis | PCR<br>CSF IgM<br>Serum serology | Supportive |
| Venezuelan equine encephalitis | Alphavirus (Togaviridae) | Birds, small mammals | Mosquito sp. | South and Central America, extreme southern USA | No seasonal distribution | Encephalitis (Meningitis) | PCR | Supportive |
| Tick-borne encephalitis virus | Flavivirus (Flaviviridae) | Birds, small mammals | Tick sp.<br>Unpasteurized milk | Europe, former Soviet Union, Asia | April to November | Meningitis<br>Encephalitis | PCR | Supportive |
| Rabies virus | Lissavirus (Rhabdoviridae) | Bats, skunks, foxes, raccoons<br>Unvaccinated dogs | Animal bite<br>Aerosol<br>(Organ transplantation) | Worldwide | No seasonal distribution | Encephalitis ("furious" or "dumb" rabies)<br>Ascending motor paralysis[n] | PCR (CSF)<br>Nuchal biopsy | Supportive |

[a]Sporadic cases of many agents may occur outside peak season.
[b]Retrospective diagnosis may be made by comparing antibody titers in acute and convalescent sera or by comparing serum:CSF ratios of antibody against those of other agents.
[c]Diagnostic methods for common agents such as HSV-1, HSV-2, enteroviruses, West Nile virus, and varicella zoster virus are readily available through many hospital and commercial laboratories. Advice concerning less usual infections may be obtained through the Centers for Disease Control and Prevention.
[d]Less frequent forms of illness are shown in parentheses.
[e]Not available in the United States.
[f]HSV-2 meningitis may occur as a single event but may also be recurrent and is the major cause of Mollaret meningitis.
[g]Mild cases of HSV-2 meningitis may not require treatment. Severe HSV-2 meningitis may require treatment with acyclovir. Treatment of recurrent HSV-2 meningitis may employ valacyclovir.
[h]Immunocompromised patients
[i]Predominantly an infection of children
[j]West Nile virus also present in much of Europe, Egypt, Israel, Africa, India, and western Asia.
[k]A murine virus. Infections also reported after exposure to infected pet hamsters.
[l]Treatment in AIDS involves suppression of HIV with antiretroviral therapy; treatment in patients developing PML in the setting of natalizumab therapy (and possible other monoclonal agents) has consisted of withdrawal of the monoclonal agent and plasma exchange to reduce circulating levels of the monoclonal antibody.
[m]Previously a major cause of viral meningitis in the United States. Still a major cause of meningitis in countries where vaccination is not routine. Associated with occasional outbreaks of infection in unvaccinated individuals in the United States and Europe.
[n]Incubation period may be 3 or more years. Obtaining history of exposure should take this into account.

**TABLE 43-2 ■ Signs and Symptoms of Viral Meningitis**

| |
|---|
| *Common* |
| Headache |
| Fever |
| Nausea, vomiting |
| Stiff neck (not present in all cases; may be subtle) |
| *Less Common* |
| Lethargy, mild confusion, irritability* |
| Seizures* |
| Systemic signs including rash, diarrhea, pharyngitis, myalgias, adenopathy (with mumps parotitis) |

*Impaired consciousness, seizures, and focal neurologic signs suggest the likelihood of encephalitis or other severe infections (meningitis, parameningeal infection, brain abscess).

has been transmitted by organ transplantation.[35,36] Reliable antiviral therapy for LCMV infection is not available; one patient with transplant-acquired LCMV infection recovered after reduction of the patient's immunosuppressive regimen and treatment with ribavirin.[35]

Mumps virus, once a major cause of meningitis worldwide, is now rare in developed countries but remains a significant cause of meningitis in areas where mumps immunization is not practiced.[37] The virus has caused occasional epidemics in Western countries in unvaccinated populations exposed to individuals who have visited areas where mumps is still prevalent.[37–39]

## Human Immunodeficiency Virus

CNS invasion occurs early in the course of primary HIV infection, and meningitis due directly to HIV occurs in 9 to 24 percent of patients (see Chapter 44).[40,41] The meningitis usually develops near the time of seroconversion and often occurs in the setting of an acute, mononucleosis-like retroviral syndrome characterized by fever, pharyngitis, and cervical lymphadenopathy; CNS findings of disorientation, confusion, or psychosis accompany this syndrome in some patients.[40] Primary HIV meningitis should be considered in young adults with meningitis, particularly when they have HIV risk factors or a coexistent mononucleosis-like syndrome. The symptoms of meningitis are usually not severe and resolve in most but not all cases; in some patients, HIV meningitis becomes chronic.[40] The CSF typically reveals a mild lymphocytic pleocytosis, mildly elevated protein content, and normal glucose level.[40] Standard serologic tests for HIV (as well as tests for home use) are negative in many patients with this acute syndrome; serologic tests first become positive 22 to 27 days after onset of acute infection.[41] The diagnosis of acute HIV meningitis is made by detecting viral RNA or viral p24 antigen in serum or plasma; the viral RNA usually becomes detectable 3 to 5 days prior to the detection of p24 antigen and is typically present in copy numbers greater than 50,000 copies/ml.[41] Treatment of HIV is with antiretroviral therapy, and follow-up assay for antiviral antibodies is used to confirm the diagnosis. In approaching patients with suspected HIV meningitis, it must be kept in mind that lymphocytic meningitis in patients with HIV infection may be caused by a wide variety of other agents, many of which are treatable.[40]

## Approach to Patients with Viral Meningitis

Bacterial meningitis is the primary concern in any patient presenting with acute meningitis. If the patient is severely ill, bacterial meningitis should be suspected and presumptive antibiotic therapy should be initiated immediately, usually along with corticosteroids. Similarly, acyclovir should be initiated if HSV encephalitis is a significant diagnostic concern. Antibiotics and acyclovir can be discontinued once CSF studies are negative. In general, patients presenting with viral meningitis are less severely ill, and antibiotic and acyclovir treatment may often be deferred.

The diagnosis of viral meningitis is made by lumbar puncture and CSF analysis. In acute bacterial meningitis, there is often an elevated opening pressure and typically a marked neutrophilic pleocytosis, with significantly elevated protein and depressed glucose concentrations.[33] In contrast, in viral meningitis the opening pressure is usually normal or mildly elevated, and the CSF white cell count is usually in the range of 50 to 2000/ml. Although viral meningitis typically produces a lymphocytic pleocytosis, polymorphonuclear leukocytes may constitute over 50 percent of the cells during the first 24 to 36 hours of the infection and may occasionally remain the predominant cell type for longer periods of time.[33] Protein is usually elevated in the range of 50 to 100 mg/dl but is sometimes higher.[33] The CSF

glucose level in viral meningitis is usually greater than 50 percent of blood glucose; the absence of CSF hypoglychorrhachia is an important consideration in differentiating viral from bacterial meningitis. Depression of glucose to levels approaching those of bacterial meningitis may occasionally occur in meningitis caused by HSV-2, VZV, mumps, and LCMV.[33] In the proper setting, lymphocytic pleocytosis with low CSF glucose may also raise concern about tuberculous or fungal meningitis.

Specific diagnosis of viral agents in CSF currently involves PCR amplification of viral RNA or DNA; at present, tissue culture isolation of virus is rarely performed for diagnostic purposes (Table 43-1).[33] PCR is rapid and has a high level of sensitivity in meningitis due to enteroviruses, HSV-2, and VZV during acute infection.[33] PCR can identify all strains of enteroviruses but does not distinguish between individual strains.[33] Enteroviral RNA can be identified in CSF in the first 1 or 2 days of meningitis, from throat for several days, and from stool for a few weeks. Because asymptomatic enterovirus infections are common in the summer months, enterovirus isolation from throat or stool does not make a definitive diagnosis of enterovirus meningitis. In one study, use of an enterovirus PCR assay in the emergency department in children with aseptic meningitis resulted in significantly less antibiotic use, shorter length of hospitalization, and lower hospital costs.[42] Although it is the diagnostic study of choice in many viral meningitides, CSF PCR may be negative early in the disease course, and diagnostic yield may be highest when CSF is obtained within 3 to 14 days of onset of meningitis.[43] In certain instances, the detection of CSF immunoglobulins may have greater diagnostic sensitivity than PCR. This is the case in WNV neuroinvasive disease and other arbovirus infections, in which detection of virus-specific immunoglobulin M (IgM) is more sensitive than PCR.[33] Similarly, detection of virus-specific IgG in CSF may prove diagnostic in infections due to protracted or reactivated VZV where PCR is negative.[44] Identification of the causative agent in viral meningitis may be made retrospectively by detecting a rise in IgG antibody titers between acute and convalescent (obtained after 3 to 6 weeks) serum or, at times, by detecting an abnormal serum:CSF ratio of antiviral antibodies.

Other laboratory studies in viral meningitis are usually unhelpful. Peripheral white blood cell count may be normal or elevated. Computed tomography (CT) scans and magnetic resonance imaging (MRI) of the brain are typically normal. The electroencephalogram (EEG) is usually normal but may occasionally show mild background slowing. Marked asymmetries or seizure foci should not be seen unless encephalitis predominates.

Viral meningitis is sometimes referred to by the older term "aseptic meningitis." This term, however, subsumes a broad range of clinical entities characterized by a meningeal reaction but distinct from purulent bacterial meningitis. It may include not only viral meningitis but also infections by bacteria that are not readily detected in routine cultures (*Leptospira icterohaemorrhagiae*, *Borrelia burgdorferi*, *Treponema pallidum*, *Mycoplasma pneumoniae*), meningeal involvement by *Rickettsia*, *Ehrlichia*, or *Anaplasma*, and infection by parasites such as *Toxoplasma gondii*. The possibility of infection by one of these agents should be kept in mind in a patient with suspected viral meningitis, since all are amenable to antibiotic treatment. In particular, *Borrelia burgdorferi* can be a major cause of lymphocytic meningitis in endemic areas (see Chapter 40).[45,46] Aseptic meningitis may also be associated with a variety of pharmacologic agents including nonsteroidal anti-inflammatory agents, trimethoprim-sulfamethoxazole, augmentin, carbamazepine, intravenous immunoglobulin G, and the murine monoclonal antibody OKT3.[47,48]

Treatment of viral meningitis is supportive in most cases. Analgesics may be required for individuals with severe headaches, and antiemetics for those with considerable nausea and vomiting. Hospitalization is seldom required except when vomiting is severe enough to cause dehydration or when bacterial meningitis cannot be excluded. Acyclovir and valacyclovir have been used to shorten the duration of illness in acute meningitis due to HSV-2 and VZV (Table 43-3).[49] However, controlled studies do not exist, and no standardized regimen has been developed.[24,50] Patients with recurrent HSV meningitis may wish to keep oral acyclovir or valacyclovir at home and take the drug at the onset of meningeal symptoms. Ongoing twice daily treatment with valacyclovir at a dose of 0.5 mg has not been shown to prevent recurrence, but higher dosages were not studied.[25] The antiviral agent pleconaril, which prevents uncoating of viral RNA, has been used in enteroviral meningitis but is not routinely available in the United States.[51,52]

As a group, patients with viral meningitis generally make a complete recovery within 1 to 2 weeks. Not all patients recover this quickly, however, and

**TABLE 43-3 ■ Antiviral Agents Used for CNS Infections**

| Antiviral | Mechanism of Action | Indication | Regimen in Adults | Major Adverse Effects |
|---|---|---|---|---|
| Acyclovir | Competes with deoxyguanosine triphosphate as a substrate for DNA polymerase. Causes viral DNA chain termination. Converted to active form in infected cells | HSV encephalitis<br>Severe HSV meningitis<br>VZV encephalitis, CNS vasculitis or severe meningitis | 10 mg/kg intravenously every 8 hours for 21 days | Nephrotoxicity: may cause renal failure if patient not adequately hydrated<br>Psychosis<br>Stevens–Johnson syndrome<br>Tissue necrosis |
| | | Recurrent HSV-2 meningitis | 800 mg orally 5 times daily for 5–7 days | |
| | | Varicella (chicken pox) or Herpes zoster (shingles) | 800 mg orally 5 times daily for 5–7 days | |
| Valacyclovir | Same as acyclovir | HSV meningitis (esp. recurrent) | 1,000 mg every 8 hours for 7 days | Similar to acyclovir |
| | | Herpes zoster (shingles) | 1,000 mg every 8 hours for 7 days | |
| Ganciclovir | Similar to acyclovir: inhibits viral DNA polymerization | Encephalitis due to cytomegalovirus or HHV-6 | 5 mg/kg every 12 hours for 14–21 days | Hematologic toxicity (anemia, leukopenia, thrombocytopenia)<br>Nephrotoxicity: may cause renal failure if patient not adequately hydrated |
| Foscarnet | Selective inhibition of viral DNA polymerase | Encephalitis due to cytomegalovirus or HHV-6; acyclovir-resistant VZV | 90 mg/kg intravenously every 12 hours for 14–21 days | Hematologic toxicity (anemia, leukopenia, thrombocytopenia)<br>Nephrotoxicity: may cause renal failure if patient not adequately hydrated |

HSV, herpes simplex virus; VZV, varicella zoster virus; HHV-6, human herpesvirus type 6.

symptoms such as fatigue may last for weeks or even months. CSF abnormalities may also persist for well beyond the initial period of recovery.[33] In addition, there have been occasional reports of permanent sequelae, usually but not always in small children, including cognitive impairment, deafness, and cranial nerve palsies.[53–57] Aqueductal stenosis with hydrocephalus is a rare complication of HSV-2 and mumps meningitis.[58,59]

## VIRAL ENCEPHALITIS

Viral encephalitis is caused by viral infection of cells within the brain parenchyma (Table 43-4). The cell populations in which viral replication occurs differ among the various viruses and may involve neurons, glia, or, at times, vascular endothelial cells. The result of the infection may be death of specific cell populations or more widespread destruction involving multiple cell types. Viruses affecting unique populations of cells include rabies, which infects neurons exclusively; poliomyelitis, which involves spinal and other motor neurons; and JC virus, which causes lytic infection almost exclusively in oligodendrocytes. Viruses infecting multiple cell types, often with extensive parenchymal destruction, include HSV and agents of the arthropod-borne encephalitides. Parenchymal destruction in severe infections such as herpes simplex encephalitis may be accompanied by hemorrhage. Virtually all viral encephalitides are accompanied by some degree of meningeal inflammation and cerebral edema, the latter of which may be severe enough to cause death.[60,61]

Viral encephalitis occurs worldwide, with a particularly high incidence in the tropics. (Table 43-1) outlines the major viruses that cause encephalitis and lists some of their distinguishing characteristics. Each year in the United States, between 1,000 and 5,000 cases of encephalitis are reported to the Centers for Disease Control (CDC). Identification of the etiologic agent in viral encephalitis is achieved in only about 50 percent of cases.[12,62]

**TABLE 43-4 ■ Signs and Symptoms of Viral Encephalitis**

| |
|---|
| *Common* |
| Impairment of consciousness: confusion, lethargy, delirium, coma |
| Inability to recall new information/anterograde amnesia (esp. HSV-1 encephalitis) |
| Headache |
| Fever |
| Stiff neck (may be subtle) |
| *Less Common* |
| Focal or generalized seizures |
| Hemiparesis, spasticity, or other signs of focal CNS dysfunction including aphasia, blindness, or ataxia |
| Cranial nerve palsies |
| Tremors |

HSV-1, herpes simplex virus type 1.

## Herpes Simplex Virus

Herpes simplex encephalitis represents only 10 to 15 percent of cases of viral encephalitis in the United States. However, it remains the most common cause of fatal nonepidemic viral encephalitis and is the only viral encephalitis for which effective antiviral therapy has been proven in clinical trials.[20,63] HSV is ubiquitous in human populations. HSV-1 is most commonly acquired as a symptomatic or asymptomatic gingivostomatitis in early childhood.[1,4] HSV-2 is more commonly sexually transmitted and is classically acquired during adolescence or adulthood.[1,4] Both agents enter neuronal processes during primary infection and persist in neurons within sensory ganglia. HSV-1 may also persist within the CNS and is responsible for 90 percent of cases of herpes simplex encephalitis in adults; of these cases, roughly two-thirds represent reactivated infection.[64,65] HSV-2 may be associated with myelitis.[22]

The pathogenesis of herpes simplex encephalitis is not well understood. Encephalitis has been postulated to follow the spread of virus from the trigeminal ganglia through sensory fibers to the meninges overlying the temporal lobes and orbitofrontal cortex or, alternatively, to follow reactivation of virus in the olfactory bulbs prior to spread to the brain itself.[20,64] HSV infects neurons, glia, and ependyma.

Herpes simplex encephalitis occurs throughout the year without seasonal incidence, affects men and women equally, and may occur at any age.[63,66] Immunosuppression does not increase the risk of encephalitis, but the course may be atypical in these individuals.[67,68] The virus has a predilection for orbitofrontal cortex and temporal lobes, which it may involve unilaterally or bilaterally.[63] The cingulate cortex is also involved in many patients. Occasionally herpes simplex encephalitis involves the occipital cortex or brainstem, in rare cases without temporal lobe involvement.[69] Vascular congestion and petechial or larger hemorrhages may be present; progression of the infection results in extensive and frequently hemorrhagic destruction of brain.[70]

Herpes simplex encephalitis presents with an almost universal triad of headache (in over 90% of cases), fever, and alteration in mental state.[20,63] Changes in mental state at presentation may range from confusion, frank psychosis, or somnolence to stupor or coma. Temporal lobe involvement may be manifested by olfactory or gustatory hallucinations, déjà vu phenomena, and upper quadrant visual field defects.[63] Bilateral temporal involvement may result in the loss of ability to store and recall new information, and involvement of the dominant hemisphere can result in aphasia. Rare patients present with symptoms and signs referable to the occipital lobes.[71] Focal or generalized seizures may occur at any point during the acute illness or after recovery.

The CSF typically contains a lymphocytic pleocytosis of 50 or more cells/mm$^3$ (median, 130 cells/mm$^3$).[72] In occasional patients, however, the cell count is normal.[33,72] Although herpes simplex encephalitis is frequently hemorrhagic, the presence or absence of red blood cells in CSF does not differentiate HSV infection from encephalitis due to other causes.[33,72] CSF protein concentration has a median value of 80 mg/dl, but ranges from normal to over 700 mg/dl; CSF glucose is usually normal.[33,72] MRI with gadolinium enhancement is the initial diagnostic procedure of choice and will usually demonstrate hyperintense T2-weighted signal along with gadolinium enhancement within the temporal lobe; it may also show involvement of the insula, orbitofrontal cortex, and cingulate gyrus (Fig. 43-1).[63] MRI abnormalities in other regions of cortex or brainstem, without temporal lobe involvement, do not exclude the diagnosis.[73] The EEG may show temporal lobe slowing or spike-wave activity. CT with contrast and EEG are less sensitive, but used together may provide diagnostic information when MRI is not available.[74]

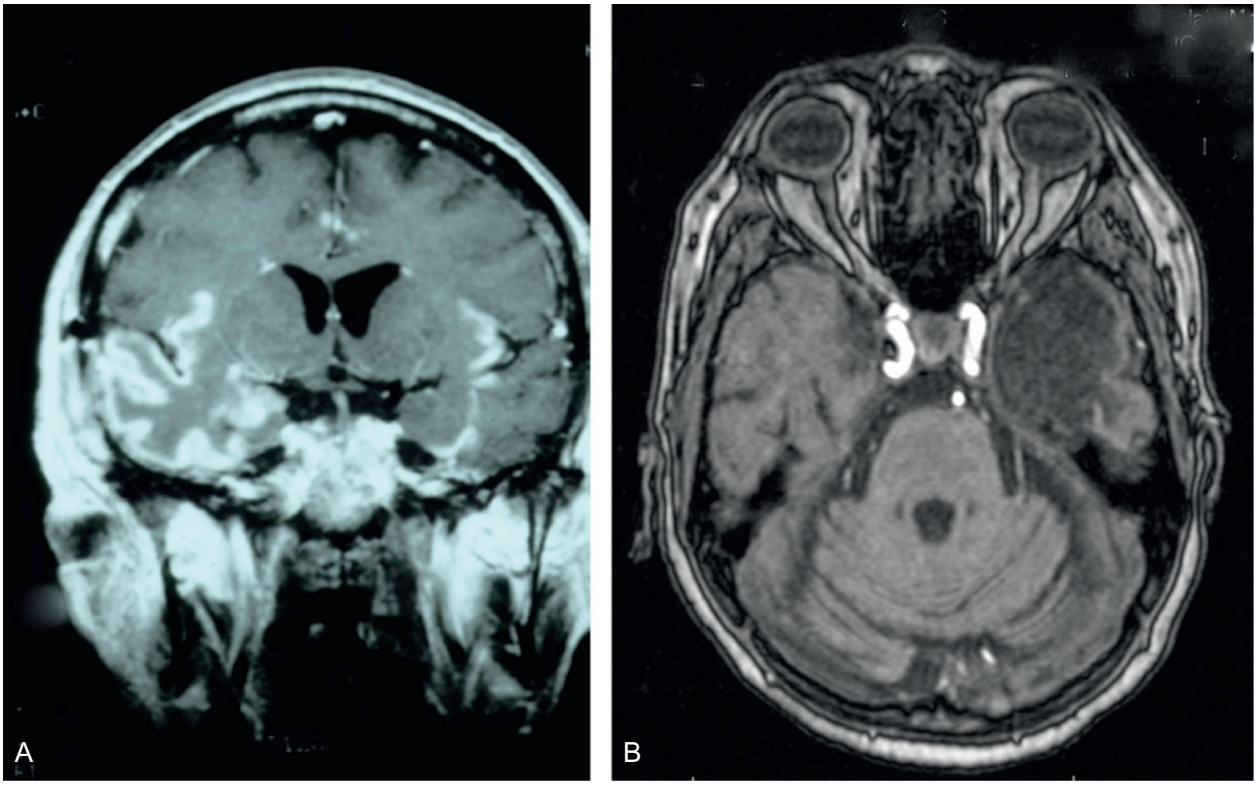


**FIGURE 43-1** ■ **A**, Magnetic resonance imaging (MRI) of herpes simplex virus encephalitis. T2-weighted fluid-attenuated inversion recovery (FLAIR) sequence showing increased signal in right temporal lobe, insula, and orbitofrontal cortex. There is also involvement of the left insula. **B**, T1-weighted MRI 6 months after infection, showing massive destruction of the left temporal lobe.

A specific diagnosis of herpes simplex encephalitis is made by amplification of viral DNA from CSF using PCR. Overall diagnostic accuracy of PCR in patients with brain biopsy-proven HSV encephalitis is 98 percent.[33,75] In some patients, however, PCR may be negative at presentation due to low copy numbers of DNA in the CSF; in these cases, repeat CSF PCR after 4 to 7 days is usually positive.[76] Diagnostic yield of PCR falls to 21 percent in patients after 2 weeks of antiviral treatment.[75] Determination of acute antibody titers is not of value in the acute diagnosis of HSV encephalitis; however, comparison of acute and convalescent serum titers may be useful retrospectively and, in rare cases, provides diagnostic information when PCR was negative or when CSF was not obtained initially.[77] Retrospective serologic confirmation of herpes simplex encephalitis may also be made by determining serum:CSF ratios of HSV-specific antibodies to identify intrathecal antibody production.

Herpes simplex encephalitis is treated with intravenous acyclovir (Table 43-3), which inhibits HSV synthesis by competing with deoxyguanosine triphosphate as a substrate for DNA polymerase and causing DNA chain termination.[67] The drug is converted into its pharmacologically active monophosphate form by virally encoded thymidine kinase and thus only becomes active in infected cells.[67] Acyclovir is administered intravenously at 10 mg/kg body weight every 8 hours for 21 days. Complications of acyclovir therapy are usually mild. The major concern is nephrotoxicity due to deposition of drug crystals, which can be avoided by careful hydration. Although acyclovir resistance has been reported in other conditions, acyclovir-resistant herpes simplex encephalitis is rare.[78,79]

Prior to the introduction of acyclovir, overall mortality from herpes simplex encephalitis was over 70 percent, with mortality approaching 100 percent in patients over the age of 40 years.[80] The advent of acyclovir has reduced the overall mortality to 28 percent, and instituting antiviral therapy at presentation when the diagnosis is suspected has reduced 1-year mortality to 14 percent.[81] Patients who are

alert or lethargic when treatment is initiated have an excellent likelihood of survival, but mortality in patients treated when semicomatose or comatose still approaches 25 percent.[63] The likelihood of death or serious neurologic impairment is greater when the patient is elderly, initiation of acyclovir treatment is delayed, or evidence of extensive CNS involvement is present on initial neuroimaging. Even with prompt initiation of treatment, up to two-thirds of patients are left with permanent neurologic deficits including epilepsy, impaired cognition, aphasia, anterograde amnesia, or motor deficits.[63,81,82] Neurologic improvement takes place over months, and some patients who are severely impaired immediately after treatment have a good functional recovery over time.

## Varicella Zoster Virus

VZV, like HSV, is an enveloped double-stranded DNA virus that is worldwide in distribution. The virus is acquired by the respiratory route and replicates initially in tonsillar tissue to produce a viremia followed by seeding of multiple tissues including skin. Primary infection classically results in chicken pox, but individuals may also be infected acutely with little or no rash. Virus is then taken up by nerves supplying infected skin or other tissues and is transported to sensory ganglia, establishing lifelong persistence.[83] VZV thus differs from HSV in that it produces an acute viremic illness and only then persists secondarily and spreads within neurons. Viral latency in sensory ganglia is heavily controlled by T-cell–mediated immunity, and reactivation of infection may occur with waning of immune response during old age or in states of compromised host immunity.[83]

Cutaneous zoster (shingles), the most common manifestation of reactivated VZV infection, affects roughly 1 million adults in the United States annually.[83] The likelihood of developing zoster is higher in individuals who acquired chicken pox during infancy.[83] Most cases of zoster occur in patients older than 50 years. Neuropathologic correlates of cutaneous zoster include focal meningeal inflammation, necrosis of associated neurons, and degeneration of motor and sensory nerve roots in the involved area.[83] Cutaneous zoster may develop without known precipitating cause or may be triggered by systemic cancer, spinal irradiation, HIV infection or other immunosuppressed states, or spinal trauma.[83] Many patients experience a sharp, burning discomfort in a dermatomal distribution for 2 to 5 days before onset of the rash. A localized redness with red macules then develops and progresses to vesicles in the same dermatomal pattern as the pain.[83] Additional vesicles may appear over the next 2 to 7 days. The distribution of herpes zoster is usually unilateral and involves a single dermatome. The rash involves the trunk in 50 percent, the head in 20 percent, the arms in 15 percent, and the legs in 15 percent of cases. Over the next month, the dermatomal pain slowly disappears, leaving residual hypoalgesia or hyperalgesia. Occasional patients may present with dermatomal pain without rash, termed *zoster sine herpete*.[83] Treatment with oral valacyclovir (1 gram three times daily for 7 to 10 days) shortens the duration of rash and acute pain.[83,84] Recommended treatment in immunocompromised individuals is 5 to 10 mg/kg of usually intravenous acyclovir given three times daily for 5 to 7 days.[83]

Postherpetic neuralgia (PHN)—pain occurring in the distribution of the original rash and persisting for longer than 3 months—occurs in 9 to 14 percent of patients following shingles and increases with advancing age.[85] The pain may be relentless, episodic, or paroxysmal and may be elicited by cutaneous contact or stimulation. Postherpetic itch is also common. The live attenuated Oka strain VZV vaccine has been shown to reduce the incidence of cutaneous zoster in healthy individuals by 50 percent and the incidence of postherpetic neuralgia by 67 percent.[86] To what extent antiviral treatment of acute zoster lessens the likelihood of PHN has not been clearly demonstrated.[84] Symptomatic treatment of PHN is often disappointing. Tricyclic antidepressants, gabapentin, pregabalin, controlled-release morphine sulfate, oxycodone, and lidocaine patches have moderate to high efficacy, but are sometimes completely unhelpful.[87] Aspirin in cream or ointment form, topical capsaicin, and intrathecal methylprednisolone are less effective, limited by side effects, or both.[87] For most of these medications, treatment involves escalating dosages of medication until pain relief is achieved or unacceptable side effects occur.

VZV may invade the CNS during primary or reactivated infection and, in reactivated infection, may do so in the absence of cutaneous zoster.[88] Prior to the advent of PCR testing, CNS invasion by VZV was considered unusual. It is now realized, however, that CNS involvement by VZV is much more

frequent; in one series VZV was found to be the most common agent identified in viral meningitis and encephalitis (29% of isolates).[88] Studies from France and England have identified the agent in 5 to 15 percent of encephalitis isolates.[89,90] The virus is now known to cause a wide range of syndromes of neurologic injury involving not only brain and spinal cord but also cranial nerves and brainstem or peripheral ganglia.[88] CNS invasion in reactivated VZV infection occurs following spread of virus from trigeminal or spinal sensory ganglia; in this process, the virus may produce ophthalmic involvement or may produce Ramsay–Hunt syndrome, in which infection of the tympanic membrane and surrounding structures is accompanied by facial nerve palsy.[88] Of greater concern and unlike HSV, VZV may infect both large and small vessels supplying the brain or spinal cord, at times followed by spread of the infection into neural parenchyma.[88,91] Involvement of vessels may produce focal or multifocal ischemic injury or may cause vessel-wall necrosis with resulting arterial dissection, aneurysm formation, or hemorrhage within the subarachnoid space or brain parenchyma.[88] The classic presentation of VZV vasculopathy is herpes zoster ophthalmicus, in which there is initial superficial zoster in the distribution of the ophthalmic branch of the trigeminal nerve followed days to weeks later by stroke in the territory of the carotid or middle cerebral artery.[88] However, VZV vasculitis may occur with or without preceding cutaneous zoster or herpes zoster ophthalmicus or oticus and may involve virtually any vascular territory within the brain or spinal cord. VZV vasculitis may be significantly more severe in HIV infection or other immunosuppressed states, and immunosuppressed patients may develop a more slowly progressive CNS vasculopathy or myelitis.[88]

CSF in acute VZV CNS infection may reveal a mononuclear pleocytosis, at times with red blood cells and sometimes hypoglychorrhachia.[33,88] VZV encephalitis in the setting of acute VZV infection may be diagnosed by PCR; however, the reaction rapidly becomes negative, so a negative PCR does not exclude the diagnosis.[88] Diagnosis of VZV vasculopathy in the setting of reactivated infection may also be made by the presence of elevated titers of anti-VZV IgG antibodies in CSF.[83,88] Oligoclonal bands are commonly present and are reactive with VZV proteins.[88]

Treatment of VZV encephalitis is with acyclovir, 10 mg/kg, usually intravenously, every 8 hours for a minimum of 14 days. Oral prednisone, 1 mg/kg, given daily for 5 days, may be used to treat the inflammatory component of the vasculitis; more prolonged treatment is avoided to prevent steroid-induced immunosuppression.[88]

## West Nile Virus

WNV, a single-stranded RNA flavivirus virus, is currently the most common cause of epidemic encephalitis in the United States.[92,93] The virus infects multiple species of animals and birds, in particular crows, jays, magpies, and ravens. *Culex* species mosquitoes, predominantly *C. tarsalis* and *C. pipiens*, are the primary vectors for human infection. WNV produces infection predominantly in the summer and early autumn, when mosquitoes are most active. As of December 2012, 5,387 cases of WNV infection had been reported to the CDC for the year, with 243 deaths (Fig. 43-2). Of these cases, 2,734 (51%) represented neuroinvasive disease (Fig. 43-3). In most individuals, WNV infection is silent or produces only trivial symptoms. In 20 percent of infected patients, symptomatic West Nile fever develops, characterized by malaise, fatigue, anorexia, headache, nausea, vomiting, myalgia, fever, eye pain, and a nonspecific maculopapular rash.[92] The illness usually lasts less than 7 days, although a minority of patients may remain symptomatic for as long as 6 weeks. [92]

Less than 1 percent of infected patients develop neuroinvasive disease, which is more common in the elderly and is especially severe in immunosuppressed patients or transplant recipients.[92,94] West Nile encephalitis typically presents with fever, headache, and altered mental state, stupor, or coma. Other signs of parenchymal involvement may include cerebellar ataxia or movement disorders including tremor, myoclonus, and parkinsonian symptoms.[94,95] WNV infection may also result in a syndrome of acute flaccid paralysis similar to that seen with polio virus.[94,95] A minority of patients develop chorioretinitis or vitritis.[96] CSF in neuroinvasive WNV infection typically shows a mild elevation in opening pressure, lymphocytic pleocytosis, mild elevation of protein level, and normal glucose concentration. Cell count is usually 50 to 260 cells/mm$^3$ but may be as high as 2,600 and may be heavily polymorphonuclear, in particular at presentation.[33,95] In one series, cell count was normal in 20 percent of patients.[97] Occasional patients have low serum sodium levels indicative of the

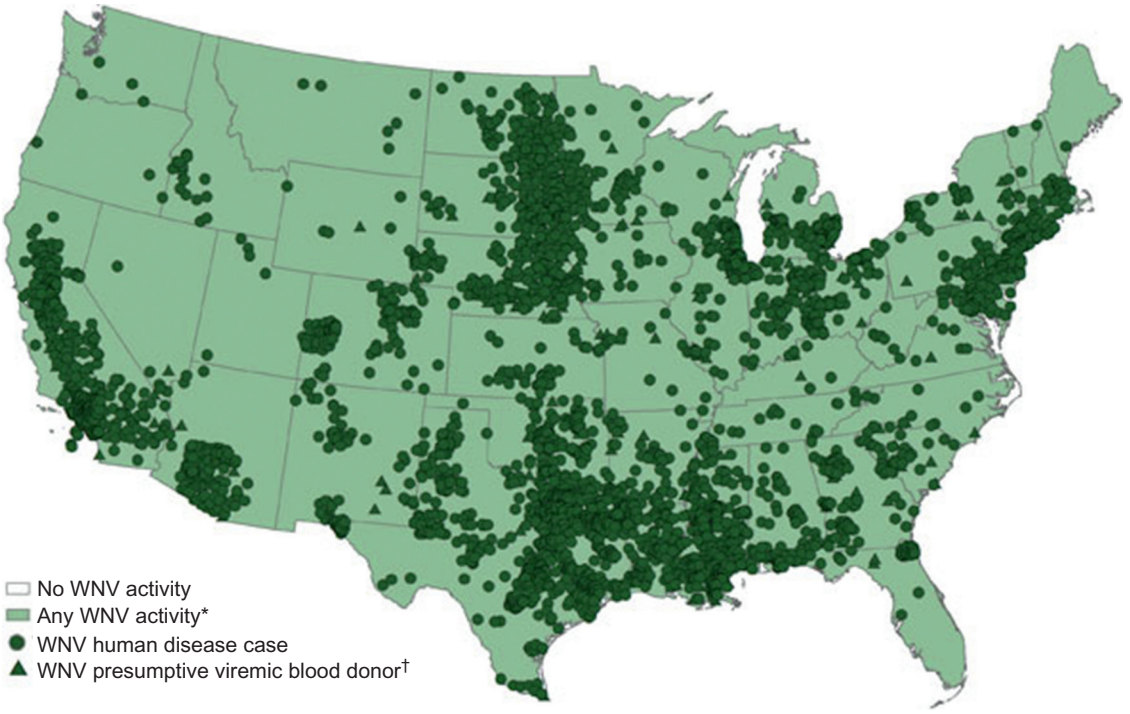


**FIGURE 43-2** ■ Distribution of West Nile virus in the United States showing cases of infection and WNV identified in blood donors, 2012. (From the US Centers for Disease Control and Prevention.)

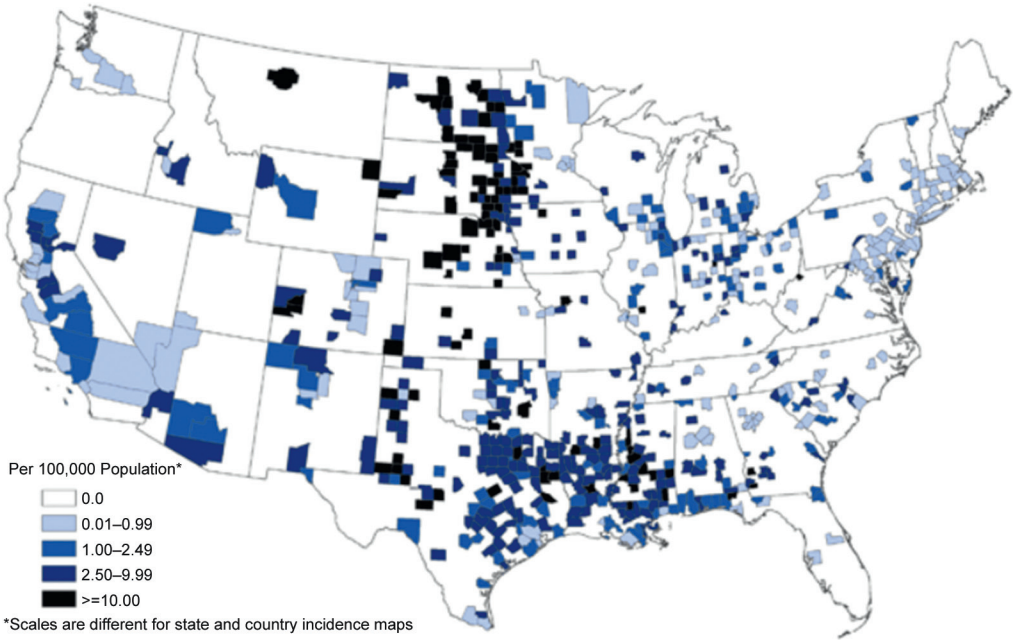


**FIGURE 43-3** ■ Distribution of cases of West Nile neuroinvasive disease in the United States, 2012. (From the US Centers for Disease Control and Prevention.)

syndrome of inappropriate antidiuretic hormone secretion (SIADH). MRI is often normal, although a minority of patients have areas of increased signal on T2-weighted and fluid-attenuated inversion recovery (FLAIR) sequences in the substantia nigra, basal ganglia, and thalamus.[98,99] Patients with WNV-induced flaccid paralysis may show increased signal in the anterior horns of the spinal cord.[99] A single,

acute, cerebrospinal fluid specimen positive for WNV-specific IgM antibodies is diagnostic of WNV neuroinvasive disease.[98] PCR is less reliable. Paired sera positive for WNV-specific IgM antibodies (a fourfold or greater rise in titer from the "acute" serum, obtained 0 to 7 days after symptom onset, and the "convalescent" serum, obtained 14 to 21 days after symptom onset) also provide serologic confirmation.

Treatment of WNV encephalitis is currently supportive. Human intravenous IgG containing high titers against WNV has been used experimentally but is not available routinely.[100] Prognosis for recovery after WNV meningitis or encephalitis is good, although recovery may be extremely prolonged. The likelihood of complete recovery after West Nile flaccid paralysis is poor.[95,98]

## Other Arthropod-Borne Viruses

Several arthropod-borne viruses other than WNV may infect humans and cause neurologic disease. All but two of the agents occurring in the United States and Canada are carried by mosquitoes, with rates of infection that peak in mid-summer through early autumn.[101] Colorado tick fever virus and Powassan virus are carried by ticks, and infections caused by these agents tend to occur in late spring and early summer.[31] Prior to the advent of WNV in the United States, St. Louis encephalitis was the most common arthropod-borne cause of encephalitis. Eastern equine encephalitis, although rare, remains the most deadly.[101] No human case of Western equine encephalitis virus infection has been reported since 1994.

St. Louis encephalitis virus, like WNV, is a mosquito-borne virus that is a member of the family Flaviviridae. Cases of St. Louis encephalitis have been reported from almost every area of the United States, but the majority occur in the central Midwest and Texas. The virus is usually seen with scattered rural infections but may also cause urban epidemics. St. Louis encephalitis resembles neuroinvasive West Nile disease but rarely if ever produces a flaccid, polio-like illness.[101] The two diseases are both more severe in the elderly and they have similar CSF findings. Diagnosis of St. Louis encephalitis is either by CSF IgM, by a rise in antibody titers, or both.

Eastern equine encephalitis virus is an agent of wading and migratory birds that is found predominantly along the Atlantic seaboard, the Gulf of Mexico, Indiana, Michigan, and Wisconsin.[101,102] Although the virus does not usually produce severe infection in its natural hosts, it can infect horses and may cause epizootic outbreaks of infection in flocks of turkeys or in exotic or game farm birds. Eastern equine encephalitis is rare in humans, with approximately 5 cases occurring annually.[101,102] The virus is most apt to cause encephalitis in infants and in individuals over 55 years of age. A prodromal illness which may include fever, headache, and abdominal pain frequently occurs.[103] Onset of encephalitis may be fulminant: nearly 70 percent of patients present in stupor or coma, and presentation only with meningeal symptoms is uncommon.[103] Corticospinal or extrapyramidal signs are often present, and the illness may be complicated by focal or generalized seizures. Overall mortality is around 35 percent, with one-third of survivors suffering significant neurologic impairment.[103]

Two groups of arthropod-borne infections occur outside the United States and should be considered when evaluating patients with encephalitis coming from endemic areas (Table 43-1). Tick-borne encephalitides relate to multiple viral agents existing throughout Eurasia, with greatest prevalence in northern Europe and Asia.[104] Japanese encephalitis virus, endemic in eastern and southeastern Asia, results in 15,000 deaths annually.[18] Both tick-borne encephalitis and Japanese encephalitis may present with findings similar to those produced by WNV, including flaccid paralysis.[17,18]

## Rabies Virus

Rabies virus is an unenveloped single-stranded RNA virus that is a member of the Lyssavirus genus of the family Rhabdoviridae. Rabies virus exists worldwide and predominant reservoirs are bats, skunks, foxes, and raccoons in developed countries where there is mandatory rabies vaccination for dogs.[105] Most—but not all—human cases acquired in the United States have resulted from bat bites.[105] In less developed countries, dogs are the source of most human cases; other animals including infected monkeys, sometimes kept as pets, may account for a minority of cases.[105,106]

Rabies virus is typically acquired through the bite of an infected animal; rare cases have occurred following exposure to aerosolized rabies virus or after inadvertent transplantation of infected tissue.[105,107–109] The virus may remain latent at the

site of an infected bite for 6 or more years before the onset of neurologic disease.[110] Unlike most other viruses causing encephalitis, rabies is specifically neurotropic: the virus enters peripheral nerve fibers at the site of inoculation, is carried proximally by reverse axoplasmic flow, and progressively infects the CNS through neuron-to-neuron spread (the centripetal phase of infection). The virus then spreads outward within nerves (the centrifugal phase of infection) to involve multiple tissues including salivary glands, corneas, and the heart. In animals, this centrifugal phase of infection, with shedding of salivary virus, may occur prior to clinical disease.[106,111,112]

Rabies classically begins with dysesthesias at the site of the bite, followed by progressive neurologic involvement with a clinical picture (termed "furious rabies") of agitated delirium, stimulus-sensitive laryngeal spasm with hydrophobia, prolonged inspiratory spasm, and progression to coma and death.[105] Rabies may also present as a more classic encephalitis with stupor and coma ("dumb rabies"), or as an ascending paralysis, similar to Guillain–Barré syndrome, followed by signs of CNS involvement.[105]

Rabies should be considered in appropriate clinical settings, in particular when there is a history of animal bite or of recent or remote travel to, or residence in, countries where rabies is a significant health problem. There may no history of bite, however; the minute punctures caused by bat bites may go unnoticed, or, alternatively, the animal bite may have occurred long enough ago to have been forgotten.[110,113] MRI may show ill-defined, mild T2-hyperintensities in the brainstem and hippocampus; early in the disease these lesions may fail to enhance with gadolinium.[114] Specific diagnosis of rabies is made by identifying rabies antigen in nuchal biopsy or by PCR from saliva or CSF.

Management of rabies consists of two strategies: prevention of clinical disease by immunotherapy and immunization at the time of the bite, and supportive treatment of clinical rabies. Preventive therapy involves washing the area of the bite thoroughly, infiltrating the area with rabies virus-specific immunoglobulin, and administration of diploid cell rabies vaccine.[105] This treatment, when administered soon after the bite, is highly effective in preventing clinical rabies.[105] Once clinical rabies develops, the patient's course may be influenced by a wide variety of CNS, autonomic, and systemic complications.[115] Rabies is almost invariably fatal; fewer than 10 patients are known to have survived, and of these, only one made a full recovery.[116] Of interest, a handful of patients known to have received infected corneal tissue or organs failed to develop clinical rabies.[107,108] One patient surviving rabies was treated with midozalam and ketamine, but the use of these agents in other cases has been unsuccessful.[117,118]

## Other Viruses

Although enteroviruses are most commonly associated with viral meningitis, they may also cause encephalitis and rarely may result in paralytic disease. Enterovirus 71, a cause of hand, foot, and mouth disease and herpangina in children, may cause encephalitis with involvement of the brainstem or, less frequently, the cortex, cerebellum, or spinal ventral roots.[119] In some patients, MRI abnormalities are detected on diffusion-weighted or FLAIR sequences.[120].

The mouse arenavirus LCMV usually causes meningitis but may occasionally cause encephalitis.[121] Infection in children and adults is rarely fatal, but clinical recovery and return of CSF to normal can be prolonged. LCMV meningoencephalitis is one of the few viral CNS infections that may cause hypoglychorrhachia.[33] Parvovirus B19, the agent of the childhood condition erythema infectiosum (fifth disease), is an uncommon cause of encephalitis in both children and adults.[122] Human herpesviruses type 6 (HHV-6, associated with roseola infantum) and type 7 (HHV-7) have been associated with seizures or, rarely, encephalopathy in early childhood.[123] In one study, HHV-6 was detected in the CSF of 40 percent of patients with encephalitis of otherwise undetermined cause.[124] Important viruses to consider in patients exposed in Southeast Asia include Japanese encephalitis virus, and the bat henipavirus, Nipah virus (Thailand) (Table 43-1).[18,125]

Epstein–Barr virus (EBV), the agent of infectious mononucleosis, has been associated with a wide variety of infectious and postinfectious neurologic disorders in both immunologically normal and immunocompromised patients.[126–128] The association of EBV with specific disease presentations, however, is made difficult by two properties of the virus. First, EBV infects and can remain latent in B lymphocytes for many years. For this reason, PCR

amplification of EBV DNA from CSF in patients with suspected CNS infection may simply indicate the presence of the virus in lymphocytes rather than proving it as a causative agent. Second, like HSV, EBV can reactivate under situations of physiologic stress, so that a rise in antibody titer in the setting of acute illness may or may not be indicative of disease causation.

## Viral Encephalitis in Immunocompromised Patients

Impairment of host B- or T-cell response, whether because of congenital immunodeficiency, HIV infection, or iatrogenic immunosuppression, may result in infection with unusual agents or produce atypical infection by more common viruses. Because control of enteroviral infection depends heavily on antibody, enteroviruses have been associated with chronic meningitis and progressive encephalitis in children with X-linked hypogammaglobulinemia or X-linked hyper-IgM syndrome; these patients exhibit ongoing presence of enteroviral RNA in CSF and may show continued enterovirus excretion in stool.[129,130] Chronic enteroviral meningoencephalitis has also been reported in patients treated with the anti-CD20 monoclonal agent rituximab.[131,132] Impairment of T-cell immune response, as in HIV-infected or immunosuppressed patients, may lead to infection with less commonly pathogenic agents such as JC virus, cytomegalovirus, adenovirus, HHV-6, or HHV-7, or may result in prolonged or atypical presentations of infections with HSV or VZV.[68,133–140] HSV and VZV are treatable with acyclovir, as is the case in immunologically intact patients. Treatment of cytomegalovirus CNS infections has usually involved gancyclovir, foscarnet, or a combination of both agents; cidofovir has been used as a second choice (Table 43-3).[141] Cases of encephalitis associated with HHV-6 have been treated with gancyclovir, foscarnet, or a combination of the two drugs.[140,142] CNS infections in immunocompromised patients may involve common infections as well as those caused by unusual organisms. Especially in patients infected with HIV, more than one infective agent may be present.

## Progressive Multifocal Leukoencephalopathy

PML is an uncommon opportunistic infection of immunocompromised patients. Its causative agent, the human polyomavirus JCV, affects over 50 percent of individuals worldwide by late adult life.[2] Acute viral infection is not known to cause symptomatic illness, but the virus establishes protracted infection of renal tubular epithelial cells and other tissues, possibly including the brain.[2,143] In PML, JCV produces lytic infection of oligodendrocytes, causing areas of demyelination; astrocytes are also infected in some cases.[2] PML was initially described as a rare disorder of patients with hematologic malignancies and in immunosuppressed patients. In untreated AIDS, however, 4 percent of patients will die of PML, which can be the presenting feature.[144] In recent years, PML has become increasingly frequent in patients treated with the more aggressive immunosuppressive regimens now used for collagen-vascular diseases and solid organ or hematopoietic stem cell transplantation.[145] PML has also become a significant—although infrequent—complication of treatment with natalizumab and other monoclonal immunosuppressive agents such as rituximab, efalizumab, alemtuzumab, and TNF-α inhibitors.[146] The course of PML is that of the progressive development of multifocal neurologic deficits that may involve motor control, sensation, speech, vision, or

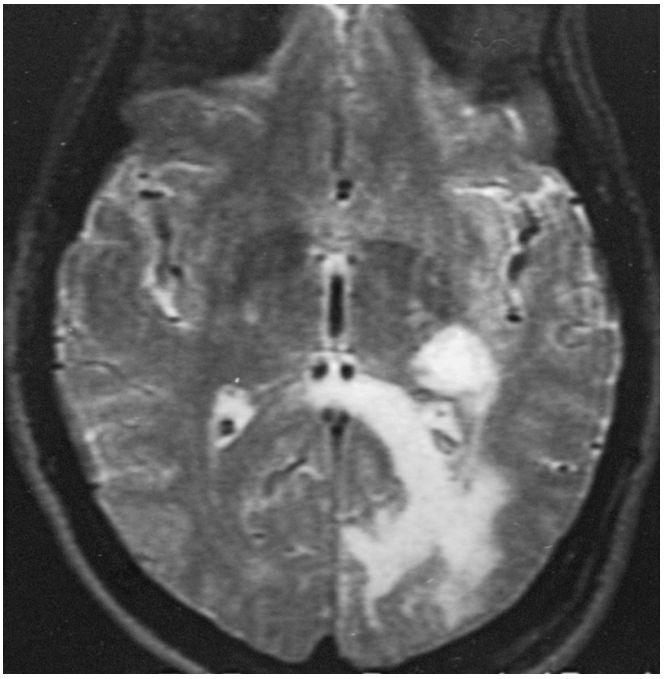

**FIGURE 43-4** ■ Progressive multifocal leukoencephalopathy (PML): axial T2-weighted MRI showing multifocal involvement of cerebral white matter.

cognition. Occasional patients develop cerebellar or brainstem signs, but clinical involvement of the spinal cord is virtually never present. Rarely AIDS patients have been reported to develop JCV infection of cerebellar granule or other neurons.[147]

PML is presumptively diagnosed by MRI, which typically shows multifocal white matter lesions in the cerebrum or, less often, brainstem or cerebellum (Fig. 43-4); PML lesions are often not apparent on CT. Although PML lesions usually do not enhance, gadolinium enhancement may occur in AIDS- and natalizumab-associated PML.[2,148] A definitive diagnosis of PML is made by PCR amplification of JCV DNA from the CSF.[2,33] Sensitivity of PCR in early studies approached 80 to 90 percent.[149] However in HIV patients treated with antiretroviral therapy, PCR is positive in only 58 percent of cases[150].

There is no proven treatment for PML. Cytosine arabinoside has been reported to have limited efficacy in non-AIDS patients only.[151] Cidofovir, mefloquine, and mirtazapine have not been effective in controlled trials. Restoration of host immune function with antiretroviral therapy in AIDS patients may lead to stabilization or improvement, as may reduction of immunosuppressive therapy in transplant recipients or other patients receiving these drugs.[2] Treatment of PML in cases associated with natalizumab involves withdrawal of that agent and plasma exchange or immunoabsorption to remove natalizumab from the circulation; this approach has not been used with other monoclonal agents.[152] Improvement of immune status may cause a fulminant immune reconstitution inflammatory syndrome (IRIS) (Fig. 43-5).[153]

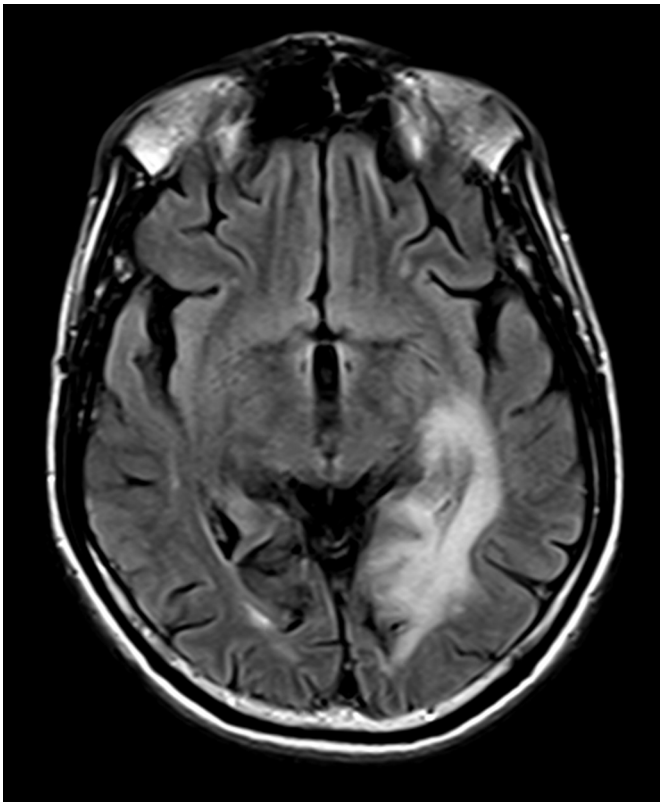

**FIGURE 43-5** ■ FLAIR MRI showing PML with immune reconstitution inflammatory syndrome (IRIS) in a patient with human immunodeficiency virus (HIV) following institution of antiretroviral therapy. There is edema in and surrounding a lesion within the left posterior cerebral white matter.

## Approach to Patients with Viral Encephalitis

Viral encephalitis should be suspected in any patient presenting with signs suggesting acute involvement of the brain parenchyma, especially in individuals with fever and alteration of consciousness.[154] Meningeal signs may or may not be present. Signs indicating temporal lobe involvement suggest herpes simplex encephalitis, but other viral encephalitides may have a similar presentation as may occasional bacterial infections or autoimmune encephalitis from antineuronal antibodies. Patients often have an elevated peripheral white blood cell count, but signs of systemic infection may also be absent. Diagnosis relies heavily on clinical findings, MRI, and the results of CSF analysis. MRI in herpes simplex encephalitis characteristically shows abnormalities of one or both temporal lobes, at times with involvement of the orbitofrontal cortex, insula, or cingulate gyrus. Similar findings, however, may be seen in other potentially treatable conditions including neurosyphilis and autoimmune encephalitis.[155,156] The CSF in viral encephalitis typically shows significant pleocytosis and an elevated protein but normal glucose concentration. The pleocytosis is commonly lymphocytic, but is neutrophilic in rare cases.[33] A depressed CSF glucose level, while not typical, has been described in VZV, LCMV, mumps, and HSV-2 infections.[33] CSF should be sent for PCR for HSV, and consideration should be given to ordering PCR for other agents. Detection of virus-specific IgM in CSF is more sensitive than PCR for the diagnosis of WNV and may be useful in other arboviral infections where PCR is negative. Similarly, elevated CSF titers of IgG may be more sensitive than PCR

in encephalitis due to reactivated VZV. Lumbar puncture may need to be deferred when there is evidence on examination, CT, or MRI of increased intracranial pressure or mass lesion.

Acyclovir should be initiated presumptively where viral encephalitis is strongly suspected and should be continued until PCR has been shown to be negative for HSV.[154] Because the initial PCR in herpes simplex encephalitis may rarely not be positive, acyclovir should be continued in seriously ill patients until a second CSF PCR, obtained 3 to 7 days later, is also negative.[33,76] Acyclovir should also be continued if VZV is detected by CSF PCR or serology. Gancyclovir should be instituted if CMV or HHV-6 infection is diagnosed; gancyclovir may be supplemented with foscarnet.[154] Antibacterials should be initiated if bacterial meningitis, brain abscess, or parameningeal infection is suspected.

Treatment of encephalitis is otherwise supportive.[154] Seizures may require intravenous phenytoin, levetiracetam, or other agents. Cerebral edema is a major concern in severe encephalitis; dexamethasone (10 mg orally or intravenously followed by 4 mg every 6 hours), mannitol, and hyperventilation have all been used in individual cases, but their efficacy is unproven. Decompressive craniectomy has resulted in patient survival with good initial outcome in a few cases of herpes simplex encephalitis complicated by fulminant cerebral edema.[157] Cerebral salt wasting or SIADH may require treatment with hydration and sodium supplementation, or fluid restriction, respectively. Attention must be given to preventing complications of severe illness such as pneumonia, deep venous thrombosis, and decubitus ulcers. Recovery in viral encephalitis may be extremely prolonged, with the full extent of recovery not realized for many months.

## PRION DISEASES

Prion diseases represent a group of rare disorders including Creutzfeldt–Jakob disease (CJD), new variant CJD (vCJD), Gerstmann–Straussler–Schenker disease, familial fatal insomnia, kuru, and variably protease–sensitive prionopathy.[158,159] Prion diseases of animals include scrapie of sheep (the prototype for this group of conditions), bovine spongiform encephalopathy, wasting disease of deer and elk, and transmissible mink encephalopathy.[159] Prion diseases are not caused by viruses but rather by a self-replicating isoform of a normal intracellular sialoglycoprotein. The normal cellular protein is termed "PrP(c)" and the self-replicating protein causing disease is referred to as "PrP(Sc)." PrP(Sc) does not contain nucleic acid, its presence does not elicit an immune response, and it is not inactivated by many agents normally used for decontamination.[159,160] Interaction of PrP(Sc) with PrP(c) appears to be essential for disease.[159,160] Except in familial cases, PrP(Sc) is thought to arise from a spontaneous mutation in PrP(c). Several different subtypes of CJD have been associated with homozygosity or heterozygosity of methionine or valine at codon 129 of the *PrP* gene, differences in variation in glycosylation patterns of PrP(Sc), and patterns of electrophoretic mobility of PrP(Sc) after proteinase K digestion.[159,160] Prion diseases have repeatedly been shown to be transmissible through PrP(Sc)-contaminated material, including PrP(Sc)-containing human grafts of dura mater or other tissues, contaminated electrodes used for intracerebral recording, and human pituitary-derived growth hormone. In the case of vCJD, transmission has occurred predominantly through ingestion of contaminated beef, but it has also occurred through blood transfusion.[159,161]

The most common human prion disease is CJD, which occurs worldwide with 1 to 2 cases per million population per year.[159] The average age at onset is 60 years, with an equal gender distribution. Most cases are sporadic (sCJD), but 12 percent cluster in families.[159] The condition affects the CNS only, without systemic symptoms. The onset of CJD is typically with subtle changes in cognition and personality changes that may include apathy, irritability, depression, or paranoia.[159] Occasional patients present with ataxia, spasticity, or visual complaints. These initial symptoms are followed by progressive dementia, often involving parietal lobe symptoms and, at times, aphasia. As the disease progresses, over 85 percent of patients develop stimulus-sensitive myoclonic jerks that tend to disappear as the disease progresses to profound dementia and a vegetative state. CJD is untreatable, and its course is relentlessly progressive, resulting in death within 6 months to 2 years.[159]

The diagnosis of CJD is made on the basis of clinical presentation, EEG, MRI, and evaluation of CSF for the proteins 14-3-3, tau, and neuron-specific enolase. The yield of these studies, however, varies among the different subtypes of CJD.[162] CSF cell count and protein levels are usually normal, such that significant pleocytosis suggests strongly that

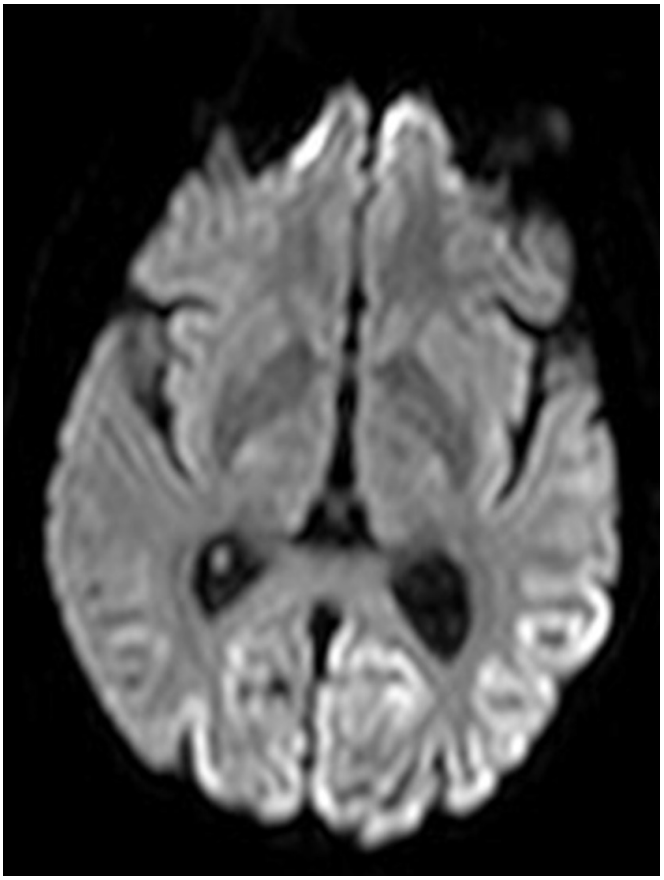

**FIGURE 43-6** ■ Creutzfeld–Jakob disease. Diffusion-weighted MRI image showing restricted diffusion within the cortical ribbon of the posterior hemispheres bilaterally.

the diagnosis is incorrect. The EEG initially may show only mild slowing but subsequently becomes strikingly abnormal, with repetitive, periodic, stereotyped, bilaterally synchronous sharp waves that usually occur at a frequency of 1 to 2 per second and are often associated with myoclonic jerks.[163,164] This periodic EEG activity may give way to generalized slowing late in the disease.[163,164] MRI has become the major diagnostic test in suspected CJD and typically shows foci of increased signal in the putamen, caudate, thalamus, and gray matter of the cerebral cortex. These findings are most prominent on diffusion-weighted sequences and, with less sensitivity, FLAIR sequences (Fig. 43-6); MRI changes are not reliably present in familial CJD.[165] Detection of 14-3-3 and tau proteins as well as neuron-specific enolase in CSF provides supportive evidence for the presence of CJD in patients with clinical, EEG, or MRI markers of the disease.[166] None of these CSF markers is specific for CJD, however, and their use in unselected patients may lead to erroneous diagnosis.[166] Postmortem diagnosis can be made by the characteristic brain histopathology and staining with specific prion antibodies or by demonstration of prions from homogenized brain using immunodiagnostic procedures.

In general, animal prion diseases such as scrapie have not been thought transmissible to humans. However, the appearance in Britain of bovine spongiform encephalopathy (BSE; mad cow disease), a prion disease, was followed by an outbreak of human cases of vCJD, which were presumably acquired by ingestion of contaminated beef.[167] Human cases peaked in 2000 after extensive culling of affected cattle.[159] Cases of vCJD have occurred primarily in younger individuals and have tended to present with psychiatric signs, with dementia and painful sensory symptoms occurring commonly. In contrast to the general population, all patients studied with vCJD have been homozygous for methionine at codon 129 of the *PrP* gene. Unlike sporadic CJD, the EEG in vCJD only rarely shows periodic activity. MRI typically shows increased signal in the pulvinar on diffusion-weighted imaging and FLAIR sequences.[168] Survival in vCJD may be more prolonged compared with sCJD.[159,160,167] Unlike sCJD, there have been cases of vCJD transmitted by blood transfusion.[159]

## POSTINFECTIOUS COMPLICATIONS OF CNS VIRAL INFECTION

The interaction of an infective agent with the host immune system usually results in containment of the agent and eradication of disease. In some instances, however, systemic or CNS viral infections may induce an immune response that reacts not only with the infecting agent but also with components of nervous tissue. This interaction may result in postinfectious encephalomyelitis, acute hemorrhagic leukoencephalitis, transverse myelitis, or injury to the peripheral nervous system resulting in peripheral nerve involvement including plexopathy and the Guillain–Barré syndrome (see Chapter 59). Rarely, optic neuritis may also occur as a postinfectious condition.

### Postinfectious Encephalomyelitis

Postinfectious encephalomyelitis is defined as an acute, monophasic demyelinating illness occurring

**TABLE 43-5 ■ Major Viruses Associated With Postinfectious Neurologic Complications**

| Postinfectious Encephalomyelitis | Transverse Myelitis | Cerebellar Ataxia | Guillain–Barré Syndrome |
|---|---|---|---|
| Varicella zoster virus | Measles virus | Varicella zoster virus | Measles virus |
| Measles virus | Mumps virus | Measles virus | Epstein–Barr virus |
| Mumps virus | Varicella zoster virus | Epstein–Barr virus | Cytomegalovirus |
| Rubella virus | Rubella virus | Influenza virus | Influenza virus |
| Influenza virus | Influenza virus | | Varicella zoster virus |
| Enteroviruses | Epstein–Barr virus | | HIV |
| Coronaviruses | Enteroviruses | | Dengue virus |
| HIV | HIV | | |
| HTLV-1 | HTLV-1 | | |
| Hepatitis A,B,C,E | Hepatitis A,B,C | | |
| Herpes simplex virus | Herpes simplex virus | | |
| Epstein–Barr virus | Human herpesvirus 6 | | |
| Cytomegalovirus | Hantavirus | | |
| Human herpesvirus 6 | Dengue virus | | |
| Hantavirus (puumala virus) | | | |
| Dengue virus | | | |
| Smallpox (historical) | | | |

HIV, human immunodeficiency virus; HTLV, human T-lymphotropic virus.

within 2 to 4 weeks of a viral or other infection (Table 43-5). The condition bears strong similarity to two other conditions: postvaccination encephalomyelitis, which follows immunization (see Chapter 48), and the experimental autoimmune demyelinating disease, experimental allergic encephalomyelitis (EAE).[169,170] Postinfectious encephalomyelitis and postvaccinal encephalomyelitis have been grouped under the common term *acute disseminated encephalomyelitis* (ADEM), which is therefore a final common pathway of autoimmune CNS injury that may be produced by a variety of infectious agents or immunizations.[169,170]

Postinfectious encephalomyelitis is more common in children than in adults and is rare in the elderly. In children, the peak age of onset is 5 to 8 years. The onset of postinfectious encephalomyelitis may be preceded by fever, malaise, headache, nausea, vomiting, or combinations of these symptoms. These prodromal symptoms are followed by the abrupt—at times fulminant—onset of CNS dysfunction. Altered mental state is almost universal and may range from drowsiness to frank coma. Meningeal signs are common. Neurologic examination may reveal unilateral or bilateral corticospinal tract signs, hemiplegia, ataxia, aphasia, sensory loss, visual field defects, or cranial nerve palsies. Focal or generalized seizures occur in up to 70 percent of children under 5 years of age, 80 percent of whom may develop status epilepticus.[171] Occasionally, postinfectious encephalomyelitis may be accompanied by optic neuritis or by involvement of the peripheral nervous system. The simultaneous occurrence of central and peripheral demyelinating events appears to be more common in adults than children.[172] A syndrome of ataxia may be seen in patients following chicken pox or, less frequently, other viral infections.[173]

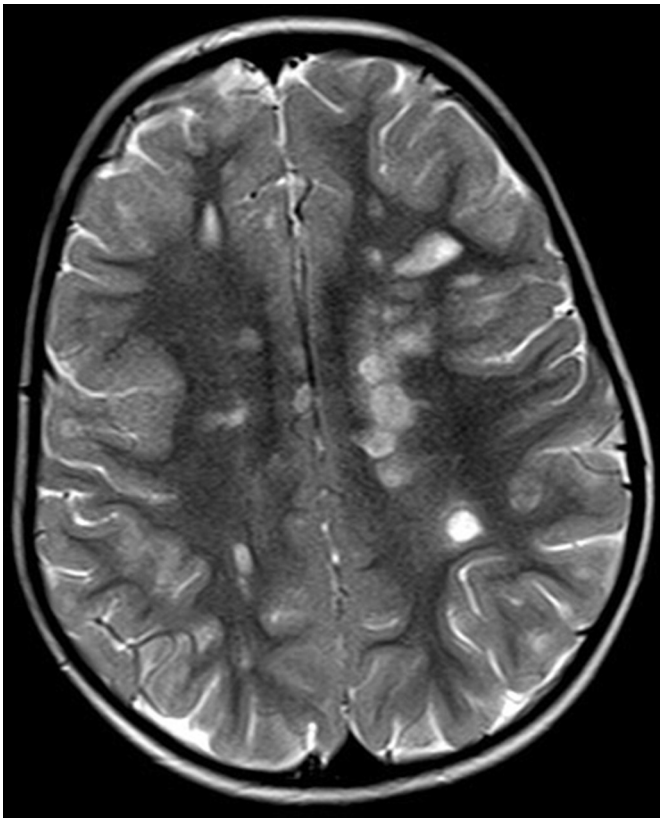

**FIGURE 43-7** ■ Acute disseminated encephalomyelitis. T2-weighted MRI showing multifocal areas of increased signal in the white matter. (From Wender M: Acute disseminated encephalomyelitis (ADEM). J Neuroimmunol 231:92, 2011, with permission from Elsevier.)

The presence of multifocal neurologic signs should raise the level of suspicion of ADEM, as should the presence of signs referable to both the CNS and the peripheral nervous system. Excluding active nervous system infection is important. CSF typically shows a lymphocytic pleocytosis; however, roughly 30 percent of patients will have a mixed pleocytosis with neutrophilic predominance.[174] Traditionally, the presence of oligoclonal bands was considered unusual; in one study, however, oligoclonal bands were detected in 20 percent of patients with ADEM.[175] In a longitudinal study, oligoclonal bands were reported in 65 percent of individuals presenting with illnesses initially diagnosed as ADEM, but over 50 percent of these patients were subsequently diagnosed as having multiple sclerosis.[176]

MRI with gadolinium enhancement is the diagnostic study of choice in ADEM. T2 and FLAIR sequences classically show multiple, large, asymmetric, irregularly shaped lesions involving subcortical white matter and the gray-white junction of both cerebral hemispheres (Fig. 43-7).[176] Periventricular white matter may be involved, but lesions confined to the corpus callosum are unusual, in contrast to multiple sclerosis.[172] Gadolinium enhancement is seen in 30 to 100 percent of patients and may vary with stage of the disease.[171] Ring-enhancing lesions are sometimes found but should raise particular concern regarding brain abscess or other active CNS infection.[172] Spinal cord involvement, usually with extensive edema and swelling, may occur in children or adults and has a predilection for the thoracic region.[172] The majority of these lesions will resolve over time.[172]

## Acute Hemorrhagic Leukoencephalitis

In roughly 2 percent of children (more rarely in adults), postinfectious encephalitis may present with fulminant hemorrhagic demyelination and cerebral edema, a condition termed "acute hemorrhagic leukoencephalitis," "acute necrotizing hemorrhagic leukoencephalitis," or "Weston Hurst syndrome."[171] MRI demonstrates not only demyelination but also hemorrhage, edema, and at times evidence of ischemia on diffusion-weighted images.[177] In contrast to postinfectious encephalomyelitis, mortality is greater than 50 percent.

## Transverse Myelitis

Postinfectious encephalomyelitis may be confined to the spinal cord, resulting in transverse myelitis (Table 43-5).[178] Unlike postinfectious encephalomyelitis, which is more frequent in young children, transverse myelitis is more common in the second decade of life. In the majority of cases, the condition involves the thoracic level of the spinal cord. Onset of symptoms is often abrupt, with rapid progression to maximal deficit; in some patients, however, progression occurs over 1 to 2 weeks. Symptoms typically include fever, back and leg pain, muscle weakness, sensory disturbances, and sphincter dysfunction. Neurologic examination may demonstrate corticospinal tract signs and level-specific sensory loss. The patient may initially exhibit flaccid weakness that progresses over weeks to spasticity. CSF usually shows a lymphocytic or

polymorphonuclear pleocytosis with protein levels that may be as high as 500 mg/dl. MRI of the spinal cord often demonstrates focal areas of increased T2 signal. Acute transverse myelitis may represent the first episode of multiple sclerosis or neuromyelitis optica.[179] MRI may have diagnostic value in differentiating these entities from postviral transverse myelitis: partial transverse lesions are more likely to indicate multiple sclerosis, whereas longitudinal involvement of multiple segments is associated with neuromyelitis optica.[180]

## Approach to Patients with Postinfectious Neurologic Injury

Initial approach to the patient with suspected Guillain–Barré syndrome involves hospitalization and, if the patient is demonstrating respiratory failure, intubation (see Chapter 59). The major initial step in patients with suspected postinfectious encephalomyelitis is to exclude multifocal CNS infection or, less likely, vasculitis. In patients with transverse myelitis, extrinsic spinal cord compression requiring surgery must be excluded. Lumbar puncture is of diagnostic value in Guillain–Barré syndrome. In contrast, the most valuable diagnostic test in postinfectious encephalomyelitis or transverse myelitis is contrast-enhanced MRI. In Guillain–Barré syndrome, the efficacy of plasma exchange and intravenous immunoglobulin G has been demonstrated in controlled trials, as discussed in Chapter 59. In contrast, the treatment of ADEM is typically based on case reports and observational studies; some evidence exists for the use of methylprednisolone, usually given at a dose of 1 gram daily for 5 days.[154,172–174,181] Plasma exchange (usually five exchanges in total, performed daily or every other day) and intravenous immunoglobulin G, given as a total dose of 2 g/kg over 3 to 5 days, have also been used, either in combination with methylprednisolone or after methylprednisolone failure.[174] A variety of other immunosuppressive agents including cyclophosphamide have been used in individual cases. Initial treatment of acute transverse myelitis typically involves high-dose intravenous methylprednisolone.[181] Although treatment of acute hemorrhagic leukoencephalitis is frequently unsuccessful, occasional patients have survived after early treatment with combinations of methylprednisolone, intravenous immunoglobulin G, plasma exchange, or cyclophosphamide.[172]

## ACKNOWLEDGEMENTS

The author thanks Dr. Karen Salzman for assistance in identifying appropriate imaging studies for this chapter. The author is supported by the Neurology and Research Services, Veterans Affairs Medical Center and the Department of Neurology, University of Utah Health Sciences Center.

## REFERENCES

1. Whitley RJ, Roizman B: Herpes simplex virus infections. Lancet 357:1513, 2001.
2. Greenlee JE, O'Neill FJ: Polyomaviruses. p. 581. In: Richman DD, Whitley RJ, Hayden FG (eds): Clinical Virology. 3rd ed. ASM Press, Washington DC, 2009.
3. Griffin DE: Alphaviruses. p. 1023. In: Knipe DM, Howley PM (eds): Fields Virology. 5th ed. Lippincott Williams & Wilkins, Philadelphia, 2007.
4. Kinchington PR, Leger AJ, Guedon JM, et al: Herpes simplex virus and varicella zoster virus, the house guests who never leave. Herpesviridae 3:5, 2012.
5. Diamond MS, Shrestha B, Mehlhop E, et al: Innate and adaptive immune responses determine protection against disseminated infection by West Nile encephalitis virus. Viral Immunol 16:259, 2003.
6. Levi ME, Quan D, Ho JT, et al: Impact of rituximab-associated B-cell defects on West Nile virus meningoencephalitis in solid organ transplant recipients. Clin Transplant 24:223, 2010.
7. Greenlee JE: Progressive multifocal leucoencephalopathy in the era of natalizumab: a review and discussion of the implications. Int MS J 13:100, 2006.
8. Rotbart HA: Viral meningitis. Semin Neurol 20:277, 2000.
9. Kupila L, Vuorinen T, Vainionpaa R, et al: Etiology of aseptic meningitis and encephalitis in an adult population. Neurology 66:75, 2006.
10. Michos AG, Syriopoulou VP, Hadjichristodoulou C, et al: Aseptic meningitis in children: analysis of 506 cases. PLoS One 2:e674, 2007.
11. Romero JR, Newland JG: Viral meningitis and encephalitis: traditional and emerging viral agents. Semin Pediatr Infect Dis 14:72, 2003.
12. Koskiniemi M, Rantalaiho T, Piiparinen H, et al: Infections of the central nervous system of suspected viral origin: a collaborative study from Finland. J Neurovirol 7:400, 2001.
13. Centers for Disease Control and Prevention (CDC) West Nile virus disease and other arboviral diseases—United States, 2011. MMWR Morb Mortal Wkly Rep 61:510, 2012.
14. Bode AV, Sejvar JJ, Pape WJ, et al: West Nile virus disease: a descriptive study of 228 patients hospitalized in a 4-county region of Colorado in 2003. Clin Infect Dis 42:1234, 2006.

15. Barton LL, Hyndman NJ: Lymphocytic choriomeningitis virus: reemerging central nervous system pathogen. Pediatrics 105:e35, 2001.
16. de Ory F, Avellon A, Echevarria JE, et al: Viral infections of the central nervous system in Spain: a prospective study. J Med Virol 85:554, 2013.
17. Hubalek Z, Rudolf I: Tick-borne viruses in Europe. Parasitol Res 111:9, 2012.
18. Misra UK, Kalita J: Overview: Japanese encephalitis. Prog Neurobiol 91:108, 2010.
19. Rotbart HA: Enteroviral infections of the central nervous system. Clin Infect Dis 20:971, 1995.
20. Whitley RJ, Roizman B: Herpes simplex virus. p. 409. In: Richman DD, Whitley RJ, Hayden FG (eds): Clinical Virology. 3rd ed. ASM Press, Washington DC, 2009.
21. Bergstrom T, Vahlne A, Alestig K, et al: Primary and recurrent herpes simplex virus type 2-induced meningitis. J Infect Dis 162:322, 1990.
22. Tyler KL: Herpes simplex virus infections of the central nervous system: encephalitis and meningitis, including Mollaret's. Herpes 11(suppl 2):57A, 2004.
23. Dylewski JS, Bekhor S: Mollaret's meningitis caused by herpes simplex virus type 2: case report and literature review. Eur J Clin Microbiol Infect Dis 23:560, 2004.
24. Landry ML, Greenwold J, Vikram HR: Herpes simplex type-2 meningitis: presentation and lack of standardized therapy. Am J Med 122:688, 2009.
25. Aurelius E, Franzen-Rohl E, Glimaker M, et al: Long-term valacyclovir suppressive treatment after herpes simplex virus type 2 meningitis: a double-blind, randomized controlled trial. Clin Infect Dis 54:1304, 2012.
26. Pahud BA, Glaser CA, Dekker CL, et al: Varicella zoster disease of the central nervous system: epidemiological, clinical, and laboratory features 10 years after the introduction of the varicella vaccine. J Infect Dis 203:316, 2011.
27. Klein NC, McDermott B, Cunha BA: Varicella-zoster virus meningoencephalitis in an immunocompetent patient without a rash. Scand J Infect Dis 42:631, 2010.
28. Gilden D, Cohrs RJ, Mahalingam R, et al: Neurological disease produced by varicella zoster virus reactivation without rash. Curr Top Microbiol Immunol 342:243, 2010.
29. Chan CW, Tam KM, To WK, et al: Hypoglycorrhachia in herpes zoster associated encephalitis of an immunocompetent young male: an unusual presentation. J Neurol 252:987, 2005.
30. Habib AA, Gilden D, Schmid DS, et al: Varicella zoster virus meningitis with hypoglycorrhachia in the absence of rash in an immunocompetent woman. J Neurovirol 15:206, 2009.
31. Romero JR, Simonsen KA: Powassan encephalitis and Colorado tick fever. Infect Dis Clin North Am 22:545, 2008.
32. Barton LL: Human infection with lymphocytic choriomeningitis virus. Emerg Infect Dis 16:1046, 2010.
33. Greenlee JE, Carroll KC: Cerebrospinal fluid in central nervous system infections. p. 6. In: Scheld WM, Whitley RJ, Marra CM (eds): Infections of the Central Nervous System. 3rd ed. Lippincott Williams & Wilkins, Philadelphia, 2004.
34. Bonthius DJ: Lymphocytic choriomeningitis virus: a prenatal and postnatal threat. Adv Pediatr 56:75, 2009.
35. Fischer SA, Graham MB, Kuehnert MJ, et al: Transmission of lymphocytic choriomeningitis virus by organ transplantation. N Engl J Med 354:2235, 2006.
36. Macneil A, Stroher U, Farnon E, et al: Solid organ transplant-associated lymphocytic choriomeningitis, United States, 2011. Emerg Infect Dis 18:1256, 2012.
37. Galazka AM, Robertson SE, Kraigher A: Mumps and mumps vaccine: a global review. Bull World Health Organ 77:3, 1999.
38. Stahl JP, Mailles A, Dacheux L, et al: Epidemiology of viral encephalitis in 2011. Med Mal Infect 41:453, 2011.
39. Centers for Disease Control and Prevention (CDC): Mumps outbreak on a university campus—California, 2011. MMWR Morb Mortal Wkly Rep 61:986, 2012.
40. Marra CM: Human immunodeficiency virus. p. 273. In: Scheld WM, Whitley RJ, Marra CM (eds): Infections of the Central Nervous System. 3rd ed. Lippincott Williams & Wilkins, Philadelphia, 2004.
41. Kahn JO, Walker BD: Acute human immunodeficiency virus type 1 infection. N Engl J Med 339:33, 1998.
42. Robinson CC, Willis M, Meagher A, et al: Impact of rapid polymerase chain reaction results on management of pediatric patients with enteroviral meningitis. Pediatr Infect Dis J 21:283, 2002.
43. Davies NW, Brown LJ, Gonde J, et al: Factors influencing PCR detection of viruses in cerebrospinal fluid of patients with suspected CNS infections. J Neurol Neurosurg Psychiatry 76:82, 2005.
44. Gilden DH, Bennett JL, Kleinschmidt-DeMasters BK, et al: The value of cerebrospinal fluid antiviral antibody in the diagnosis of neurologic disease produced by varicella zoster virus. J Neurol Sci 159:140, 1998.
45. Garro AC, Rutman MS, Simonsen K, et al: Prevalence of Lyme meningitis in children with aseptic meningitis in a Lyme disease-endemic region. Pediatr Infect Dis J 30:990, 2011.
46. Tveitnes D, Natas OB, Skadberg O, et al: Lyme meningitis, the major cause of childhood meningitis in an endemic area: a population based study. Arch Dis Child 97:215, 2012.
47. Hopkins S, Jolles S: Drug-induced aseptic meningitis. Expert Opin Drug Saf 4:285, 2005.
48. Nettis E, Calogiuri G, Colanardi MC, et al: Drug-induced aseptic meningitis. Curr Drug Targets Immune Endocr Metabol Disord 3:143, 2003.
49. Davis LE: Acute and recurrent viral meningitis. Curr Treat Options Neurol 10:168, 2008.
50. Steiner I, Budka H, Chaudhuri A, et al: Viral meningoencephalitis: a review of diagnostic methods and guidelines for management. Eur J Neurol 17:999, 2010.

51. Desmond RA, Accortt NA, Talley L, et al: Enteroviral meningitis: natural history and outcome of pleconaril therapy. Antimicrob Agents Chemother 50:2409, 2006.
52. Rotbart HA, Webster AD: Treatment of potentially life-threatening enterovirus infections with pleconaril. Clin Infect Dis 32:228, 2001.
53. Ihanamaki T, Seppanen M, Tiainen M, et al: Echovirus type 4 as a probable cause of meningitis associated with bilateral optic neuritis: a case report. Clin Infect Dis 38:e49, 2004.
54. Waespe N, Steffen I, Heininger U: Etiology of aseptic meningitis, peripheral facial nerve palsy, and a combination of both in children. Pediatr Infect Dis J 29:453, 2010.
55. Lee HY, Chen CJ, Huang YC, et al: Clinical features of echovirus 6 and 9 infections in children. J Clin Virol 49:175, 2010.
56. Munoz-Sellart M, Garcia-Vidal C, Martinez-Yelamos S, et al: Peripheral facial palsy after varicella. Report of two cases and review of the literature. Enferm Infecc Microbiol Clin 28:504, 2010.
57. Sanjay S, Chan EW, Gopal L, et al: Complete unilateral ophthalmoplegia in herpes zoster ophthalmicus. J Neuroophthalmol 29:325, 2009.
58. Heppner PA, Schweder PM, Monteith SJ, et al: Acute hydrocephalus secondary to herpes simplex type II meningitis. J Clin Neurosci 15:1157, 2008.
59. Aydemir C, Eldes N, Kolsal E, et al: Acute tetraventricular hydrocephalus caused by mumps meningoencephalitis in a child. Pediatr Neurosurg 45:419, 2009.
60. Maraite N, Mataigne F, Pieri V, et al: Early decompressive hemicraniectomy in fulminant herpes simplex encephalitis. Bull Soc Sci Med Grand Duche Luxemb 279, 2010.
61. Kumar G, Kalita J, Misra UK: Raised intracranial pressure in acute viral encephalitis. Clin Neurol Neurosurg 111:399, 2009.
62. Glaser CA, Gilliam S, Schnurr D, et al: In search of encephalitis etiologies: diagnostic challenges in the California Encephalitis Project, 1998–2000. Clin Infect Dis 36:731, 2003.
63. Whitley RJ: Herpes simplex encephalitis: adolescents and adults. Antiviral Res 71:141, 2006.
64. Baringer JR, Pisani P: Herpes simplex virus genomes in human nervous sytem tissue analyzed by polymerase chain reaction. Ann Neurol 36:823, 1994.
65. Aurelius E, Johansson B, Skoldenberg B, et al: Encephalitis in immunocompetent patients due to herpes simplex virus type 1 or 2 as determined by type-specific polymerase chain reaction and antibody assays of cerebrospinal fluid. J Med Virol 39:179, 1993.
66. Whitley RJ, Kimberlin DW: Herpes simplex encephalitis: children and adolescents. Semin Pediatr Infect Dis 16:17, 2005.
67. Whitley RJ, Lakeman F: Herpes simplex virus infections of the central nervous system: therapeutic and diagnostic considerations. Clin Infect Dis 20:414, 1995.
68. Tan IL, McArthur JC, Venkatesan A, et al: Atypical manifestations and poor outcome of herpes simplex encephalitis in the immunocompromised. Neurology 79:2125, 2012.
69. Livorsi D, Anderson E, Qureshi S, et al: Brainstem encephalitis: an unusual presentation of herpes simplex virus infection. J Neurol 257:1432, 2010.
70. Booss J, Esiri MM: Herpes simplex encephalitis. p. 41. In: Booss J, Esiri MM (eds): Viral Encephalitis in Humans. ASM Press, Washington DC, 2003.
71. Jubelt B, Mihai C, Li TM, et al: Rhombencephalitis/brainstem encephalitis. Curr Neurol Neurosci Rep 11:543, 2011.
72. Whitley RJ, Soong SJ, Linneman Jr C, et al: Herpes simplex encephalitis. Clinical Assessment. JAMA 247:317, 1982.
73. Taylor SW, Lee DH, Jackson AC: Herpes simplex encephalitis presenting with exclusively frontal lobe involvement. J Neurovirol 13:477, 2007.
74. Al-Shekhlee A, Kocharian N, Suarez JJ: Re-evaluating the diagnostic methods in herpes simplex encephalitis. Herpes 13:17, 2006.
75. Lakeman FD, Whitley RJ: Diagnosis of herpes simplex encephalitis: application of polymerase chain reaction to cerebrospinal fluid from brain-biopsied patients and correlation with disease. National Institute of Allergy and Infectious Diseases Collaborative Antiviral Study Group. J Infect Dis 171:857, 1995.
76. Weil AA, Glaser CA, Amad Z, et al: Patients with suspected herpes simplex encephalitis: rethinking an initial negative polymerase chain reaction result. Clin Infect Dis 34:1154, 2002.
77. Denes E, Labach C, Durox H, et al: Intrathecal synthesis of specific antibodies as a marker of herpes simplex encephalitis in patients with negative PCR. Swiss Med Wkly 140:w13107, 2010.
78. Schulte EC, Sauerbrei A, Hoffmann D, et al: Acyclovir resistance in herpes simplex encephalitis. Ann Neurol 67:830, 2010.
79. Kakiuchi S, Nonoyama S, Wakamatsu H, et al: Neonatal herpes encephalitis caused by a virologically confirmed acyclovir-resistant herpes simplex virus 1 strain. J Clin Microbiol 51:356, 2013.
80. Whitley RJ, Alford CA, Hirsch MS, et al: Factors indicative of outcome in a comparative trial of acyclovir and vidarabine for biopsy-proven herpes simplex encephalitis. Infection 15(suppl 1):S3, 1987.
81. Hjalmarsson A, Blomqvist P, Skoldenberg B: Herpes simplex encephalitis in Sweden, 1990–2001: incidence, morbidity, and mortality. Clin Infect Dis 45:875, 2007.
82. McGrath N, Anderson NE, Croxson MC, et al: Herpes simplex encephalitis treated with acyclovir: diagnosis and long term outcome. J Neurol Neurosurg Psychiatry 63:321, 1997.

83. Gilden D, Mahalingam R, Nagel MA, et al: Review: the neurobiology of varicella zoster virus infection. Neuropathol Appl Neurobiol 37:441, 2011.
84. Bruxelle J, Pinchinat S: Effectiveness of antiviral treatment on acute phase of herpes zoster and development of post herpetic neuralgia: review of international publications. Med Mal Infect 42:53, 2012.
85. Kost RG, Strauss SE: Postherpetic neuralgia—pathogenesis, treatment, and prevention. N Engl J Med 335:32, 1996.
86. Oxman MN, Levin MJ, Johnson GR, et al: A vaccine to prevent herpes zoster and postherpetic neuralgia in older adults. N Engl J Med 352:2271, 2005.
87. Dubinsky RM, Kabbani H, El-Chami Z, et al: Practice parameter: treatment of postherpetic neuralgia: an evidence-based report of the Quality Standards Subcommittee of the American Academy of Neurology. Neurology 63:959, 2004.
88. Gilden D, Cohrs RJ, Mahalingam R, et al: Varicella zoster virus vasculopathies: diverse clinical manifestations, laboratory features, pathogenesis, and treatment. Lancet Neurol 8:731, 2009.
89. Mailles A, Stahl JP: Infectious encephalitis in France in 2007: a national prospective study. Clin Infect Dis 49:1838, 2009.
90. Granerod J, Ambrose HE, Davies NW, et al: Causes of encephalitis and differences in their clinical presentations in England: a multicentre, population-based prospective study. Lancet Infect Dis 10:835, 2010.
91. Booss J, Esiri MM: Varicella-zoster virus: the paradox of immune mediation and immunocmpromize. p. 127. In: Booss J, Esiri MM (eds): Viral Encephalitis in Humans. ASM Press, Washington DC, 2003.
92. Petersen LR, Marfin AA: West Nile virus: a primer for the clinician. Ann Intern Med 137:173, 2002.
93. Solomon T, Whitley RJ: Arthropod-borne viral encephalitides. p. 205. In: Scheld WM, Whitley RJ, Marra CM (eds): Infections of the Central Nervous System. Lippincott Williams & Wilkins, Philadelphia, 2004.
94. Davis LE, DeBiasi R, Goade DE, et al: West Nile virus neuroinvasive disease. Ann Neurol 60:286, 2006.
95. Sejvar JJ, Haddad MB, Tierney BC, et al: Neurologic manifestations and outcome of West Nile virus infection. JAMA 290:511, 2003.
96. Anninger WV, Lomeo MD, Dingle J, et al: West Nile virus-associated optic neuritis and chorioretinitis. Am J Ophthalmol 136:1183, 2003.
97. Leis AA, Stokic DS, Polk JL, et al: A poliomyelitis-like syndrome from West Nile virus infection. N Engl J Med 347:1279, 2002.
98. Tyler KL: West Nile virus infection in the United States. Arch Neurol 61:1190, 2004.
99. Petropoulou KA, Gordon SM, Prayson RA, et al: West Nile virus meningoencephalitis: MR imaging findings. AJNR Am J Neuroradiol 26:1986, 2005.
100. Makhoul B, Braun E, Herskovitz M, et al: Hyperimmune gammaglobulin for the treatment of West Nile virus encephalitis. Isr Med Assoc J 11:151, 2009.
101. Griffin DE: Arboviruses and the central nervous system. Springer Semin Immunopathol 17:121, 1995.
102. Smith DW, Mackenzie JS, Weaver SC: Alphaviruses. p. 1241. In: Richman DD, Whitley RJ, Hayden FG (eds): Clinical Virology. 3rd Ed. ASM Press, Washington DC, 2009.
103. Deresiewicz RL, Thaler SJ, Hsu L, et al: Clinical and neuroradiographic manifestations of eastern equine encephalitis. N Engl J Med 336:1867, 1997.
104. Dobler G, Gniel D, Petermann R, et al: Epidemiology and distribution of tick-borne encephalitis. Wien Med Wochenschr 162:230, 2012.
105. Fishbein DB, Robinson LE: Current concepts: rabies. N Engl J Med 329:1632, 1993.
106. Centers for Disease Control and Prevention (CDC) Imported human rabies in a U.S. Army soldier—New York, 2011. MMWR Morb Mortal Wkly Rep 61:302, 2012.
107. Vetter JM, Frisch L, Drosten C, et al: Survival after transplantation of corneas from a rabies-infected donor. Cornea 30:241, 2011.
108. Maier T, Schwarting A, Mauer D, et al: Management and outcomes after multiple corneal and solid organ transplantations from a donor infected with rabies virus. Clin Infect Dis 50:1112, 2010.
109. Srinivasan A, Burton EC, Kuehnert MJ, et al: Transmission of rabies virus from an organ donor to four transplant recipients. N Engl J Med 352:1103, 2005.
110. Smith JS, Fishbein DB, Rupprecht CE, et al: Unexplained rabies in three immigrants in the United States a virologic investigation. N Engl J Med 324:205, 1991.
111. Jackson AC, Ye H, Phelan CC, et al: Extraneural organ involvement in human rabies. Lab Invest 79:945, 1999.
112. Jogai S, Radotra BD, Banerjee AK: Rabies viral antigen in extracranial organs: a post-mortem study. Neuropathol Appl Neurobiol 28:334, 2002.
113. Mrak RE, Young L: Rabies encephalitis in a patient with no history of exposure. Hum Pathol 24:109, 1993.
114. Laothamatas J, Hemachudha T, Mitrabhakdi E, et al: MR imaging in human rabies. AJNR Am J Neuroradiol 24:1102, 2003.
115. Frenia ML, Lafin SM, Barone JA: Features and treatment of rabies. Clin Pharm 11:37, 1992.
116. Hattwick MAW, Weis TT, Stechschulte CJ, et al: Recovery from rabies. A case report. Ann Intern Med 76:931, 1972.
117. Jackson AC: Current and future approaches to the therapy of human rabies. Antiviral Res 99:61, 2013.
118. Willoughby Jr RE, Tieves KS, Hoffman GM, et al: Survival after treatment of rabies with induction of coma. N Engl J Med 352:2508, 2005.

119. Ooi MH, Wong SC, Lewthwaite P, et al: Clinical features, diagnosis, and management of enterovirus 71. Lancet Neurol 9:1097, 2010.
120. Jang S, Suh SI, Ha SM, et al: Enterovirus 71-related encephalomyelitis: usual and unusual magnetic resonance imaging findings. Neuroradiology 54:239, 2012.
121. Kang SS, McGavern DB: Lymphocytic choriomeningitis infection of the central nervous system. Front Biosci 13:4529, 2008.
122. Douvoyiannis M, Litman N, Goldman DL: Neurologic manifestations associated with parvovirus B19 infection. Clin Infect Dis 48:1713, 2009.
123. Ward KN, Andrews NJ, Verity CM, et al: Human herpesviruses-6 and -7 each cause significant neurological morbidity in Britain and Ireland. Arch Dis Child 90:619, 2005.
124. Yao K, Honarmand S, Espinosa A, et al: Detection of human herpesvirus-6 in cerebrospinal fluid of patients with encephalitis. Ann Neurol 65:257, 2009.
125. Griffin DE: Emergence and re-emergence of viral diseases of the central nervous system. Prog Neurobiol 91:95, 2010.
126. Kleinschmidt-DeMasters BK, Gilden DH: The expanding spectrum of herpesvirus infections of the nervous system. Brain Pathol 11:440, 2001.
127. Majid A, Galetta SL, Sweeney CJ, et al: Epstein-Barr virus myeloradiculitis and encephalomyeloradiculitis. Brain 125:159, 2002.
128. Portegies P, Corssmit N: Epstein-Barr virus and the nervous system. Curr Opin Neurol 13:301, 2000.
129. Quartier P, Foray S, Casanova JL, et al: Enteroviral meningoencephalitis in X-linked agammaglobulinemia: intensive immunoglobulin therapy and sequential viral detection in cerebrospinal fluid by polymerase chain reaction. Pediatr Infect Dis J 19:1106, 2000.
130. Cunningham CK, Bonville CA, Ochs HD, et al: Enteroviral meningoencephalitis as a complication of X-linked hyper IgM syndrome. J Pediatr 134:584, 1999.
131. Ganjoo KN, Raman R, Sobel RA, et al: Opportunistic enteroviral meningoencephalitis: an unusual treatable complication of rituximab therapy. Leuk Lymphoma 50:673, 2009.
132. Ahmed R, Buckland M, Davies L, et al: Enterovirus 71 meningoencephalitis complicating rituximab therapy. J Neurol Sci 305:149, 2011.
133. Anders HJ, Goebel FD: Neurological manifestations of cytomegalovirus infection in the acquired immunodeficiency syndrome. Int J STD AIDS 10:151, 1999.
134. Carrigan DR: Adenovirus infections in immunocompromised patients. Am J Med 102:71, 1997.
135. Clark DA: Human herpesvirus 6 and human herpesvirus 7: emerging pathogens in transplant patients. Int J Hematol 76(suppl 2):246, 2002.
136. Chretien F, Belec L, Hilton DA, et al: Herpes simplex virus type 1 encephalitis in acquired immunodeficiency syndrome. Neuropathol Appl Neurobiol 22:394, 1996.
137. Gray F, Belec L, Lescs MC, et al: Varicella-zoster virus infection of the central nervous system in the acquired immune deficiency syndrome. Brain 117:987, 1994.
138. van de Beek D, Patel R, Daly RC, et al: Central nervous system infections in heart transplant recipients. Arch Neurol 64:1715, 2007.
139. Dewhurst S: Human herpesvirus type 6 and human herpesvirus type 7 infections of the central nervous system. Herpes 11(suppl 2):105A, 2004.
140. Pot C, Burkhard PR, Villard J, et al: Human herpesvirus-6 variant A encephalomyelitis. Neurology 70:974, 2008.
141. Maschke M, Kastrup O, Diener HC: CNS manifestations of cytomegalovirus infections: diagnosis and treatment. CNS Drugs 16:303, 2002.
142. Birnbaum T, Padovan CS, Sporer B, et al: Severe meningoencephalitis caused by human herpesvirus 6 type B in an immunocompetent woman treated with ganciclovir. Clin Infect Dis 40:887, 2005.
143. Perez-Liz G, Del Valle L, Gentilella A, et al: Detection of JC virus DNA fragments but not proteins in normal brain tissue. Ann Neurol 64:379, 2008.
144. Berger JR, Concha M: Progressive multifocal leukoencephalopathy: the evolution of a disease once considered rare. J Neurovirol 1:5, 1995.
145. Palazzo E, Yahia SA: Progressive multifocal leukoencephalopathy in autoimmune diseases. Joint Bone Spine 79:351, 2012.
146. Tavazzi E, Ferrante P, Khalili K: Progressive multifocal leukoencephalopathy: an unexpected complication of modern therapeutic monoclonal antibody therapies. Clin Microbiol Infect 17:1776, 2011.
147. Koralnik IJ, Wuthrich C, Dang X, et al: JC virus granule cell neuronopathy: a novel clinical syndrome distinct from progressive multifocal leukoencephalopathy. Ann Neurol 57:576, 2005.
148. Yousry TA, Pelletier D, Cadavid D, et al: Magnetic resonance imaging pattern in natalizumab-associated progressive multifocal leukoencephalopathy. Ann Neurol 72:779, 2012.
149. Greenlee JE: Progressive multifocal leukoencephalopathy. p. 399. In: Aminoff MJ, Goetz CG (eds): Handbook of Clinical Neurology. Elsevier, Amsterdam, 1998.
150. Marzocchetti A, Di Giambenedetto S, Cingolani A, et al: Reduced rate of diagnostic positive detection of JC virus DNA in cerebrospinal fluid in cases of suspected progressive multifocal leukoencephalopathy in the era of potent antiretroviral therapy. J Clin Microbiol 43:4175, 2005.
151. Aksamit AJ: Treatment of non-AIDS progressive multifocal leukoencephalopathy with cytosine arabinoside. J Neurovirol 7:386, 2001.
152. Tan IL, McArthur JC, Clifford DB, et al: Immune reconstitution inflammatory syndrome in natalizumab-associated PML. Neurology 77:1061, 2011.

153. Vendrely A, Bienvenu B, Gasnault J, et al: Fulminant inflammatory leukoencephalopathy associated with HAART-induced immune restoration in AIDS-related progressive multifocal leukoencephalopathy. Acta Neuropathol (Berl) 109:449, 2005.
154. Tunkel AR, Glaser CA, Bloch KC, et al: The management of encephalitis: clinical practice guidelines by the Infectious Diseases Society of America. Clin Infect Dis 47:303, 2008.
155. Kupersmith MJ, Martin V, Heller G, et al: Idiopathic hypertrophic pachymeningitis. Neurology 62:686, 2004.
156. Zuliani L, Graus F, Giometto B, et al: Central nervous system neuronal surface antibody associated syndromes: review and guidelines for recognition. J Neurol Neurosurg Psychiatry 83:638, 2012.
157. Adamo MA, Deshaies EM: Emergency decompressive craniectomy for fulminating infectious encephalitis. J Neurosurg 108:174, 2008.
158. Sikorska B, Liberski PP: Human prion diseases: from kuru to variant Creutzfeldt-Jakob disease. Subcell Biochem 65:457, 2012.
159. Johnson RT: Prion diseases. Lancet Neurol 4:635, 2005.
160. Prusiner SB: The prion diseases. Brain Pathol 8:499, 1998.
161. Brown P, Brandel JP, Sato T, et al: Iatrogenic Creutzfeldt-Jakob disease, final assessment. Emerg Infect Dis 18:901, 2012.
162. Collins SJ, Sanchez-Juan P, Masters CL, et al: Determinants of diagnostic investigation sensitivities across the clinical spectrum of sporadic Creutzfeldt-Jakob disease. Brain 129:2278, 2006.
163. Geschwind MD, Haman A, Miller BL: Rapidly progressive dementia. Neurol Clin 25:783, 2007.
164. Wieser HG, Schindler K, Zumsteg D: EEG in Creutzfeldt-Jakob disease. Clin Neurophysiol 117:935, 2006.
165. Macfarlane RG, Wroe SJ, Collinge J, et al: Neuroimaging findings in human prion disease. J Neurol Neurosurg Psychiatry 78:664, 2007.
166. Hamlin C, Puoti G, Berri S, et al: A comparison of tau and 14-3-3 protein in the diagnosis of Creutzfeldt-Jakob disease. Neurology 79:547, 2012.
167. Almond JW: Bovine spongiform encephalopathy and new variant Creutzfeldt-Jakob disease. Br Med Bull 54:749, 1998.
168. Zeidler M, Sellar RJ, Collie DA, et al: The pulvinar sign on magnetic resonance imaging in variant Creutzfeldt-Jakob disease. Lancet 355:1412, 2000.
169. Young NP, Weinshenker BG, Lucchinetti CF: Acute disseminated encephalomyelitis: current understanding and controversies. Semin Neurol 28:84, 2008.
170. Wender M: Acute disseminated encephalomyelitis (ADEM). J Neuroimmunol 231:92, 2011.
171. Tenembaum S, Chamoles N, Fejerman N: Acute disseminated encephalomyelitis: a long-term follow-up study of 84 pediatric patients. Neurology 59:1224, 2002.
172. Tenembaum S, Chitnis T, Ness J, et al: Acute disseminated encephalomyelitis. Neurology 68:S23, 2007.
173. van der Maas NA, Bondt PE, de Melker H, et al: Acute cerebellar ataxia in the Netherlands: a study on the association with vaccinations and varicella zoster infection. Vaccine 27:1970, 2009.
174. Sonneville R, Klein I, de Broucker T, et al: Postinfectious encephalitis in adults: diagnosis and management. J Infect 58:321, 2009.
175. de Seze J, Debouverie M, Zephir H, et al: Acute fulminant demyelinating disease: a descriptive study of 60 patients. Arch Neurol 64:1426, 2007.
176. Schwarz S, Mohr A, Knauth M, et al: Acute disseminated encephalomyelitis: a follow-up study of 40 adult patients. Neurology 56:1313, 2001.
177. Mader I, Wolff M, Nagele T, et al: MRI and proton MR spectroscopy in acute disseminated encephalomyelitis. Childs Nerv Syst 21:566, 2005.
178. Borchers AT, Gershwin ME: Transverse myelitis. Autoimmun Rev 11:231, 2012.
179. Fazio R, Radaelli M, Furlan R: Neuromyelitis optica: concepts in evolution. J Neuroimmunol 231:100, 2011.
180. Scott TF, Frohman EM, De Seze J, et al: Evidence-based guideline: clinical evaluation and treatment of transverse myelitis: report of the Therapeutics and Technology Assessment Subcommittee of the American Academy of Neurology. Neurology 77:2128, 2011.
181. Sebire G, Hollenberg H, Meyer L, et al: High dose methylprednisolone in severe acute transverse myelopathy. Arch Dis Child 76:167, 1997.
182. Kappos L, Bates D, Edan G, et al: Natalizumab treatment for multiple sclerosis: updated recommendations for patient selection and monitoring. Lancet Neurol 10:745, 2011.