



Case Report

Reversal of life-threatening hepatopulmonary syndrome in Gaucher disease by imiglucerase enzyme replacement therapy



Amal El Beshlawy^a, Vagishwari Murugesan^b, Pramod Kumar Mistry^c, Khaled Eid^{a,*}

^a Pediatric Hematology, Department of Pediatrics, Cairo University, Egypt

^b Department of Internal Medicine, Yale University School of Medicine, United States of America

^c Internal Medicine and Pediatrics, Yale University School of Medicine, 333 Cedar St, LMP 1080, PO Box 208019, New Haven, CT 06520-8019, United States of America

ARTICLE INFO

Keywords:

Gaucher disease
Hepatopulmonary syndrome
Enzyme replacement therapy
Pulmonary complications

ABSTRACT

Advanced liver disease complicated by hepatopulmonary syndrome is a recognized complication of Gaucher disease. Macrophage-targeted, recombinant enzyme replacement therapy is effective in reversing clinical manifestations attributed to the accumulation of glycolipid-laden macrophages but it is not known whether advanced fibrotic features of the disease can be ameliorated. We describe a splenectomized patient with Gaucher disease who developed massive hepatomegaly, cirrhosis of the liver and life-threatening hepatopulmonary syndrome. Treatment with Imiglucerase enzyme replacement therapy resulted in dramatic reversal of hepatopulmonary syndrome and liver disease. Our report suggests that Gaucher disease pathology involving advanced fibrosis and life-threatening complications can be reversed by imiglucerase enzyme therapy.

Synopsis: Effect of imiglucerase enzyme replacement therapy on Hepatopulmonary Syndrome in Gaucher Disease.

1. Introduction

Gaucher disease (GD) is one of the most prevalent lysosomal storage disorders throughout the world with an incidence of 1 in 40,000 in the general population but as high as 1 in 800 in the Ashkenazi Jewish population [1]. An autosomal recessive disorder, it occurs due to bi-allelic mutations in *GBA1* gene on chromosome 1q21. The metabolic defect is a deficiency of the lysosomal enzyme acid- β glucosidase, due to mutations in *GBA1* which results in the accumulation of the primary substrate, glucosylceramide and its downstream bioactive lipids [2]. The hallmark of the disease is accumulation of glucosylceramide-laden macrophages (Gaucher cells) that leads to the clinical phenotype of hepatosplenomegaly, cytopenia and a diverse pattern of skeletal disease.

The liver is universally involved in Gaucher disease ranging from mild to massive hepatomegaly associated with mild elevation of liver function tests and liver fibrosis as well as markedly elevated risk of hepatocellular carcinoma [3–5], even in non-cirrhotic liver. Rarely, hepatopulmonary syndrome (HPS) arising from advanced liver disease is seen in GD patients [6–8]. The standard of care for HPS is liver transplantation as there are no known medical therapies that can

reverse this life-threatening complication, hence these patients are given high priority on waiting lists [9].

Macrophage-targeted recombinant enzyme replacement therapy (ERT) is based on delivery of the therapeutic enzyme to macrophages via macrophage mannose receptor and while it reverses visceral and hematological manifestation, it is not known whether this form of treatment has the potential to reverse disease manifestations that include advanced fibrosis [10]. Pathophysiology of GD involves development of fibrosis at multiple sites including the liver, the spleen, the bone marrow and the lungs [11]. We report a patient with Gaucher disease with advanced liver disease complicated by hepatopulmonary syndrome that was reversed by Imiglucerase enzyme replacement therapy (Fig. 1).

2. Case

The patient was born to first degree consanguineous parents and was found to have progressive splenomegaly and pallor at 18 months of age. Over the following 18 months, her spleen became massive with spleen tip in the pelvis, her Hb was 7 g/DL and platelets 60,000/ μ L. She underwent splenectomy at age 3 and her Hb and platelets normalized,

Abbreviations: GD, Gaucher disease; HPS, Hepatopulmonary Syndrome; PAH, Pulmonary arterial hypertension; ERT, Enzyme replacement therapy; MCP-1, Lung monocyte chemoattractant protein; PDGF, Platelet derived growth factor

* Corresponding author.

E-mail address: drkhaleid@netscape.net (K. Eid).

<https://doi.org/10.1016/j.ymgmr.2019.100490>

Received 9 May 2019; Received in revised form 23 June 2019

Available online 28 June 2019

2214-4269/© 2019 The Authors. Published by Elsevier Inc. This is an open access article under the CC BY-NC-ND license

(<http://creativecommons.org/licenses/by-nc-nd/4.0/>).

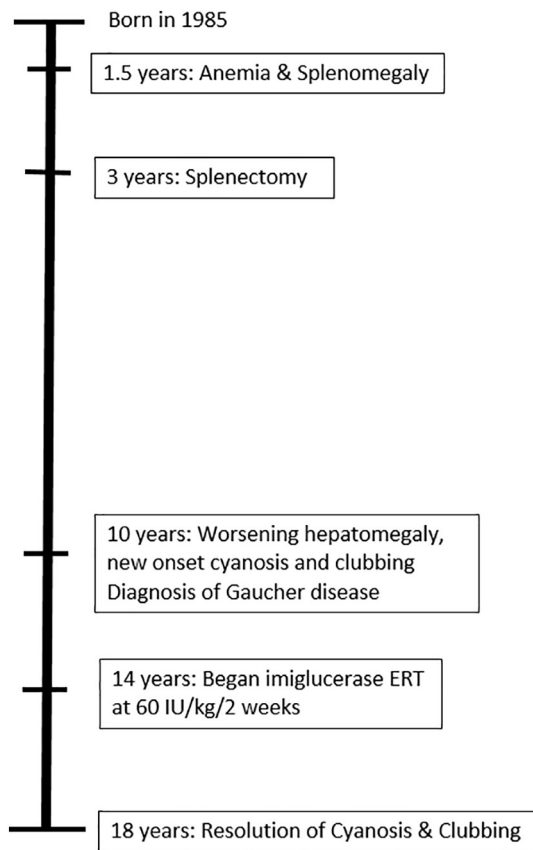


Fig. 1. Timeline of events of patient.

and her growth parameters improved initially. However, she developed progressive hepatomegaly, liver dysfunction and failure to thrive. Hepatomegaly assumed huge proportions such that the liver occupied the entire abdomen and descended into the pelvis [Fig. 2A]. By age 10, she became increasingly short of breath and developed florid finger clubbing [Fig. 2C]. Biopsy of her liver showed massive infiltration by Gaucher cells and cirrhosis. Bone marrow aspiration showed intense infiltration by Gaucher cells. Patient was found to be homozygous for p.Leu483Pro *GBA* mutation. From age 10 to age 14, the patient became incapacitated with hepatopulmonary syndrome, chronic hypoxemia (pulse oximetry on room air was 72%) and massive hepatomegaly. At age 14, her Hb was 11.5 g/dL and platelets 140,000/ μ L, both relatively low for patient who had previously been splenectomized. Pulmonary function tests showed a restrictive defect. A lung perfusion study with Technecium99 Macro-aggregated Albumin (MAA) showed scintigraphic evidence of right – left shunting and arterio-venous fistulae in the hilum and periphery of the upper lung [Fig. 2E]. Survival prospects for this young patient were poor without liver transplantation.

The patient began Imiglucerase enzyme replacement therapy at age 14 years at a dose of 60 IU/kg/2 weeks through a humanitarian program established by Project Hope and Sanofi Genzyme. She had a dramatic response with reversal of hepatomegaly, anemia (Hb rising from 11.5 g/dL to 16 g/dL), relative thrombocytopenia (platelets rising from 140,000 to 260,000/ μ L), hypoxemia (pulse oximetry on room air improving from 72% to 95%), growth failure and finger clubbing [Fig. 2B & D]. Concomitantly, her biomarkers of Gaucher disease, serum chitotriosidase fell from 12,650 to 4350 nmol/ml/h (normal < 150). Doppler echocardiogram with bubble contrast showed no evidence of late shunting, consistent with reversal of intrapulmonary shunting. Estimated right ventricular systolic pressure derived from speed of tricuspid regurgitant jet was 40 mmHg (normal).

The patient enjoyed a good quality of life, married and became

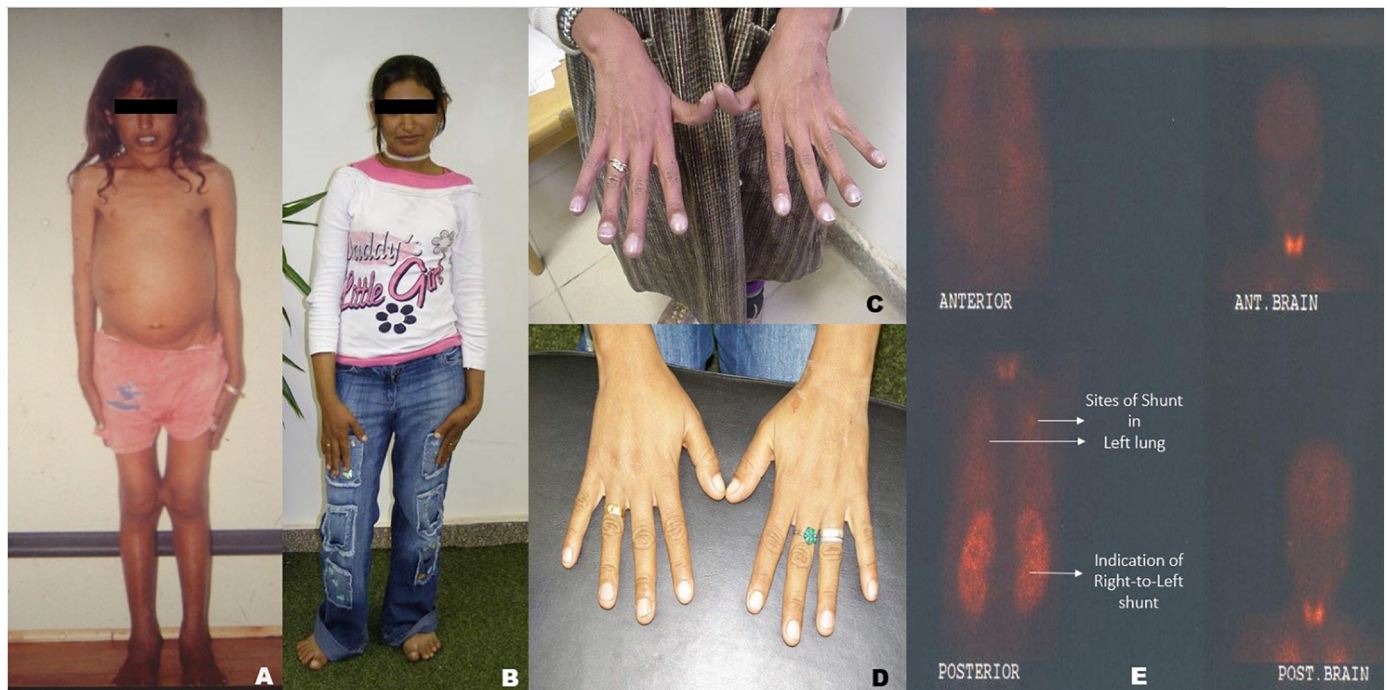


Fig. 2. Impact of imiglucerase ERT on hepatopulmonary syndrome and massive hepatomegaly.

A: Prominent hepatomegaly seen at 10 years of age leading to diagnosis of GD.

B: Reversal of hepatomegaly after beginning ERT at 18 years of age.

C: Cyanosis and clubbing at 10 years of age.

D: Reversal of cyanosis and clubbing at 18 years of age after ERT.

E: Abnormal pulmonary shunting characteristic of hepatopulmonary syndrome demonstrated in.

Technicium 99 MAA lung perfusion study with abnormal accumulation of radiolabeled MAA in the kidneys and the brain.

pregnant while continuing imiglucerase ERT. By this time, she had been on ERT for 10 years. Unfortunately she developed peripartum cardiomyopathy during pregnancy. Doppler echocardiogram showed biventricular failure with ejection fraction of 65% and there was no intrapulmonary shunting. Speed of tricuspid regurgitant jet could not be measured accurately due to biventricular failure. There was no evidence pericarditis/pericardial effusion on EKG or echocardiogram. Taken together with normal Doppler echocardiogram prior to start of pregnancy, it was felt the most likely diagnosis was peripartum cardiomyopathy. Resultant complications led to the development of cardiogenic shock after successful delivery of a healthy baby and she died 7 days postpartum.

3. Discussion

Pulmonary involvement in Gaucher disease can span the spectrum of interstitial lung disease to pulmonary vascular disease. Pulmonary vascular complications of GD comprise hepatopulmonary syndrome (HPS) and pulmonary arterial hypertension (PAH) and these can occur concurrently in the same patient [6–8]. Prior to the availability of ERT, these complications were invariably fatal [12–14]. Prevalence of parenchymal pulmonary involvement by Gaucher disease was reported by Lee et al., who found a third of GD1 and GD3 patients who died harbored extensive pulmonary infiltration by Gaucher cells at autopsy [15]. A more recent study of pulmonary function tests in GD1 patients reported a decreased functional reduced capacity in 45% of the patients along with a decrease in transfer coefficient for carbon monoxide, decreased total lung capacity in 22% patients and an increase in residual lung volume in 18% of patients [16].

HPS is a triad of intrapulmonary vascular dilations and an imbalance in alveolar-arterial oxygen gradient in the setting of advanced liver disease [17]. The pathogenesis of intrapulmonary vascular dilations in HPS is not clearly understood but may involve shunting of vasoactive mediators due to portosystemic shunting related to advanced liver disease. A unique feature of HPS in Gaucher disease, is that it can occur concurrently with plexogenic vasculopathy that underlies pulmonary hypertension. Consistent with this concept, Lo et al. reported 3 patients with florid HPS with massive hepatomegaly that reversed with imiglucerase ERT and unmasked underlying pulmonary arterial hypertension [6]. Similarly, Dawson et al. reported 2 patients with HPS who showed reversal of HPS after administration of alglucerase ERT but who subsequently developed PAH [7]. Thus the limited reports thus far have suggested a picture of pulmonary vascular disease in GD ranging from HPS to PAH, with concurrent occurrence in some patients.

Lung involvement has been described in Gaucher Disease Type 1 and in patients with p.Asn409Ser *GBA1* mutation [6]. It is becoming clear that lung involvement is more common among patients homozygous for p.Leu483Pro mutation, the genotype of our patient [18]. Indeed, non- p.Asn409Ser *GBA* mutations were associated with increased severity of pulmonary hypertension [19]. Our patient, although carrying the neuronopathic phenotype, failed to manifest any neurological disease throughout the duration of her life but suffered severe hypoxemia and cyanosis from pulmonary complications from age 10 years. Our patient harbored other known risk factors for this complication, namely, female gender and asplenia [19]. Earlier studies also showed that severity score index was well correlated with HPS but not with PAH [6].

The association of GD and HPS is related to the presence of end-stage liver disease as well as the central role of macrophages in GD pathophysiology. A study by Thenappan et al. postulates that CD 68+ macrophages play an essential role in the pathogenesis of HPS in chronic liver disease in murine models of study [20]. GD is associated with macrophage activation and activated macrophages are known to be recruited to pulmonary arterioles and capillaries through plasma endotoxins and lung monocyte chemoattractant protein (MCP-1) [21].

Accumulation of macrophages in the small vasculature results in the release of cytokines, inflammatory and growth factors including inducible nitric oxide synthase, vascular endothelial growth factor and platelet derived growth factor (PDGF) that trigger vascular dilation and angiogenesis seen in HPS. In addition macrophages are known to contribute to a proliferative vasculopathy and cellular remodeling through PDGF through an increase in the medial thickness of small pulmonary arteries and increased alveolar capillary density. Key role of macrophages in driving HPS pathophysiology is highlighted by this study where depletion of macrophages resulted in inhibition and regression of HPS in murine models [20].

The established role of macrophages in HPS pathophysiology is highly relevant to GD, a disorder associated with prominent expansion of the macrophage system and macrophage activation [22]. Glucosylceramide-laden macrophages, Gaucher cells, accumulate in not only the vascular spaces of the pulmonary system but also in the interstitium and alveolar spaces [23]. In addition, bioactive lipids that accumulate systemically via glucosylceramide-laden macrophages is associated with immune activation and hypercytokinemia. Hypercytokinemia of GD includes significant elevation of MCP-1, a chemokine capable of recruiting macrophages to the pulmonary circulation in non-GD patients [21]. It should be noted that our patient had a dramatic response to Imiglucerase, a macrophage-targeted ERT. Due to the systemic nature of macrophage involvement in GD, the impressive therapeutic effect of Imiglucerase ERT on HPS is likely to be related to dual effects on hepatic disease as well as on macrophage infiltration of the lungs.

The lungs are already known to be a site that is relatively inaccessible to the effects of ERT due high uptake by the liver and it seems likely that as patient had prior splenectomy, delivery to extrahepatic disease compartments, such as the lungs was improved. [24]. Hence the dramatic effects of Imiglucerase ERT seen in our patient is likely due to primary reversal of liver disease and hepatic fibrosis with additional effect on pulmonary vascular macrophages. The pathophysiology linking glucosylceramide accumulation and macrophage activation with fibrosis is not understood, nor is the potential role of hepatic stellate cells. This is an important area of study since fibrosis is a widespread response to the metabolic defect in GD involving the liver, bone marrow, spleen and the lungs.

Acknowledgements

PKM is supported by a grant from the National Institutes of Arthritis, Musculoskeletal and Skin Diseases AR 65932 and Center of Excellence Grant in Clinical Translational Research from Genzyme, a Sanofi Company. He has received research support, honoraria and consulting fees from Genzyme.

References

- [1] P.K. Mistry, M.D. Cappellini, E. Lukina, H. Ozsan, S. Mach Pascual, H. Rosenbaum, et al., A reappraisal of Gaucher disease-diagnosis and disease management algorithms, *Am. J. Hematol.* 86 (1) (2011) 110–115.
- [2] P.K. Mistry, N. Belmatoug, S. vom Dahl, R. Giugliani, Understanding the natural history of Gaucher disease, *Am. J. Hematol.* 90 (Suppl. 1) (2015) S6–11.
- [3] M. de Fost, S. Vom Dahl, G.J. Weverling, N. Brill, S. Brett, D. Haussinger, et al., Increased incidence of cancer in adult Gaucher disease in Western Europe, *Blood Cells Mol. Dis.* 36 (1) (2006) 53–58.
- [4] R.H. Lachmann, D.G. Wight, D.J. Lomas, N.C. Fisher, J.P. Schofield, E. Elias, et al., Massive hepatic fibrosis in Gaucher's disease: clinico-pathological and radiological features, *QJM* 93 (4) (2000) 237–244.
- [5] R. Xu, P. Mistry, G. McKenna, S. Emre, T. Schiano, M. Bu-Ghanim, et al., Hepatocellular carcinoma in type 1 Gaucher disease: a case report with review of the literature, *Semin. Liver Dis.* 25 (2) (2005) 226–229.
- [6] S.M. Lo, J. Liu, F. Chen, G.M. Pastores, J. Knowles, M. Boxer, et al., Pulmonary vascular disease in Gaucher disease: clinical spectrum, determinants of phenotype and long-term outcomes of therapy, *J. Inher. Metab. Dis.* 34 (3) (2011) 643–650.
- [7] A. Dawson, D.J. Elias, D. Rubenson, S.H. Bartz, P.R. Garver, A.C. Kay, et al., Pulmonary hypertension developing after alglucerase therapy in two patients with type 1 Gaucher disease complicated by the hepatopulmonary syndrome, *Ann. Intern. Med.* 125 (11) (1996) 901–904.
- [8] D. Harats, R. Pauzner, D. Elstein, A. Many, M.W. Klutstein, M.R. Kramer, et al.,

- Pulmonary hypertension in two patients with type I Gaucher disease while on alglucerase therapy, *Acta Haematol.* 98 (1) (1997) 47–50.
- [9] R. Rodriguez-Roisin, M.J. Krowka, Is severe arterial hypoxaemia due to hepatic disease an indication for liver transplantation? A new therapeutic approach, *Eur. Respir. J.* 7 (5) (1994) 839–842.
- [10] A.E. Bohte, L. van Dussen, E.M. Akkerman, A.J. Nederveen, R. Sinkus, P.L. Jansen, et al., Liver fibrosis in type I Gaucher disease: magnetic resonance imaging, transient elastography and parameters of iron storage, *PLoS One* 8 (3) (2013) e57507.
- [11] R.E. Lee, The pathology of Gaucher disease, *Prog. Clin. Biol. Res.* 95 (1982) 177–217.
- [12] N.D. Theise, P.C. Ursell, Pulmonary hypertension and Gaucher's disease: logical association or mere coincidence? *Am. J. Pediatr. Hematol. Oncol.* 12 (1) (1990) 74–76.
- [13] W.C. Roberts, D.S. Fredrickson, Gaucher's disease of the lung causing severe pulmonary hypertension with associated acute recurrent pericarditis, *Circulation.* 35 (4) (1967) 783–789.
- [14] R.L. Smith, G.M. Hutchins, G.H. Sack Jr., R.L. Ridolfi, Unusual cardiac, renal and pulmonary involvement in Gaucher's disease. Interstitial glucocerebrosidase accumulation, pulmonary hypertension and fatal bone marrow embolization, *Am. J. Med.* 65 (2) (1978) 352–360.
- [15] R. Lee, S. Yousem (Eds.), *The Frequency and Type of Lung Involvement in Patients with Gaucher's Disease. Laboratory Investigation*, Williams & Wilkins 351 West Camden ST, Baltimore, MD, 1988, pp. 21201–22436.
- [16] E. Kerem, D. Elstein, A. Abrahamov, Y. Bar Ziv, I. Hadas-Halpern, E. Melzer, et al., Pulmonary function abnormalities in type I Gaucher disease, *Eur. Respir. J.* 9 (2) (1996) 340–345.
- [17] Y. Lv, D. Fan, Hepatopulmonary syndrome, *Dig. Dis. Sci.* 60 (7) (2015) 1914–1923.
- [18] F. Santamaria, G. Parenti, G. Guidi, M. Filocamo, P. Strisciuglio, G. Grillo, et al., Pulmonary manifestations of Gaucher disease: an increased risk for L444P homozygotes? *Am. J. Respir. Crit. Care Med.* 157 (3 Pt 1) (1998) 985–989.
- [19] P.K. Mistry, S. Sirrs, A. Chan, M.R. Pritzker, T.P. Duffy, M.E. Grace, et al., Pulmonary hypertension in type 1 Gaucher's disease: genetic and epigenetic determinants of phenotype and response to therapy, *Mol. Genet. Metab.* 77 (1–2) (2002) 91–98.
- [20] T. Thenappan, A. Goel, G. Marsboom, Y.H. Fang, P.T. Toth, H.J. Zhang, et al., A central role for CD68(+) macrophages in hepatopulmonary syndrome. Reversal by macrophage depletion, *Am. J. Respir. Crit. Care Med.* 183 (8) (2011) 1080–1091.
- [21] P.K. Mistry, J. Liu, M. Yang, T. Nottoli, J. McGrath, D. Jain, et al., Glucocerebrosidase gene-deficient mouse recapitulates Gaucher disease displaying cellular and molecular dysregulation beyond the macrophage, *Proc. Natl. Acad. Sci. U. S. A.* 107 (45) (2010) 19473–19478.
- [22] L.A. Boven, M. van Meurs, R.G. Boot, A. Mehta, L. Boon, J.M. Aerts, et al., Gaucher cells demonstrate a distinct macrophage phenotype and resemble alternatively activated macrophages, *Am. J. Clin. Pathol.* 122 (3) (2004) 359–369.
- [23] D.J. Ross, S. Spira, N.A. Buchbinder, Gaucher cells in pulmonary-capillary blood in association with pulmonary hypertension, *N. Engl. J. Med.* 336 (5) (1997) 379–381.
- [24] P.K. Mistry, E.P. Wraight, T.M. Cox, Therapeutic delivery of proteins to macrophages: implications for treatment of Gaucher's disease, *Lancet (London, England).* 348 (9041) (1996) 1555–1559.