

Technetium-99m methylene diphosphonate bone scan in evaluation of insufficiency fractures – A pictorial assay and experience from South India

ABSTRACT

Insufficiency fractures (IFs) can be challenging to diagnose due to varied presentations, and sometimes, it changes the course of treatment, as in cancer patients in whom it has to be differentiated with metastatic disease. We present the role of Technetium 99m methylene diphosphonate (^{99m}Tc -MDP) bone scan, which is a low-cost, simple to perform, whole body diagnostic investigation in the diagnosis of IFs. This is a retrospective analysis of all patients who underwent a ^{99m}Tc -MDP bone scan in a tertiary care teaching hospital during 2013–2017 and were diagnosed as having an IF on bone scan. The bone scans were performed on a dual-head gamma camera using low-energy high-resolution collimators. Of all the bone scan performed during 2013–2017, a total of 138 patients with a mean age of 57.5 ± 14.7 years were diagnosed as having IFs based on bone scan and final clinical diagnosis. Among them, the most common complaint was regional bony pain in 62% of patients, while the most common cause was osteoporosis in 47% of patients, both postmenopausal and senile osteoporosis. In all, 265 sites of fractures were identified with a fracture average of 1.9/patient, the most common site being dorsolumbar vertebrae, followed by ribs and lower limb bones. Many unusual sites were also identified such as talus, sternum, clavicle, and scapula. ^{99m}Tc -MDP bone scan, being noninvasive whole-body imaging, is a useful investigation for evaluation of IFs and in correlation with biochemical analysis and other imaging can be used to determine the etiology of IF.

Keywords: Dorsolumbar vertebrae, insufficiency fracture, osteoporosis, talus fracture, technetium-99m methylene diphosphonate bone scan

INTRODUCTION

Insufficiency fracture (IF) presents a diagnostic dilemma for the treating clinicians due to its varied presentation and multiple causes. The clinical presentation can be trivial, as seen in many elderly patients, from dull ache pain and many times fractures after insignificant trauma. IF is a relatively underdiagnosed entity that may lead to incorrect diagnosis and unnecessary investigations. There are many causes for IFs, the most common being osteoporosis which can be primary or senile osteoporosis and secondary osteoporosis.^[1] Other causes include Vitamin D deficiency, osteomalacia, hyperparathyroidism, prolonged corticosteroid therapy, renal failure, rheumatoid arthritis (RA), and postradiotherapy. The underlying mechanism for IF is the same in most of the causes,


i.e., “normal stress on abnormal bone.”^[2] Although IFs rarely cause mortality, it is important to diagnose them at the earliest to prevent morbidity in the form of restricted movement or immobility and its complications.

MADHUR KUMAR SRIVASTAVA, RAM MANOHAR PAGALA, VINODH KENDARLA, KAVITHA NALLAPAREDDY

Department of Nuclear Medicine, Nizams Institute of Medical Sciences, Hyderabad, Telangana, India

Address for correspondence: Dr. Kavitha Nallapareddy, Department of Nuclear Medicine, Nizams Institute of Medical Sciences, Hyderabad, Telangana, India. E-mail: drkavithanallapareddy@gmail.com

Submitted: 30-Nov-2020, **Revised:** 21-May-2021,
Accepted: 17-Jun-2021, **Published:** 25-Nov-2021

Access this article online	
Website: www.wjnm.org	Quick Response Code 
DOI: 10.4103/wjnm.wjnm_155_20	

This is an open access journal, and articles are distributed under the terms of the Creative Commons Attribution-NonCommercial-ShareAlike 4.0 License, which allows others to remix, tweak, and build upon the work non-commercially, as long as appropriate credit is given and the new creations are licensed under the identical terms.

For reprints contact: WKHLRPMedknow_reprints@wolterskluwer.com

How to cite this article: Srivastava MK, Pagala RM, Kendarla V, Nallapareddy K. Technetium-99m methylene diphosphonate bone scan in evaluation of insufficiency fractures – A pictorial assay and experience from South India. World J Nucl Med 2021;20:355-60.

Imaging plays an important role in the diagnosis of IF and includes radiographs, computed tomography (CT), magnetic resonance imaging (MRI), technetium-99m methylene diphosphonate (^{99m}Tc-MDP) bone scan, and fluorine-18 (F-18) bone scan. ^{99m}Tc-MDP is an important investigation to see bone turnover and has the ability to pick up IF much earlier as compared to radiographs and CT scan. Moreover, its cost-effectiveness scores over MRI and F-18 bone scans. It is important for radiologists and nuclear medicine physicians to know various patterns of IF and their normal and abnormal locations to prevent it from being misdiagnosed as a metastatic disease. As IFs are usually multifocal and distributed both in the axial and appendicular skeleton, the ^{99m}Tc-MDP bone scan is an ideal investigation to screen and scan the whole body at one go, as against other imaging. We evaluated the incidence, clinical presentation, and various sites of IF in a tertiary care hospital and discuss the role of ^{99m}Tc-MDP bone scan in its diagnosis.

MATERIALS AND METHODS

This is a retrospective analysis of ^{99m}Tc-MDP bone scan studies performed in a tertiary care teaching hospital from 2013 to 2017 and all patients in whom bone scan suggested IF were further studied. Most of these patients were referred from the department of orthopedics, nephrology, endocrinology, medical oncology, surgical oncology, radiation oncology, and internal medicine. History and demographic data were collected after retrieving the inpatient case records from the medical records department and the final diagnosis of the patient, as determined by the referring clinician, was used to compare the results of the bone scan. All patients included in the study had an inpatient record during or after the bone scan was performed. All ^{99m}Tc-MDP bone scans were performed in the Department of Nuclear Medicine on an E-Cam® dual-head gamma camera manufactured by Siemens® Medical Solutions, Erlangen, Germany, using low-energy high-resolution collimators.

Imaging protocol

All patients had been injected intravenously with 740–1110 MBq of ^{99m}Tc-MDP and delayed whole-body planar and spot static imaging was performed after 2–3 h. In a few cases, region-specific blood flow and blood pool images had been acquired immediately after the intravenous injection of the radiotracer. The patients had been asked to empty their bladder before the delayed imaging. The whole-body planar imaging was done from head to toe in 256 × 1024 at the rate of 10–12 cm/min. This was followed by static images of the concerned region taken in 256 × 256 matrix for 3–5 min. The whole process of scanning took approximately 20–30 min.

In a few cases, single photon-emission CT (SPECT) of the concerned region was performed. Whole-body planar and spot static images were displayed in anterior and posterior views, while SPECT images were displayed in axial, coronal, and sagittal planes. The images had been reviewed by experienced nuclear medicine physicians for interpretation and reporting. There are no known side effects of ^{99m}Tc-MDP injection; however, the patient gets a radiation average effective dose of 4.2 mSv which is equivalent to ~3 lumbar spine radiographs, which give a radiation average effective dose of 1.5 mSv.^[3]

RESULTS

During the 2013–2017 period, a total of 5013 ^{99m}Tc-MDP bone scans were performed in the Department of Nuclear Medicine, out of which 138 patients were diagnosed as having IF, based on bone scan findings and final clinical diagnosis. Out of these 138 patients, 81 were male patients (58.7%) and 57 were female patients (41.3%). The mean age at the time of the ^{99m}Tc-MDP bone scan was 57.5 ± 14.7 years with an age range of 21–85 years. The maximum number of patients ($n = 59$) were in the 61–80 years' age group followed by 52 patients in the 41–60 years' age group [Figure 1]. None of the patients was below 21 years of age. Out of these 138 patients, the indication for a bone scan in 85 patients (62%) was regional bony pain, for example, pelvic pain. Thirty patients (22%) presented with suspected pathological fractures and were referred for the skeletal survey. Fourteen patients (10%) had a ^{99m}Tc-MDP bone scan performed for metastatic workup where radiograph was suspicious of metastatic disease. In six patients (4%), multiple myeloma was suspected and a ^{99m}Tc-MDP bone scan was performed to rule out any other

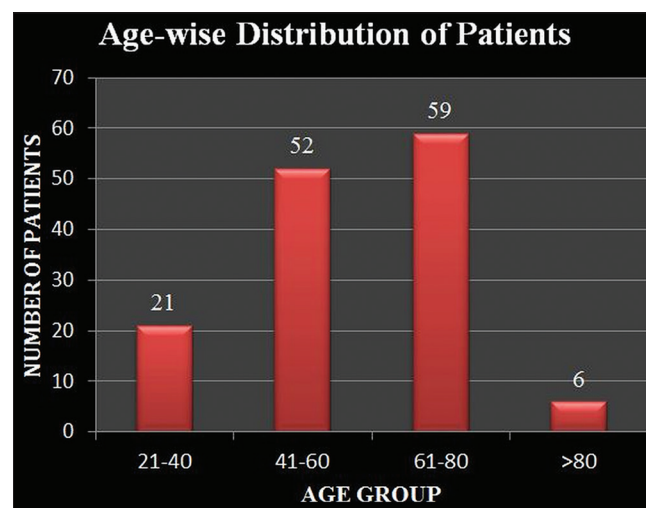


Figure 1: Age-wise distribution of patients, with the maximum patients in the age group of 61–80 years followed by patients in the age group of 41–60 years

cause. In the remaining three patients (2%), two patients had suspected tuberculosis and one patient was after total knee replacement surgery.

Among the various causes of IF [Figure 2], osteoporosis was seen most commonly in 65 patients (47%), of which postmenopausal osteoporosis, also called Type I osteoporosis, was noted in 35 patients and senile osteoporosis, also called Type II osteoporosis, in 30 patients. IF due to chronic kidney

disease [Figure 3] was seen in 33 patients (24%) and due to osteomalacia in 22 patients (16%). Drug-induced IF was seen in five patients (4%), out of which four were after prolonged steroid use and one was after prolonged bisphosphonate therapy. In six patients (4%), IF was secondary to primary hyperparathyroidism [Figures 4 and 5], while three (2%) patients had RA. IF after undergoing radiation therapy was noted in four patients (3%).

In all, 265 sites of abnormal increased ^{99m}Tc-MDP were noted in 138 patients, considered to be due to IF [Figure 6]. Fractures averaged 1.9/patient (range, 1–7 fractures/patient). In 91 patients (66%), multiple sites of IF were seen,

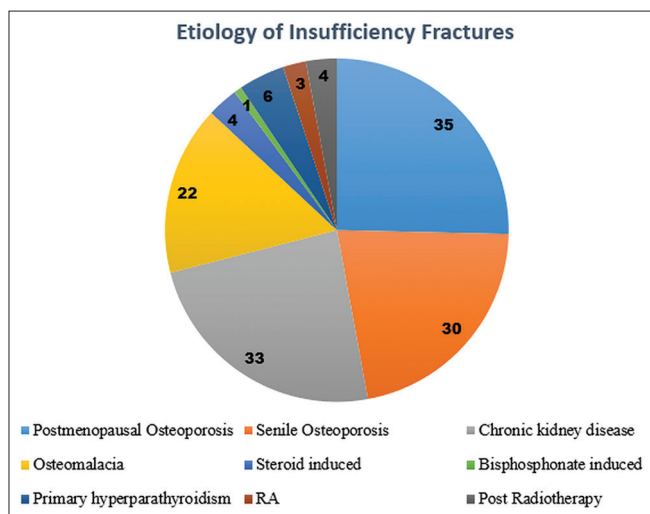


Figure 2: Etiology of insufficiency fractures (Numbers indicate the number of patients). Insufficiency fractures due to Osteoporosis, including Postmenopausal (Type I) and Senile (Type II) was the most common etiology followed by chronic kidney disease

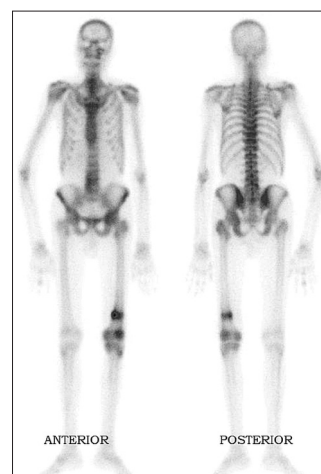


Figure 3: A 40-year man with a history of CKD, presenting with severe pain in the left thigh after trivial trauma. The skeletal survey by bone scan showed horizontal linear uptake in distal femur suggestive of insufficiency fracture in the background of CKD. Furthermore, kidneys are not visualized suggestive of high turnover bone disease as seen in renal osteodystrophy

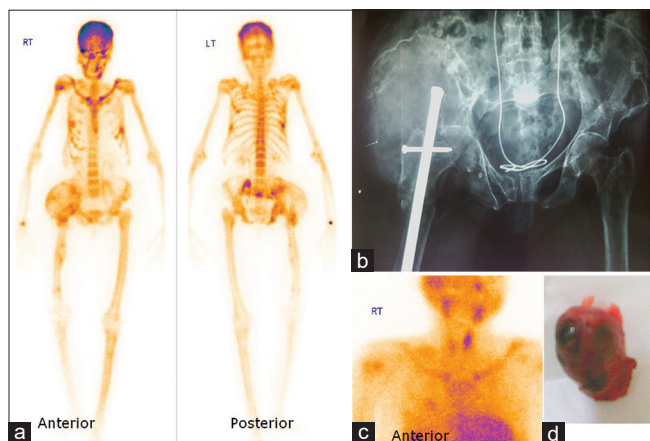


Figure 4: A 61-year female presenting with a lytic lesion involving the right acetabulum and right femoral head on the radiograph (b). Technetium-99m methylene diphosphonate bone scan (a) was performed as part of the metastatic survey. It showed findings of superscan with insufficiency fractures and brown tumor suggested the diagnosis of primary hyperparathyroidism which was confirmed on the parathyroid scintigraphy, done after injecting 555 MBq of technetium-99m methoxy-isobutyl-isonitrile (MIBI) scan and acquiring anterior images of neck and upper thorax at 20 min and 2 h which showed parathyroid adenoma in the left upper parathyroid gland (c). The patient was operated and parathyroid adenoma was removed (d). At present, the patient is doing well after 1 year of follow-up

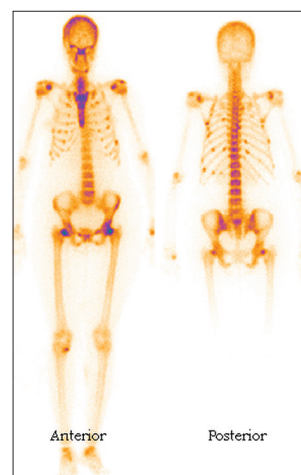


Figure 5: A 36-year male with a history of recurrent pancreatitis and severe bone pains sent for skeletal survey. It showed features of superscan with multiple insufficiency fractures involving ribs, the neck of both femora, bilateral scapula, and right tibia. Elevated parathormone in this context confirms the diagnosis of primary hyperparathyroidism

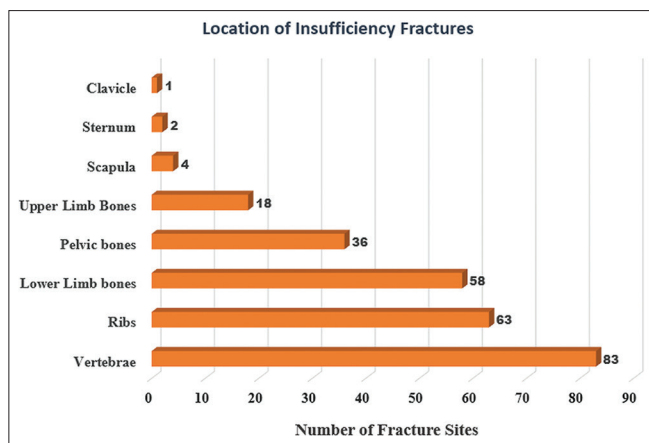


Figure 6: Location of insufficiency fracture (numbers indicate the number of patients). Most common location was seen in vertebrae, ribs, and lower limb bones

while 47 patients (34%) had single-site involvement. In 265 sites of IF, the dorsolumbar spine was most commonly involved ($n = 83$) followed by ribs ($n = 63$). Lower limb bones (femur, tibia, fibula, calcaneus, and talus) had 58 sites of IF, while upper limb bones (humerus, radius, and ulna) had 18 sites. Pelvic bones (sacrum, pubic, and iliac bones) showed 36 sites of IF. Four sites of IF were noted in the scapula, two in the sternum, and one in the clavicle. Few unusual sites of IF noted were in the talus, sternum, clavicle, scapula, and iliac wings. It is important to know the usual and unusual sites of IF to prevent misdiagnosis.

DISCUSSION

The incidence of IF increases with age and is more common in females as compared to males. Melton *et al.*^[4] showed the incidence of IF as 37/100,000 person-years increasing to 446.3/100,000 person-years in women 85 or older. Our analysis also had a higher proportion of the elderly population and more cases of osteoporosis compared to other etiologies. The overall increase in the aging population results in an increase in IF with each passing year as shown by Burge *et al.*^[5] who projected that the annual rate of osteoporosis-related fractures would rise by almost 50% by the year 2025, as compared to the year 2005. Similarly, Lin *et al.*^[6] showed an 8.6% increase in the incidence of all types of hip fractures over the period of 2000–2010, age being the most important risk factor for it.

The most common predisposing factor for IF is postmenopausal (Type I) and senile (Type II) osteoporosis.^[7] Similar results were obtained in our study also with 47% of IFs attributed to osteoporosis with almost equal incidence due to postmenopausal state and due to senile cause. With an increase in the aging population, diagnosis of IF

in this age group is becoming a great challenge. The basic difference between Type I and Type II osteoporosis is the role of osteoclast activity. In Type I osteoporosis, due to loss of estrogen drive, there is an increase in serum cytokines levels which, in turn, increases the recruitment of osteoclast precursors resulting in augmented bone resorption. This most commonly involves fractures of the trabecular bone-like distal forearm and vertebral bodies. In Type II osteoporosis, seen in the normal aging process, there is reduced osteoblastic activity without an increase in osteoclastic activity ultimately leading to decreased bone formation and delayed fracture healing process. This is commonly seen as a fracture of cortical bones like the neck and shaft of the femur, proximal tibia, and pelvis.^[8]

In our study, three patients had RA-related IF which can be per se due to disease activity resulting from bone erosions and osteopenia-related bone fragility aggravated by other factors such as increased vascularity, inactivity, and steroid therapy.^[9,10] Even methotrexate, used in the treatment of RA, in low doses can induce osteopathy leading to IFs.^[11] One patient in our study, presenting with IF, was on prolonged bisphosphonate therapy. Although bisphosphonates are used for the prevention of fractures, their prolonged use has been associated with an increased risk of fractures. The reasons, being inhibition of osteoclast function and an increase in apoptosis leading to suppression of bone turnover rate, thereby reducing the heterogeneity of organic matrix and mineralization causing accumulation of microdamages and deterioration of bone quality, all leading to increased chances of fractures.^[12,13] This phenomenon is more pronounced in Asians than in the American population.^[13] Hence, IFs should be considered in patients who are on prolonged bisphosphonate therapy and present with bony pain.

In few patients presenting with bone pain, multiple myeloma was suspected and a ^{99m}Tc-MDP bone scan was requested to rule out other causes. Multiple myeloma is associated with purely lytic skeletal lesions which appear as photopenic areas on bone scan. However, if any of these lytic lesions show cortical break, then there is associated bony sclerosis which shows increased MDP uptake. In addition, the kidneys in multiple myeloma patients usually show increased MDP uptake, the reason attributed is increased tissue calcium levels, which may or may not be associated with the hypercalcaemic state seen in multiple myeloma.^[14,15] Other conditions associated with IF usually show normal/reduced uptake in kidneys.

Although our analysis did not have any pediatric case, many times, similar appearance of multiple hot spots, as seen in

IF, can be seen in children and this pattern strongly suspects child abuse. The child abuse can be differentiated with IF, to some extent, with predominant involvement of long bones (metaphyseal), skull, vertebrae, ribs, scapula, and facial bones, associated soft-tissue component and SPECT/CT or radiographs showing fractures in different stages of healing.^[16,17]

The most common sites involved in IF are the spine, pelvis, and lower extremities.^[5,7,18] Our study had similar results, with dorsolumbar spine being most commonly involved followed by ribs and lower extremity. For reasons unknown, the pelvis was less commonly involved in our study as compared to other sites. In pelvis, the sacrum was most commonly involved, as seen in other studies.^[2,19,20]

MRI is considered a very reliable investigation for diagnosis of IFs due to its high soft-tissue contrast, able to detect fracture line, bone marrow edema, and multiplanar imaging,^[21] but its use is limited due to specific region imaging, high cost, and claustrophobic environment. Instead, a bone scan using ^{99m}Tc-MDP is now being commonly used imaging study for IFs due to whole-body imaging, low cost, and easy imaging technique. Zhong *et al.*,^[21] in their article, concluded that MRI is a useful diagnostic technique for further characterization of postradiotherapy pelvic lesions which show increased uptake on the ^{99m}Tc-MDP bone scan. With the use of SPECT and SPECT/CT, the sensitivity and specificity of detecting lesions seem on planar bone scans have further increased.^[22,23] Even in the diagnosis of occult lesions, a bone scan with SPECT/CT is very helpful.^[24]

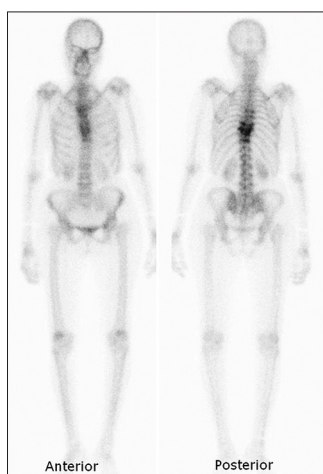

Figure 7: A 65-year-old patient who underwent esophagectomy and chemoradiation for adeno-carcinoma of esophagus, now presented with pain in the upper back. Technetium-99m methylene diphosphonate bone scan showed increased tracer uptake in contiguous dorsal vertebrae (D7-10) with no other focal hot spot. As the methylene diphosphonate uptake was coming at the site of radiation port, this was interpreted as radiotherapy induced insufficiency fractures and the patient was managed conservatively. The patient is fine after a follow-up of 2 years

Krumme *et al.*^[25] in their study concluded that bone scan is an “underused tool” in the evaluation and management of orthopedic patients including those presenting with IFs and the authors concur with that.

The history of the patient plays an important role in the evaluation of any lesion including IFs. It could be challenging to diagnose IF in the case of single-site involvement where history and other correlative imaging play an important role. Similarly, the involvement of unusual sites warrants further investigation unless history and other imaging are in favor of IFs. In our analysis, all unusual sites of IF were seen along with usual sites of IF, like right talus was involved with other areas of IF in ribs and both femora, thereby making a diagnosis of IF easier.

Few points which should raise suspicion of IFs are (1) symmetrical involvement of skeletal sites, which is highly unlikely in metastatic disease; (2) radiotracer uptake conforming to radiation site treatment port [Figure 7]; (3) overall pattern of radiotracer uptake like focal radiotracer uptake in multiple ribs in a patient with metabolic super-scan [Figure 5]; (4) knowledge of various well-known signs of IFs like H-shaped Honda sign^[26] [Figure 8] and Bow sign;^[27] and (5) proper history taking like intake of drugs causing IF. Hence, symmetrical MDP uptake in the skeleton, features of super-scan or metabolic scan on ^{99m}Tc-MDP bone scan, supplemented with history and suitable investigations can point toward IFs, thereby preventing further costlier workup.

The limitation of this study is its retrospective design. For final diagnosis, the authors relied on clinical final diagnosis

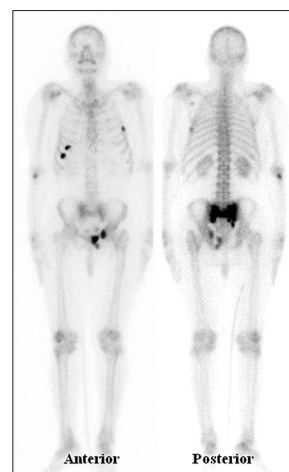


Figure 8: A 74-year-old female presented with severe backache and inability to get up from the bed. Tc-99m methylene diphosphonate bone scan showed intense tracer uptake in the sacrum (Honda Sign) and focal tracer uptake in multiple ribs and anterior pubis suggestive of multiple insufficiency fractures

as determined by the referring physician and did not further analyze correlative imaging findings or biochemical analysis used for reaching the final diagnosis, though it might have helped in substantiating the final diagnosis.

CONCLUSION

IFs are increasing in number and it is imperative to diagnose them for proper management and prevent further unnecessary and costly investigations. ^{99m}Tc-MDP bone scan is a very useful imaging tool for the evaluation of IFs due to its easy availability, whole-body imaging, low cost, and can replace other costlier investigations.

Financial support and sponsorship

Nil.

Conflicts of interest

There are no conflicts of interest.

REFERENCES

- Tarantino U, Iolascon G, Cianferotti L, Masi L, Marcucci G, Giusti F, *et al.* Clinical guidelines for the prevention and treatment of osteoporosis: Summary statements and recommendations from the Italian Society for Orthopaedics and Traumatology. *J Orthop Traumatol* 2017;18 Suppl 1:3-36.
- Cabarrus MC, Ambekar A, Lu Y, Link TM. MRI and CT of insufficiency fractures of the pelvis and the proximal femur. *Am J Roentgenol* 2008;191:995-1001.
- Fahey FH, Treves ST, Adelstein AJ. Minimizing and communicating radiation risk in pediatric nuclear medicine. *J Nucl Med* 2011;52:1240-51.
- Melton LJ 3rd, Sampson JM, Morrey BF, Ilstrup DM. Epidemiologic features of pelvic fractures. *Clin Orthop Relat Res.* 1981;(155):43-7.
- Burge R, Dawson-Hughes B, Solomon DH, Wong JB, King A, Tosteson A. Incidence and economic burden of osteoporosis-related fractures in the United States, 2005-2025. *J Bone Miner Res* 2007;22:465-75.
- Lin KB, Yang NP, Lee YH, Chan CL, Wu CH, Chen HC, *et al.* The incidence and factors of hip fractures and subsequent morbidity in Taiwan: An 11-year population-based cohort study. *PLoS One* 2018;13:e0192388.
- Vaishya R, Agarwal AK, Banka PK, Vijay V, Vaish A. Insufficiency fractures at unusual sites: A case series. *J Orthop Case Rep* 2017;7:76-9.
- Simpson AH, Murray IR. Osteoporotic fracture models. *Curr Osteoporos Rep* 2015;13:9-15.
- Resnick D, Cone R. Pathological fractures in rheumatoid arthritis: Sites and mechanisms. *Radiographics* 1984;4:549-62.
- Spina A, Clemente A, Vancini C, Fejzo M, Campioni P. Spontaneous talar and calcaneal fracture in rheumatoid arthritis: A case report. *J Radiol Case Rep* 2011;5:15-23.
- Trickey JC, Barkham N. Foot and ankle insufficiency fractures in rheumatoid arthritis: A case series. *Rheumatology* 2015;54 Suppl 1:i57.
- Saita Y, Ishijima M, Kaneko K. Atypical femoral fractures and bisphosphonate use: Current evidence and clinical implications. *Ther Adv Chronic Dis* 2015;6:185-93.
- Black DM, Geiger EJ, Eastell R, Vittinghoff E, Li BH, Ryan DS, *et al.* Atypical femur fracture risk versus fragility fracture prevention with bisphosphonates. *N Engl J Med* 2020;383:743-53.
- Buxton-Thomas MS, Wraith EP. High renal activity on bone scintigrams. A sign of hypercalcaemia? *Br J Radiol* 1983;56:911-4.
- Siddiqui AR. Increased uptake of technetium-99m-labeled bone imaging agents in the kidneys. *Semin Nucl Med* 1982;12:101-2.
- Chuang YW, Hsu CC, Chang CC, Lin CY, Chu HL, Huang YF, *et al.* Multiple bony injuries on bone scan in a case of unsuspected child abuse. *Case Rep Med* 2017;2017:1-4.
- Fong CM, Cheung HM, Lau PY. Fractures associated with non-accidental injury – An orthopaedic perspective in a local regional hospital. *Hong Kong Med J* 2005;11:445-51.
- Cooper KL. Insufficiency stress fractures. *Curr Probl Diagn Radiol* 1994;23:29-68.
- Kwon JW, Huh SJ, Yoon YC, Choi SH, Jung JY, Oh D, *et al.* Pelvic bone complications after radiation therapy of uterine cervical cancer: Evaluation with MRI. *AJR Am J Roentgenol* 2008;191:987-94.
- Lapina O, Tiškevičius S. Sacral insufficiency fracture after pelvic radiotherapy: A diagnostic challenge for a radiologist. *Medicina (Kaunas)* 2014;50:249-54.
- Zhong X, Li J, Zhang L, Lu B, Yin J, Chen Z, *et al.* Characterization of insufficiency fracture and bone metastasis after radiotherapy in patients with cervical cancer detected by bone scan: Role of magnetic resonance imaging. *Front Oncol* 2019;9:183.
- Bryant LR, Song WS, Banks KP, Bui-Mansfield LT, Bradley YC. Comparison of planar scintigraphy alone and with SPECT for the initial evaluation of femoral neck stress fracture. *Am J Roentgenol* 2008;191:1010-5.
- Zhang L, He Q, Jiang M, Zhang B, Zhong X, Zhang R. Diagnosis of insufficiency fracture after radiotherapy in patients with cervical cancer: Contribution of Technetium Tc 99m-labeled methylene diphosphonate single-photon emission computed tomography/computed tomography. *Int J Gynecol Cancer* 2018;28:1369-76.
- Scheyerer MJ, Hüllner M, Pietsch C, Werner CM, Veit-Haibach P. Evaluation of pelvic ring injuries using SPECT/CT. *Skeletal Radiol* 2015;44:217-22.
- Krumme JW, Lauer MF, Stowell JT, Beteslassie NM, Kotwal SY. Bone scintigraphy: A review of technical aspects and applications in orthopedic surgery. *Orthopedics* 2019;42:e14-24.
- Schneider R, Yacovone J, Ghelman B. Unsuspected sacral fractures: Detection by radionuclide bone scanning. *Am J Roentgenol* 1985;144:337-41.
- Srivastava MK, Nallapareddy K, Pagala RM, Kendarla VK. Iliac insufficiency fracture: “Bow sign” on bone scan. *Indian J Nucl Med* 2019;34:317-8.