

MEETING ABSTRACT

Open Access

Endovascular repair for acute mesenteric ischemia: case report

L Fiengo^{1*}, C Paciotti¹, G Patrizi¹, L Venturini¹, A Pucci², F Fanelli², A Bruni², M Allegritti², A Redler¹

From XXIII Annual Meeting of the Italian Society of Geriatric Surgery
Lecce, Italy. 2-4 December 2010

Background

Acute mesenteric ischemia (AMI) is an abdominal emergency caused by: embolism (40-50%), with Superior Mesenteric Artery (SMA) thrombosis (20-25%), mesenteric venous thrombosis (5%) and non occlusive mesenteric ischemia (20%). The mortality rate is high and ranges from 64 to 93%.

Methods

We present a case of a 75-year-old patient with acute occlusive mesenteric ischemia that was successfully treated with endovascular intervention.

Angiography revealed high-grade stenosis of the proximal tract of the SMA. Immediate option for endovascular therapy was made, and a MARIS self-expandable 6x40 mm stent was positioned. The patient was discharged 2 days after with full recovery from the symptoms.

Results

Control angiography showed the correct apposition of the stent and regular flow inside. The patient was symptom free 12 months later.

Conclusions

We suggest that the endovascular technique is a valid option in patients with AMI preventing intestinal infarction.

Author details

¹Department of Vascular and General Surgery, Faculty of Medicine "La Sapienza", Roma, Italy. ²Department of Vascular and Interventional Radiology, Faculty of Medicine "La Sapienza", Roma, Italy.

* Correspondence: lesliefiengo@hotmail.com

¹Department of Vascular and General Surgery, Faculty of Medicine "La Sapienza", Roma, Italy

Full list of author information is available at the end of the article

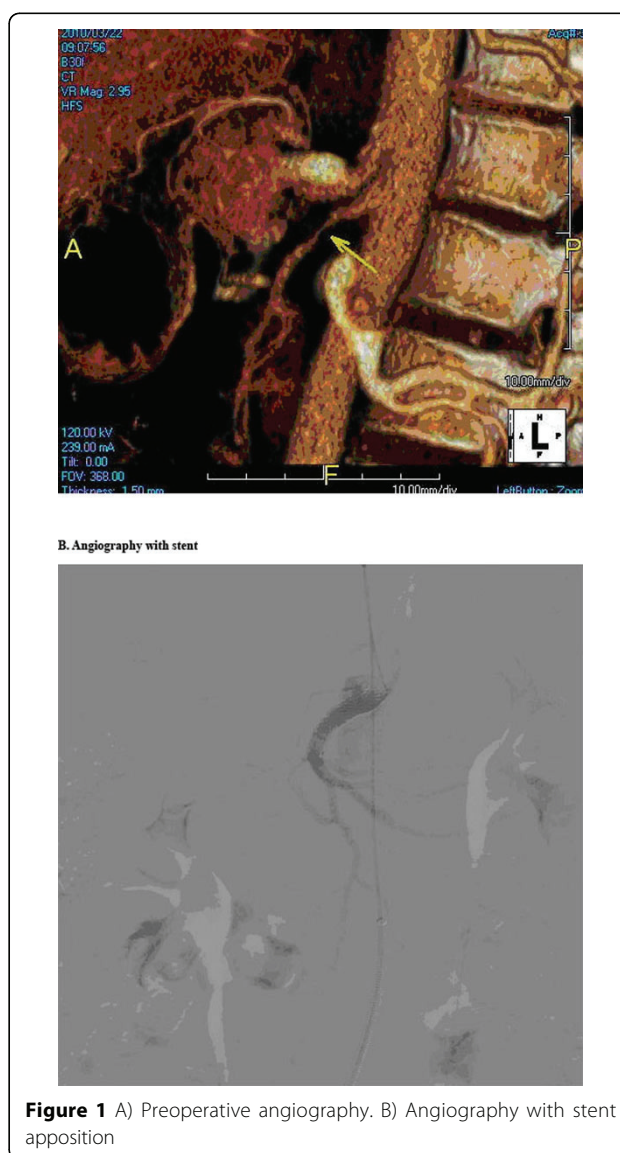


Figure 1 A) Preoperative angiography. B) Angiography with stent apposition

Published: 24 August 2011

References

1. Peck MA, Conrad MF, Kwolek CJ, LaMuraglia GM, Paruchuri V, Cambria RP: **Intermediate-outcomes of endovascular treatment for symptomatic chronic mesenteric ischemia.** *J Vasc Surg* 2010, **51**:140-7.
2. Aksu C, Demirpolat G, Oran I, Parildar M, Memis A: **Stent Implantation in Chronic Mesenteric Ischemia.** *Acta Radiol* 2009, **50**:610-616.
3. Atkins MD, Kwolek CJ, LaMuraglia GM, Brewster DC, Chung TK, Cambria RP: **Surgical revascularization versus endovascular therapy for chronic mesenteric ischemia: a comparative experience.** *J Vasc Surg* 2007, **45**:1162-71.
4. Nyman U, Ivancev K, Lindh M, Uher P: **Endovascular Treatment of Chronic Mesenteric Ischemia: report of Five Cases.** *Cardiovasc Intervent Radiol* 1998, **21**:301-313.
5. Demirpolat G, Oran I, Tamsel S, Parildar M, Memis A: **Acute mesenteric ischemia: endovascular therapy.** *Abdom Imaging* 2007, **32**:299-303.
6. Fioule B, van de Rest HJM, Meijer JRM, van Leersum M, van Koeverden S, Moll FL, van den Berg JC, de Vries PM JP: **Percutaneous transluminal angioplasty and stenting as first-choice treatment in patients with chronic mesenteric ischemia.** *J Vasc Surg* 2010, **51**:386-391.

doi:10.1186/1471-2318-11-S1-A17

Cite this article as: Fiengo et al.: Endovascular repair for acute mesenteric ischemia: case report. *BMC Geriatrics* 2011 **11**(Suppl 1):A17.

**Submit your next manuscript to BioMed Central
and take full advantage of:**

- Convenient online submission
- Thorough peer review
- No space constraints or color figure charges
- Immediate publication on acceptance
- Inclusion in PubMed, CAS, Scopus and Google Scholar
- Research which is freely available for redistribution

Submit your manuscript at
www.biomedcentral.com/submit

