

CASE REPORT

Accuracy of mucosa supported guided dental implant surgery

Andoni Jones 

Private practice in Dublin

Correspondence

Andoni Jones, 20 Broadfield Heights,
Rathcoole, Ireland.
Email: andoni.jones@gmail.com

Key Clinical Message

Implant deviation at platform and apex was comparable to that seen in similar studies, showing that Mucosa Supported Guided Dental Implant Surgery can be a safe implant placement technique. Implant diameter and length, bone density and density deviations showed moderate strong correlation with apical deviation.

KEYWORDS

accuracy, bone density, dental implant, guided surgery, post-extraction implant

1 | INTRODUCTION

Implant therapy has become a standard procedure to treat the edentulous patient.^{1,2} As the demand of implant procedures has increased, different approaches have been used to treat the more complex cases.³ Guided implant surgery was introduced into clinical practice over a decade ago to place implants in a precise way and reduce intraoperative human error.⁴

Implant osseointegration alone is not enough to determine implant success nowadays.⁵ The implant and restoration must be surrounded by healthy and stable tissues, and offer a good esthetic outcome.⁶ Implant malposition can lead to peri-implant soft tissue and bone loss, peri-implant disease and esthetic compromise of the restoration.⁷ It can be a challenge to restore implants that are not correctly placed in the prosthetic corridor.⁸

The main advantage of computer-guided surgery is the ability to preplan the prosthetic needs of the patient and incorporate them into the surgical planning.⁹ This allows the clinician to deliver the implants in a prosthetic and biologically driven way, to place them into sufficient hard and soft tissue and at the same time avoid prosthetic complications, such as compromised esthetics or comfort.¹⁰ In summary, to have a smooth and predictable workflow from implant placement to restoration.⁴

The main challenge remains in transferring the 3D implant planning accurately from the computer screen into the

patient's oral cavity.¹¹ The scientific evidence in the field of MSGS is scarce, with few clinical studies in humans.¹² The objective of this study was to contribute more data regarding its accuracy and assess if implant diameter (ID), implant length (IL), bone density (BD) and bone density deviations (BDD) had an impact in the results. The null hypothesis was that these four variables did not affect implant deviation.

2 | MATERIALS AND METHODS

2.1 | Study design

This observational study was a retrospective data collection that did not alter the standard treatment protocols (radiologic exposure, prosthetic planning, surgical management, and implant loading protocol) implemented by the author to treat the full-arch implant patient in private clinical practice. The procedures were carried out between December 2014 and June 2016 by the same operator in a private clinical setting in Dublin, Ireland. This study was carried out following STROBE guidelines.

2.2 | Patient selection

Patients needing full-arch fixed implant restorations were included in this study. Patients had to be fit for implant surgery, ASA I, and ASA II, without contraindicating medical

history or medication. Patients without sufficient native bone and with the need for grafting were excluded. Only fully mucosa supported guided procedures were included; in those cases where remaining teeth were still present, these were removed prior to seating the surgical guides (Figure 1).

2.3 | 3D planning protocol

A teeth set up in the desired prosthetic position with the correct function and esthetics was prepared. The set up was transformed into a scanning appliance, using clear acrylic and gutta-percha markers.¹³ The scanning appliance was relined in the patient's mouth with self-curing Bis-acrylic Composite (Protemp™, 3M ESPE AG, Seefeld, Germany), which had the same radiopacity as the scanning appliance's acrylic material; therefore, both materials were undistinguishable on a CBCT. This was done to ensure complete and intimate fitting of the scanning appliance onto the patient's mucosa and eliminate air gaps. Dual scan protocol was used¹⁴ to merge the scanning appliance into the 3D Implant Planning Software (Nemoscan, Nemotec, Madrid, Spain). The same CBCT unit (Carestream Cs 9300, Carestream, NY, New York, USA) was used to take all preoperative and postoperative scans, with a 1 mm slice thickness and 0.5 mm voxel size.

The prosthetic plan was imported into the implant planning software (Nemoscan), and BEGO Semados® S implants (BEGO GmbH & Co. KG, Bremen, Germany) were virtually placed to meet the prosthetic needs of the patient. Once the planning was completed, the DICOM files were sent to the surgical guide manufacturing center (Nemotec) to prepare the stereolithographic guides. A single guide to direct every step of the guided surgical procedure (fully guided surgery, including implant insertion through the guide) was manufactured.

Bone density average (BD) and bone density deviation (BDD) of each implant site were three-dimensionally measured in Hounsfield units using the Nemoscan software.

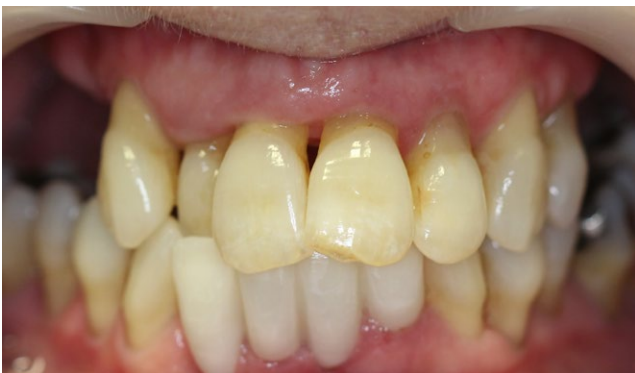

FIGURE 1 Initial situation, patient requiring the extraction of the remaining seven maxillary teeth

2.4 | Surgical protocol

Patients received prophylactic antibiotic therapy and local articaine anesthesia. Full seating of the surgical guides was verified by tissue blanching visible via the clear surgical guides, as well as by direct visualization through the metal drilling cylinders. Digital pressure bilaterally on the premolar-molar region of the guides was applied to immobilize the guides before inserting 3 metal pins in buccal to further secure the guide (Figure 2).

Following the guided surgery protocol of the manufacturer (BEGO Guide System, BEGO GmbH & Co. KG), diameter reducing spoons were used inside the metal cylinders to match every drill, preparing osteotomies in a diameter increasing way. Every drill had vertical stops.

The final drill of each osteotomy was dictated by the 3D planning and guided surgery report (Nemoscan), which considered the bone density to decide whether to use a final hard bone drill or not (countersink, screw tap drill).

Implants were placed with guided surgery insertions tools which matched the metal cylinders on the surgical guides, with vertical stops. The surgical guide had indexing points to get proper orientation of the implant platform internal hex.

Osteotomies were prepared and implants placed one at a time, removing the implant insertion tools before proceeding with the next osteotomy. Guide position and immobilization were checked before and during every drilling and implant insertion step.

2.5 | Radiologic merging and deviation measuring

After placing the implants, the surgical guide was removed, and a final CBCT was taken using the same scanning appliance and radiologic protocol as during the planning procedure. Full

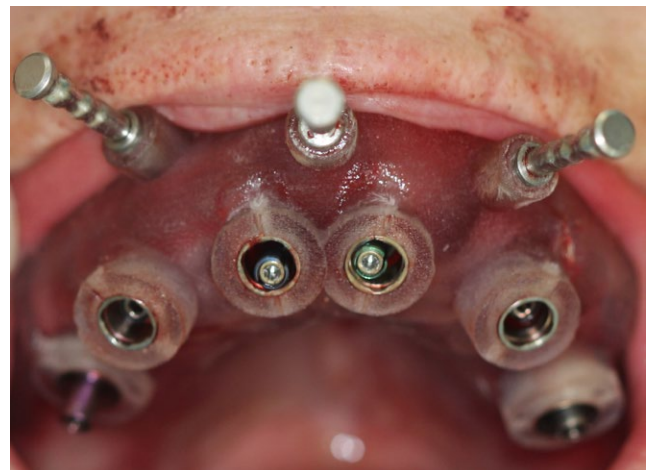

FIGURE 2 Surgical guide in situ. Fixed with three pins. Six implants placed




FIGURE 3 3D view of preoperative and postoperative (green color) implants of the same patient merged

seating of the scanning appliance to reproduce the preoperative registration was verified intraorally and digitally, making sure of the absence of air between mucosa and scan appliance on the CBCT,¹⁵ before importing it into the planning software (Nemoscan) (Triple Scan Technique,¹⁶ (Figure 3).

Measurements of platform and apex deviations were taken in the planning software (Nemoscan). Each implant was assessed and measured in cross-section and transversal images. This way, the highest deviation value three dimensionally around the implant was looked for and recorded in millimeters. Apex measurements were taken from the apical center of the virtual implant to the apical center of the placed implant.

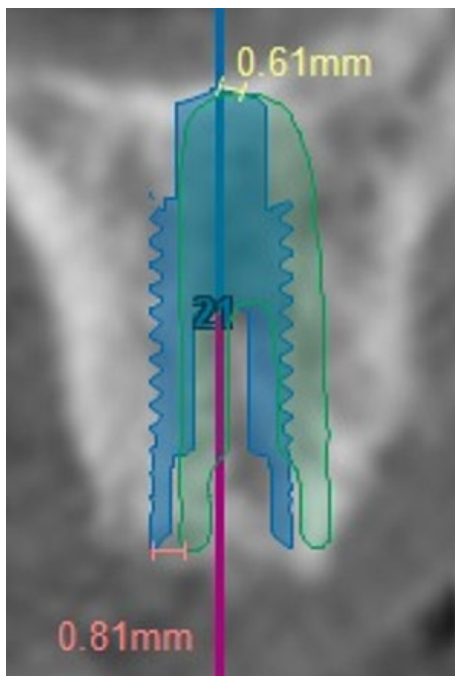


FIGURE 4 Cross-section of the preoperative and postoperative (green outline) merge of an implant in the maxillary left central incisor area. Deviation in apical and platform measured

The vertex was used to take references and measurements at platform level (Figure 4).

2.6 | Statistical analysis

The main purpose of the statistical analysis was to determine if there was any relationship between ID, IL, BD and BDD and deviations at apex (DA) and platform (DP). Therefore, the first four were considered independent variables for statistical modeling purposes and the latter two were the dependent variables. Both deviations (apex and platform) were considered to follow a normal distribution.

Differences in deviation between patients, between implants placed into post-extractions sites vs healed sites, and between implants placed in partially edentulous and fully edentulous patients were also studied in this paper.

3 | RESULTS

Thirty-one implants were placed into six patients, all in the maxilla (average 5.16 implants per arch). Four patients had edentulous arches, two were partially dentated, but got the teeth removed to seat the mucosa supported guides. Four implants were placed into post-extraction sites (12.9% of the sample), all in the same patient. Postoperative CBCT showed all implants were placed within safety limits inside the bony walls and away from important anatomic structures. It was possible to load all implants immediately using a screw-retained full-arch provisional restoration (Figure 5). Three months later, provisional restorations were removed, and all implants had successfully osseointegrated. The implants were then restored with definitive screw-retained restorations (Figures 6, 7, 8 and 9).

Average deviation at the platform was 1.05 mm (max. 2.05 mm) and at the apex 1.08 mm (max 1.92 mm). Standard

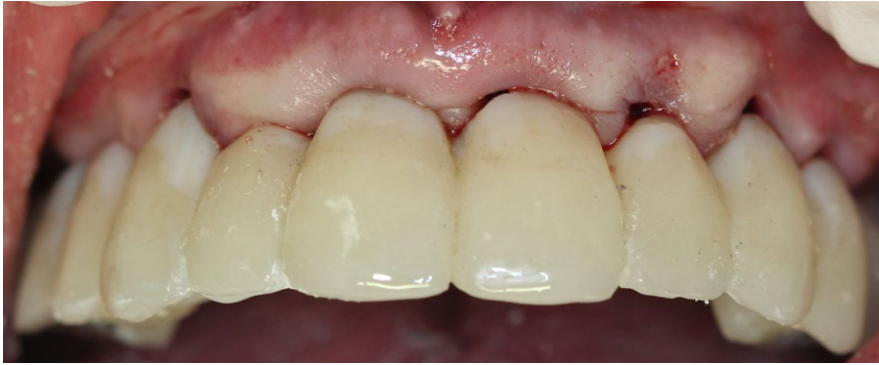

FIGURE 5 Immediate screw-retained polymethyl methacrylate (PMMA) provisional restoration

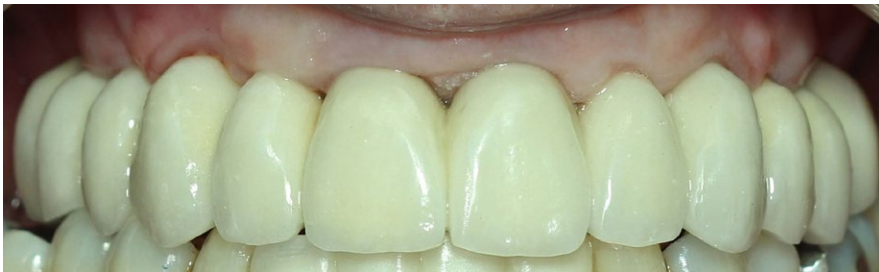

FIGURE 6 Final metal-ceramic screw-retained full-arch bridge

deviation of the deviation was 0.46 mm at the platform and 0.53 mm at the apex (Table 1).

3.1 | Correlation between variables and deviation

Pearson R and R^2 were calculated for each of the four independent variables individually (ID, IL, BD, and BDD) in order to measure possible correlation of the independent variables with both deviation at apex (DA) and deviation at platform (DP) (Table 2).

These results led to the conclusion that the independent variables individually were not correlated with the deviations.

For measuring the relationship between combined independent variables with DA and DP, two linear regression models were run.

The relationship between DA and the four independent variables was proven to be moderately strong. For DP, there was no statistical proof of relationship between the variables; however, correlation was higher combining variables than when independent variables were considered individually.

3.2 | Difference in deviations between patients

An ANOVA test was conducted in order to determine if there were significant differences in deviations between patients.

3.2.1 | For platform deviation

P -value = 0.06, so we rejected the null hypothesis (equal means for different patients) with a 10% significance level.

About 33% of the variance was explained by the variance between patients, and 67% was due to variance among implants.

3.2.2 | For apex deviation

P -value = 0.055, so we rejected the null hypothesis (equal means for different patients) with a 10% significance level.

About 34% of the variance was explained by the variance between patients, and 66% was due to variance among implants.

There were differences in deviation between patients, but the differences were not explained by intrinsic characteristics of the patients, but instead by characteristics of the individual implants.

3.3 | Difference in deviations of post-extraction implants vs healed sites

Four of the implants were placed in post-extraction sites. These implants seemed to have higher deviations as compared to implants placed in healed sites (Table 3).

Group 1 referred to the four implants placed in post-extraction sites; group 2 was made up of the other 27 implants placed into healed sites.

It could be concluded that in both cases (DA and DP), post-extraction implants resulted in a higher deviation (+22% in the sample for DP and +42% for DA).

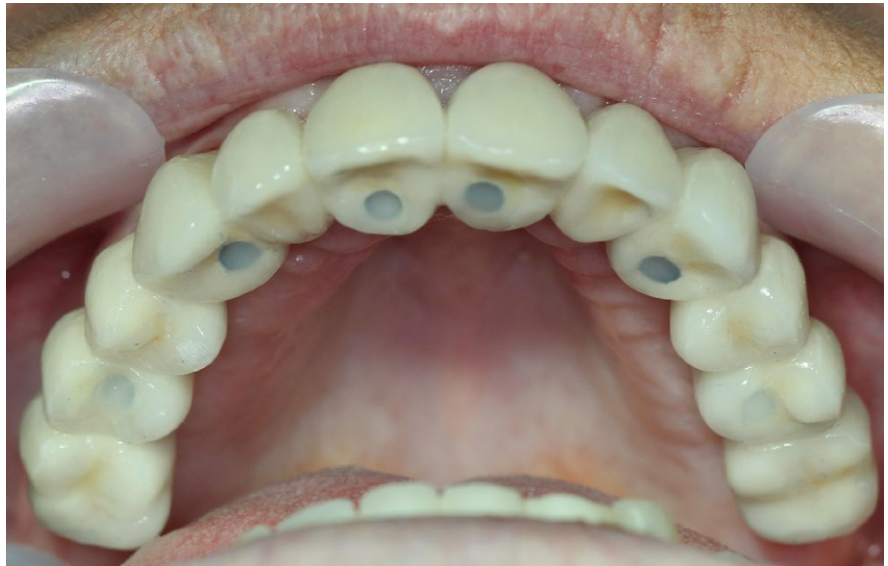


FIGURE 7 Occlusal view of the final restoration. Favorable prosthetic emergence of the implants

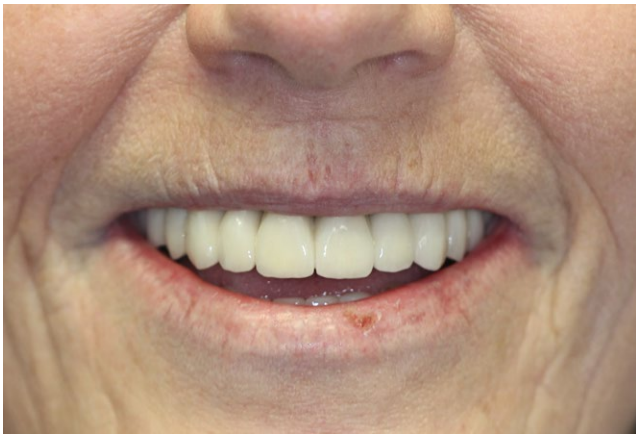

FIGURE 8 Full smile with final restoration

3.4 | Differences in deviation between partially vs fully edentulous patients

Twelve implants corresponded to two partially dentured patients, whereas 19 belonged to patients with no teeth (Table 4).

We concluded that differences in deviations were statistically significant. In the sample, mean deviation for DP was 28% higher among partially edentulous patients and 43% higher when it came to DA.

4 | DISCUSSION

Guided surgery is a tool that can be used to preoperatively plan the best locations for implants regarding adequate bone and soft tissue quality and quantity, as well as to smoothly integrate the implants into the prosthetic workflow.¹⁷ Long-term success of implants relies on avoiding biologic and prosthetic complications.¹⁸ Mucosa supported guides allow for flapless

implant insertion, which reduces the postoperative swelling and pain,¹⁹ and seems to accelerate the formation of a biologic seal between the soft tissues and the implant-abutment interface, as the tissues are not reflected and sutured back together.²⁰ To preplan implant locations also allows to more easily and predictably prepare immediate load provisional restorations, by knowing exactly where the implants should be placed to get the right prosthetic support.²¹

The key matter is if the presurgical 3D implant planning can accurately and safely be transferred into the patient.²² Not only to place the implants in the correct prosthetic positions (good distribution of implants, parallelism, correct emergence of the screw channel) but to avoid damaging important anatomic structures such as nerves, roots, or sinuses.^{23,24} MSGS is a blind technique and bone cannot be visualized during the implant drilling and insertion; therefore, guided surgery systems must deliver an accurate implantation.¹¹ It would not be possible to take accurate periapical radiographs during the drilling and placement phase of the implants with a surgical guide in situ, and 2D images would offer very limited postoperative information regarding implant position and treatment safety, so it would be necessary to take postoperative 3D images to verify good implant position and rectify any possible errors or implant malposition, before moving on to the prosthetic phase.

Scientific literature in the field of MSGS is quite scarce.²² More in vivo studies should be carried out as it is in the real clinical scenario where many variables can affect the surgical accuracy (limited mouth opening, visibility, patient and/or surgical guide movement during surgery, bone density differences between sites and within the site, operator fatigue).¹⁵ A recent review stated that more clinical studies should be performed to show more evidence about the accuracy of guided surgery, as well as to evaluate the variables that could affect the precision of the technique.¹² That study compared three

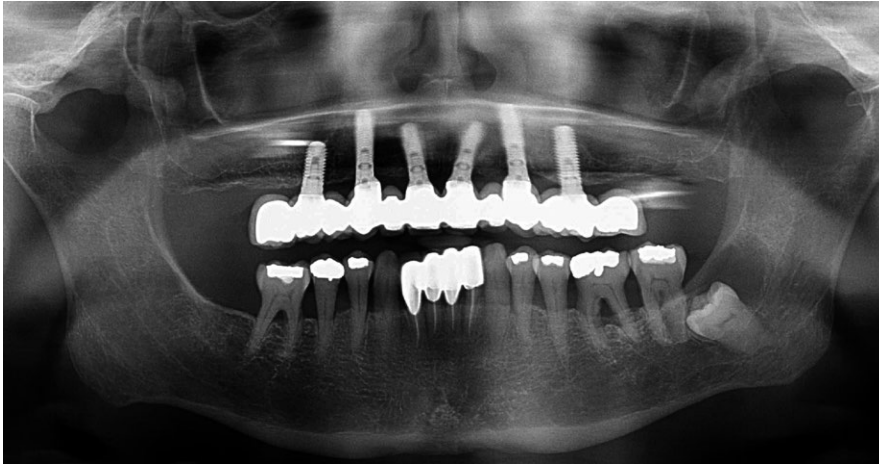


FIGURE 9 OPG with final restoration

types of guides (bone, mucosa, or tooth supported), and the included studies accounted for a total of 345 implants placed with mucosa supported guides.

There is very little scientific data correlating implant dimensions and bone density with implant placement accuracy.²⁵ In that study, a positive correlation between angular deviation of the implants and bone density was found. This present work showed that long implants, dense bone, and bone density changes correlate to higher implant deviation. All guided surgery systems design their drills, spoons, and metal sleeves with a degree of tolerance,²⁶ if the tolerance were very small, it would be difficult to pass the drills through the guides and metal debris would be formed.²⁷ This tolerance allows certain movement of the drills when they pass through the metal tubes, which could make them deviate toward the softer part of the bone during drilling, altering the implant trajectory. With the same angle deviation, a long drill's apex will deviate more millimeters in the apex than a short drill. It makes sense to believe that long implants could have higher deviations in apical.

A limitation of this study would be the small sample of implants. Still, the deviation results obtained in this work (1.05 mm in the platform, 1.08 mm in the apex) would be very similar to those showed in other studies. A recent systematic review²⁸ showed 1.07 mm deviation in the platform and 1.64 mm in the apex using MSGS. Furthermore, the sample in the present study was enough to show correlation between the variables (ID, IL, BD, and BDD) and implant deviation. More studies of this type should be carried out, to confirm these findings. They would be useful to have a better understanding of how much implant dimensions and bone density can alter the implant position, and guided surgery and implant manufacturers could accordingly adapt the drilling and placement equipment and protocols to reduce errors.²⁵

Preoperative and intraoperative factors altering accuracy of guided surgery have been described in the literature.¹⁵ Errors taken place during the planning phase could cause

implant malposition. The Dual Scan Protocol¹⁴ requires a very intimate fit between the scan appliance and mucosa, to avoid any movement and be able to reproduce this fitting surface onto the surgical guide, so that when the guide is fitted in for surgery, it is in the correct position. The surgical guide manufacturing has been discussed as well, as changes in the radiologic threshold can result in a thicker guide, causing the implants not to be placed deep enough.²⁹ It is paramount to be scrupulous following each step of the surgical guide planning and manufacturing, to ensure that any errors during this phase will not be cumulative to other errors derived from intraoperative variables.³⁰ Great care was taken in this study to ensure that the scanning appliances had an intimate fit onto the mucosa; they were all relined intraorally before proceeding with the Dual Scan.

Preoperative and postoperative CBCT merging technique to compare implant deviation used in this study is the Triple Scan Protocol.¹⁶ This could also add some bias into the accuracy measurements, as factors such as scan appliance positioning after the surgery, patient movement during CBCT exposure, or factors related to software file merging could play a role.^{29,31}

Intraoperative factors such as mucosa thickness and resilience have been pointed out to affect surgical guide movement and implant accuracy.³² In this study, there were differences in accuracy between patients, but significantly greater between implants regardless of which patient there were placed in. This could be explained by the 4 variables (ID, IL, BD, and BDD) assessed in this study. Bone density can vary from a patient to another, but it can also greatly vary from one implant site to another, and even within the same implant site. Chosen implant diameter and lengths also vary within patients. This could lead to think that the variables that explain deviation variances are not intrinsic variables of each patient, but intrinsic variables for each specific implant. Therefore, each site should be drilled and implanted with meticulous care, as deviation seems to be a risk for every single implant and not for patients as a whole. In this study,

TABLE 1 Implant position (IP), implant diameter (ID), implant length (IL), deviation at the platform (DP) and deviation at the apex (DA) in mm, bone density (BD) and bone density deviation (BDD) of each implant in Hounsfield units illustrated in this table

Patient	IP	ID (mm)	IL (mm)	DP	DA	BD	BDD
1	15	4.5	10	1.33	1.52	253.29	85.35
	13	3.75	15	1.32	1.45	619.37	389.57
	11	3.75	13	1.58	1.46	411.36	231.29
	21	3.25	13	1.05	1.8	466.59	212.8
	23	3.75	15	1.05	1.13	598.81	360.8
2	25	4.1	13	1.8	1.84	496	49.69
	16	4.1	10	0.72	0.3	202.98	188.88
	14	3.75	13	1.26	1.87	371.54	162.9
	13	3.25	13	1.94	1.92	432.13	78.94
	21	3.25	11.5	0.86	0.97	503.28	120.99
	25	3.75	13	0.7	0.77	361.52	92.13
3	26	4.1	10	1.03	0.92	289.52	160.43
	15	4.5	10	0.83	0.61	268.72	133.96
	13	4.1	13	0.9	0.43	421.81	114.09
	11	4.1	13	0.76	0.43	638.79	81.54
	21	3.75	11.5	0.94	1.65	607.49	99.28
	23	3.75	13	0.47	0.52	398.01	114.87
4	25	4.1	10	1.03	0.96	395.99	188.69
	15	3.75	13	0.76	0.92	142.17	116.14
	11	3.75	11.5	0.78	0.8	178.12	147.4
	21	3.75	11.5	0.46	0.56	220.3	141.54
	25	4.1	10	0.37	0.24	322.38	64.41
5	14	3.25	15	1.42	1.06	370.24	236.66
	11	3.25	11.5	0.45	0.54	329.86	172.09
	21	3.25	11.5	0.38	0.81	353.49	125.56
	24	3.25	15	1.06	1.9	323.09	111.05
	26	3.25	10	1.97	1.13	238.13	294.15
6	15	3.75	11.5	1.19	1.44	542.47	234.8
	11	3.75	11.5	2.05	1.82	558.26	67.18
	21	3.75	11.5	1.04	0.71	648.63	200.23
	25	3.75	11.5	1.18	1.12	469.69	177.93
Average		3.75	12.09	1.05	1.08	401.09	159.85

In yellow patients that had teeth prior to the surgery. In purple implants placed into extraction sockets.

TABLE 2 Pearson R and R^2 of ID, IL, BD, and BDD

	Pearson R		R^2	
	DP	DA	DP	DA
ID	-0.13	-0.32	0.02	0.10
IL	0.15	0.35	0.02	0.12
BD	0.26	0.29	0.07	0.09
BDD	0.17	0.06	0.03	0.00

the operator drilled and placed one implant at a time, removing the implant transporter and relieving any pressure from the guide before moving on to the next implant. The surgical

guide's fitting and position were checked on every step, to ensure that before inserting a drill or an implant through it, it had not moved. It is a common practice to place one implant in each side of the arch and leave the implant transporters attached, which would further stabilize the guide, to continue placing the rest of the implants. But in the authors' opinion, if these implants already carry some deviation and move the guide slightly, this will be passed onto the implants that are placed subsequently.

Four immediate post-extraction, implants were included in this study, and despite the small sample, they showed a significantly greater deviation at the apex than implants placed into healed sites. A fresh socket would normally present a dense

TABLE 3 Difference between post-extraction and healed sites

	Post-extraction	Healed sites	Difference
	Group 1	Group 2	
N	4	27	
Mean of DP	1.25	1.03	+22%
Mean of DA	1.46	1.03	+42%
Variance of DP	0.06	0.23	
Variance of DA	0.07	0.29	

TABLE 4 Difference between partially vs fully edentulous patients

	Partially edentulous patients	Edentulous patients	
	Group 3	Group 4	
N	12	19	
Mean of DP	1.22	0.95	28%
Mean of DA	1.33	0.93	43%
Variance of DP	0.16	0.23	
Variance of DA	0.26	0.23	

lamina dura and softer lamellar bone,³³ and drilling against the palatal bone through a surgical guide is done on an oblique angle which could lead to facial tilting of the drill. Furthermore, longer implants would be necessary to achieve sufficient stability in post-extraction sites.³⁴ So, all the variables evaluated in this study (implant dimensions, high bone density, and density deviations) would come together in the post-extraction implant case. It would be logical to assume that immediate implants could have higher potential to deviation; thus, the clinician should be ready for it and plan the cases allowing more margin of error (narrow implants perhaps) or modify the drilling sequence to avoid buccal drifting of the apex.

In this study, two patients were partially edentulous, and the surgical guides were prepared before extracting the remaining teeth. Still, it was considered that the surgical guides had sufficient edentulous ridge and palate surface to obtain enough stability to reproduce the positioning of the guide predictably after the dental extractions. But significant difference was seen between implants placed into partially vs fully edentulous patients, patients with remaining teeth showing greater deviation of their implants at platform and apex level. This could mean that surgical guides in edentulous patients would move less during surgery due to a more intimate fit all around the arch (larger fitting surface) delivering more accurate results.

To conclude, predictability and accuracy of guided surgery will depend on the management of preoperative and

intraoperative steps. Strict protocols to reduce errors on all phases of guided surgery should be followed, and when complying with them, MSGS shows to be a reliable implant placement technique. A better understanding of the variables that can affect the precision will allow the clinician to deliver more accurate results. ID, IL, BD, and BDD should not be overlooked, as they can have an impact in implant deviation. No matter how meticulously the guided surgery technique is carried out, scientific literature seems to accept and expect a 1.5 mm inaccuracy²⁸ which is far less than when following freehand techniques (Van Assche et al, 2012). Despite MSGS has been used for over a decade, the scientific evidence to back its accuracy is scarce. More clinical trials on humans should be carried out to support the findings in this study.

ACKNOWLEDGMENT

Special acknowledgments to Daniel Jones (BMath) for the statistical analysis and giving a meaning to the numbers.

CONFLICT OF INTEREST

None declared.

AUTHORSHIP

This manuscript is single authored.

ORCID

Andoni Jones  <http://orcid.org/0000-0002-2144-2751>

REFERENCES

1. Dudley J. Implants for the ageing population. *Aust Dent J*. 2015;60:28-43.
2. Peñarrocha-Oltra D, Covani U, Peñarrocha-Diago M, Peñarrocha-Diago M. Immediate loading with fixed full-arch prostheses in the maxilla: review of the literature. *Med Oral Patol Oral Cir Bucal*. 2014;19:512-517.
3. Sorní M, Guarínós J, García O, Peñarrocha M. Implant rehabilitation of the atrophic upper jaw: a review of the literature since 1999. *Med Oral Patol Oral Cir Bucal*. 2005;10:45-56.
4. Ganz SD. Three - dimensional imaging and guided surgery for dental implants. *Dent Clin North Am*. 2015;59:265-290.
5. Sousa V, Mardas N, Farias B, et al. A systematic review of implant outcomes in treated periodontitis patients. *Clin Oral Implant Res*. 2016;27:787-844.
6. Fuentealba R, Jofré J. Esthetic failure in implant dentistry. *Dent Clin North Am*. 2015;59:227-246.
7. Pesce P, Canullo L, Grusovin MG, de Bruyn H, Cosyn J, Pera P. Systematic review of some prosthetic risk factors for periimplantitis. *J Prosthet Dent*. 2015;114:346-350.
8. Wheeler SL. Implant complications in the esthetic zone. *J Oral Maxillofac Surg*. 2007;65:93-102.

9. Mora MA, Chenin DL, Arce RM. Software tools and surgical guides in dental-implant-guided surgery. *Dent Clin North Am.* 2014;58:597-626.
10. Sadid-Zadeh R, Kutkut A, Kim H. Prosthetic failure in implant dentistry. *Dent Clin North Am.* 2015;59:195-214.
11. Schneider D, Marquardt P, Zwahlen M, Jung RE. A systematic review on the accuracy and the clinical outcome of computer-guided template-based implant dentistry. *Clin Oral Implant Res.* 2009;20:73-86.
12. Raico Gallardo YN, da Silva-Olivio IRT, Mukai E, Morimoto S, Sesma N, Cordaro L. Accuracy comparison of guided surgery for dental implants according to the tissue of support: a systematic review and meta-analysis. *Clin Oral Implant Res.* 2017;28:602-612.
13. Jacobs R, Adriansens A, Verstrecken K, Suetens P, van Steenberghe D. Predictability of a three dimensional planning system for oral implant surgery. *Dentomaxillofac Radiol.* 1999;28:105-111.
14. Verstrecken K, Van Cleynenbreugel J, Martens K, Marchal G, van Steenberghe D, Suetens P. An image-guided planning system for endosseous oral implants. *IEEE Trans Med Imaging.* 1998;17:842-852.
15. Vercruyssen M, Laleman I, Jacobs R, Quirynen M. Computer supported implant planning and guided surgery: a narrative review. *Clin Oral Implant Res.* 2015;26:69-76.
16. Zechner W. Clinical solutions for improved treatment planning. 2007. Nobel Biocare World Congress (Invited Oral Presentation: 22 May 2007).
17. Cassetta M, Giansanti M, Di Mambro A, Stefanelli LV. Accuracy of positioning of implants inserted using a mucosa-supported stereolithographic surgical guide in the edentulous maxilla and mandible. *Int J Oral Maxillofac Implants.* 2014;29:1071-1078.
18. Slagter KW, den Hartog L, Bakker NA, Vissink A, Meijer HJ, Raghoobar GM. Immediate placement of dental implants in the esthetic zone: a systematic review and pooled analysis. *J Periodontol.* 2014;85:241-250.
19. Van Steenberghe D. Interactive imaging for implant planning. *J Oral Maxillofac Surg.* 2005;63:883-884.
20. Malo P, Araujo M, López A. The use of computer-guided flapless implant surgery and four implants placed in immediate function to support a fixed denture: preliminary results after a mean follow-up period of thirteen months. *J Prosthet Dent.* 2007;97:S26-S34.
21. Kan JY, Rungcharassaeng K, Oyama K, Chung SH, Lozada JL. Computer-guided immediate provisionalization of anterior multiple adjacent implants: surgical and prosthodontic rationale. *Pract Proced Aesthet Dent.* 2006;18:617-623.
22. Cassetta M, Stefanelli LV, Giansanti M, Calasso S. Accuracy of implant placement with a stereolithographic surgical template. *Int J Oral Maxillofac Implants.* 2012;27:655-663.
23. Colombo M, Mangano C, Mijiritsky E, Krebs M, Hauschild U, Fortin T. Clinical applications and effectiveness of guided implant surgery: a critical review based on randomized controlled trials. *BMC Oral Health.* 2017;13:150.
24. Jacobs R, Quirynen M, Bornstein MM. Neurovascular disturbances after implant surgery. *Periodontol 2000.* 2014;66:188-202.
25. Cassetta M, Di Mambro A, Giansanti M, Stefanelli LV, Cavallini C. The intrinsic error of a stereolithographic surgical template in implant guided surgery. *Int J Oral Maxillofac Surg.* 2013;42:264-275.
26. Van Assche N, Quirynen M. Tolerance within a surgical guide. *Clin Oral Implant Res.* 2010;21:455-458.
27. Schneider D, Schober F, Grohmann P, Hammerle CH, Jung RE. In-vitro evaluation of the tolerance of surgical instruments in templates for computer-assisted guided implantology produced by 3-D printing. *Clin Oral Implant Res.* 2014;26:320-325.
28. Tahmaseb A, Wismeijer D, Coucke W, Derksen W. Computer technology applications in surgical implant dentistry: a systematic review. *Int J Oral Maxillofac Implants.* 2014;29:25-42.
29. Verhamme LM, Meijer GJ, Boumans T, Schutyser F, Bergé SJ, Maal TJ. A clinically relevant validation method for implant placement after virtual planning. *Clin Oral Implant Res.* 2013;24:1265-1272.
30. Schneider J, Decker R, Kalender WA. Accuracy in medicinal modelling. *Phidias Newsletters.* 2002;8:5-14.
31. Pettersson A, Komiyama A, Hultin M, Nasstrom K, Klinge B. Accuracy of virtually planned and template guided implant surgery on edentate patients. *Clin Implant Dent Relat Res.* 2012;14:527-537.
32. D'haese J, De Bruyn H. Effect of smoking habits on accuracy of implant placement using mucosally supported stereolithographic surgical guides. *Clin Implant Dent Relat Res.* 2013; 15:402-411.
33. Huynh-Ba G, Pjetursson BE, Sanz M, et al. Analysis of the socket bone wall dimensions in the upper maxilla in relation to immediate implant placement. *Clin Oral Implant Res.* 2010;21:37-42.
34. Schwartz-Arad D, Chaushu G. Immediate implant placement. A procedure without incisions. *J Periodontol.* 1998;69:743-750.
35. Van Assche N, Vercruyssen M, Coucke W, Teugheis W, Jacob R, Quirynen M. Accuracy of Computer - aided implant placement. *Clin Oral Implants Res.* 2012;23:112-123.

How to cite this article: Jones A. Accuracy of mucosa supported guided dental implant surgery. *Clin Case Rep.* 2018;6:2131–2139. <https://doi.org/10.1002/ccr3.1809>