

# Hamstring Autograft Applications for Treatment of Achilles Tendon Pathology

Carson M. Rider, MD<sup>1</sup> , Oliver B. Hansen, BA<sup>1</sup> ,  
 and Mark C. Drakos, MD<sup>1</sup>

**Keywords:** tendon disorders, sports

## Introduction

Patients who present with extensive Achilles tendinopathy are often left with a lack of functional tissue, which represents a challenge for the orthopedic surgeon. The management of both acute and chronic Achilles injuries continues to be debated. The intrinsic viscoelasticity and tension-length relationship of the native tendon that allows efficient propulsion in bipeds is challenging to replicate once the tendon has been injured. Once significant tendinopathy is present, these pathologic changes within the tendon cannot be reversed with debridement and repair alone. In such cases, autograft replacement using one of the various techniques described in this article may be indicated since normally aligned collagen fibrils may better reproduce normal tendon biomechanics. Nonoperative intervention in these patients can lead to the tendon healing in an elongated position, which can lead to pain, weakness, and decreased activity levels.

In cases of Achilles injury where direct debridement and repair are not possible, other authors have described the use of flexor hallucis longus (FHL) transfer, V-Y lengthening, and allograft reconstruction.<sup>6-8,13</sup> However, both FHL transfer and V-Y lengthening may lead to a persistent loss of ankle plantarflexion strength that may hinder physically active patients.<sup>7,8,12,13</sup> Furthermore, the larger incisions, routinely 10 to 15 cm or greater,<sup>1,7,9,12</sup> needed to accommodate these procedures may put patients at a higher risk of infections and wound breakdown in an area of poor vascularity.<sup>15</sup> We have found that reconstruction with hamstring autograft may better restore ankle biomechanics and physical function. Hamstring autograft has been described by previous authors as an alternative to V-Y lengthening and can lower complication rates when treating chronic Achilles ruptures.<sup>1</sup> This article will describe our indications for Achilles tendon reconstruction, demonstrate the steps of hamstring tendon harvest in the prone position, and illustrate several operative

techniques that highlight the versatility of hamstring tendon autograft for the treatment of a spectrum of Achilles tendon pathology.

## Technique

### Preoperative Planning

Several factors should be considered when developing an operative strategy for treatment of Achilles pathology using hamstring autograft. A thorough history and physical examination should be the first step for each patient. A bilateral Thompson test should be performed, and the resting tension of the affected extremity should be compared to that of the unaffected extremity. Passive dorsiflexion should also be evaluated, with increased passive dorsiflexion indicating Achilles tendon attenuation. The medical history should be reviewed for factors such as diabetes mellitus, smoking, and obesity that may affect wound healing.<sup>3,4,11,14</sup>

The underlying pathology should be elucidated based on the history, physical examination, and radiographic evaluation. Chronic Achilles ruptures that have healed with scarring typically alter the resting tension of the tendon, which compromises the ability of the tendon to effectively transfer loads from the calf muscle to the calcaneus and leads to weakness during push off.<sup>7,12</sup> Large areas of tendinosis can lead to abnormal tendon elasticity and we believe that this diseased tendon should be resected to optimize outcomes. Some patients will also have insertional disease combined

<sup>1</sup> Foot and Ankle Service, Hospital for Special Surgery, New York, NY, USA

### Corresponding Author:

Carson M. Rider, MD, Hospital for Special Surgery, 523 E 72nd St, 5th Floor, New York, NY 10021, USA.  
 Email: riderc@hss.edu



with midsubstance pathology, and both pathologies may need to be addressed at the time of surgery.

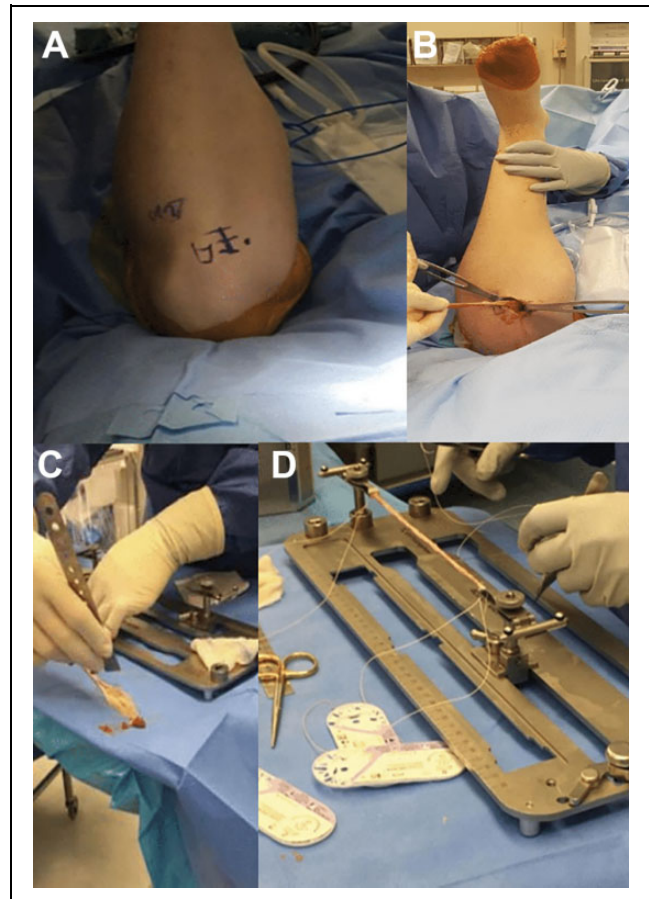
The anatomic location of the Achilles pathology should be determined using a combination of clinical and radiographic evaluation. During the physical examination, the surgeon should palpate the tendon for gaps, pain, swelling, and thickening. The clinical examination should then be correlated with radiographic findings. Weightbearing anteroposterior, lateral, and oblique radiographs are obtained to assess overall alignment and to detect any fractures or any enthesophytes. Exostoses or bony abnormalities that could lead to mechanical irritation of the tendon should also be identified. Magnetic resonance imaging (MRI) is obtained to determine the location and length of a rupture and to assess the quality of the remaining Achilles tissue. The distal portion of the tendon should be assessed both clinically and radiographically. If the distal portion of the tendon appears to have at least 2 to 3 cm of healthy tissue remaining, the surgeon can use the distal stump to dock the autograft. If the distal portion of the tendon is severely diseased or avulsed from the bone, then the surgeon should consider docking the autograft into the posterosuperior calcaneus using an osseous fixation device (ie, tenodesis screw).

The surgeon should estimate how much of the diseased tendon will be resected during the case, as the size of the defect remaining after resection can help guide the number of hamstring tendons that will be harvested. The gracilis tendon has an average diameter of 3.5 to 4.3 mm and an average length of 22 to 28 cm. The semitendinosus tendon has an average diameter of 4 to 5 mm and an average length of 23 to 30 cm. Bundling of each tendon will increase the overall diameter by 1 to 1.5 mm. In our experience, tendon defects smaller than 5 cm in length can likely be reconstructed using only the gracilis tendon with multiple passes in a cerclage or Pulvertaft fashion. For residual tendon defects larger than 5 cm, we recommend harvesting both the gracilis and the semitendinosus to adequately reconstruct the Achilles tendon with multiple passes.

### Harvesting the Hamstring Tendons in the Prone Position

We harvest the hamstring tendons in the prone position, regardless of the type of Achilles pathology that is present. With the knee flexed, the tibial tubercle is drawn out in its entirety and a dot is placed on the posteromedial border of the tibia. The incision for hamstring harvest in the prone position should be parallel to the medial face of the tibia, halfway between the tibial tubercle and the posteromedial aspect of the tibia (Figure 1A). The proximal aspect of the incision should be even with the top of the tibial tubercle, and the incision is typically 3 cm in length.

A no. 15 blade is used to incise the skin and blunt dissection is carried out down to the level of the sartorial fascia. Electrocautery should be used to maintain hemostasis during



**Figure 1.** Hamstring harvest in the prone position. (A) The incision is drawn parallel to the medial face of the tibia, halfway between the tibial tubercle and the medial border of the tibia. (B) The hamstring tendon(s) of interest are harvested using the tendon stripper. The distal aspect of the autograft is then incised sharply at the pes anserinus. (C) Residual muscle is removed from the autograft using the edge of a metal ruler. (D) A running, locking no. 0 Vicryl suture is placed at each end of the graft to facilitate passage of the autograft during reconstruction. These limbs can also be passed through the native tendon with a free needle to serve as another point of graft fixation.

the approach. The saphenous nerve and its branches should be protected if encountered. Clear off the sartorial fascia using an elevator so that adequate visualization is obtained before making the fascial incision. Sharply incise the sartorial fascia in line with its fibers, parallel and just a few millimeters medial to the tibia. This will create a “window” through which the tendons can be harvested. Palpate the hamstring tendons between knee layers 1 and 2, and then use finger dissection to free up any adhesions that are present. The tendons are best palpated by sweeping the finger from anterior to posterior. The knee can be manipulated into flexion and extension to allow the surgeon to better palpate the hamstring tendons.

Place a right-angle clamp around the gracilis tendon and then pass a penrose drain around the tendon to provide countertraction. Additional countertraction can be obtained by

placing a Langenbeck retractor around the tendon as well. Remove any remaining adhesions from the medial head of the gastrocnemius muscle using Metzenbaum scissors. Once the tendon has been completely mobilized, place a tendon stripper over the tendon, flex the knee, and push the tendon stripper toward the ischial tuberosity to harvest the tendon (Figure 1B). Sharply transect the distal insertion of the gracilis tendon and remove any remaining muscle that is on the tendon surface using a metal ruler (Figure 1C). If the semitendinosus is also needed for the reconstruction, harvest this tendon in a similar fashion.

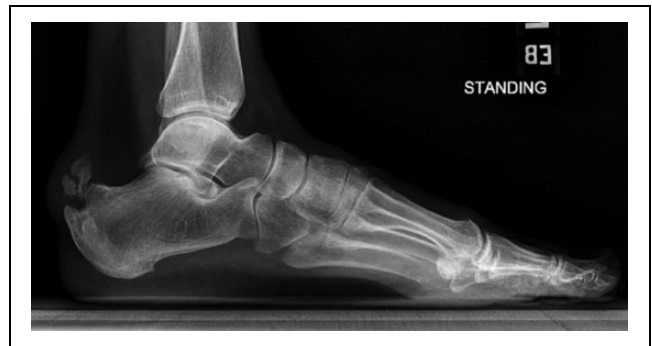On the back table, the hamstring tendons are prepared for insertion. The ends of the graft are tubularized using a locking no. 0 Vicryl suture, ensuring that there are ample suture tails to be used during passage of the graft (Figure 1D). If needed, the gracilis and semitendinosus grafts can be bundled together to address larger Achilles tendon defects. The graft is not pretensioned. The wound is copiously irrigated, and the sartorial fascia is closed with a running 3-0 Vicryl stitch. The skin is closed in a layered fashion.

### *Insertional Achilles Tendinopathy*

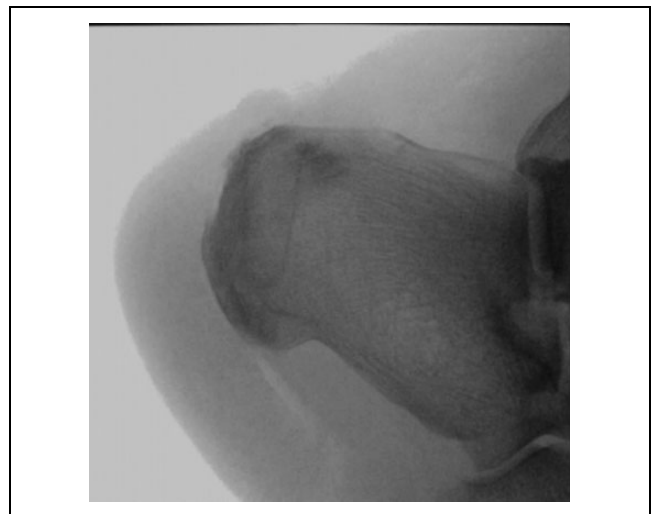
The hamstring tendons are harvested in the prone position as previously outlined. We prefer a lateral-based incision due to enhanced vascularity in this region.<sup>15</sup> This also avoids placing an incision directly over the Achilles tendon and allows us to directly visualize and protect the sural nerve. The distal portion of our incision is drawn out just lateral to the Achilles near its bony insertion, which allows the surgeon to address insertional tendon degeneration as well as bony pathology such as enthesophytes or Haglund exostoses that may need to be removed (Figure 2). This incision is typically 3.5 to 4 cm in length. Using the preoperative MRI and clinical examination, the distal aspect of “healthy” tendon is marked proximally above the area of insertional degeneration.

We begin by exposing the distal Achilles insertion to address insertional pathology. The sural nerve and small saphenous vein are identified and protected laterally. The Haglund’s deformity is resected with an oscillating saw and any distal enthesophytes are removed using an osteotome (Figure 3). This will sometimes require dissecting through healthy tissue, in which case care is taken to disturb it as minimally as possible. Any sharp bony prominences are smoothed down using an oscillating rasp. Degenerative tendon is debrided until only healthy-appearing tendon is present.

In patients with significant insertional disease that require extensive debridement near the Achilles insertion, we prefer to anchor the hamstring autograft into the calcaneal tuberosity using an osseous fixation device. We also place a free strand of SutureTape (Arthrex, Naples, FL) through the eyelet of the tenodesis screw so that the screw acts as a suture anchor. A guidewire is placed into the posterosuperior



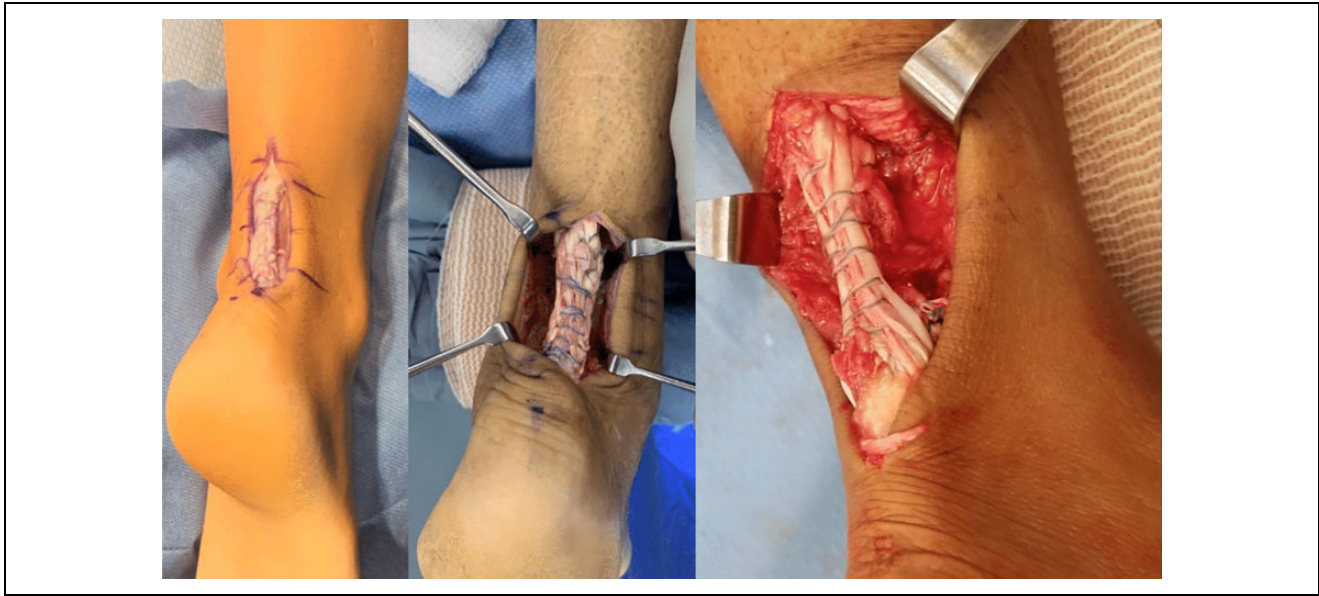
**Figure 2.** Preoperative imaging demonstrating tendinotic calcification and enthesophyte formation in a patient with advanced insertional Achilles tendinopathy.



**Figure 3.** Intraoperative fluoroscopy demonstrating the tunnel position for the transosseous fixation device used to dock the hamstring autograft. The regions of tendinotic calcification and the insertional enthesophyte have been resected.

portion of the calcaneal tuberosity, and the wire position is verified with fluoroscopy. Once satisfied, a drill is sent over the guide wire and the hamstring graft is docked into the bone using a tenodesis screw loaded with the SutureTape. Pass only 1 limb of the no. 0 Vicryl autograft tagging suture through the eyelet of the osseous fixation device and leave the other limb free for later incorporation into the reconstruction. Fixation of the screw is tested to ensure that the graft is securely anchored. If satisfied with screw fixation, pass the remaining free no. 0 Vicryl suture from the distal limb of the autograft into remaining native stump using a free needle. This adds another point of distal fixation to the construct.

Once the graft has been docked distally, attention is turned to securing the graft to the proximal portion of healthy tendon. It is important to dock the graft proximally under an appropriate amount of tension, ensuring that adequate dorsiflexion to neutral can be obtained without jeopardizing the integrity of the reconstruction. The proximal no. 0



**Figure 4.** Examples of reconstruction constructs through a 6- to 8-cm incision for treatment of subacute Achilles ruptures or chronic midsubstance tendinosis with significant tendon involvement.

Vicryl limbs of the graft are then pulled from lateral to medial through the proximal edge of healthy tendon using a curved tissue weaver. With the foot positioned under appropriate tension—so that resting tension is similar to the contralateral side at 10 to 15 degrees of plantarflexion—the graft is secured to the medial and lateral aspects of the native Achilles with buried figure-of-8 SutureTapes. The graft is then shuttled distally once more from a medial to lateral direction using the tissue weaver, and it is secured again with buried figure-of-8 SutureTapes. This technique creates a cerclage of autograft between the distal insertion site and healthy, proximal native tendon. The graft can also be anchored down to the screw with the limbs of the free SutureTape within the screw eyelet using a free needle. At this point, there should be continuity of the graft between the proximal and distal aspects of the defect. However, if there is remaining length on the graft, it can be passed proximally again and secured in a similar fashion. We can typically make 4 to 6 passes with the autograft for defect sizes measuring 2-3 cm in length.

Once all the graft length has been used, the medial and lateral limbs of the graft should be tubularized together with a running SutureTape. This will bring the limbs of the graft together to form a single, central unit (Figure 4). A 3-0 Vicryl suture can be used to help bury any knots that are present on the posterior surface of the tendon, as well as to fill in any gaps between the SutureTapes to create a smooth posterior tendon surface. A SutureTape “ripstop” stitch should be placed proximal to the docking site in the proximal tendon stump to serve as a checkrein against suture migration. A Thompson test should be performed to ensure continuity of the reconstruction. Appropriate tension should allow dorsiflexion to neutral. The wounds are copiously

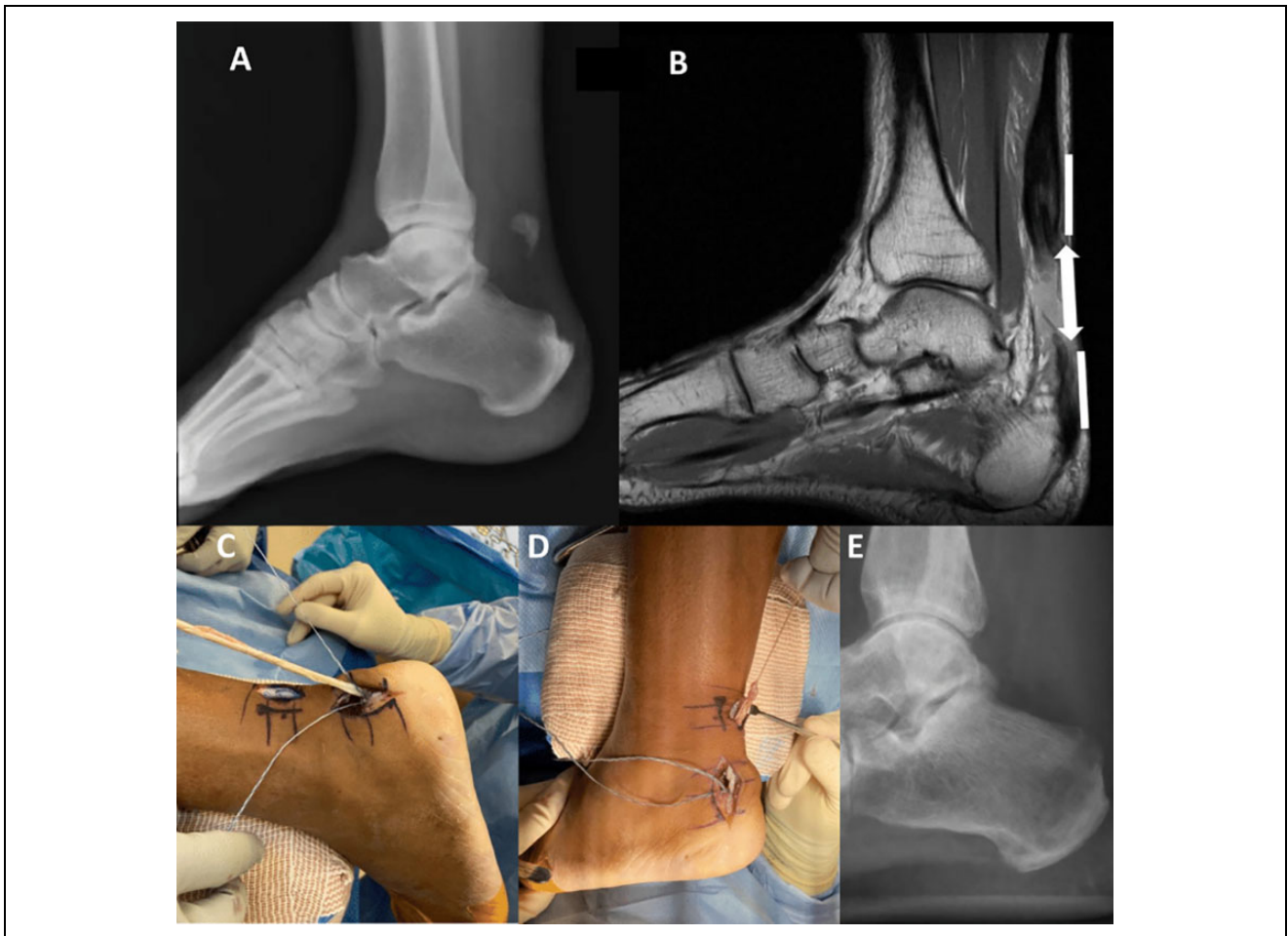
irrigated. The subcutaneous layer is closed with buried interrupted 3-0 Vicryl suture and the skin is closed with a running 3-0 Monocryl stitch.

#### *Acute Bony Avulsion Injuries in the Setting of Chronic Insertional Achilles Tendinopathy*

In this situation, there is often proximal retraction of the avulsed bone fragment. We begin by utilizing the lateral-based incision as described above. The insertional disease is also addressed as described above, ensuring that any degenerative tissue is debrided and any bony prominences are excised. If the avulsed bone fragment can be reached through our initial incision, we will excise the bony fragment from within the tendon and reconstruct the Achilles insertion using the cerclage technique as outlined above. We often place a locking no. 0 Vicryl traction suture into the proximal stump to assist with tendon mobilization and will incorporate these suture limbs into the final construct with a free needle at the conclusion of the case.

For cases with more proximal retraction of the avulsed bony fragment, we use a 2-cm longitudinal “window” incision just lateral and proximal to the avulsed bony fragment (Figure 5). This avoids creating a single, large posterior incision and minimizes the potential for wound complications. Once the avulsed bone fragment is exposed, we transect the tendon just distal to the avulsed bone. A locking no. 0 Vicryl traction suture is placed into the healthy proximal tendon stump. This allows the proximal portion of the tendon to be brought out through the “window” incision for inspection and debridement until a healthy-appearing proximal stump is obtained. Once the bone fragment has been excised and the proximal tendon has been debrided, we then





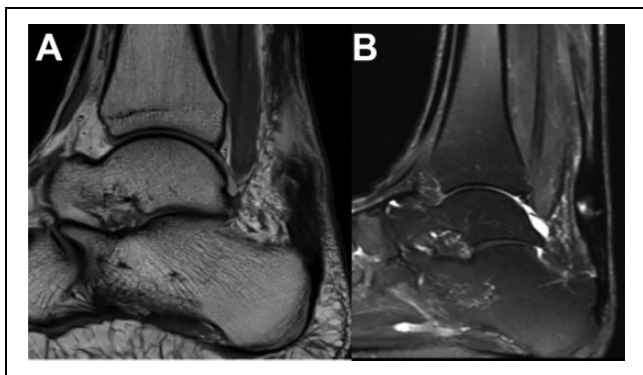
**Figure 5.** A patient with an acute bony avulsion injury in the setting of chronic insertional tendinopathy. (A) Preoperative radiograph showing an avulsed bone fragment with a prominent posterosuperior calcaneal exostosis and an insertional enthesophyte. (B) Preoperative magnetic resonance imaging (MRI) demonstrating the templated “window” incision sites (heavy lines) and the location of the residual gap after tendon resection (double arrow). (C) The graft is docked into the calcaneus using a transosseous fixation device. (D) The graft is tunneled under the skin bridge and docked into the healthy proximal stump using a Pulvertaft weave. (E) Postoperative radiograph depicting the tunnel position for the transosseous fixation device. The prominent posterosuperior tuberosity and the insertional enthesophyte have been resected.

use a Cobb elevator to create a plane under the skin bridge so that the hamstring graft can be shuttled between the 2 incision sites.

The hamstring autograft is then docked distally using the osseous fixation device as outlined above (Figure 5C). The proximal portion of the graft is then shuttled under the skin bridge, ensuring that the graft is underneath the fascial layer and not directly under the skin. The autograft is then docked into the proximal stump utilizing the same cerclage technique as outlined above (Figure 5D). The no. 0 Vicryl traction suture limbs can also be passed into the construct with a free needle to add another point of fixation. Ensure that the graft is anchored in an appropriate amount of tension. The graft is then shuttled back distally underneath the skin bridge, secured distally, and the limbs are tubularized as outlined above. The remaining steps from this point are outlined in the previous section.

### *Subacute Achilles Tendon Ruptures*

In these patients, there is often some healing that has occurred, but the tendon is often elongated and scarred, leading to abnormal resting tension and weakness (Figure 6A). If the surgery is 4 to 8 weeks from the time of rupture, we typically use a 3-4 cm incision about the lateral aspect of the Achilles, placed slightly proximal to the center of the tear (Figure 7A). If the surgery is later than 3 months from the time of rupture, there is often significant scarring, and we therefore use a larger incision to allow for adequate scar resection. After sharply incising the skin, there is often a significant amount of scar tissue that is encountered, and a true fascial layer that typically overlies the tendon will not be readily identified. With the sural nerve and small saphenous vein protected laterally, aggressive debridement of scar tissue and adhesions is performed to mobilize the tendon (Figure 7B and D). A Cobb elevator can be used



**Figure 6.** Magnetic resonance imaging scans demonstrating (A) a subacute Achilles rupture and (B) chronic midsubstance tendinosis.

to develop a plane above, below, medial, and lateral to the tendon. Avoid aggressive dissection into the deep posterior compartment.

Once the tendon has been exposed and mobilized, we then completely resect the diseased portion of the tendon, leaving healthy-appearing tendon proximally and distally (Figure 7C). This area of resection should ideally match the templated amount of resection determined on preoperative imaging. Once the diseased portion of the Achilles has been resected, both edges of the native tendon should be tagged with a locking no. 0 Vicryl suture to serve as traction sutures.

Attention is then turned to docking the hamstring autograft distally. In patients with 2 to 3 cm of nondiseased distal stump, we prefer to use this portion of the native stump to anchor our graft using a Pulvertaft weave. When using the curved tissue weaver, be sure to firmly spread the tips after coming through the far side of the tendon to help create a path for the autograft. The tissue weaver is inserted into the medial aspect of the Achilles, pushed through the lateral tendon edge, and one limb of the autograft no. 0 Vicryl suture is pulled from the lateral to medial direction. Stop pulling once the edge of the autograft is resting flush with the medial aspect of the distal Achilles stump. The graft is then secured with a buried figure-of-8 SutureTape on the medial and lateral aspects of the distal Achilles stump. Because only one limb of the autograft no. 0 Vicryl suture tail was pulled through the distal Achilles stump initially, the other limb should be passed from lateral to medial with a free needle and then tied to the previously shuttled no. 0 Vicryl limb to add another point of graft fixation. The graft is now docked into the distal portion of native, healthy tendon. If there is not a sufficient amount of healthy distal stump, anchor the graft into the bone using an osseous fixation device as mentioned above.

Ensure that there is appropriate tension in the construct and complete the cerclage technique as outlined above to dock the graft proximally. These steps can be repeated until there is no additional graft length remaining (Figure 7E). The limbs of the graft are then tubularized together using a running SutureTape with the knots buried (Figure 7F).

### *Chronic Midsubstance Achilles Tendinosis*

These cases are completed using a similar technique to that outlined in the subacute rupture section, but a larger incision may be needed to ensure that diseased tendon is adequately resected (Figure 6B). We typically remove 90% of the diseased Achilles while ensuring that tension remains intact (Figure 7B and C). Once the diseased tendon has been resected, we reconstruct the Achilles as outlined in the previous section using a Pulvertaft weave (Figure 7E and F).

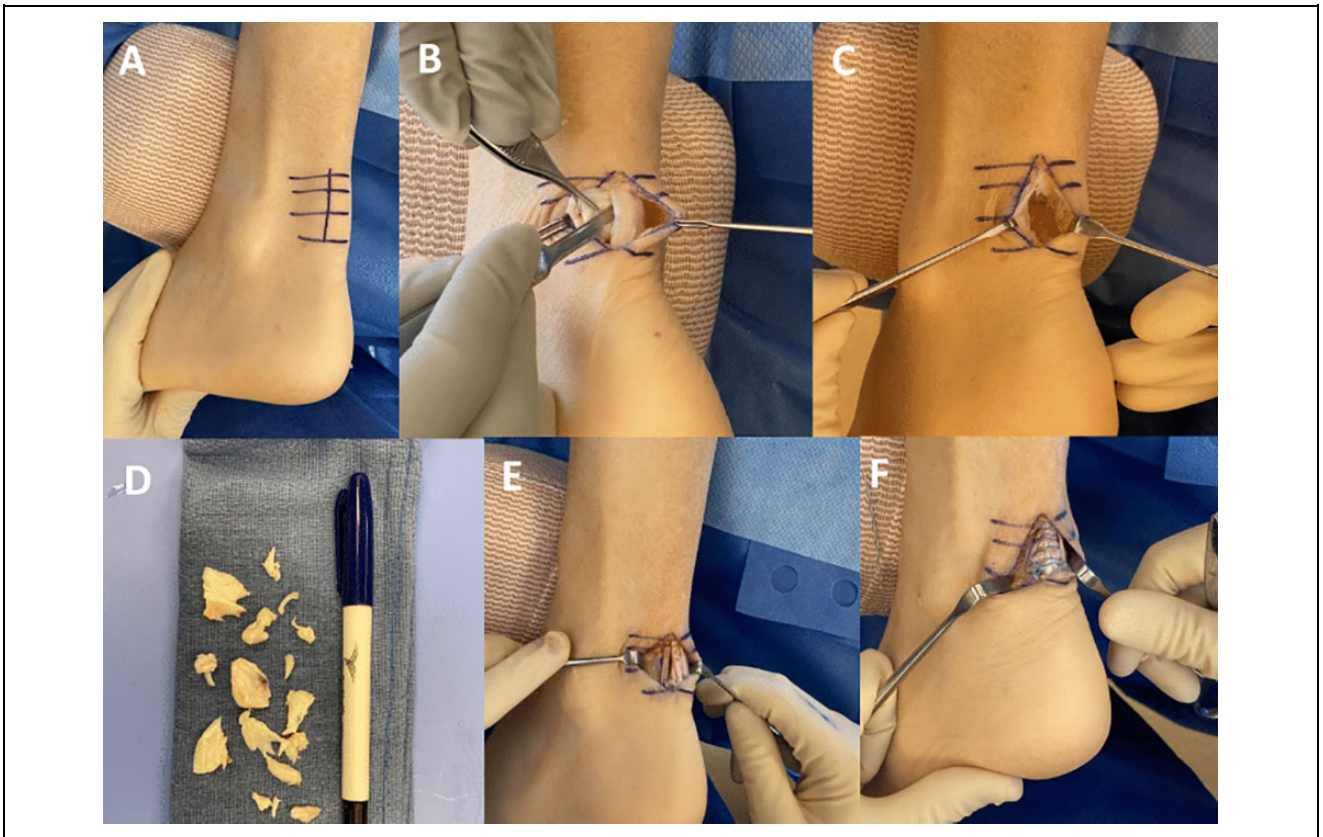
### *Achilles Infection*

In the setting of revision cases with suspected infection, baseline laboratory markers should be obtained to assess the response to treatment postoperatively. Wound cultures should be obtained intraoperatively to guide postoperative antibiotic therapy. To provide adequate infection eradication, the surgeon should plan on resecting as much of the infected tissue as possible (Figure 8B). If a patient has had prior Achilles surgery, the previous operative incision should be incorporated if it is in a reasonable location. After all the infected tissue is resected, copious irrigation with antibiotic-impregnated normal saline should be performed. For cases involving an active infection, we will perform a staged procedure to ensure that the infection is resolved before the graft is introduced. The defect can now be reconstructed using the autograft cerclage techniques outlined previously. Topical antibiotic powder is placed into the wound prior to closure. Infectious disease consultation is recommended to guide antibiotic therapy and monitor progression after the operation.

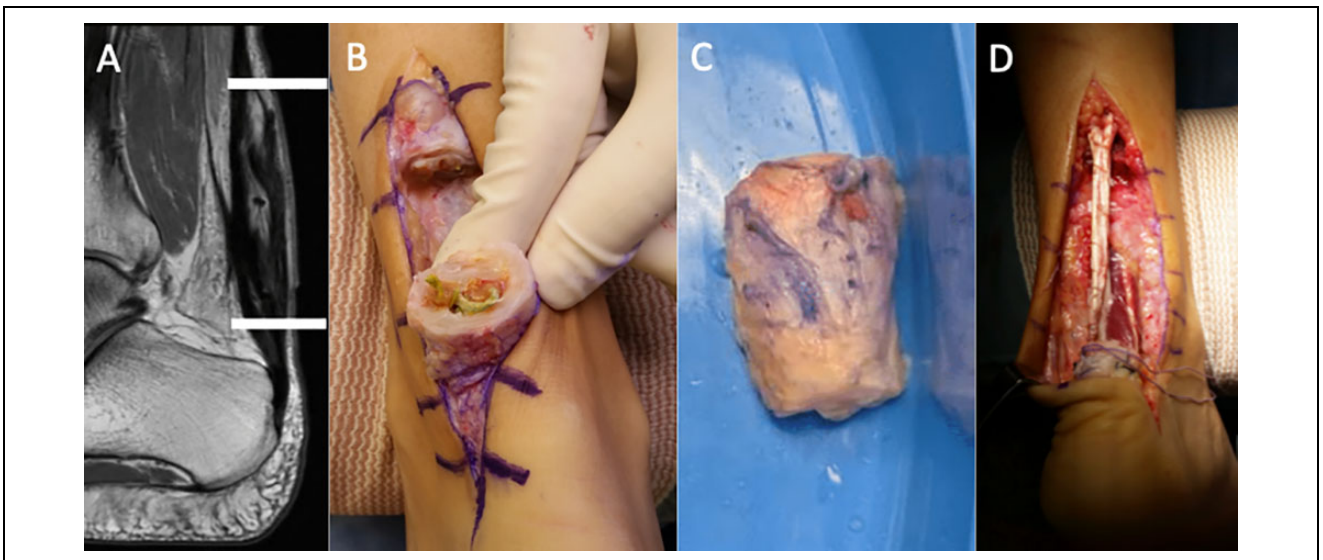### *Augmentation Using FHL Transfer*

In highly active patients who wish to return to sport, a flexor hallucis longus transfer can also be performed to supplement the hamstring reconstruction and enhance strength during the recovery period (Figure 8). The FHL tendon can be harvested through the same posterior incision that was made to expose the Achilles tendon. The surgeon should remain lateral to the FHL tendon during this portion of the case to minimize the risk of neurovascular injury. The fascia over the FHL tendon is incised and the tendon is mobilized. We believe that enough tendon can be harvested without exposing the Knot of Henry, so we typically harvest approximately 4 cm of the tendon from within the tarsal canal posteriorly. After the FHL tendon is harvested, we tubularize the end of the tendon using a locking no. 0 Vicryl suture.

In cases with a healthy distal Achilles stump, we use a Pulvertaft weave of the FHL tendon into the distal stump. For cases with no healthy distal stump, we use the osseous fixation device technique as mentioned previously, incorporating both the hamstring autograft and FHL tendon into the distal insertion site. The FHL tendon is tensioned by placing the foot in 10 to 15 degrees of plantarflexion. Based on the technique



**Figure 7.** Key steps in the treatment of a subacute Achilles rupture or chronic midsubstance tendinosis using a 3- to 4-cm incision. (A) The lateral-based skin incision is marked. (B) The diseased portion of the tendon is incised longitudinally, and unhealthy tendon is sharply excised. (C) Residual tendon gap after resection of the diseased tendon. (D) Portions of abnormal tendon that were removed. (E) Multiple hamstring autograft limbs are visible after multiple passes utilizing the Pulvertaft technique. (F) The limbs of autograft are tubularized with SutureTape to complete the reconstruction.



**Figure 8.** (A) Magnetic resonance imaging scan demonstrating advanced chronic insertional tendinosis and muscle atrophy requiring hamstring autograft with supplemental FHL transfer. The region between the heavy lines is the templated region of resection. (B) Infected Achilles tendon requiring extensive resection. (C) En bloc resection of diseased tendon in a patient with a subacute Achilles rupture. (D) The diseased region of tendon has been resected. The hamstring autograft is paired with an FHL tendon transfer to augment the reconstruction.



of distal fixation, the FHL tendon is either sutured to the distal Achilles stump using a SutureTape in a buried figure-of-8 fashion, or brought down to the osseous fixation device using the free suture tape in the eyelet. The no. 0 Vicryl suture tails from the FHL graft are then tied to any remaining suture tails to add another point of distal fixation to the construct.

### Postoperative Protocol

Patients are splinted with the foot resting in permissive equinus (approximately 10 degrees of plantarflexion) and instructed to remain nonweightbearing for 2 weeks postoperatively. At the 2-week postoperative clinic visit, sutures are removed and the patient is placed into a controlled ankle motion walking boot with a heel lift. At this time, patients are progressed to weightbearing as tolerated, and formal physical therapy is ordered to improve ankle range of motion. At 6 weeks postoperatively, therapy is advanced to focus on strengthening and proprioception. Patients can go back into a regular shoe at the 6-week visit. Return to light exercise is allowed at 3-4 months postoperatively, and patients can return to full activity 6-9 months after surgery.

### Conclusion

We find that the hamstring reconstruction methods outlined hold several advantages over alternatives such as FHL transfer and V-Y advancement. Although FHL transfer has historically played a pivotal role in the treatment of Achilles pathology, we only use this technique in situations where more muscle is needed to augment our Achilles reconstruction. The vector of pull of the FHL is not the same as that of the native Achilles, and there may be a loss of great toe plantarflexion strength after FHL transfer.<sup>5,10</sup> Furthermore, FHL transfer has been shown to result in significant and lasting strength deficits, as well as inconsistent return to sport or activity.<sup>8,13</sup> This may be due to the width of the FHL graft, which is significantly thinner than multiple passes with a hamstring graft. The V-Y advancement technique is similarly not ideal for large defects.<sup>1</sup> We tend to avoid V-Y advancements and debridement and repair since these techniques do not restore normal tendon integrity and mechanics, leading to persistent loss of strength.<sup>7,12</sup> Furthermore, the incisions for FHL transfer and V-Y advancement are typically larger than the incisions that we use during the outlined autograft reconstruction techniques, which inherently increases the risk of wound complications.<sup>1</sup> Lastly, although tendon allografts can be used in a similar manner to autografts, they may introduce additional risks such as an adverse immune response or infection. Furthermore, allograft tissue may be difficult to source and expensive.<sup>2</sup> When treating Achilles tendon pathology, the ultimate goal is to replace tendon gaps and diseased tendon segments with healthy collagen in continuity. We believe that this may be effectively accomplished by using the hamstring autograft replacement techniques outlined in this article.

### Ethics Approval

Ethical approval was not sought for the present study because it was based on clinical expertise and did not involve the collection of patient data.



### Declaration of Conflicting Interests

The author(s) declared no potential conflicts of interest with respect to the research, authorship, and/or publication of this article. ICMJE forms for all authors are available online.

### Funding

The author(s) received no financial support for the research, authorship, and/or publication of this article.

### ORCID iD

Carson M. Rider, MD,  <https://orcid.org/0000-0003-0760-5355>  
Oliver B. Hansen, BA,  <https://orcid.org/0000-0003-3736-6797>

### References

1. Bai L, Guan S, You T, Zhang W, Chen P. Comparison of gastrocnemius turn flap and hamstring graft for the treatment of Kuwada type 3 chronic ruptures of the Achilles tendon: a retrospective study. *Orthop J Sports Med.* 2019;7(12):2325967119887673. doi:10.1177/
2. Beer AJ, Tauro TM, Redondo ML, Christian DR, Cole BJ, Frank RM. Use of allografts in orthopaedic surgery: safety, procurement, storage, and outcomes. *Orthop J Sports Med.* 2019;7(12):2325967119891435.
3. Bruggeman NB, Turner NS, Dahm DL, et al. Wound complications after open Achilles tendon repair: an analysis of risk factors. *Clin Orthop Relat Res.* 2004;427:63-66.
4. Burrus MT, Werner BC, Park JS, Perumal V, Cooper MT. Achilles tendon repair in obese patients is associated with increased complication rates. *Foot Ankle Spec.* 2015;9(3):208-214.
5. Charlton T, Thomas D, Thordarson D, Metzger M, Nelson T. Biomechanical impact of FHL tendon harvest on forefoot and great toe push-off strength and its correlation to knot of henry crossover variation. *Foot Ankle Orthop.* 2018;3(3). doi:10.1177/2473011418S00034
6. Deese JM, Gratto-Cox G, Clements FD, Brown K. Achilles allograft reconstruction for chronic Achilles tendinopathy. *J Surg Orthop Adv.* 2015;24(1):75-78.
7. Guclu B, Basat HC, Yildirim T, Bozduman O, Us AK. Long-term results of chronic Achilles tendon ruptures repaired with V-Y tendon plasty and fascia turndown. *Foot Ankle Int.* 2016;37(7):737-742.
8. Hahn F, Meyer P, Maiwald C, Zanetti M, Vienne P. Treatment of chronic Achilles tendinopathy and ruptures with flexor hallucis tendon transfer: clinical outcome and MRI findings. *Foot Ankle Int.* 2008;29(8):794-802.
9. Hartog BDD. Surgical strategies: delayed diagnosis or neglected Achilles' tendon ruptures. *Foot Ankle Int.* 2008;29(4):456-463.



10. Richardson DR, Willers J, Cohen BE, Davis WH, Jones CP, Anderson RB. Evaluation of the hallux morbidity of single-incision flexor hallucis longus tendon transfer. *Foot Ankle Int.* 2009;30(7):627-630.
11. Stavenuiter XJR, Lubberts B, Prince RM, Johnson AH, DiGiovanni CW, Guss D. Postoperative complications following repair of acute Achilles tendon rupture. *Foot Ankle Int.* 2019;40(6):679-686.
12. Us AK, Bilgin SS, Aydin T, Mergen E. Repair of neglected Achilles tendon ruptures: procedures and functional results. *Arch Orthop Trauma Surg.* 1997;116(6):408-411.
13. Wegrzyn J, Luciani JF, Philippot R, Brunet-Guedj E, Moyon B, Besse JL. Chronic Achilles tendon rupture reconstruction using a modified flexor hallucis longus transfer. *Int Orthop.* 2010;34(8):1187-1192.
14. Wiewiorski M, Barg A, Hoerterer H, Voellmy T, Henninger HB, Valderrabano V. Risk factors for wound complications in patients after elective orthopedic foot and ankle surgery. *Foot Ankle Int.* 2014;36(5):479-487.
15. Yepes H, Tang M, Geddes C, Glazebrook M, Morris SF, Stanish WD. Digital vascular mapping of the integument about the Achilles tendon. *J Bone Joint Surg.* 2010;92(5):1212-1220.