

## Dermoscopic features of acutely exacerbated plaque psoriasis induced by anti-programmed death-1 for lung cancer

Chang-Lin Sui, Xue-Fei Lin, Li He, Wei Zhu

Department of Dermatology, Xuan Wu Hospital, Capital Medical University, Beijing 100053, China.

*To the Editor:* Programmed death-1 (PD-1) inhibitors are new and effective anti-tumor drugs, but they may cause serious immune-related adverse events, such as toxic epidermal necrolysis and psoriasis.<sup>[1]</sup> The first recombinant human-derived anti-PD-1 monoclonal antibody, Sintilimab (Innovent Biologics, Inc., Suzhou, China), was approved for listing at the end of 2018 in China. Here, we reported the dermoscopic features of acutely exacerbated plaque psoriasis induced by anti-PD-1 for lung cancer to direct clinicians' attention to this potential adverse reaction.

The patient was a 56-year-old man diagnosed with lung adenocarcinoma of multiple metastases and had a history of psoriasis for 25 years, with only a few lesions limited to the scalp and limbs. One year ago, he underwent video-assisted thoracoscopic surgery for left upper lung adenocarcinoma and regular chemotherapy after surgery. He developed chest tightness with dyspnea and left-arm movement restriction 3 months ago. Imaging examination showed metastases of lymph nodes, pleura, and liver. Sintilimab (200 mg) was injected into the patient for the first time 1 month ago. Thereafter, his general condition improved and his diet, rest, and sleep were normal. Moreover, he did not take other new special drugs. Two weeks later without obvious cause, the patient's skin showed generalized red and swollen plaques accompanied with severe itching. He was hospitalized in thoracic surgery 5 days ago. Dermatological examination revealed a large number of plaques, scales, scratches, crusts, and pigmentation on the scalp, trunk, and limbs [Figure 1A].

Dermoscopic and histopathological examinations were conducted on one lesion on his left leg during hospitalization [Figure 1B]. The dermoscopic patterns showed the lesion of regular scales under 50× lens and dotted blood vessels under 200× lens [Figure 1C and 1D]. Histopathology analysis showed hyperkeratosis with hypokeratosis, acanthosis, epidermal ridge extension, and mild infiltration

of lymphocytes surrounding the blood vessels in superficial dermis [Figure 1E and 1F].

Sintilimab was discontinued after he was hospitalized, and intravenous infusion of methylprednisolone (40 mg per day) was given for 3 days. After consultation with a dermatologist, he was treated with oral prednisone (30 mg per day), antihistamine, and tripterygium glycoside tablets. We did not stop the glucocorticoid administration to prevent his psoriasis progression. The patient's condition improved quickly, and he was discharged from the hospital. He was told to continue these oral medications and was followed-up after 2 weeks. Two weeks later, the patient discontinued the oral drugs on his own accord. Scaly plaques rapidly covered most of his body, and he experienced severe itching. Thus, he was hospitalized again.

According to previous experience, only oral antihistamine was given, and hydrocortisone mixed with Vaseline was spread onto all his lesions twice a day. The patient felt slight relief of pruritus, and his condition improved gradually. He was discharged from the hospital again after a few days of observation without further exacerbation.

We then compared the patient's lesions and histopathology features with those of plaque psoriasis. They were similar, but have some differences. Histopathology results showed less hypokeratosis and denser hyperkeratosis in our case. However, we also found that our patient had dotted blood vessels and regular white scales that are typical dermoscopic features of plaque psoriasis. These features could help differentiate it from pityriasis rubra pilaris and eczematous drug eruption. The dermoscopic features of pityriasis rubra pilaris are round-to-oval yellowish areas surrounding a central hair with or without follicular plugs, and blood vessels are absent.<sup>[2]</sup> Eczematous drug eruption lacks regular white scales and dotted blood vessels. The mechanism of anti-PD-1 or anti-programmed death ligand 1 (PD-L1) underlying psoriasis exacerbation may be

Access this article online

Quick Response Code:



Website:  
www.cmj.org

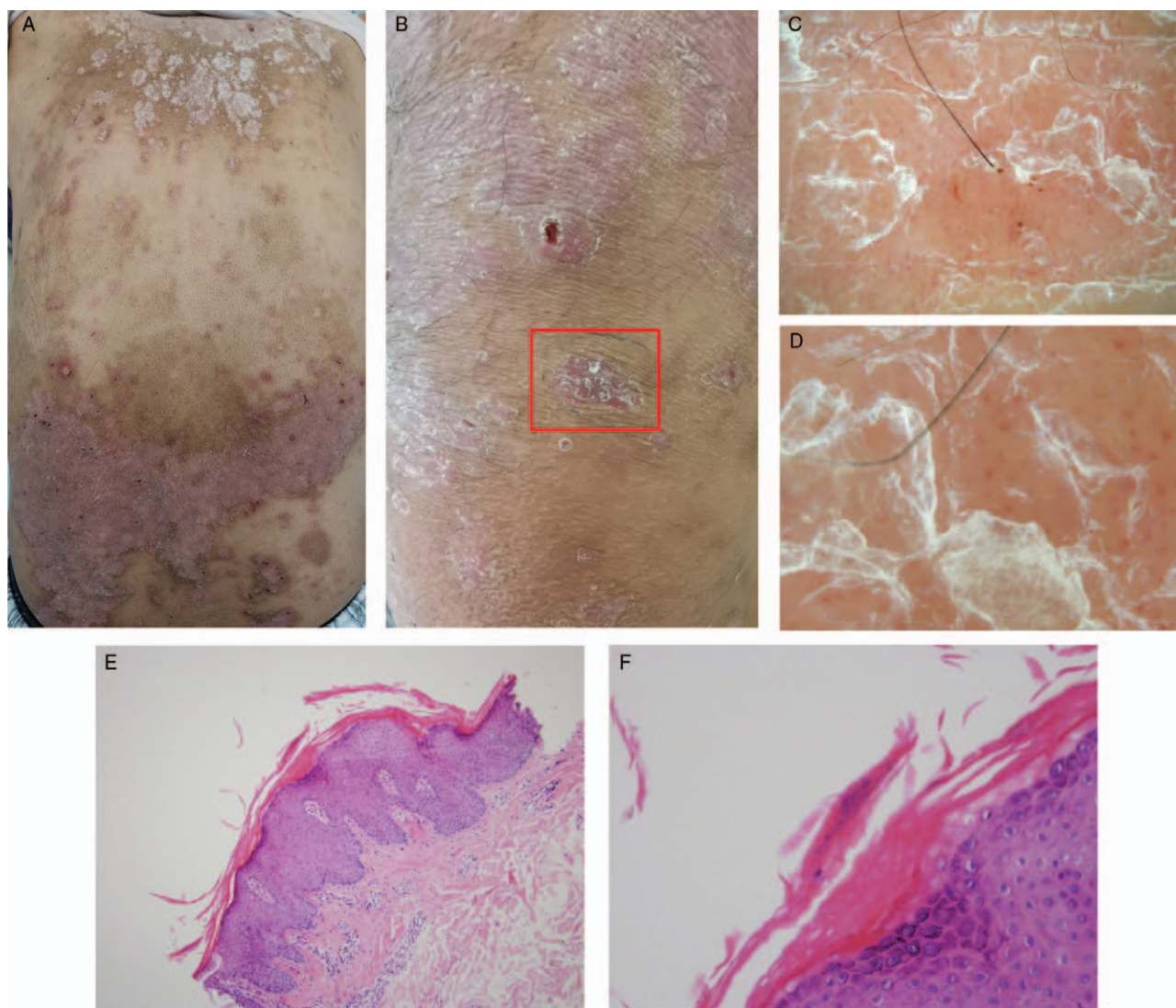
DOI:  
10.1097/CM9.0000000000000958

**Correspondence to:** Dr. Wei Zhu, Department of Dermatology, Xuanwu Hospital, Capital Medical University, Beijing 100053, China  
E-mail: zhuwei@xwh.ccmu.edu.cn

Copyright © 2020 The Chinese Medical Association, produced by Wolters Kluwer, Inc. under the CC-BY-NC-ND license. This is an open access article distributed under the terms of the Creative Commons Attribution-Non Commercial-No Derivatives License 4.0 (CCBY-NC-ND), where it is permissible to download and share the work provided it is properly cited. The work cannot be changed in any way or used commercially without permission from the journal.

Chinese Medical Journal 2020;133(17)

Received: 30-04-2020 Edited by: Li-Shao Guo



**Figure 1:** Lesions, dermoscopic, and histopathological patterns of the patient. (A) Large area of scaly plaque on the back. (B) Lesion where dermoscopic patterns and histopathology analyses were performed (red box). (C) Dermoscopic changes were shown as regular scales (polarized-light pattern, non-contact, original magnification  $\times 50$ ). (D) Dermoscopic changes were shown as regular scales and clear dotted blood vessels (polarized-light pattern, non-contact, original magnification  $\times 200$ ). (E) The histology showed hyperkeratosis with hypokeratosis, acanthosis, epidermal ridge extension, and mild infiltration of lymphocytes that surround the blood vessels in superficial dermis (hematoxylin-eosin staining, original magnification  $\times 100$ ). (F) The histology showed hyperkeratosis with hypokeratosis (hematoxylin-eosin staining, original magnification  $\times 400$ ).

related to the downregulation of PD-1 on the surface of T cells, resulting in indirect activation of downstream cytokines, such as interleukin (IL)-1, IL-17, and IL-22. These factors are crucial to the occurrence or exacerbation of psoriasis.<sup>[3]</sup> However, the specific mechanism remains unclear. Some similar cases have been reported in foreign literature, in which psoriasis is exacerbated during the use of anti-PD-1 or anti-PD-L1 for different kinds of tumors. The general management for these patients is similar to that for common psoriasis.<sup>[4]</sup> Whether patients could continue to use anti-PD-1 during such severe psoriasis remains a controversial issue, and these patients are relatively challenging to handle. As a precautionary measure, we recommended that our patient discontinue using Sintilimab because further research is necessary to formulate a standardized treatment plan. Meanwhile, the

use of dermoscopy should be promoted and applied as it is a good tool for quickly and accurately diagnosing this adverse reaction. Oncologists and thoracic surgeons should strengthen cooperation with dermatologists to achieve early diagnosis and scientific treatment of such patients. Otherwise, we should pay more attention to the adverse skin reaction of anti-PD1 drug given its extensive use.

#### **Declaration of patient consent**

The authors certify that they have obtained all appropriate patient consent forms. In the form, the patient has given his consent for his images and other clinical information to be reported in the journal. The patient understands that his name and initials will not be published and due efforts will

be made to conceal his identity, but anonymity cannot be guaranteed.

### Acknowledgements

Thanks to Dr. Hui Chen, Dr. Yu Zhao from Department of Dermatology, Xuan Wu Hospital, Capital Medical University for their opinions of treatment for the patient. Thanks to Dr. Yu-Ying Lin from Department of Dermatology, Xuan Wu Hospital, Capital Medical University for her guidance in the revision of the paper. Thanks to Dr. Shu-Yang Yao from Department of Thoracic Surgery, Xuan Wu Hospital, Capital Medical University for providing information of the patient, and professional knowledge of lung cancer and anti-PD-1.

### Conflicts of interest

None.

### References

1. Di Altobrando A, Bruni F, Alessandrini A, Starace M, Misciali C, Piraccini BM. Severe de-novo palmoplantar and nail psoriasis complicating Nivolumab treatment for metastatic melanoma. *Dermatol Therapy* 2020; published ahead of print. doi: 10.1111/dth.13363.
2. Jha AK, Lallas A, Sonthalia S, Jhakar D, Udayan UK, Chaudhary RKP. Differentiation of pityriasis rubra pilaris from plaque psoriasis by dermoscopy. *Dermatol Pract Concept* 2018;8:299–302. doi: 10.5826/dpc.0804a10.
3. Bartosińska J, Zakrzewska E, Purkot J, Michalak-Stoma A, Kowal M, Krasowska D, *et al.* Decreased blood CD4+PD-1+ and CD8+PD-1+ T cells in psoriatic patients with and without arthritis. *Postepy Dermatol Alergol* 2018;35:344–350. doi: 10.5114/ada.2018.75609.
4. De Bock M, Hulstaert E, Kruse V, Brochez L. Psoriasis vulgaris exacerbation during treatment with a PD-1 checkpoint inhibitor: case report and literature review. *Case Rep Dermatol* 2018;10:190–197. doi: 10.1159/000491572.

---

**How to cite this article:** Sui CL, Lin XF, He L, Zhu W. Dermoscopic features of acutely exacerbated plaque psoriasis induced by anti-programmed death-1 for lung cancer. *Chin Med J* 2020;133:2123–2125. doi: 10.1097/CM9.0000000000000958