

CASE REPORT

Pediatric osmotic demyelination syndrome in a case of type 1 diabetes mellitus with diabetic ketoacidosis

Ashlesha Chaudhary¹  | Aashutosh Chaudhary^{1,2}  | Radhaya Shyam Yadav¹ |
Yashaswi Shrestha¹ | Ritu Shah¹

¹Nepal Medical College and Teaching Hospital, Kathmandu, Nepal

²Kathmandu University School of Medical Sciences, Dhulikhel, Kavreplanchowk, Nepal

Correspondence

Ashlesha Chaudhary, Nepal Medical College and Teaching Hospital, Jorpati, Kathmandu, Nepal.
Email: ashlesha04.ac@gmail.com

Funding information

None.

Abstract

Cautious treatment of hyponatremia in diabetic ketoacidosis is necessary in order to avoid the development of osmotic demyelination syndrome which is a demyelinating disorder. Individualized supportive therapy would be fruitful for the management of such cases but there is a need for larger studies to guide the management.

KEYWORDS

case reports, central pontine myelinolysis, diabetic ketoacidosis, hyponatremia

1 | INTRODUCTION

Diabetic ketoacidosis (DKA) is a common acute medical emergency in patients with type 1 diabetes mellitus characterized by the triad of ketosis (urine and serum ketone positive), hyperglycemia (blood sugar level >250 mg/dl), and metabolic acidosis (arterial pH <7.3 and serum bicarbonate <18 mEq/L).¹ Osmotic demyelination syndrome (ODS) is a rare complication of DKA and is characterized by the loss of myelin sheath involving pontine and extrapontine areas manifesting with quadriparesis and neurocognitive changes with characteristic changes in magnetic resonance imaging (MRI).² Here, we report a unique case of a 19-year-old woman with DKA complicated with severe sepsis, metabolic acidosis, mild hypokalemia, and ODS, which to the best of our knowledge, is being reported for the first time from this country.

2 | CASE DESCRIPTION

A 19-year-old girl was referred to our setting from another hospital with a diagnosis of type 1 diabetes mellitus with DKA with severe sepsis with severe metabolic acidosis with mild hypokalemia. Prior to this, the patient had a history of vomiting, abdominal pain, chest pain, and lower back pain 12 days back for which she was admitted where she had been treated along the line of management of diabetic ketoacidosis. One day prior to her admission to our hospital, her reports showed hyponatremia (126 mEq/L) which increased to 137 mEq/L and then to 154 mEq/L (increase by 28 mEq/L) within a period of 24 h.

On presentation, the patient was disoriented. Her vital signs on arrival were temperature of 97 Fahrenheit, respiratory rate of 32 breaths per minute, pulse rate of 102 beats per minute, and the blood pressure was not accessible. Her oxygen saturation was 78% in room air and the

This is an open access article under the terms of the Creative Commons Attribution-NonCommercial License, which permits use, distribution and reproduction in any medium, provided the original work is properly cited and is not used for commercial purposes.

© 2022 The Authors. *Clinical Case Reports* published by John Wiley & Sons Ltd.

Glasgow Coma Score was 7/15. Both the pupils were reactive to light. She had a central line in situ. She was treated with isotonic normal saline, noradrenaline, potassium chloride, insulin, and oxygen after which the blood pressure was noted as 80/50 mm Hg.

Workup on the same day showed a complete blood count of 18,400/cumm, neutrophils 83%, lymphocytes 10%, random blood glucose 171 mg/dl, serum urea 56.1 mg/dl, serum creatinine 1.8 mg/dl, sodium 145.5 mEq/L, potassium 3.3 mEq/L, serum chloride 114.7 mEq/L, ALP 250 U/L, and urine for acetone was positive in dipstick test which showed (+++) indicative of 80 mg/dl. Other findings were unremarkable. She was then intubated after which her SpO₂ was 100% with bagging, pulse rate—100 beats per minute, respiratory rate—24 breaths per minute, and blood pressure—118/76 mm Hg. Her laboratory workups are highlighted in Table 1.

The patient was quadriplegic, with features suggestive of lower cranial nerve paralysis, mutism and preserved consciousness, all of which implied locked-in syndrome but she had no eye movement. Her pupils were fixed (3 mm). She had flaccid paralysis, and reflexes were absent.

On 4th day of admission, plain MRI of the brain (Figure 1) was done which reported:

1. Gyriform pattern T2/FLAIR hyperintensity in the right frontal lobe with diffusion restriction.

2. An area of T1 hypointensity and an area of T2/FLAIR hyperintensity in the central part of the pons without diffusion restriction.

These findings along with clinical scenarios were suggestive of osmotic pontine and extra pontine myelinolysis. She was then managed conservatively with hypotonic fluids, antibiotics, and methylprednisolone. She also required a tracheostomy for prolonged ventilation.

She showed gradual improvement and had a normal motor function with considerable improvement in her cognitive and functional status at the end of her 40 days of admission after which she was discharged from the hospital. After this, the patient was asked to follow-up in one month, but she was lost to follow-up.

The key limitation of this report is the lack of availability of proper documentation of the management and workup of the patient in other hospital from where she was referred.

3 | DISCUSSION

Our case presented a 19-year-old girl diagnosed with type 1 diabetes mellitus with diabetic ketoacidosis with severe sepsis with severe metabolic acidosis with mild hypokalemia who was later diagnosed with ODS which is a rare,³⁻⁵ acute, demyelinating disorder, usually occurring several days after a rapid increment in the serum

TABLE 1 Important laboratory workups

	One day prior to presentation (report from previous hospital)	At the day of presentation (Day 0)	At the time of onset of ODS symptoms (Day 4)	At (Day 31)
Sodium (mEq/L)	126 and 137	154 and 145.5	140	138
Potassium (mEq/L)	–	3.3 and 3.1	3.6	3.6
Chloride (mEq/L)	–	114.6 and 118	111	109
Hemoglobin (g/dl)	–	13.3	11.4	8.9
Random Glucose (mg/dl)	–	171	132	–

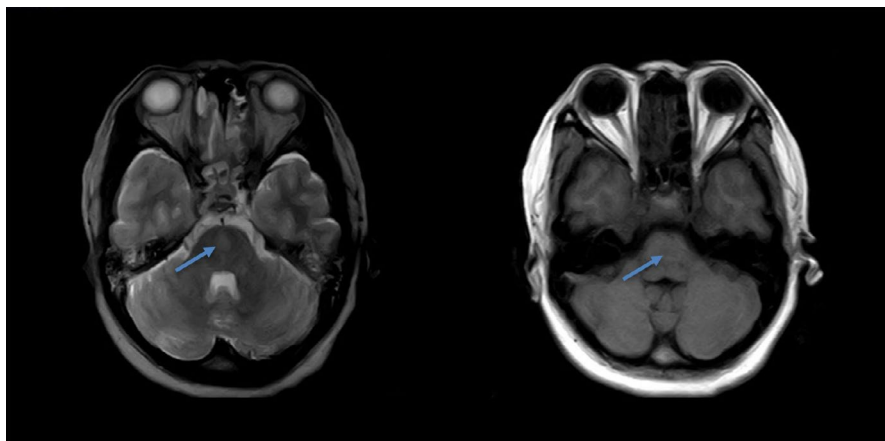


FIGURE 1 Features suggestive of ODS seen in the MRI of the brain

osmolality. ODS in pediatric age group is even more uncommon than it is in adults. Additionally, pediatric ODS is more common in between the age of 1 and 5 years (35%) with its prevalence decreasing with an increase in age group.⁶

The explanation for the pathophysiology of the development of ODS has commonly centered around the rapid correction of hyponatremia or a rise in the serum sodium levels causing the movement of water into the extracellular space leading to the shrinkage of endothelial cells and glial cells of the brain. This could result in the disruption of the blood-brain barrier and eventually to inflammatory demyelination.^{7,8} Other factors besides the rapid correction of hyponatremia could be chronic alcoholism,⁹ hypernatremia,⁶ hypokalemia,^{10,11} hypophosphatemia,¹² anorexia nervosa,¹³ and diabetes mellitus.¹⁴ The possible factors at interplay that could have led to ODS in our case could be overcorrection of hyponatremia leading to hypernatremia; hypokalemia secondary to insulin therapy; and malnourishment and uncontrolled diabetes mellitus. Among these, the most remarkable factor could be the rapid overcorrection of hyponatremia as she had already received a significant amount of fluid at another hospital resulting in an increase of serum sodium level from 126 mEq/L to 154 mEq/L corresponding to a rise of 28 mEq/L in a span of 24 h.

Osmotic myelinolysis is frequently observed in the central pons and other central nervous system regions where maximum admixture of gray and white matter is seen.¹⁵ A review by Bansal LR, et al showed that among 106 pediatric ODS cases, isolated central pontine myelinolysis (CPM) was reported in 46% (49), isolated extra pontine myelinolysis (EPM) in 28% (30), and combined CPM and EPM in the rest, that is, 25% (27).⁶ Our case reported the involvement of both the central pontine and extra pontine regions of the central nervous system.

Osmotic demyelination syndrome, clinically can be presenting with symptoms, including but not limited to progressive spastic quadriparesis, pseudobulbar affect, pseudobulbar palsy, dysarthria, ophthalmoplegia, dysphagia, nystagmus, ataxia, and cranial nerve paralysis. "Locked-in" syndrome or death may be the features of severe cases of ODS.¹⁶ MRI of the brain remains the diagnostic modality of choice for the demonstration of CPM and EPM which could show T2 hyperintensity in the central pons with hypointensity on T1 as reported in the MRI findings of this case. Although there have been reports of asymmetrical lesions, pontine lesions are commonly symmetrical.¹⁷

For the management of a case with ODS, an effective specific treatment has not yet been identified. Hence, the current treatment modality consists of general supportive

care and treatment of the underlying etiology,¹⁸ which was all that was done for the treatment of our patient. Depending on the case, slow correction of electrolyte imbalance,¹⁹ steroids,¹⁷ intravenous immunoglobulin (IVIG),²⁰ plasmapheresis,²¹ thyroid-releasing hormone (TRH), minocycline, lovastatin, and myoinositol are the various options for the treatment, most of which are still under study and lacking enough evidence.²²⁻²⁵

4 | CONCLUSION

We reported an interesting and rare case of ODS in case of pediatric DKA possibly secondary to the rapid overcorrection of hyponatremia also linked to hypokalemia which may very well be considered to reinforce a warning emphasizing on cautious correction of electrolyte imbalances to prevent irreversible consequences. As an effective standard treatment for the case is not yet available, prevention of ODS with a proper approach to hyponatremia should be more focused on.

ACKNOWLEDGMENTS

The authors would like to appreciate the cooperation of the patient and the patient's family for this paper.

CONFLICT OF INTEREST

None.

AUTHOR CONTRIBUTIONS

Ashlesha Chaudhary is the corresponding author, who followed up the patient and involved in the data collection, interpretation, literature review, and manuscript preparation. Radhay Shyam Yadav contributed in data collection and interpretation and revision of the manuscript. Aashutosh Chaudhary contributed in the literature review, data interpretation, and manuscript preparation. Yashaswi Shrestha and Ritu Shah contributed in the literature review and manuscript preparation.

ETHICAL APPROVAL

No ethical limits were crossed during reporting of this article.

CONSENT


Informed written consent was obtained from the patient's husband.

DATA AVAILABILITY STATEMENT

The data related to the patient are available in the Nepal Medical College and Teaching Hospital, Jorpati, Kathmandu, Nepal.

ORCID

Ashlesha Chaudhary  <https://orcid.org/0000-0002-7870-9664>

Aashutosh Chaudhary  <https://orcid.org/0000-0002-5557-5608>

REFERENCES

- Kitabchi AE, Umpierrez GE, Miles JM, Fisher JN. Hyperglycemic crises in adult patients with diabetes. *Diabetes Care*. 2009;32(7):1335-1343. doi:10.2337/dc09-9032
- King JD, Rosner MH. Osmotic demyelination syndrome. *Am J Med Sci*. 2010;339(6):561-567. doi:10.1097/maj.0b013e3181d3cd78
- de Souza A, Desai PK. More often striatal myelinolysis than pontine? A consecutive series of patients with osmotic demyelination syndrome. *Neurol Res*. 2012;34(3):262-271. doi:10.1179/1743132812y.0000000009
- Kallakatta RN, Radhakrishnan A, Fayaz RK, Unnikrishnan JP, Kesavadas C, Sarma SP. Clinical and functional outcome and factors predicting prognosis in osmotic demyelination syndrome (central pontine and/or extrapontine myelinolysis) in 25 patients. *J Neurol Neurosurg Psychiatry*. 2011;82(3):326-331. doi:10.1136/jnnp.2009.201764
- Bhoi KK, Pandit A, Guha G, Barma P, Mishra AK, Garai PK. Reversible parkinsonism in central pontine and extrapontine myelinolysis: a report of five cases from India and review of the literature. *Neurol Asia*. 2007;12:101-109. http://www.neurology-asia.org/articles/20072_101.pdf
- Bansal LR, Zinkus T. Osmotic demyelination syndrome in children. *Pediatr Neurol*. 2019;97:12-17. doi:10.1016/j.pediatrneurol.2019.03.018
- Sugimura Y, Murase T, Takefuji S, et al. Protective effect of dexamethasone on osmotic-induced demyelination in rats. *Exp Neurol*. 2005;192(1):178-183. doi:10.1016/j.expneurol.2004.10.018
- Murase T, Sugimura Y, Takefuji S, Oiso Y, Murata Y. Mechanisms and therapy of osmotic demyelination. *Am J Med*. 2006;119(7 suppl 1):S69-73. doi:10.1016/j.amjmed.2006.05.010
- Lampl C, Yazdi K. Central pontine myelinolysis. *Eur Neurol*. 2002;47(1):3-10. doi:10.1159/000047939
- Shintani M, Yamashita M, Nakano A, et al. Central pontine and extrapontine myelinolysis associated with type 2 diabetic patient with hypokalemia. *Diabetes Res Clin Pract*. 2005;68(1):75-80. doi:10.1016/j.diabres.2004.08.005
- Lohr JW. Osmotic demyelination syndrome following correction of hyponatremia: association with hypokalemia. *Am J Med*. 1994;96(5):408-413. doi:10.1016/0002-9343(94)90166-x
- Turnbull J, Lumsden D, Siddiqui A, Lin JP, Lim M. Osmotic demyelination syndrome associated with hypophosphataemia: 2 cases and a review of literature. *Acta Paediatr*. 2013;102(4):e164-e168. doi:10.1111/apa.12143
- Patel AS, Matthews L, Bruce-Jones W. Central pontine myelinolysis as a complication of refeeding syndrome in a patient with anorexia nervosa. *J Neuropsychiatry Clin Neurosci*. 2008;20(3):371-373. doi:10.1176/jnp.2008.20.3.371
- O'Malley G, Moran C, Draman MS, et al. Central pontine myelinolysis complicating treatment of the hyperglycaemic hyperosmolar state. *Ann Clin Biochem*. 2008;45(Pt 4):440-443. doi:10.1258/acb.2008.007171
- Gocht A, Colmant HJ. Central pontine and extrapontine myelinolysis: a report of 58 cases. *Clin Neuropathol*. 1987;6(6):262-270.
- Brown WD. Osmotic demyelination disorders: central pontine and extrapontine myelinolysis. *Curr Opin Neurol*. 2000;13(6):691-697. doi:10.1097/00019052-200012000-00014
- Bansal LR. Therapeutic effect of steroids in osmotic demyelination of infancy. *Child Neurol Open*. 2018;5:2329048X1877057. doi:10.1177/2329048x18770576
- Louis G, Megarbane B, Lavoué S, et al. Long-term outcome of patients hospitalized in intensive care units with central or extrapontine myelinolysis*. *Crit Care Med*. 2012;40(3):970-972. doi:10.1097/ccm.0b013e318236f152
- Yamada H, Takano K, Ayuzawa N, Seki G, Fujita T. Relowering of serum Na for osmotic demyelinating syndrome. *Case Rep Neurol Med*. 2012;2012:704639. doi:10.1155/2012/704639
- Murthy SB, Izadyar S, Dhamne M, Kass JS, Goldsmith CE. Osmotic demyelination syndrome: variable clinical and radiologic response to intravenous immunoglobulin therapy. *Neurol Sci*. 2013;34(4):581-584. doi:10.1007/s10072-012-1027-8
- Atchaneeyasakul K, Tipirneni A, Gloria S, Berry AC, Shah K, Yavagal DR. Osmotic demyelination syndrome: plasmapheresis versus intravenous immunoglobulin? *Intern Emerg Med*. 2017;12(1):123-126. doi:10.1007/s11739-016-1452-4
- Chemaly R, Halaby G, Mohasseb G, Medlej R, Tamraz J, el-Koussa S. Myélinolyse extra-pontine: traitement par T.R.H [Extrapontine myelinolysis: treatment with TRH]. *Rev Neurol (Paris)*. 1998;154(2):163-165. French.
- Silver SM, Schroeder BM, Sterns RH, Rojiani AM. Myoinositol administration improves survival and reduces myelinolysis after rapid correction of chronic hyponatremia in rats. *J Neuropathol Exp Neurol*. 2006;65(1):37-44. doi:10.1097/01.jnen.0000195938.02292.39
- Takefuji S, Murase T, Sugimura Y, et al. Role of microglia in the pathogenesis of osmotic-induced demyelination. *Exp Neurol*. 2007;204(1):88-94. doi:10.1016/j.expneurol.2006.09.025
- Suzuki H, Sugimura Y, Iwama S, et al. Minocycline prevents osmotic demyelination syndrome by inhibiting the activation of microglia. *J Am Soc Nephrol*. 2010;21(12):2090-2098. doi:10.1681/asn.2010040438

How to cite this article: Chaudhary A, Chaudhary A, Yadav RS, Shrestha Y, Shah R. Pediatric osmotic demyelination syndrome in a case of type 1 diabetes mellitus with diabetic ketoacidosis. *Clin Case Rep*. 2022;10:e05584. doi:[10.1002/ccr3.5584](https://doi.org/10.1002/ccr3.5584)