

Recurrent pneumothorax in a patient with liposarcoma as either a complication of lung micrometastasis or a potential adverse event from antibiotic therapy: A case report

MANLIO MONTI¹, FRANCESCO GIULIO SULLO¹, ANDREA PROCHOWSKI IAMURRI², CATERINA GIANNI¹, PAOLO SILIMBANI³, GIULIA BARTOLINI¹, MARTINA VALGIUSTI¹, LUCA ESPOSITO¹, DANIELA MONTANARI¹, STEFANO ANTONINI¹ and GIOVANNI LUCA FRASSINETI¹

¹Department of Medical Oncology; ²Radiology Unit; ³Oncology Pharmacy Unit, IRCCS Istituto Romagnolo per lo Studio dei Tumori (IRST) 'Dino Amadori', I-47014 Meldola, Italy

Received February 9, 2022; Accepted March 31, 2022

DOI: 10.3892/ol.2022.13324

Abstract. Spontaneous pneumothorax (PNX) is an infrequent manifestation of primary lung cancer, soft tissue sarcoma and metastasis. There are no easily accessible data in the literature regarding the correlation between PNX and antibiotics, whereas cases of PNX following chemotherapy have been observed. Only 1-10% of treatment-related adverse events are estimated to be reported to the Food and Drug Administration. The present study described a case of PNX of the left lung in a 70-year-old treatment-naïve patient with retroperitoneal liposarcoma. The PNX developed after 8 days of treatment with levofloxacin and after 6 days of piperacillin/tazobactam treatment for a suspicious inflammatory area in the right lung detected by an FDG-PET scan before the patient started chemotherapy. A chest CT scan confirmed the presence of metastasis in the right lung, but neither FDG-PET/CT nor CT showed metastatic disease in the left lung. A total of 14 days after the end of the third cycle of doxorubicin (2 months after the initial diagnosis of PNX), the patient manifested a massive PNX of the right lung. In conclusion, these findings indicated that spontaneous PNX could be linked to the use of some antibiotics.

Introduction

Pharmacovigilance plays an important role in evaluating, monitoring and preventing adverse drug reactions (ADRs) (1). Although randomized clinical trials are acknowledged as the gold standard to assess the efficacy and safety of drugs (2), their design is often based on small and homogeneous populations monitored for short periods, making it difficult to detect drug-related reactions (3). Thus, the identification of suspected ADRs in clinical practice represents the foundation of postmarketing surveillance (4). Naranjo *et al* created a tool to distinguish between true ADRs and suspected ADRs (5). Drugs-induced pleural lesions are rare. To date, more than 40 drugs have been linked to the development of pleural lesions, and this number is destined to increase as new drugs are introduced (6). Like levofloxacin, fluoroquinolones (FQs), have been identified as being strongly associated with collagen degradation, aortic dissection, aneurysm and tendinopathy, but up until now no adverse events have been linked to pleura.

Piperacillin/tazobactam is an injectable antibacterial product consisting of the semisynthetic antibiotic piperacillin sodium and the β -lactamase inhibitor tazobactam sodium. We report a case of recurrent PNX following administration of levofloxacin and piperacillin/tazobactam in a patient with chemotherapy-naïve retroperitoneal liposarcoma.

Case report

In January 2020, a 70-year-old Caucasian male was diagnosed with retroperitoneal dedifferentiated liposarcoma. His past surgical, medical, and family history were negative in particular there was no known history of autoimmune conditions, malignancy and PNX. Furthermore, the patient had stopped smoking a few years before. An abdominal CT scan performed in December 2019 had revealed a mass of 190x130 mm in the left retroperitoneum, subsequently confirmed by an MRI. In January 2020, an F-fluorodeoxyglucose (FDG) PET/CT scan showed intense hyperfixation of the radiopharmaceutical in the previously described (SUVmax 16.7) (Fig. 1). After a multi-disciplinary evaluation, it was decided to start neoadjuvant

Correspondence to: Dr Manlio Monti, Department of Medical Oncology, IRCCS Istituto Romagnolo per lo Studio dei Tumori (IRST) 'Dino Amadori', Via P. Maroncelli 40, I-47014 Meldola, Italy
E-mail: manlio.monti@irst.emr.it

Abbreviations: ADR, adverse drug reaction; BAL, bronchoalveolar lavage; FBS, fibrobronchoscopy study; FDG, F-fluorodeoxyglucose; FQ, fluoroquinolone; PICC, peripherally inserted central catheter; PNX, spontaneous pneumothorax

Key words: pneumothorax, levofloxacin, piperacillin/tazobactam, adverse event, adverse drug reaction

chemotherapy with epirubicin 60 mg/m² (4-h infusion) in days 1-2 plus ifosfamide 3,000 mg/m² (2-h infusion) on days 1-2-3 (every 21 days). However, the staging investigations detected signs of lung inflammation in the basal segment of the right lower lobe (SUVmax 5.8), anterior segment of the right upper lobe and hilum, bilaterally. The pulmonologist thus recommended a fibrobronchoscopy study (FBS) and bronchoalveolar lavage (BAL), the latter revealing the presence of macrophages (44%), lymphocytes (6%) and neutrophilic granulocytes (50%). Fungi and neoplastic cells were absent. The quantiferon test was negative.

The patient started levofloxacin 750 mg daily whilst waiting to start chemotherapy. In February 2020 he was admitted to the Inpatient Ward of IRCCS Istituto Romagnolo per lo Studio dei Tumori (IRST) 'Dino Amadori' (Meldola, Italy) to start treatment. Clinical examination was unremarkable and vital signs were: Blood pressure 120/70, heart rate 82/min, oxygen saturation 98%, temperature 36.5°C, respiratory rate 18/min. Blood tests revealed neutrophils 6.9x10⁹/l (range 2.0-8.0), hemoglobin 10.3 g/dl (12.0-17.0), platelets 79x10⁹/l (140-400), creatinine 0.71 mg/dl (0.70-1.20), e GFR 96 ml/min/1.73 m², total bilirubin 0.24 mg/dl (<1.20), aspartate aminotransferase 16 U/l (<40), PCR 106.8 mg/l (<5). Serology test results were negative for hepatitis B and C. To complete the search for potential respiratory infections, urinary antigen tests were performed for *Legionella* and *Pneumococcus*, both negative. The patient was in good clinical conditions but complained of low back pain that radiated down the left thigh for which he only took acetaminophen 500 mg + codeine 30 mg, as needed (usually once a day for nine days). A peripherally inserted central catheter (PICC) was inserted into the basilic vein of the right arm (right basilic vein). The chest X-ray after the positioning of the PICC was negative for lesions and complications (Fig. 2). Given the suspected lung inflammation and elevated PCR (106.8), it was agreed with the pulmonologist to add piperacillin 4 g/tazobactam 500 mg three times a day to levofloxacin. After 5 days of levofloxacin and after three days of piperacillin/tazobactam, PCR values increased to 141.3 mg/l, without fever, and we decided to perform a chest and abdominal CT scan to restage the disease and check the situation in the lungs. After 8 days of antibiotic therapy with levofloxacin and after six days with piperacillin/tazobactam, the CT scan revealed an increase in the size of the primary tumour (177x175x241 mm) and, unexpectedly, the presence of an asymptomatic left apical PNX (87 mm) and a slight homolateral pleural effusion (Fig. 3). The pulmonary nodules in the right upper lobe had increased from 6 to 12 mm and were therefore strongly suggestive of metastasis (Fig. 4). The PCR had dropped slightly to 128.5 mg/l. PNX was initially treated with oxygen therapy 2 l/min and rest. A third chest X-ray performed after 6 days, showed an increase in the PNX (Fig. 5) and the patient thus underwent left pleural drainage, with complete resolution of the problem (Fig. 6). Levofloxacin was stopped after ten days, while piperacillin/tazobactam was continued for a total of 17 days. Given the presence of metastatic disease, it was decided to change antitlastic treatment and so the patient started palliative chemotherapy with doxorubicin 75 mg/m² (q21). Fourteen days after the end of the third cycle of doxorubicin (and just over two months after the first PNX), the patient developed a massive PNX of the right lung with

deviation of cardiomedastinal structures. We summarize the timeline that correlates the use of drugs with the two episodes of PNX (Fig. 7). Pleural drainage was performed, resolving the latter and improving the former. Specific treatment was also administered for *Pneumocystis jirovecii* pneumonia. Best supportive care (BSC) was implemented because of the patient's poor performance status but death ensued four months later.

Discussion

In the area of pharmacovigilance, the most common strategies to evaluate causality between reporting the administration of a drug and a subsequent adverse event are clinical judgment, probabilistic methods and algorithms. However, there is still no universally acknowledged method to assess drug-event causality (7,8). Clinical judgment involves subjective individual assessments made by expert clinicians based on their knowledge and experience in the field to assess causality. Probabilistic methods use specific 'features' of drug-related events within individual case safety reports to transform a previous probability estimate (calculated from existing epidemiologic information) into an estimate of drug causation probability. Algorithms generally use a series of 'yes/no' questions regarding specific characteristics of a drug-related event that have associated scores used to calculate the probability of a cause-effect relationship.

We believe levofloxacin and/or piperacillin/tazobactam could give rise to PNX. The pathophysiologic mechanisms of drug-induced lung injury are still not fully understood. It is believed that drugs may induce a direct toxic effect, acting like a hapten or mimicking an immune cell-activating antigen that is responsible for the damage (6). Some authors have proposed the most convincing hypothesis, suggesting that several classes of antibiotics may trigger oxidative stress in mitochondria, inhibiting their function (9,10).

PNX can present in one of three ways: primary spontaneous pneumothorax (PSP), secondary spontaneous pneumothorax (SSP) and traumatic pneumothorax. PSP is defined as a lack of manifest lung disease and emphysema-like anomalies (blebs, cysts, or bullae). Smoking is the most important environmental risk factor for PSP. SSP is associated with an underlying pulmonary disease, e.g. chronic obstructive pulmonary disease, asthma, cystic fibrosis, pneumonia, pulmonary abscess, tuberculosis, malignancy, interstitial lung disease, connective tissue disease (e.g. Marfan syndrome, rheumatoid arthritis), pulmonary infarction, foreign body aspiration, Birt-Hogg-Dube syndrome (11). Traumatic PNX may be a complication of an invasive procedure such as transthoracic and transbronchial needle biopsy, insertion of a central venous catheter, or positive ventilation. Patients may present with a range of symptoms such as tachycardia and dyspnea. The diagnosis of spontaneous PNX is based on clinical conjecture subsequently confirmed by imaging.

In our case, the patient was an ex-smoker (20 pack/year up to 5 years before the PNX) and did not have a clinical history of obstructive bronchopneumopathy. As far as we know, he was not a user of cocaine, which can also cause PNX (12). We thus hypothesized a correlation between the onset of spontaneous PNX and the antibiotic therapy administered.

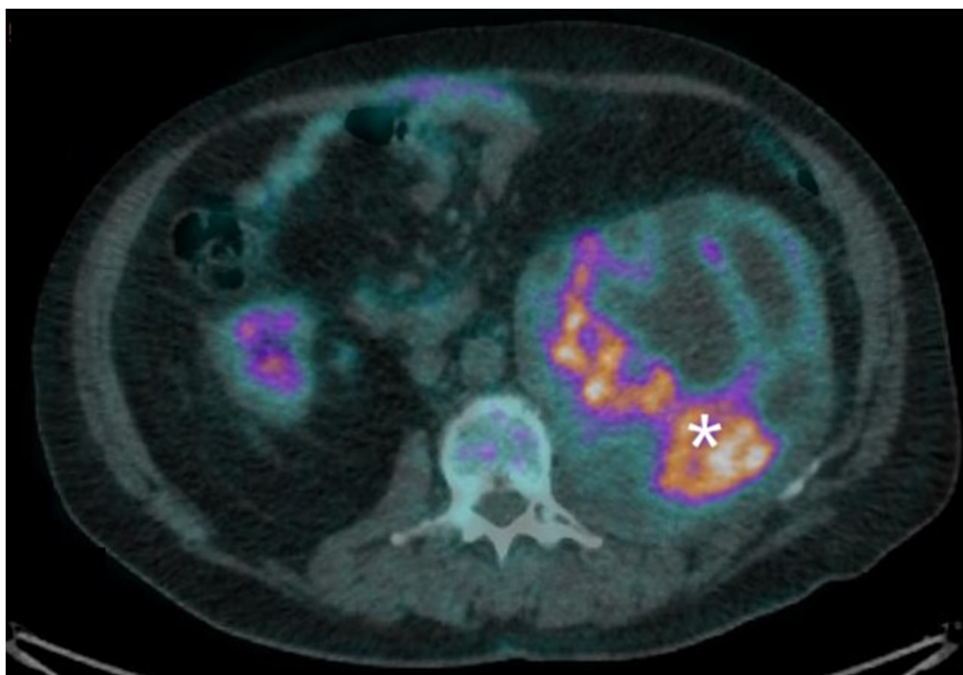


Figure 1. Area of intense uptake of F-fluorodeoxyglucose (white asterisk) inside the retroperitoneal mass present in the left lumbar region.

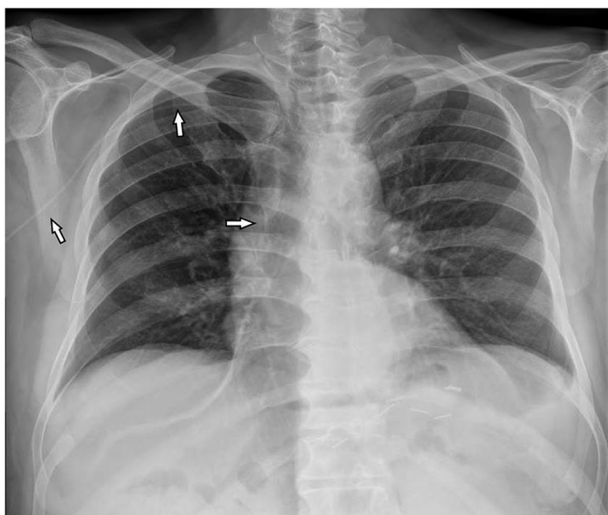


Figure 2. Normal chest X-ray after positioning of a peripherally inserted central catheter line (white arrows) in the right antecubital vein.

Lung injury induced by levofloxacin, a frequently used fluoroquinolone (FQ), is rare. FQs kill bacteria by blocking called class II topoisomerases enzymes. They can also cause severe collagen-associated adverse events (13). *In vivo* and animal research has shown that FQs cause the upregulation of the matrix metalloproteinase enzyme that degrades collagen, in particular collagen I and III. Cell biology and animal studies have also elucidated the pathophysiology by which FQs induce tendon rupture (14,15). Collagen (90% type I and 10% type III) makes up 70% of the dry weight of a tendon (16). Types I and III are also the dominant forms of collagen in the aortic wall, suggesting that a treatment that contributes to tendon rupture may also induce aortic aneurysm (17). Collagen is an essential component of reticular fibres in the

interstitial tissue of the liver, lungs, skin, spleen and blood vessels (18).

As far as we know, only 5 cases of levofloxacin-induced lung injury have been reported in the literature (19-23). In particular, Facciolongo *et al* published a report (22) of acute eosinophilic infiltrate after treatment with piperacillin/tazobactam and levofloxacin for *Legionella pneumophila* and subsequent development of PNx. It is plausible that the PNx in Facciolongo's patient may have been a consequence of anatomical disruption by the immune system. Only one case of lung damage has been correlated with the use of either ciprofloxacin or tosufloxacin (24,25).

Piperacillin is a beta-lactam bactericidal antibiotic that inhibits the synthesis of specific penicillin-binding proteins inside the bacterial cell wall. Tazobactam is an irreversible inhibitor of bacterial beta-lactamases (e.g. staphylococcal penicillinase and extended-spectrum beta-lactamases) that increases piperacillin activity. To the best of our knowledge, the data sheet of only one of many piperacillin/tazobactam compounds approved by the U.S. Regulatory Authority (26) reports a 1.3% incidence of PNx in a nosocomial pneumonia study using a dose regimen of 3.375 g administered every 4 h together with an aminoglycoside.

The occurrence of PNx as a complication of the anti-cancer effect of chemotherapy has been reported in a small number of cases and in several tumour types including sarcoma with multiple lung metastases and osteosarcoma (27). Several hypotheses have been put forward to explain the mechanism of PNx after chemotherapy: i) Rupture of a subpleural bulla; ii) rupture of an emphysematous bulla in a lung partially obstructed by a tumour; and iii) formation of fistula induced directly by tumour lysis or necrosis following cytotoxic chemotherapy. Several case reports of PNx after chemotherapy containing doxorubicin have been published (28,29).

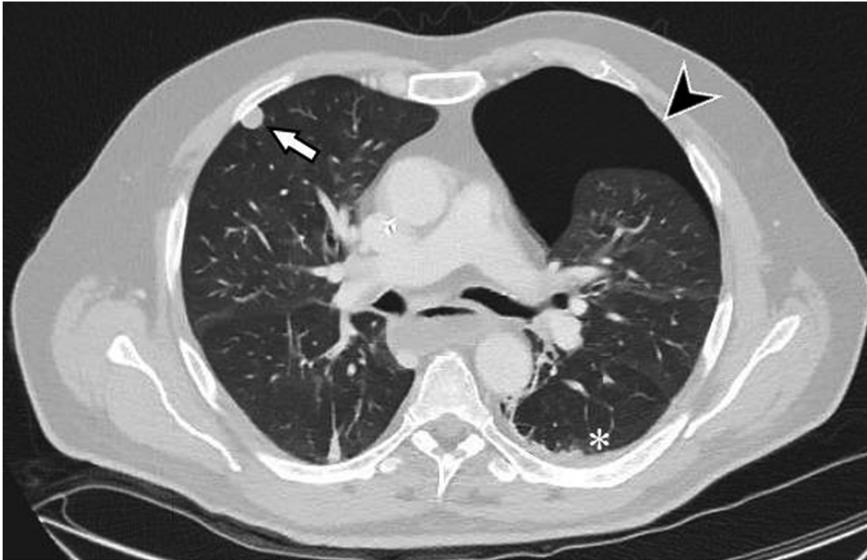


Figure 3. Left pneumothorax (black arrowhead) and pulmonary metastasis (white arrow). Small left pleural effusion is present (white asterisk).

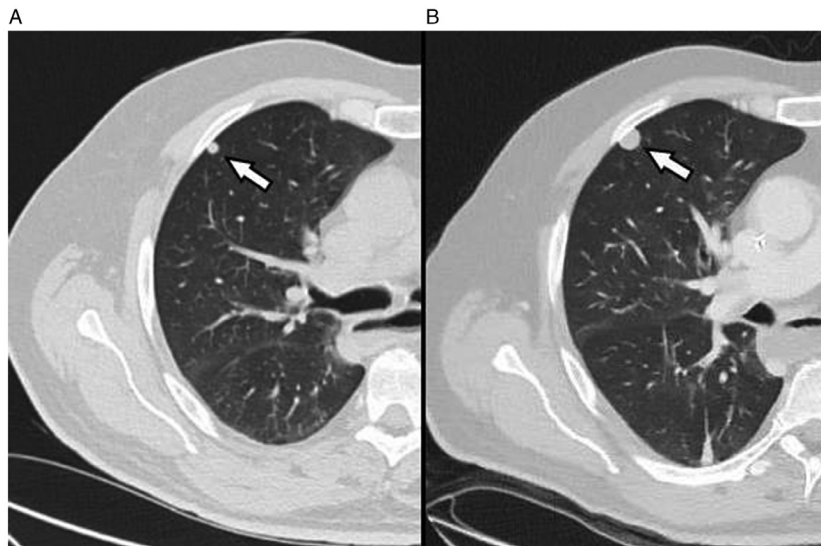


Figure 4. Two consecutive CT scans showing that the right upper lobe lung nodule (white arrows). (A) Initial size of the nodule (6 mm) and (B) the nodule after 1 month (12 mm).

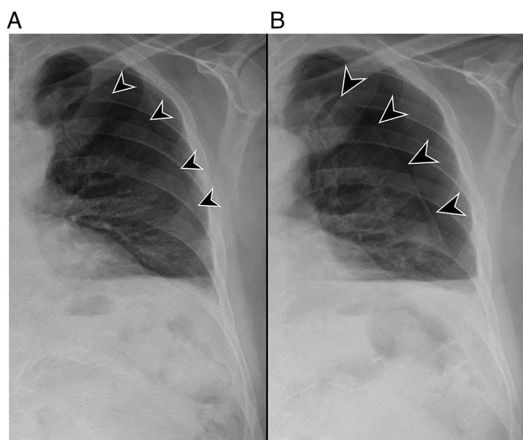


Figure 5. Two expiration views of chest x-ray performed (A) before (A) and (B) after 6 days of oxygen therapy, showing an increase in the size of the left pneumothorax (black arrowheads).

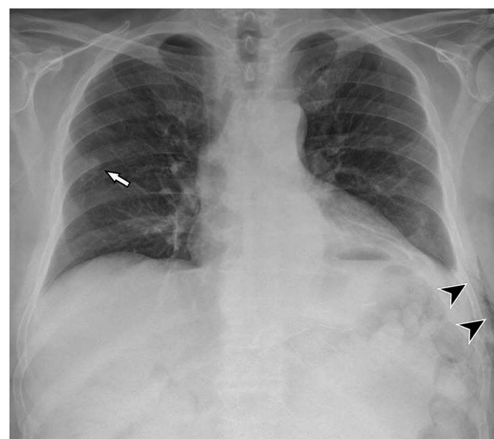


Figure 6. Normal chest X-ray after the removal of left pulmonary drainage. Presence of a small amount of subcutaneous emphysema (black arrowheads) and previously confirmed right upper lobe nodule (white arrow).

Table I. Naranjo algorithm assessment for adverse drug reactions (5).

Question	Scoring	Levofloxacin	Piperacillin/ tazobactam
Are there previous conclusive reports on this reaction?	Yes [+1]	0	1
Did the adverse reaction occur after the suspected drug was given?	Yes [+2]	2	2
Did the adverse reaction improve when the drug was discontinued, or a specific antagonist was given?	Yes [+1]	0	0
Did the adverse reaction appear when the drug was re-administered?	Do not know or not done [0]	0	0
Are there other causes that could have triggered the reaction?	No [+2]	0	0
Did the reaction re-appear when a placebo was given?	Do not know or not done [0]	0	0
Was the drug detected in any body fluid in toxic concentrations?	Do not know or not done [0]	0	0
Was the reaction more severe when the dose was increased or less severe when the dose was decreased?	Do not know or not done [0]	0	0
Did the patient have a similar reaction to the same or similar drugs in any previous exposure?	No [0]	0	0
Was the adverse event confirmed by any objective evidence?	Yes [+1]	1	1
Naranjo score	-	3	4
Adverse drug reaction	-	Possible	Possible

The table shows the score the patient obtained.

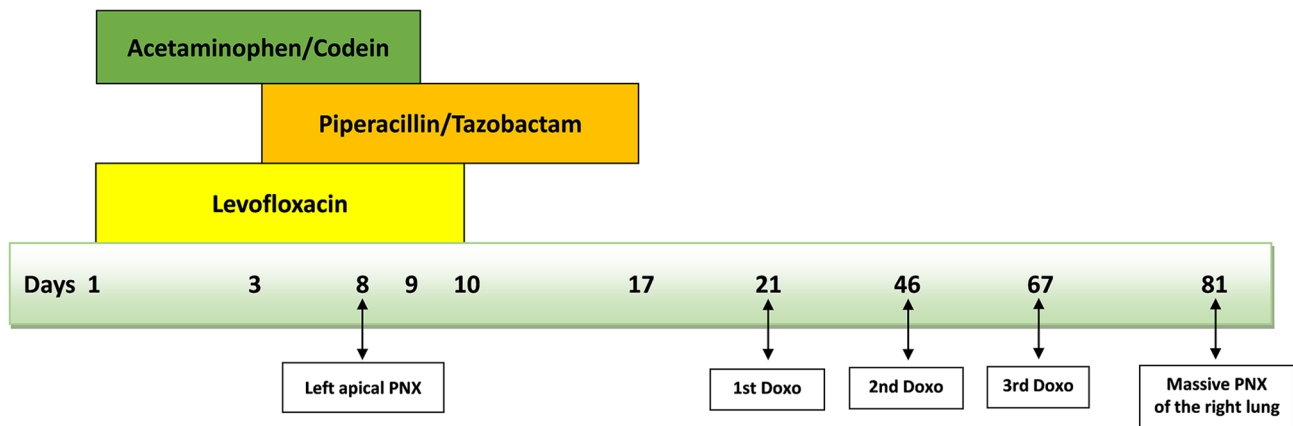


Figure 7. Time-line with drugs and PNX. Days are calculated from the first day of Levofloxacin and Acetaminophen/codeine. PNX, pneumothorax; Doxo, doxorubicin.

A potential limit of our case report is the fact that spontaneous PNX is also a rare indication of primary lung cancer or metastasis. It is estimated that <1% of all cases of spontaneous PNX are associated with malignancies, in particular metastatic osteogenic or soft-tissue sarcomas, and documented mainly in cytotoxic chemotherapy or radiotherapy settings (30). In our case there was a pleural metastasis in the right lung but no evidence of disease in the left lung. However, we cannot exclude the possibility of the presence of micrometastasis in the left lung that was not detectable by CT scan.

Another possible limit of our study is that spontaneous PNX can have a genetic or familial origin (31): We did not do genetic testing or a genetic consultation to verify a genetic

cause of PNX on the other hand, the negative personal and family history for PNX did not require such tests. However mutations in the FLCN gene have also been found in sporadic PNX and not only in familial cases.

Our patient had no previous clinical history of such events and the insertion of the PICC could not have caused the PNX. If we consider that our patient was an ex-smoker we know that smoking is associated to bronchiolitis which has a significant impact on the recurrence rates of PSP (32) but it is not clear in the literature if an ex-smoker still has the same risk to develop a PNX. Recently Kim *et al* (33) reported that relative humidity, carbon monoxide, and air pressure are trigger factors for PSP in patients who were younger (<45 years),

non- or ex-smokers, and male. A possible theory is the patient had an idiopathic PSP that then progressed to massive PNx due to the use of antibiotics. Instead to our knowledge there is no published literature on PubMed that correlates acetaminophen and/or codeine to PNx. A correlation between piperacillin/tazobactam and levofloxacin and the PNx in the left lung seems plausible given the description of other similar PNx cases in the literature (24-26), the fact that the patient had not yet started chemotherapy, and the rapidity with which the PNx occurred during antibiotic therapy. The ADR Probability Scale (Naranjo) consists of 10 questions that are answered as either Yes, No, or 'Do not know'. Different point values (-1, 0, +1 or +2) are assigned to each answer. Total scores range from -4 to +13; the reaction is considered definite if the score is 9 or higher, probable if 5 to 8, possible if 1 to 4, and doubtful if 0 or less. Our patient scored 3 and 4 on the Naranjo Algorithm Assessment for adverse drug reactions (a total score between 1 and 4 indicates a possible adverse drug reaction) in case of levofloxacin and piperacillin/tazobactam respectively (Table I). The appearance of a second, massive PNx in the right lung two months after the first PNx in the contralateral lung (and 14 days after the end of the third cycle of doxorubicin) could be related to the presence of a right lung metastasis and to the chemotherapy administered. Furthermore, we cannot exclude the possibility that the pulmonary inflammation from *Pneumocystis jirovecii* may have facilitated the event.

We believe that a potential correlation between levofloxacin and/or piperacillin/tazobactam and PNx may be underestimated and diagnosed as spontaneous PNx. Although the reporting of adverse drug reactions via pharmacovigilance is vital for monitoring drug safety, improvements in the quality and availability of these documents is urgently needed. The main reason for the underreporting of adverse drug reactions stems from the fact that medical professionals often have a limited knowledge about pharmacovigilance. Training and follow-up activities organized by regulatory authorities on the basis of the needs of healthcare operators could represent an important step towards rectifying this situation.

In conclusion, we invite the scientific community to take into account that spontaneous PNx could result from the use of levofloxacin and/or piperacillin/tazobactam but definitely more retrospective and prospective studies are needed to confirm this conclusion and that PNx may be a complication of lung metastases and/or chemotherapy.

Acknowledgements

Not applicable.

Funding

No funding was received.

Availability of data and materials

The datasets generated and/or analysed during the current study are available from the corresponding author on reasonable request.

Authors' contributions

MM drafted the manuscript and examined the patient. API performed and reviewed the radiological imaging to confirm the presence/absence of lung metastasis. FGS, CG and GLF assisted in the preparation of the manuscript and examined the patient. MM, PS and GB conceptualized and designed the study. LE and DM examined the patient and conducted the literature research. PS, GB, MV, LE, DM and SA examined the patient and critically reviewed the manuscript. MM and GLF confirm the authenticity of all the raw data. All authors have read and approved the final version of this manuscript.

Ethics approval and consent to participate

The study was carried out in accordance with the principles laid down in the 1964 Declaration of Helsinki. Ethics approval was not necessary for this work due to its design (case report). Authors ensured compliance with EQUATOR Guidelines (CARE Case Report Checklist).

Patient consent for publication

Written informed consent was obtained from the patient for the publication of this case report.

Competing interests

The authors declare that they have no competing interests.

References

- Lopes P, Nunes T, Campos D, Furlong LI, Bauer-Mehren A, Sanz F, Carrascosa MC, Mestres J, Kors J, Singh B, *et al*: Gathering and exploring scientific knowledge in pharmacovigilance. *PLoS One* 8: e83016, 2013.
- Silverman SL: From randomized controlled trials to observational studies. *Am J Med* 122: 114-120, 2009.
- Alves C, Macedo AF and Marques FB: Sources of information used by regulatory agencies on the generation of drug safety alerts. *Eur J Clin Pharmacol* 69: 2083-2094, 2013.
- Pal SN, Duncombe C, Falzon D and Olsson S: WHO strategy for collecting safety data in public health programmes: Complementing spontaneous reporting systems. *Drug Saf* 36: 75-81, 2013.
- Naranjo CA, Busto U, Sellers EM, Sandor P, Ruiz I, Roberts EA, Janecek E, Domecq C and Greenblatt DJ: A method for estimating the probability of adverse drug reactions. *Clin Pharmacol Ther* 30: 239-245, 1981.
- Kubo K, Azuma A, Kanazawa M, Kameda H, Kusumoto M, Genma A, Saijo Y, Sakai F, Sugiyama Y, Tatsumi K, *et al*: Consensus statement for the diagnosis and treatment of drug-induced lung injuries. *Respir Investig* 51: 260-277, 2013.
- Agbabiaka TB, Savović J and Ernst E: Methods for causality assessment of adverse drug reactions: A systematic review. *Drug Saf* 31: 21-37, 2008.
- Khan LM, Al-Harthi SE, Osman AM, Sattar MA and Ali AS: Dilemmas of the causality assessment tools in the diagnosis of adverse drug reactions. *Saudi Pharm J* 24: 485-493, 2016.
- Kalghatgi S, Spina CS, Costello JC, Liesa M, Morones-Ramirez JR, Slomovic S, Molina A, Shirihai OS and Collins JJ: Bactericidal antibiotics induce mitochondrial dysfunction and oxidative damage in Mammalian cells. *Sci Transl Med* 5: 192ra85, 2013.
- Wang X, Zhao X, Malik M and Drlica K: Contribution of reactive oxygen species to pathways of quinolone-mediated bacterial cell death. *J Antimicrob Chemother* 65: 520-524, 2010.
- Costumbrado J and Ghassemzadeh S: Spontaneous pneumothorax. In: *StatPearls*. StatPearls Publishing, Treasure Island, FL, 2022.

12. Ciriaco P, Rossetti F, Carretta A, Sant'Angelo M, Arrigoni G and Negri G: Spontaneous pneumothorax in cocaine users. *QJM* 112: 519-522, 2019.
13. Bennett AC, Bennett CL, Witherspoon BJ and Knopf KB: An evaluation of reports of ciprofloxacin, levofloxacin, and moxifloxacin-association neuropsychiatric toxicities, long-term disability, and aortic aneurysms/dissections disseminated by the food and drug administration and the European medicines agency. *Expert Opin Drug Saf* 18: 1055-1063, 2019.
14. Reviglio VE, Hakim MA, Song JK and O'Brien TP: Effect of topical fluoroquinolones on the expression of matrix metalloproteinases in the cornea. *BMC Ophthalmol* 3: 10, 2003.
15. Guzzardi DG, Teng G, Kang S, Geeraert PJ, Pattar SS, Svystonyuk DA, Belke DD and Fedak PWM: Induction of human aortic myofibroblast-mediated extracellular matrix dysregulation: A potential mechanism of fluoroquinolone-associated aortopathy. *J Thorac Cardiovasc Surg* 157: 109-119.e2, 2019.
16. Tsai WC, Hsu CC, Chen CP, Chang HN, Wong AM, Lin MS and Pang JH: Ciprofloxacin up-regulates tendon cells to express matrix metalloproteinase-2 with degradation of type I collagen. *J Orthop Res* 29: 67-73, 2011.
17. Berillis P: The role of collagen in the aorta structure. *Open Circ Vasc J* 6: 1-8, 2013.
18. Gelse K, Pöschl E and Aigner T: Collagens-structure, function, and biosynthesis. *Adv Drug Deliv Rev* 55: 1531-1546, 2003.
19. Fujimori K, Shimatsu Y, Suzuki E, Arakawa M and Gejyo F: Levofloxacin-induced eosinophilic pneumonia complicated by bronchial asthma. *Nihon Kogyoku Gakkai Zasshi* 38: 385-390, 2000 (In Japanese).
20. Tohyama M, Arakaki N, Tamaki K and Shimoji T: A case of drug-induced pneumonitis due to levofloxacin and kampo medicine. *Nihon Kogyoku Gakkai Zasshi* 44: 951-956, 2006 (In Japanese).
21. Shibusa T and Onuma K: A case of possible drug-induced lung injury caused by levofloxacin. *Nihon Kyoubu Rinsho* 74: 691-696, 2015 (In Japanese).
22. Facciolongo N, Menzella F, Castagnetti C, Cavazza A, Piro R, Carbonelli C and Zucchi L: Eosinophilic infiltrate in a patient with severe *Legionella* pneumonia as a levofloxacin-related complication: A case report. *J Med Case Rep* 4: 360, 2010.
23. Hosogaya N, Toida K, Ishihara H and Kugiyama K: A case of drug induced lung injury caused by levofloxacin eye drops. *Respir Med Case Rep* 24: 12-15, 2018.
24. Steiger D, Bubendorf L, Oberholzer M, Tamm M and Leuppi JD: Ciprofloxacin-induced acute interstitial pneumonitis. *Eur Respir J* 23: 172-174, 2004.
25. Kimura N, Miyazaki E, Matsuno O, Abe Y and Tsuda T: Drug-induced pneumonitis with eosinophilic infiltration due to tosufloxacin tosylate. *Nihon Kogyoku Gakkai Zasshi* 36: 618-622, 1998 (In Japanese).
26. USA Food and Drug Administration, Department of Health and Human Services, NDA approval No. 050684/S-055, S-061 and 050750/S-016, S-020. Available from: https://www.accessdata.fda.gov/drugsatfda_docs/applletter/2012/050684s061,050750s016ltr.pdf.
27. Graf-Deuel E and Knoblauch A: Simultaneous bilateral spontaneous pneumothorax. *Chest* 105: 1142-1146, 1994.
28. Upadya A, Amoateng-Adjepong Y and Haddad RG: Recurrent bilateral spontaneous pneumothorax complicating chemotherapy for metastatic sarcoma. *South Med J* 96: 821-823, 2003.
29. Lee CH, Park KU, Nah DY and Won KS: Bilateral spontaneous pneumothorax during cytotoxic chemotherapy for angiosarcoma of the scalp: A case report. *J Korean Med Sci* 18: 277-280, 2003.
30. Matsuura Y, Ninomiya H, Ichinose J, Nakao M, Ishikawa Y, Okumura S and Mun M: Pathogenesis of secondary spontaneous pneumothorax complicating osteosarcoma. *Ann Thorac Surg* 110: e81-e83, 2020.
31. Boone PM, Scott RM, Marciniak SJ, Henske EP and Raby BA: The genetics of pneumothorax. *Am J Respir Crit Care Med* 199: 1344-1357, 2019.
32. Cheng YL, Huang TW, Lin CK, Lee SC, Tzao C, Chen JC and Chang H: The impact of smoking in primary spontaneous pneumothorax. *J Thorac Cardiovasc Surg* 138: 192-195, 2009.
33. Kim D, Eom SY, Shin CS, Kim YD, Kim SW and Hong JM: The clinical effect of smoking and environmental factors in spontaneous pneumothorax: A case-crossover study in an Inland province. *Ther Adv Respir Dis* 14: 1753466620977408, 2020.



This work is licensed under a Creative Commons Attribution-NonCommercial-NoDerivatives 4.0 International (CC BY-NC-ND 4.0) License.