



A New Complex Minimally Invasive Thread Lift Method for One-Time Three-Step Fixation of the Face and Neck Soft Tissues

Olga Zhukova, MD, PhD¹ Sergey Dydykin, MD, PhD² Eliska Kubíková, MD, DSc³
 Natalia Markova, MD, MMed⁴ Yuriy Vasil'ev, DDS, PhD² Marina Kapitonova, MD, PhD⁵

¹Department of Dermatology and STD, RUDN Peoples' Friendship University of Russia, Moscow, Russia

²Department of Topographical Anatomy and Operative Surgery, Sechenov University, Moscow, Russia

³Anatomical Institute, Comenius University, Bratislava, Slovakia

⁴S.R.O. "Medical Esthetic", Prague, Czech Republic

⁵Department of Basic Medical Sciences, Faculty of Medicine and Health Sciences, Universiti Malaysia Sarawak, Kota Samarahan, Sarawak, Malaysia

Address for correspondence Marina Kapitonova, MD, PhD, Department of Basic Medical Sciences, Faculty of Medicine and Health Sciences, Universiti Malaysia Sarawak, Kota Samarahan, Sarawak 94300, Malaysia (e-mail: kmarina@unimas.my).

Arch Plast Surg 2022;49:296–303.

Abstract

Background In recent years thread lift has become widespread; however, existing methods need to improve their long-term outcome, which requires considering topographic anatomy of face and neck, especially the ligamentous apparatus. This study aims to assess the effectiveness and safety of an innovative method of one-time three-step thread facelift, which provides an additional support to the ligamentous structures of the upper, middle, and lower thirds of the face and neck.

Methods The study included 357 patients aged 32 to 67 years with various morphotypes of aging. The original method of thread lift was applied, and its effectiveness was followed up for to 2 years. The Wrinkle Severity Rating Score (WSRS) and Global Aesthetic Improvement Scale (GAIS) scores were used for assessment by investigators, independent observers, and patients. Statistical significance was determined using paired *t*-test and chi-square test.

Results The mean WSRS score was 3.88 ± 0.88 before the thread lift, 1.93 ± 0.81 one month after the procedure, and 2.36 ± 0.85 after 2 years of follow-up. The mean GAIS was 4.80 ± 0.04 one month after thread lift, and 4.01 ± 0.04 after 2 years, while in the patients' assessment Global Satisfaction Scale was 4.86 ± 0.02 and 4.10 ± 0.02 , respectively. There were no clinically significant complications throughout the observation period.

Conclusion The new method of one-time three-step thread fixation of the soft tissues of the face and neck demonstrated a high degree of satisfaction by both experts and patients after 2 years of follow-up. It showed high efficacy and safety, including in the group of patients with pronounced age-related changes of the skin of face and neck.

Keywords

- ▶ aesthetic
- ▶ face
- ▶ minimally invasive facial lifting procedures

DOI <https://doi.org/10.1055/s-0042-1748641>.
 ISSN 2234-6163.

© 2022. The Korean Society of Plastic and Reconstructive Surgeons. All rights reserved.

This is an open access article published by Thieme under the terms of the Creative Commons Attribution-NonDerivative-NonCommercial-License, permitting copying and reproduction so long as the original work is given appropriate credit. Contents may not be used for commercial purposes, or adapted, remixed, transformed or built upon. (<https://creativecommons.org/licenses/by-nc-nd/4.0/>)

Thieme Medical Publishers, Inc., 333 Seventh Avenue, 18th Floor, New York, NY 10001, USA

These days, when the life expectancy of people is increasing, and youth and beauty are being actively promoted everywhere, aesthetic medicine is in great demand, and one of the main tasks becomes the elimination of the external signs of aging of the body; therefore, the last few years have been characterized by a surge of interest in the methods of support and reinforcement of the superficial soft tissues of the face and neck.^{1–4}

For a long time, face lift surgery was the main way to correct age-related changes of the face and neck. However, any surgical intervention usually includes skin incisions, suturing, risk of infection, pronounced postoperative scars, and a long rehabilitation period. Currently, requests for facial rejuvenation are growing in parallel with increasing demand for reduced invasiveness of antiaging interventions, and therefore surgical lifting is gradually giving way to thread lifting.^{5–7} At the same time, the main current requirements are a shorter duration of the procedure, easier technical execution, faster postoperative recovery, fewer complications, and durable effect—all these features made thread lift more attractive than rhytidectomy for both patients and doctors.^{3,8}

The increased interest in thread lifting is actively promoted by the mass media. At the same time, along with the rapidly growing volume of publications in the media, there are fewer papers in the scientific literature, which often present observations over a limited number of patients mainly with moderate skin laxity, short follow-up periods, and not always demonstrating a sufficient degree of objectivity.^{5,6,9,10} Only a few studies show observational data for patients after 18 months from the procedure or using objective assessment methods, such as measuring the lifting height.^{3,11,12}

Thus, despite the significant progress achieved in recent years in thread lift due to progress in facial anatomy, better understanding of the mechanisms of aging, the development of new materials, and tremendous efforts of innovative surgeons, there are no generally accepted standard methods for face and neck thread lifting; aesthetic medicine has not developed common objective criteria for assessment of its effectiveness and still much needs to be done to streamline the technique and technology of thread lift.^{1,13} The aim of this study is to assess the effectiveness and safety of an innovative method of one-time three-step thread lift, which provides an additional strong support to the ligamentous structures of the upper, middle, and lower thirds of the face and neck.

Methods

The study included patients who applied for the correction of age-related changes of the face and neck from 2012 to 2017 at the Esteline Medical Center, Moscow, RF. Inclusion criteria: age 30 to 69 years, men and women with gravitational ptosis corresponding to patient type I, II, and III,¹⁴ and who agreed to participate in the study.

Exclusion criteria: skin diseases, active bacterial, viral, or fungal infection at the site of the proposed thread implanta-

tion, hemophilia, malignant blood diseases, taking anticoagulants, hypoglycemic drugs, and medications which affect skin wound healing, infectious diseases (hepatitis, human immunodeficiency virus, syphilis), type IV patients according to the Baker classification,¹⁴ pregnancy and lactation, severe somatic diseases in the acute stage and/or autoimmune diseases, mental illnesses, and wrinkle correction less than 1 year before the study.

Prior to the procedure, all patients completed a standardized questionnaire and signed a voluntary informed consent protocol in accordance with the principles of the Good Clinical Practice and the Declaration of Helsinki on Human Rights. The consent was extended to participation in the project, publication of the results, and use of the patients' images. The study was approved by the institutional ethics committee (Protocol N09–14, 06.03.2019).

Photographs of the patients were taken using a Canon G10 camera before the procedure and during follow-up visits in a standard sitting position, with the specified parameters of distance and illumination. All thread lifts were performed by the same surgical team. All candidates were divided into three observation groups based on the Baker classification according to the severity of gravitational ptosis¹⁴ and correlating it with Wrinkle Severity Rating Score (WSRS), developed specifically for wrinkle assessment from photographs¹⁵ (► **Table 1**).

Thread Lift Materials

Aptos Visage Excellence (Aptos, Georgia) resorbable surgical thread with multidirectional barbs, USP 2/0, EP 3, 190 mm, made of a co-polymer of polycaprolactone and L-lactic acid; cannula 20G × 150 mm; and lancet point needle 1.8G × 40 mm (► **Fig. 1**).

Surgical Technique

Previously, in an anatomical experiment, threads were implanted at one time in the face (upper, middle, and lower thirds) and neck (data in print).

In our clinical setting all patients underwent a one-time three-stage thread lift with fixation of all significant ligamentous structures of the face in one procedure. Thread implantation was performed under local anesthesia (1% lidocaine with norepinephrine 1:200,000). Using a blunt cannula, barbed sutures were inserted according to the

Table 1 Classification of patients based on the WSRS and Baker's types¹⁴

Group	Number of patients (%)	Baker's type and WSRS
I	92 (25.7)	Type I WSRS 2–3 point
II	153 (42.8)	Type II WSRS 3–4 point
III	112 (31.5)	Type III by WSRS 4–5 points

Abbreviation: WSRS, Wrinkle Severity Rating Score.

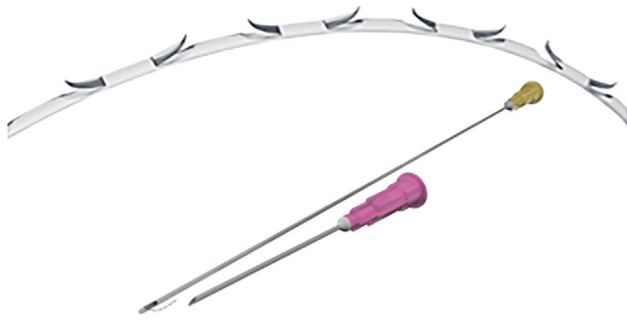


Fig. 1 Apsos Visage Excellence resorbable surgical thread with multidirectional barbs and Apsos Visage Excellence cannula 20G × 150 mm with lancet point needle 1.8G × 40 mm.

determined vectors, as shown in **Fig. 2**. The ends of the suture were brought out to the skin surface at the point of cannula insertion (**Fig. 2**).

1. From a point in the temporoparietal fascia through the zygomatic ligaments, a cannula with a thread was advanced along the lateral temporal-cheek compartment through the masseteric cutaneous ligaments to the mandibular ligament with fixation in the fibers of the mentalis muscle.
2. From a point in the area of the frontal aponeurosis, passing through the temporal region and sending the cannula along the zygomatic arch, passing through the zygomatic ligament, the superior cheek septum or zygomatic cutaneous ligament, the maxillary ligament and then toward the nasolabial compartment with fixation in it.

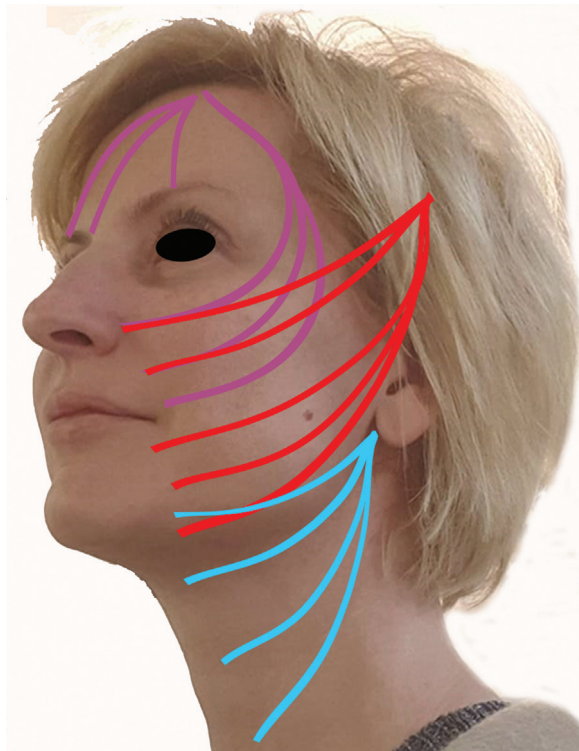


Fig. 2 Directions of thread implantation are indicated in the upper third of the face (purple), in the middle third of the face (red), in the lower third (blue).

3. From a point in the area of the mastoid process, five consequent threads were introduced subcutaneously in a fan-shaped manner, with mandatory fixation in the ligamentous structures, such as platysma-auricular ligament, mandibular septum, mandibular ligament, cervico-mental angle suspensory ligament, and cervical retaining ligaments.

Evaluation of Results

The safety and effectiveness of the thread lift were assessed by clinical examination immediately after the procedure and at the follow-ups: 1 month, 1 and 2 years after the thread implantation. The patients evaluated their satisfaction degree on the 5-point Global Satisfaction Scale (GSS) with scores of 1 (very dissatisfied), 2 (dissatisfied), 3 (fair), 4 (satisfied), and 5 (very satisfied). Blinded assessment of the surgical outcomes of the thread lift was performed by the two certified plastic surgeons not involved in the procedure based on the wrinkle severity assessment tool (5-point scale WSRS, rating as 1: absent; 2: slight; 3: moderate; 4: severe; 5: extreme) comparing the photographs taken at the baseline and at the follow-ups. Level of satisfaction of the surgeons was categorized using a 5-point Global Aesthetic Improvement Scale (GAIS) as 5: “very much improved,” 4: “much improved,” 3: “improved,” 2: “no change,” and 1: “worse.” For statistical analysis, the software SPSS version 13.0 was used. The data were presented as mean values ± standard deviation (M ± SD). Chi-square and paired *t*-test were used to compare the pre- and postoperative scores. Differences were considered statistically significant at $p < 0.05$.

Results

Among the patients who applied to our institution for correction of gravitational ptosis of the face and neck within the specified time frame, 357 patients met our inclusion criteria; they underwent one-time three-stage thread fixation of the main ligamentous structures (inferior temporal septum, zygomatic, maxillary, mandibular, and platysma-auricular ligaments) and fat compartments of the face. The distribution of patients by age and sex is shown in **Table 2**.

As shown in **Table 2**, female patients prevailed in the study (94.7%). The youngest patient was 32 years old, the oldest one aged 67 years. The mean age was 49.50 ± 7.36 years. No major complications were observed in the postoperative period which required debridement or suture removal. Minor side effects did not last long, such as ecchymosis (39.8%)—up to 2 weeks; edema (30%)—5 to 7 days; tenderness (20.7%)—1 to 2 days. Three patients (0.8%) developed dimpling which disappeared after light massaging within 7 to 14 days. Two patients (0.6%) developed asymmetry which was corrected by massaging/pressing the overtightened side.

The lift effect was pronounced and lasted up to 2 years in all patients (**Figs. 3–8**).

WSRS was assessed by two independent experts (surgeons) before the procedure, 1 month and 2 years after thread lift (**Fig. 9**).

Before surgery, the WSRS mean value was 3.88 ± 0.05 ; 1 month after surgery it significantly decreased to

Table 2 Distribution of patients by sex and age

Group	Age	Women	Men	Absolute number of patients (%)
I	32–49 y	84	8	92 (25.7)
II	50–59 y	142	11	153 (42.8)
III	60–67 y	112	–	112 (31.5)

1.93 ± 0.04 ($p < 0.001$) and 2 years later it increased to 2.36 ± 0.04 ($M \pm SD$), remaining significantly lower than before the procedure.

One month after surgery, all patients showed a decrease in the WSRS index, while in 92.4% patients this score dropped by more than 1 point. After 2 years 57.7% of patients sustained WSRS at the immediate postoperative level, and in the remaining 42.3% it increased by 1 point, while in none of the patients the WSRS score returned to the prelifting level.

Aesthetic efficacy (GAIS) as assessed by physicians and patients' satisfaction (GSS) are presented in **Fig. 10**. The patients' subjective assessment of the efficacy and safety of the procedure showed that after 1 month, 313 people (87.7%) rated the result by 3 points, 39 people (10.9%) by 2 points, 5 (1.4%) patients by 1 point (average GSS score being 4.86 ± 0.02). In the assessment of the procedure's results by the two independent surgeons, 5 points were assigned to the 307 (86.0%) patients, 4 points to 27 (7.6%), and 3 points to 23 (6.4%) patients (mean GAIS score being 2.80 ± 0.04).

After 2 years, the average score decreased in patients to 4.10 ± 0.02 ($p < 0.001$), and in observers to 4.01 ± 0.04 ($p < 0.001$). At the same time, in 36.7% of patients, GSS did not decrease compared with the assessment at the 1-month follow-up, in 49.9% it decreased by 1 point, and in 13.4% by 2 points, but in all patients, it remained 3 and above. According to observers, at the 2-year follow-up, GAIS also did not drop below 3 in any patient; while for 38.1% it remained at the same level, for 45.4% it decreased by 1 point, and for 16.5% by 2 points.

Discussion

Aging is accompanied by sagging, drooping of soft tissues, and the formation of wrinkles, which can be improved by

lifting and removing excess skin with lost elasticity, while at least sagging and drooping can be removed with thread lifting.³ Thread lifting of facial tissues was introduced in the late 1980s and was immediately called "one hour lunch break lift."^{5,16} Early technologies mainly used nonabsorbable sutures, such as Aptos Thread, Woffles thread, Isse's Endo Progressive Facelift suture, Contour threads, and Silhouette suture, which can compete in efficiency with face lifting, but remain in the skin forever, often causing complications, such as expulsion.^{11,17,18} Soluble threads made from polydioxanone, polygluconate, polycaprolactone, or poly-L-lactic acid, as well as their copolymers, give fewer complications, especially in the long term. They are now more popular, although their effectiveness is still estimated ambiguously. The Silhouette Instalift is the one of the common thread-lift brands made of 18% polyglycolic acid and 82% poly-L-lactic acid. Polydioxanone threads have also become widespread giving a high level of patients' satisfaction, characterized by painless setting, a low number of complications, a relatively low cost, a fast recovery period, but within 6 months they completely dissolve, which leads to a rapid attenuation of the visible effect after this period.^{6,19–22} On the other hand, it was demonstrated that the threads themselves, such as polydioxanone sutures in particular, dissolve within 4 to 6 months, after which the lifted tissues are fixed by a newly formed collagen, which is able to retain them for up to 12 to 15 months, giving a satisfactory result within this period.^{5,23}

Threads have different lengths and thicknesses and are supplied with various tightening structures, such as knots, barbs, notches, and cones running in different directions.^{5,7,10,24} The main mechanisms of action of implanted threads are lifting, fixation, and biostimulation of collagen genesis in the surrounding tissues. Modern threads often successfully combine all these mechanisms. Aptos threads

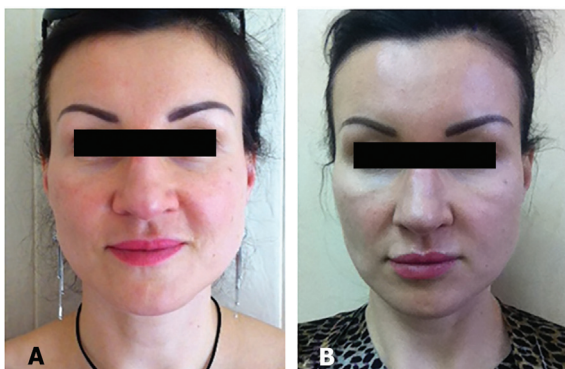

Fig. 3 Patient K., 45 years old, group I. (A) Before the procedure; (B) 2 years after the procedure.

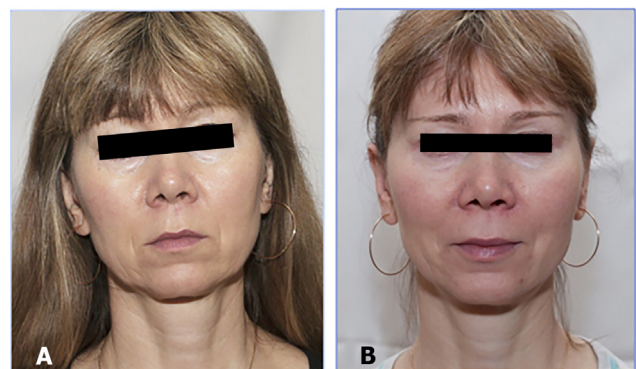


Fig. 4 Patient N., 52 years old, group II. (A) Before the procedure; (B) 2 years after the procedure.

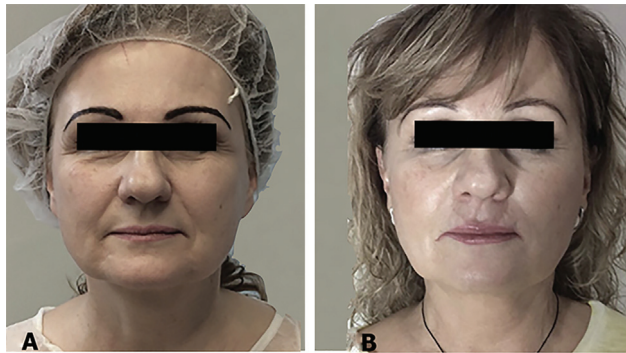

Fig. 5 Patient S., 54 years old, group II. (A) Before the procedure; (B) 2 years after the procedure.

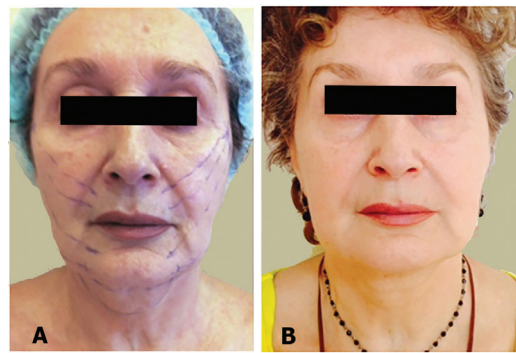

Fig. 6 Patient N., 58 years old, group III. (A) Before the procedure; (B) 2 years after the procedure.

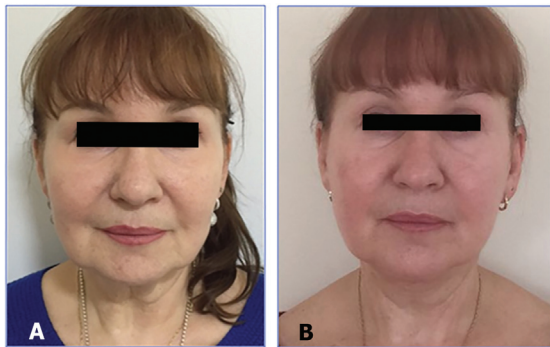

Fig. 7 Patient J., 58 years old, group II. (A) Before the procedure; (B) 2 years after the procedure.

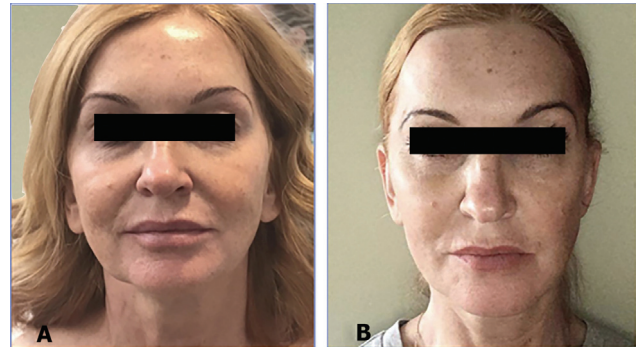

Fig. 8 Patient N., 45 years old, group I. (A) Before the procedure; (B) 2 years after the procedure.

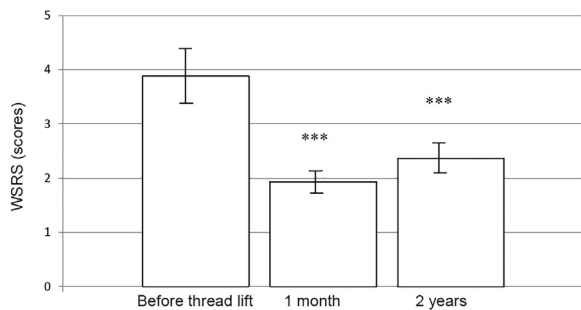


Fig. 9 WRS before and after the thread lift, mean \pm standard deviation. *** $p < 0.001$ compared with before thread lift. WRS, Wrinkle Severity Rating Score.

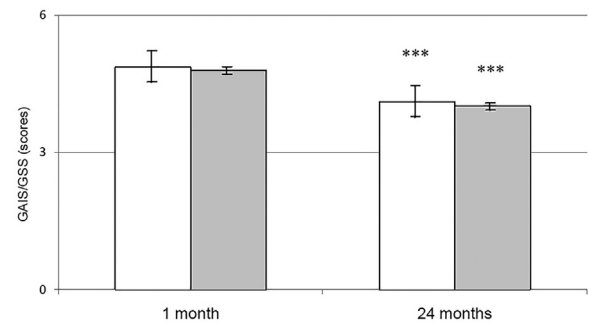


Fig. 10 GAIS and GSS at different periods of observation, mean \pm standard deviation. *** $p < 0.001$ compared with 1 month. GAIS, Global Esthetic Improvement Scale; GSS, Global Satisfaction Scale.

have a unique position in aesthetic medicine.^{3,8} Introduced at the end of the last century as the first insoluble sutures with notches, they gained popularity among both doctors and patients, and their successful application is referred to by many authors.^{4,25} One of the latest versions of Aptos materials is soluble polycaprolactone threads with multidirectional barb. They have a longer degradation period compared with other soluble threads, which makes their effect sufficiently long, almost comparable to that of insoluble sutures. In our study, modern soluble barbed Aptos threads with multidirectional cuts made of polycaprolactone and L-lactic acid copolymer were used, which have proven themselves well among doctors and patients.^{3,8} They induce long-term adhesion reactions and provide an effect essentially comparable

to that of nonabsorbable threads.³ Their multidirectional barb form a good fixing frame and induce a fairly intensive biostimulation of fibrillogenesis, causing a long-lasting effect.⁴ It is understandable that the notches decrease the diameter of the threads and accordingly their strength. However, the technique of the proposed method, which involves triple anchoring of ptotic tissues, makes the thread scaffold stronger and provides a long-term result of lifting and tissue fixation.

Even though today various types of threads are widely available in cosmetology, and each doctor can make a choice according to his preferences and goals, the effect does not always meet expectations, one of the serious reasons being not considering the ligamentous apparatus of the face. Many issues of durable effectiveness and safety need to be further addressed. Therefore, to develop effective and safe methods of thread implantation, considering the important features of the facial topographic anatomy, especially its ligamentous apparatus, is still an urgent task that many surgeons are trying to solve.^{3,26}

The new method of one-time three-step thread lift of the face and neck used by us provides reliable and long-term fixation of soft tissues. The barbed threads with counter-directed incisions serving as a fixation apparatus are simultaneously inserted in the three areas of the face: frontal, temporal, and mastoid, and pass through the ligaments and septa with dense fibrous structure. In most thread-lift procedures, the sutures are implanted in a fan-like mode from one, two, or three points located in the zone of the zygomatic ligaments or the temporal septum. According to our new technique, simultaneously introduced surgical threads with several fixation points in the ligaments and fascia retain the entire superficial musculoaponeurotic system of the face and neck, while the additional intersection of threads in the forehead and cheek area creates a reliable framework for ptotic tissues of the face and provides a complex and more durable reinforcement of the upper, middle, and lower thirds of the face and neck. Addition of the third stage allowed us to get long-term results even without combination of thread lifting with other methods of rejuvenation, such as suction-assisted liposuction, laser-assisted lipolysis, fat grafting, neuromodulators, and filler injection.^{17,27}

The method showed a high degree of satisfaction by both doctors and patients with the result, which lasted up to 2 years of follow-up. It demonstrated high effectiveness in correction of age-related changes in patients with different morphotypes of aging and the degree of gravitational ptosis, including patients of Baker's type III. The success of the proposed method of thread implantation is confirmed by high rates of patients' and doctors' satisfaction as demonstrated by combined assessment of the GAIS/GSS (for patients and doctors) and WSRs (for observers) scales.

Many authors mention that large-scale blind clinical trials on the long-term consequences of minimally invasive facial lifting procedures are missing, while a 6- to 12-month follow-up or even less is not enough to assess the duration of thread lift results, as the procedure has both short- and long-term consequences.^{3,18,24} A few papers present the results of patients' follow-up only for the first 4 to 6 months after thread lift.^{7,20} Few researchers provide statistical data on the results of the 2 or more years of follow-up.^{3,12,13} In several studies, some patients were followed up for 2 years, but statistical data are not provided.^{28,29} This enables some authors to doubt the possibility of getting a long-term effect by the thread lift.^{10,20} Rare studies with a 2-year follow-up of patients after thread lift with soluble threads (polydioxanone, polyglactin) were performed on a limited number of

patients: from 8 to 74.^{3,12,13} The satisfaction scores in the papers of the cited authors are lower compared with our results, the reasons for which probably lie in the special features of our technique, which allows for enhanced fixation of facial tissues affected by gravitational ptosis.

This study is one of the few that combined, first, a larger number of observations (357), and second, a longer period of postoperative follow-up, as we included only patients available for the 2-year follow-up. In many papers it was stated that the results between the second and the sixth months after the procedure not only sustained but even improved, despite the fact that soluble threads usually degrade during this period, but they are taken over by the newly formed type I and III collagen fibers, synthesis of which was stimulated by barbs and cogs.^{22,28} In our study, we focused on longer follow-ups (up to 2 years). Our study showed that a month after the procedure independent observers (surgeons) in a blinded study demonstrated 100% improvement of the WSRs score, which was improved in 92% of cases by more than 1 point. The GSS and GAIS scores were high in 98.6 and 93.6% of patients respectively. At a 2-year follow-up, all patients retained an improvement in the WSRs score compared with the baseline, which in most patients remained decreased by 2 points; however, compared with the immediate postoperative result, WSRs remained at an improved early postoperative level in 58% and worsened by 1 point in 42% of patients.

A slight decrease in the GAIS score was noted in a 2-year follow-up compared with the early postoperative observation (1 month). Despite this fact, in 100% of patients by the end of the second year, the result was at least satisfactory, and in 69 and 73% of patients GAIS and GSS respectively were high. Therefore, this result was better than the one obtained by other researchers (43–60%) using thread lift by the soluble sutures with notches and without additional rejuvenation procedures,^{3,13} while in another study,¹² none of the patients had a higher than satisfactory result.

Thus, contrary to the opinion of several researchers on the thread lifting effect not lasting more than 6 to 18 months,^{6,20–22} our proposed technique for enhanced fixation of tissues susceptible to gravitational ptosis allowed us to extend the effect of thread lift for up to at least 24 months. In all of our 357 patients, the lifting effect persisted until the end of the follow-up period.

It is noted that the duration of the thread lifting effect is inversely proportional to the age of patients and may last long only in younger patients.³ Most authors provide data on the high efficiency of thread lifting in patients with moderate severity of gravitational ptosis.^{5,7,9} In our study, we managed to achieve good results in older patients and with more severe laxity of skin, including Baker's type III patients,¹⁴ which can also be explained by the special features of our method, which gives additional support to the tissues subjected to ptosis.

To date, only a few studies have been conducted using objective methods for assessment of the effectiveness of thread lifting,^{13,20} which actually demonstrate a certain parallelism between objective and subjective data. The

lifting height is measured,¹³ and image analysis is used to detect upward displacement of the facial contour line and a decreased distance between the gonions, as well as between the gonions and the wings of the nose,²⁰ but so far most of the authors have been using visual methods of assessment.

Our method showed a high degree of safety, since no patients had complications that would require surgical intervention or removal of threads, and all minor complications (pain, erythema, edema, bruises) disappeared after 1 or 2 weeks, while rare asymmetry and dimpling were easily corrected and eliminated within 2 weeks. These results are comparable to observations in similar procedures by other authors.^{3,7,28}

Limitations of the Study

The objective methods for assessment of the effectiveness of thread lifting were not applied by us. Currently only single researchers use them for evaluation of the effectiveness of thread lifting.^{12,20} These studies showed that the data obtained by measurements correlated with the results of the visual methods; therefore, subjective data are considered reliable, provided the assessment methods meet the requirements: to be blinded, performed by several certified facial plastic surgeons on a large number of patients, and with long follow-up periods.^{17,18} In our research we complied with all these requirements.

Author Contributions

O.Z.: Conceptualization; data curation; formal analysis investigation; writing—original draft; writing—review and editing. S.D.: Conceptualization; data curation; writing—original draft; writing—review and editing. E.K.: Data curation; formal analysis validation; visualization. N.M.: Data curation; formal analysis; project administration; resources. Y.V.: Software supervision validation; visualization; writing—review and editing. M.K.: Methodology project administration; writing—original draft; writing; review and editing.

Ethical Approval

This study was approved by the institutional ethics committee (Protocol N09–14, 06.03.2019).

Patient Consent

Informed consent was obtained from all individual participants included in the study.

Conflict of Interest

None declared.

References

- Kim BJ, Choi JH, Lee Y. Development of facial rejuvenation procedures: thirty years of clinical experience with face lifts. *Arch Plast Surg* 2015;42(05):521–531
- Pak CS, Chang LS, Lee H, et al. A multicenter noncomparative clinical study on midface rejuvenation using a nonabsorbable polypropylene mesh: evaluation of efficacy and safety. *Arch Plast Surg* 2015;42(05):572–579
- Park YJ, Cha JH, Han SE. Maximizing thread usage for facial rejuvenation: a preliminary patient study. *Aesthetic Plast Surg* 2021;45(02):528–535
- Wong V. The science of absorbable poly(L-lactide-co-ε-caprolactone) threads for soft tissue repositioning of the face: an evidence-based evaluation of their physical properties and clinical application. *Clin Cosmet Investig Dermatol* 2021;14:45–54
- Kang SH, Byun EJ, Kim HS. Vertical lifting: a new optimal thread lifting technique for Asians. *Dermatol Surg* 2017;43(10):1263–1270
- Halepas S, Chen XJ, Ferneini EM. Thread-lift sutures: anatomy, technique, and review of current literature. *J Oral Maxillofac Surg* 2020;78(05):813–820
- Rezaee Khiabanloo S, Jebreili R, Aalipour E, Eftekhari H, Saljoughi N, Shahidi A. Innovative techniques for thread lifting of face and neck. *J Cosmet Dermatol* 2019;18(06):1846–1855
- Yu N, Yu P, Liu Z, et al. Elastic thread modified minimal access cranial suspension lift for lower and middle third facial rejuvenation. *Medicine (Baltimore)* 2020;99(13):e19381
- Lee H, Yoon K, Lee M. Outcome of facial rejuvenation with polydioxanone thread for Asians. *J Cosmet Laser Ther* 2018;20(03):189–192
- Atiyeh BS, Chahine F, Ghanem OA. Percutaneous thread lift facial rejuvenation: literature review and evidence-based analysis. *Aesthetic Plast Surg* 2021;45(04):1540–1550
- Park TH, Seo SW, Whang KW. Facial rejuvenation with fine-barbed threads: the simple Miz lift. *Aesthetic Plast Surg* 2014;38(01):69–74
- Ali YH. Two years' outcome of thread lifting with absorbable barbed PDO threads: Innovative score for objective and subjective assessment. *J Cosmet Laser Ther* 2018;20(01):41–49
- Wattanakrai K, Chiemchaisri N, Wattanakrai P. Mesh suspension thread for facial rejuvenation. *Aesthetic Plast Surg* 2020;44(03):766–774
- Baker DC. Lateral SMASectomy, plication and short scar facelifts: indications and techniques. *Clin Plast Surg* 2008;35(04):533–550
- Savoia A, Landi S, Baldi A. A new minimally invasive mesotherapy technique for facial rejuvenation. *Dermatol Ther (Heidelb)* 2013;3(01):83–93
- Garvey PB, Ricciardelli EJ, Gampper T. Outcomes in threadlift for facial rejuvenation. *Ann Plast Surg* 2009;62(05):482–485
- Abraham RF, DeFatta RJ, Williams EF III. Thread-lift for facial rejuvenation: assessment of long-term results. *Arch Facial Plast Surg* 2009;11(03):178–183
- Gülbitti HA, Colebunders B, Pirayesh A, Bertossi D, van der Lei B. Thread-lift sutures: still in the lift? a systematic review of the literature. *Plast Reconstr Surg* 2018;141(03):341e–347e
- Archer KA, Garcia RE. Silhouette Instalift: benefits to a facial plastic surgery practice. *Facial Plast Surg Clin North Am* 2019;27(03):341–353
- Kwon HH, Choi SC, Park GH, Jung JY. Clinical evaluations of a novel thread lifting regimen using barbed polyglyconate suture for facial rejuvenation: analysis using a 3-dimensional imaging system. *Dermatol Surg* 2019;45(03):431–437
- Wu WTL. Commentary on: effectiveness, longevity, and complications of facelift by barbed suture insertion. *Aesthet Surg J* 2019;39(03):248–253
- Ziade G, Daou D, Karam D. Patient satisfaction with absorbable anchoring facial threads. *Facial Plast Surg* 2021;37(03):383–389
- Suh DH, Jang HW, Lee SJ, Lee WS, Ryu HJ. Outcomes of polydioxanone knotless thread lifting for facial rejuvenation. *Dermatol Surg* 2015;41(06):720–725
- Fukaya M. Long-term effect of the insoluble thread-lifting technique. *Clin Cosmet Investig Dermatol* 2017;10:483–491
- Rezaee Khiabanloo S, Nabie R, Aalipour E. Outcomes in thread lift for face, neck, and nose; a prospective chart review study with APTOS. *J Cosmet Dermatol* 2020;19(11):2867–2876

- 26 Seo YS, Song JK, Oh TS, Kwon SI, Tansatit T, Lee JH. Review of the nomenclature of the retaining ligaments of the cheek: frequently confused terminology. *Arch Plast Surg* 2017;44(04):266–275
- 27 Jeong TK, Chung CH, Min KH. Multi-modal treatment strategy for achieving an aesthetic lower face. *Arch Plast Surg* 2020;47(03):256–262
- 28 Savoia A, Accardo C, Vannini F, Di Pasquale B, Baldi A. Outcomes in thread lift for facial rejuvenation: a study performed with happy lift™ revitalizing. *Dermatol Ther (Heidelb)* 2014;4(01):103–114
- 29 Unal M, İslamoğlu GK, Ürün Unal G, Köylü N Experiences of barbed polydioxanone (PDO) cog thread for facial rejuvenation and our technique to prevent thread migration. *J Dermatolog Treat* 2021;32(02):227–230