

A systematic review and meta-analysis on the value of the external rotation stress test under fluoroscopy to detect syndesmotic injuries

F T Spindler^{id}, V Herterich, B M Holzapfel, W Böcker, H Polzer^{id} and S F Baumbach^{id}

Department of Orthopaedics and Trauma Surgery, Musculoskeletal University Center Munich (MUM), University Hospital, LMU Munich, Munich, Germany

Correspondence should be addressed to H Polzer

Email

Hans.Polzer@med.uni-muenchen.de

- **Purpose:** The aim was to conduct a systematic literature review and meta-analysis to analyze the diagnostic accuracy of the external rotation stress test (ERST) for syndesmotic injuries.
- **Methods:** The systematic review was conducted according to the PRISMA-P guidelines (Prospero ID: CRD42021282457). Four common databases were searched from inception to September 29, 2021. Eligible were any studies facilitating the ERST under fluoroscopy in a defined state of syndesmotic instability. Syndesmotic ligament-specific rupture must have been proven by MRI, arthroscopy, or controlled dissection (cadaver study). Two reviewers independently conducted each step of the systematic literature review. The risk of bias was assessed by the Quality Appraisal for Cadaveric Studies Score scale. The data analysis was performed qualitatively and quantitatively.
- **Results:** Eight studies were eligible for a qualitative analysis, and six studies were eligible for a quantitative analysis. All studies included were cadaver studies. The qualitative analysis comprised 94 specimens and revealed considerable heterogeneity. Six studies allowed for a quantitative analysis of the tibiofibular clear space (TFCS) and five studies for the medial clear space (MCS) during the ERST. The quantitative analysis of the TFCS revealed no significant differences between intact and any stage of syndesmotic injury. The MCS was able to differentiate between intact and 2-ligament- ($Z=2.04$, $P=0.02$), 3-ligament- ($Z=3.2$, $P=0.001$), and 3-ligament+deltoid ruptures ($Z=3.35$, $P<0.001$).
- **Conclusion:** The ERST is the only noninvasive test to assess syndesmotic instability and can be conducted bilaterally. The uninjured contralateral side can serve as a baseline reference. Based on the conducted quantitative analysis, the MCS seems to be able to differentiate between stable (intact/1-ligament) and unstable (2-ligament/3-ligament) lesions.

Keywords

- ▶ external rotation stress test
- ▶ syndesmosis
- ▶ syndesmotic injury

EFORT Open Reviews
(2022) 7, 671–679

Introduction

Isolated injuries to the syndesmotic complex occur in approximately 1–17% of all ankle sprains (1, 2) and in up to 30% in high-impact sports (3). Furthermore, the syndesmosis is injured in up to 13% of all ankle fractures (4). However, assessing syndesmotic stability remains a challenge.

The syndesmotic complex comprises three major ligaments: the anterior inferior tibiofibular ligament (AiTFL), the interosseous membrane (IOM), and the posterior inferior tibiofibular ligament (PiTFL). These provide a three-point fixation of the fibula to the tibia (5). Additionally, the deltoid ligament (DL) stabilizes the talus

medially and restrains its lateral shift (6). Syndesmotic injuries are commonly classified by the Calder adaption of the West Point Ankle Grading System (1, 7, 8). Whereas Grade I (AiTFL sprain) and Grade IIA (AiTFL rupture) lesions are considered stable injuries, Grade IIB (AiTFL, IOM rupture or Deltoid rupture) and Grade III (AiTFL, IOM, PiTFL rupture ± Deltoid) lesions are unstable and necessitate surgery (7). Calder *et al.* also took into consideration the DL, which we do not aim to address in the current study. Therefore, we refer to a Grade IIA injury as an isolated injury to the AiTFL, whereas a Grade IIB injury is defined as an injury to the AiTFL and IOM.

Up to date, especially the differentiation between IIA and IIB injuries remains clinically challenging. Although

MRI is considered the noninvasive gold standard, it remains a static examination, the visualization of the IOM at the level of the syndesmotic complex is limited, and its reported diagnostic accuracy varies (9, 10). As a result, the MRI is limited in distinguishing Grade IIA from Grade IIB injuries. More recently, arthroscopy has been promoted (7). However, arthroscopy is an invasive, highly demanding technique, and the definition of instability criteria is hindered due to considerable individual anatomical variations (11).

The external rotation stress test (ERST) under fluoroscopy is the most commonly used noninvasive, dynamic examination (12). Despite an excellent interobserver agreement (13), its diagnostic accuracy has been questioned, as the definition of cut-off criteria for the different radiographic parameters is limited due to the individual anatomical variations (14). Due to the noninvasive nature of the ERST, it can be conducted bilaterally. This might be a still underestimated advantage of this test. The contralateral, uninjured side could serve as a patient-specific, intact reference standard. Conducting the ERST bilaterally therefore does not rely on general cut-off values, but on patient-specific, contralateral values. This might increase its diagnostic accuracy and possibly allows a differentiation of more subtle instability, i.e. a differentiation between Grade IIA and IIB injuries.

The aim was to conduct a systematic literature review and meta-analysis to analyze the diagnostic accuracy of the ERST for syndesmotic injuries. The primary question of interest was if the ERST could differentiate Grade IIA from IIB injuries.

Materials and methods

The systematic review was conducted according to the PRISMA guidelines (15). The study was *a priori* registered at Prospero (CRD42021282457).

Search strategy

The review question was framed according to the PICOS criteria (Table 1).

Medline (PubMed), Scopus, Central, and Embase were searched from inception to September 29, 2021.

A gray literature search for conference proceedings was performed in Scopus and EMBASE and a general search in OpenGrey (16) (<http://www.opengrey.eu>). In addition, all of the studies' references were hand-searched to identify papers that may not have been found in the systematic electronic search. The search strategy was built upon the principal strategies of Injury AND Syndesmosis AND Radiographs. The entire search strategy is presented in Supplementary data 1 (see section on [supplementary materials](#) given at the end of this article).

Study selection and data extraction

Each database was searched separately, and the resulting datasets were exported to Endnote™ (version 20.1; Fa. Clarivate). Following the removal of duplicates, the final dataset was exported to Covidence™ (Melbourne, Australia). The study selection was conducted independently by two reviewers (F T S, V H). Disagreement was resolved in discussion (S F B). First, a title/abstract screening was conducted. In case of uncertainty, the paper was included for full-text evaluation. Then the full-text screening was performed.

Two reviewers (F T S, S F B) independently conducted the data extraction. Disagreement was again resolved by discussion (H P). The data extracted were level of evidence, study details, and radiographic measurements in the stressed state, separately per the injured syndesmotic ligaments (AiTFL, IOM, PiTFL, and/or DL). If applicable, these parameters were also collected for the intact state (biomechanical studies) or contralateral side (clinical studies). The radiographic parameters were extracted as mean ± s.d. Depending on the data presented, authors were contacted to provide additional information or data values in a different format. If possible, data conversion was performed according to the recommendations of the Cochrane Handbook (17).

Risk of bias assessment

The level of evidence of each study was assessed according to the recommendations of Wright *et al.* (18). The methodological quality of the clinical studies was assessed using the Quality Assessment of Diagnostic Accuracy Studies (QUADS)-2 score (19). The risk of bias

Table 1 PICOS criteria defining the inclusion and exclusion criteria.

Population	Adult patients/human/adult specimens with a defined/known instability of one or more ligaments of the syndesmotic complex, including the deltoid ligament. Adult is defined as ≥18 years of age. Defined injury applies to cadaver studies in which one or more ligaments of the syndesmotic complex have been dissected under direct visual control. Known injury is defined as a verified injury (MRI or arthroscopy) or dissection to one or more ligaments of the syndesmotic complex in patients. Instability is defined as a complete lesion to the respective syndesmotic ligament. For the IOM, at least the distal 5 cm must have been ruptured completely.
Intervention	External rotation stress test under fluoroscopy conducted in a defined state of syndesmotic instability as outlined above. Any radiographic parameter assessed in the stressed state was eligible.
Comparison	If applicable (cadaver studies) intact syndesmotic complex
Outcomes	Any radiographic parameter assessed during the external rotation stress test
Study	Eligible were any cadaver/biomechanical studies or clinical studies, regardless of the study design, with at least 10 patients in clinical studies.

in the cadaveric studies was assessed using the Quality Appraisal for Cadaveric Studies Score (QUACS) scale facilitating a 13-item checklist (20). The QUACS scale is highly reliable with a strong construct validity (20). Study heterogeneity was assessed using the I^2 test. Risk of bias assessment was conducted by two reviewers (F T S, S F B) independently and disagreement was resolved by discussion (H P).

Data synthesis and statistics

The papers included were analyzed per the syndesmotc ligaments ruptured/dissected, and the radiographic parameters assessed during the ERST. Data interpretation was performed as a qualitative and, if possible, a quantitative synthesis.

The quantitative synthesis, i.e. a meta-analysis, was conducted if three or more studies revealed sufficient comparability, using Cochrane RevMan 5.4.1 (version 5.4. The Cochrane Collaboration). Due to possible variations in the exact measurement locations of the assessed radiographic parameters, the differences between different dissection stages were calculated and further analyzed. By using the delta values, a possible interstudy measurement bias could be reduced. Due to the observed heterogeneity, a random effect model with mean difference effect measure was performed for the meta-analysis. Heterogeneity was assessed using the I^2 statistic and rated according to the recommendations by Deeks *et al.* (21): $I^2=0-40%$: not important heterogeneity, $I^2=30-60%$: moderate heterogeneity, $I^2=50-90%$: substantial heterogeneity, and $I^2=75-100%$: considerable heterogeneity.

Results

Figure 1 depicts the study selection process. After removal of duplicates, 2226 studies were screened for title and abstract and the remaining 258 for full text. Nine studies met the eligibility criteria. Gosselin-Papadopoulos *et al.* published two papers (22, 23). After contacting the authors, it became apparent that both studies were based on the same cadaver study. Therefore, these two studies were considered as one study. Consequently, eight studies were eligible for the qualitative (22, 23, 24, 25, 26, 27, 28, 29, 30) and six for the quantitative analysis (22, 23, 25, 27, 28, 29, 30). Their mean QUACS-2 score (20) was 68% (range: 54–77%; Fig. 2).

Five study groups were contacted throughout the study selection process (22, 23, 25, 27, 28, 29). Stoffel *et al.* (29) presented their results in a graph. They were unable to provide absolute data. Therefore, these were extracted from the graph using a scaled y-axis in Photoshop. Three studies (22, 23, 27) only reported differences between the unstressed and stressed conditions, but the authors provided the raw data. Out of these, one group verified that the measurement was conducted on mortise views (25). Finally, one study only reported the *P*-values (28). The authors also provided the raw data.

Qualitative synthesis

The study characteristics of the eight eligible papers are outlined in Fig. 2. Overall, only cadaveric studies met the inclusion and exclusion criteria. The studies comprised a total of 94 fresh-frozen cadaveric specimens. All studies used around the knee amputates and conducted a varying but sequential dissection of the syndesmotc complex.

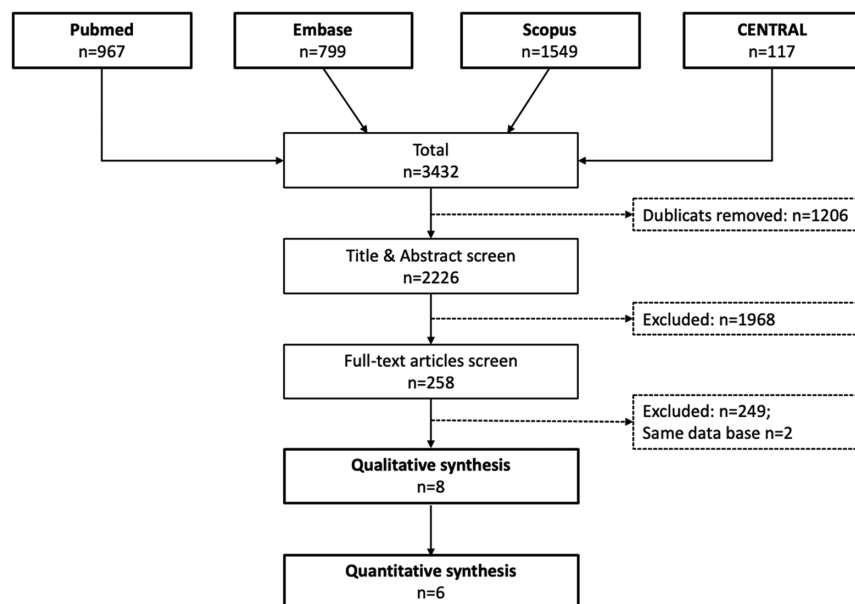
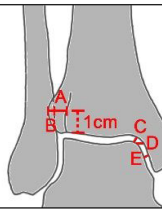
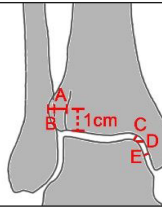
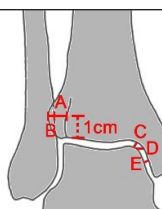
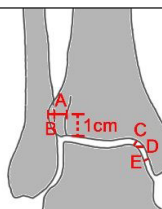
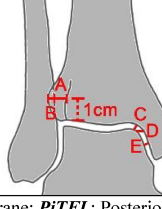


Figure 1 PRISMA flow chart illustrating the study selection process. *n*, number of studies.

Study (year)	Quality assessment [QUACS Scale]	Study model	Participants	Dissection stages (if applicable)	Test assessed	Radiographic view	Radiological parameters
Xenos et al. (1995) (30)	77%	Cadaveric	n=25 Above knee fresh-frozen specimens	Baseline vs. AiTFL vs. AiTFL+2cm IOM vs. AiTFL+4cm IOM vs. AiTFL+6cm IOM vs. AiTFL+8cm IOM vs. AiTFL+IOM+PiTFL	ERST (5Nm)	Mortise view, Lateral view	TFCS: A 
Beumer et al. (2003) (24)	54%	Cadaveric	n=10 Through knee fresh-frozen specimens	Baseline vs. AiTFL or PiTFL or ADL vs. AiTFL+ADL or PiTFL vs. AiTFL+ADL+PiTFL	ERST (150N, 7.5Nm)	AP RSA, Lateral view	AP RSA: Translation and Rotation in various planes [mm] Lateral view: Posterior [mm]
Stoffel et al. (2009) (29)	69%	Cadaveric	n=14 Above knee fresh-frozen specimens	Baseline vs. AiTFL vs. AiTFL+IOM	ERST (7.5Nm) LST (100N)	Mortise view	MCS: D TFCS: A TFO: B 
Femino et al. (2013) (26)	69%	Cadaveric	n=6 Through knee fresh-frozen specimens	Baseline vs. DL vs. DL+AiTFL+IOM+PiTFL	ERST + varus/valgus stress (n.s.)	Mortise view RSA	Medial gutter, Syndesmosis
Jiang et al. (2014) (27)	69%	Cadaveric	n=11 Above knee fresh-frozen specimens	Baseline vs. DL vs. DL+AiTFL vs. DL+AiTFL+PiTFL vs. DL+AiTFL+PiTFL+IOM	ERST (7.5Nm) LST (100N)	Mortise view	MCS: C TFCS: A 
Feller et al. (2017) (25)	69%	Cadaveric	n=10 Above knee fresh-frozen specimens	Baseline vs. AiTFL vs. AiTFL+IOM vs. AiTFL+IOM+PiTFL vs. AiTFL+IOM+PiTFL+DL	ERST (150N, 7.5Nm)	Mortise, (Arthroscopic probing)	MCS: n.s. TFCS: n.s. TFO: n.s.
Gosselin-Papadopoulos et al. (2018 / 2019) (22; 23)	62%	Cadaveric	n=9 above knee fresh-frozen specimens	Baseline vs. AiTFL vs. AiTFL+IOM vs. AiTFL+IOM+PiTFL	ERST (45N) LST (100N)	Mortise, (Direct visualization)	MCS: C TFCS: A 
LaMothe et al. (2018) (28)	77%	Cadaveric	n=9 Above knee fresh-frozen specimens	Baseline vs. AiTFL vs. AiTFL+IOM vs. AiTFL+IOM+PiTFL vs. AiTFL+IOM+PiTFL+DL	ERST (6.5Nm), LST (80N), Sagittal Stress Test (80N)	Mortise view, Lateral view	MCS: E TFCS: A 

N: Number of studies; **Baseline**: Intact syndesmotic complex; **AiTFL**: Anterior inferior tibiofibular ligament; **IOM**: Interosseus membrane; **PiTFL**: Posterior inferior tibiofibular ligament; **DL**: Deltoid ligament; **ADL**: Anterior portion of the Deltoid ligament; **ERST**: External rotation stress test; **LST**: Lateral stress test / Hook test / Cotton test; **RSA**: Radiostereometric Analysis; **MCS**: Medial Clear Space, **TFCS**: Tibio-fibular Clear Space; **TFO**: Tibio-fibular Overlap; **IR**: Internal rotation

Figure 2

Study characteristics. ADL, anterior portion of the deltoid ligament; AiTFL, anterior inferior tibiofibular ligament; baseline, intact syndesmotic complex; DL, deltoid ligament; ERST, external rotation stress test; IOM, interosseus membrane; IR, internal rotation; LST, lateral stress test / Hook test / Cotton test; MCS, medial clear space; N, number of studies; PiTFL, posterior inferior tibiofibular ligament; RSA, radiostereometric analysis; TFCS, tibiofibular clear space; TFO, tibiofibular overlap.

Seven studies performed an ERST (22, 23, 24, 25, 27, 28, 29, 30), and one study conducted an ERST and additionally ERSTs with varus or valgus stress (26). Three studies (22, 23, 27, 29) compared the ERST to a lateral stress test (LST), and one study (28) compared the ERST to the LST and a sagittal stress test. One study each compared the ERST to either arthroscopic probing (25) or direct visualization (23).

Seven studies analyzed their radiographic parameters on Mortise views (22, 23, 25, 26, 27, 28, 29, 30), and two studies performed a radiostereometric analysis (24, 26). Seven studies assessed either the medial clear space (MCS), tibiofibular clear space (TFCS), and/or tibiofibular overlap (TFO) (22, 23, 25, 26, 27, 28, 29, 30).

Out of the six studies performing an ERST and clinical relevant radiographic measurements on mortise views (22, 23, 25, 27, 28, 29, 30), five studies performed sequential dissection from anterior to posterior, i.e. starting with the AiTFL (22, 23, 25, 28, 29, 30), and one study started with the DL (27).

Table 2 summarizes the significant differences of the ERST per the different dissection stages from anterior to posterior compared to baseline measurements, separately for the MCS, TFCS, and TFO. When looking at each study individually, a considerable heterogeneity becomes apparent. Per the differentiation between intact and Grade IIB (AiTFL+IOM) lesions, only one (29) out of four studies (22, 23, 25, 28, 29) found a significant widening for the MCS. For the TFCS, two (29, 30) out of five studies (22, 23,

25, 28, 29, 30) and for the TFO, one (25) out of two (25, 29) found significant differences between intact state and Grade IIB (AiTFL+IOM) lesions.

Quantitative synthesis

As outlined in Table 2, five studies assessed the MCS (22, 23, 25, 27, 28, 29) and six studies assessed the TFCS (22, 23, 25, 27, 28, 29, 30) at some dissection stage during the ERST. All studies were cadaver studies, facilitating a similar setup, performing an ERST, and conducting their measurements on Mortise views. Therefore, these studies allowed for a meta-analysis of two radiographic measurements (MCS and TFCS) during the ERST (Fig. 3). Only two studies assessed the TFO, which did not allow for a cumulative analysis.

For the MCS, the test for heterogeneity varied between $I^2 = 0-91\%$, indicating a considerable varying level of heterogeneity. The cumulative analysis showed that the MCS could not differentiate between intact and AiTFL lesions ($Z=1.43, P=0.15$) but between baseline and AiTFL+IOM lesions ($Z=2.04, P=0.02$), AiTFL+IOM+PiTFL lesions ($Z=3.2, P=0.001$), and AiTFL+IOM+PiTFL+DL lesions ($Z=3.35, P<0.001$). Moreover, the MCS allowed a differentiation between AiTFL and AiTFL+IOM lesions ($Z=3.95, P<0.001$). But, it did not allow to differentiate AiTFL+IOM from AiTFL+IOM+PiTFL lesions ($Z=0.99, P=0.32$).

Table 2 Significant differences of the ERST per the different dissection stages.

Reference	Baseline vs single-ligament (AiTFL)	Baseline vs double-ligament (AiTFL+IOM)	Baseline vs triple-ligament (AiTFL+IOM+PiTFL)	Baseline vs complete dissection (AiTFL+IOM+PiTFL+DL)
Xenos <i>et al.</i> (30)				
MCS				
TFCS	Yes		Yes	
TFO		Yes		
Stoffel <i>et al.</i> (29)				
MCS	Yes	Yes		
TFCS	No	Yes		
TFO	No	No	Yes	
Jiang <i>et al.</i> (27)				
MCS				Yes
TFCS				Yes
TFO				
Feller <i>et al.</i> (25)				
MCS	No	No	Yes	Yes
TFCS	Yes	No	No	Yes
TFO	No	Yes	Yes	Yes
Gosselin-Papadopoulos <i>et al.</i> (22, 23)				
MCS	No	No	No	
TFCS	No	No	No	
TFO				
LaMothe <i>et al.</i> (28)				
MCS	No	No	Yes	Yes
TFCS	No	No	Yes	Yes
TFO				

ADL, anterior portion of the deltoid ligament; AiTFL, anterior inferior tibiofibular ligament; baseline, intact syndesmotic complex; DL, deltoid ligament; ERST, external rotation stress test; IOM, interosseus membrane; IR, internal rotation; LST, lateral stress test/Hook test/Cotton test; MCS, medial clear space; N, number of studies; PiTFL, posterior inferior tibiofibular ligament; RSA, radiostereometric analysis; TFCS, tibiofibular clear space; TFO, tibiofibular overlap..

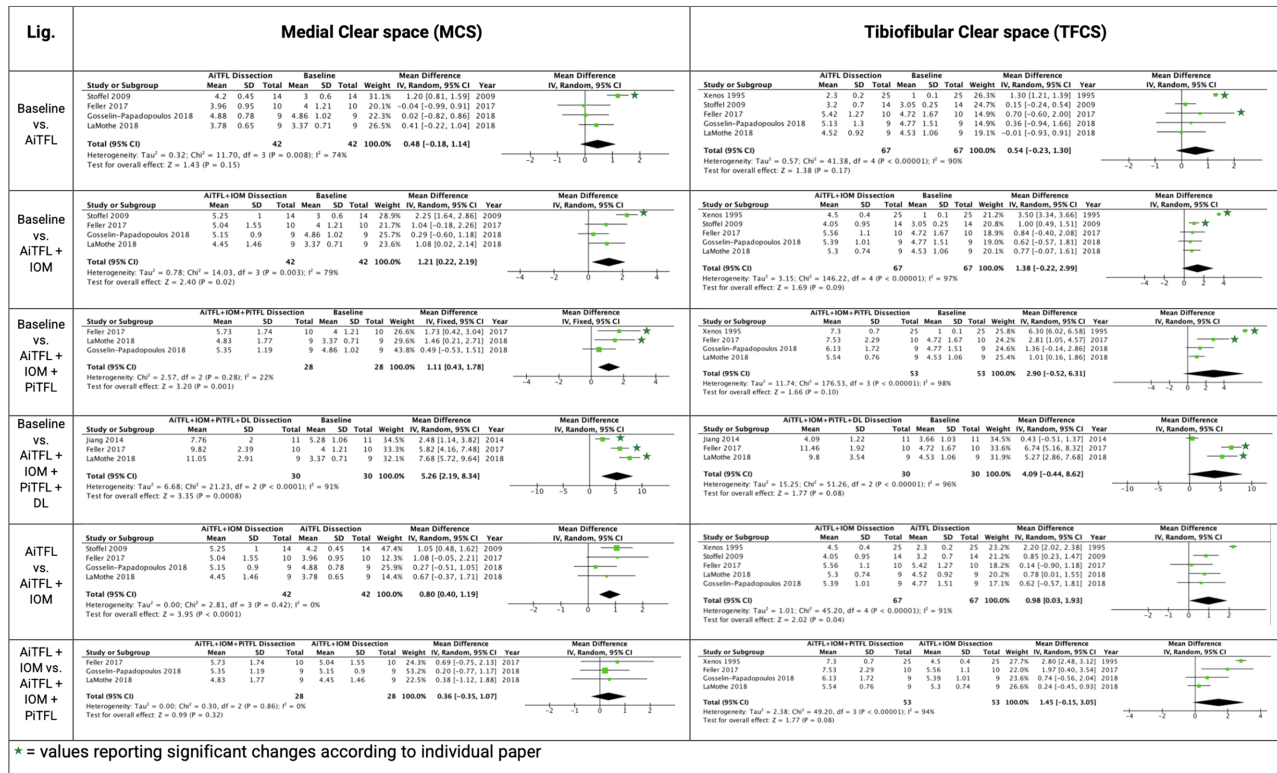

Figure 3

Quantitative analysis of the ERST at different dissection stages of the syndesmodic complex. Xenos *et al.* 1995 (30); Stoffel *et al.* 2009 (29); Jiang *et al.* 2014 (27); Feller *et al.* 2017 (25); Gosselin-Papadopoulos *et al.* 2018/19 (22; 23); LaMothe *et al.* 2018 (28).

The meta-analysis for the TFCS showed a high degree of heterogeneity, ranging between 90 and 98%. Although the mean diastasis of the TFCS increased progressively throughout the stepwise dissection process, it never reached the level of significance in the herein-conducted meta-analysis. The only significant increase for the TFCS was found between AiTFL and AiTF+IOM ($Z=2.02, P=0.04$).

Discussion

Assessing syndesmodic instability remains one of the major challenges in foot and ankle surgery. Especially the differentiation between a stable Grade IIA (AiTFL rupture) and an unstable Grade IIB (AiTFL, IOM rupture) injury is a matter of ongoing discussion (7, 31). The ERST remains a standard procedure to assess syndesmodic instability. Other than the hook test or arthroscopic probing, it is noninvasive, can be conducted bilaterally, and is therefore not only applicable in the OR but also in the outpatient clinic. This is the first study to systematically assess the ligament-specific diagnostic value of the ERST per the different radiographic parameters.

The included studies' mean QUACS scale (20) was 68% with a considerable heterogeneity (range: 54–77%; Fig.

2), indicating a moderate risk of bias. All studies sufficiently outlined their purpose, applied methodology, and data interpretation in the context of current evidence. Still, the quantitative analysis of the individual studies revealed a considerable heterogeneity in the diagnostic accuracy of the ERST.

For the qualitative analysis, there was an increasing agreement between the studies with each additional dissection step (AiTFL < AiTFL+IOM < AiTFL+IOM+PiTFL < AiTFL+IOM+PiTFL+DL). But only one (29) out of four studies assessing the MCS (23, 25, 28, 29) and two (29, 30) out of five studies using the TFCS (23, 25, 28, 29, 30) found a significant increase between baseline and AiTFL+IOM (Grade IIB) dissection.

Five studies (23, 25, 28, 29, 30) allowed for a pooled analysis for the MCS and six studies for the TFCS. The meta-analysis showed that the MCS was able to detect a significant widening of 1.21 mm for the ERST between intact and Grade IIB injuries ($Z=2.04, P=0.02$) but at a significant heterogeneity ($I^2 = 79%, P=0.003$). When comparing the Grade IIA (rupture of the AiTFL) to Grade IIB (rupture of the AiTFL+IOM) lesions, the MCS also increased significantly by 0.8 mm ($Z=3.95, P<0.001$) but with no heterogeneity ($I^2 = 0%, P=0.420$). Especially,

when compared to the uninjured side, it appears plausible that the MCS is capable of differentiating stable (i.e. Grade I/IIA) from unstable (Grade IIB/III) injuries. Nevertheless, the question remains whether an MCS difference of about 1 mm during the ERST is actually of clinical relevance. Previous biomechanical studies have indicated that a lateral shift of the talus by 1.0 mm results in a reduction of 40% of the tibiotalar contact surface area (32, 33). Therefore, a 1 mm increase in lateral shift can be considered clinically relevant.

The meta-analysis for the TFCS found no significant differences between any dissection stage but only between Grade IIA (rupture of the AiTFL) and Grade IIB (rupture of the AiTFL+IOM) lesions ($Z=2.02$, $P=0.04$). Consequently, these findings must be considered inconclusive. One reason for these inconclusive findings could be the high level of heterogeneity observed between the included studies ($I^2=90-98\%$, $P<0.001$). Consequently, it appears reasonable to rather use the MCS than the TFCS to assess syndesmotic instability based on the ERST.

The herein-conducted meta-analysis assessed the difference between intact and ligament-specific dissection stages using the ERST. No absolute values could be defined as cut-off values. The definition of absolute cut-off values in general is limited because of a considerable brought natural morphologic- and gender variance. Previous studies have reported MCS ranging from 2.0 to 4.7 mm (34) and TFCS values ranging from 2.3 to 4.8 mm (34) for the intact stressed state on mortise views. This heterogeneity also limits the definition of absolute cut-off values for arthroscopic probing (11).

The comparison between intact and dissected stages might appear artificial and not applicable in daily practice, as the intact values are unknown. However, due to its noninvasive nature, the ERST can easily be conducted bilaterally. Thereby, the uninjured side can serve as a patient-specific baseline reference. Using the contralateral side as a baseline reference eliminates the above-mentioned problems resulting from the great intersubject variability. By using the contralateral side as a reference, it appears reasonable that more subtle differences can be identified. Based on the herein-conducted meta-analysis, any increased widening of the MCS of more than 1 mm, compared to the contralateral, uninjured side, should be considered as an instability of the syndesmotic complex. Figure 4 outlines an exemplary patient case. The bilateral ERST was conducted in our outpatient clinic. Care has to be taken to achieve true mortise views for both ankles and to apply a similar external rotational force to both ankles. In this case, the obvious side-to-side difference of the MCS indicated a subtle, type IIB syndesmotic lesion. Per the authors' clinical routine, this patient was scheduled for arthroscopically assisted syndesmotic stabilization. Syndesmotic lesion and instability were verified during

arthroscopy and the distal tibiofibular joint was stabilized by a single dynamic suture device. In fracture cases, we would first fix the bony lesions and then conduct a bilateral ERST. In case of obvious MCS side-to-side differences, we would extend the lateral incision disto-ventrally to directly visualize the AiTFL. We then perform another ERST under direct visualization.

Despite these promising findings, several limitations have to be discussed. Most pronounced the abovementioned heterogeneity observed in the meta-analysis. Possible reasons could be the differences in torque applied for the ERST and varying measurement locations. Regarding the torque applied during the ERST, one study did not provide any information (26), one study only stated the force (45 N) (22, 23), and the remaining studies applied between 5 and 7.5 Nm of rotational moment (24, 25, 27, 28, 29, 30). Gosselin-Papadopoulos *et al.* examined the force used under ERST in clinical practice by three surgeons. They found a mean force of 45 N to best reflect the daily practice. They further compared 150N to 45N and found no differences in the mean TFCS (23). Consequently, the observed variety might only have a minor impact on the results. A further source of heterogeneity was the varying measurement locations for the MCS (Fig. 2). One study did not specify the measurement location (25), one study measured the perpendicular MCS (28), one study the horizontal MCS (29), and two studies the oblique MCS (22, 23, 27). These different MCS measurement techniques

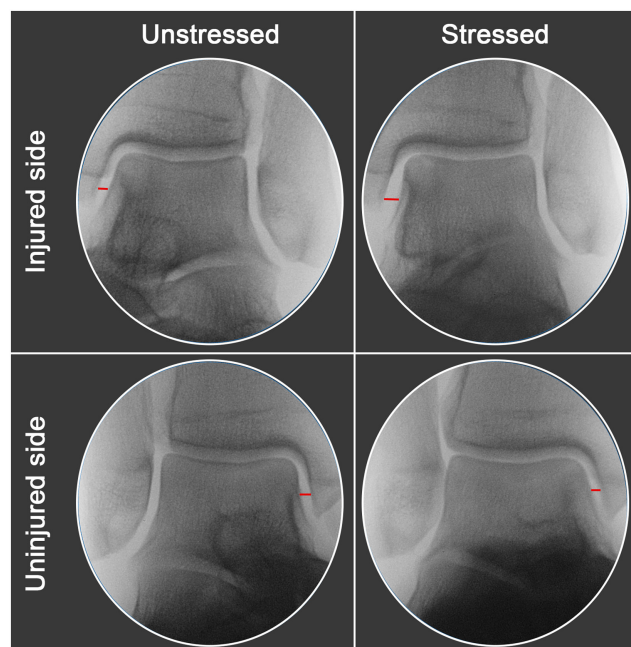


Figure 4

Exemplary patient case illustrating a subtle type IIB syndesmotic injury by bilateral ERST.

result in different measurement values (35, 36). Still, it has been shown that both the perpendicular and oblique MCS behave similarly during the ERST (35). Therefore, these differences can be considered a systemic bias, which most likely did not affect the overall outcome especially as not the total values but the differences were used in this study. A further limitation could be missing clinical data. Still, the aim of this study was to include only highly controlled studies. The subsequent strict inclusion criteria were only met by cadaveric studies. Clinical studies were excluded due to the lack of standardized comparators. It could be argued that the lack of clinical studies was compensated by a sufficient number of highly controlled cadaver studies, six of which were even suitable for a meta-analysis. Finally, the MCS has been shown vulnerable to rotation (37, 38) and the actual foot position (35). Due to the highly standardized setups of the cadaveric studies included in this review, this might be of less importance.

Conclusion

Based on a systematic literature review and meta-analysis, the assessment of the MCS was found more sensitive than the TFCS using the ERST. During the ERST, the MCS apparently allows for a differentiation between stable Grade I (intact)/Grade IIA (AiTFL) and unstable Grade IIB (AiTFL, IOM)/Grade III (AiTFL, IOM, PiTFL) lesions. The great advantage of the noninvasive ERST is that it can be performed bilaterally. Thereby, the uninjured, contralateral side can serve as an intact reference value. Future studies should facilitate the bilateral ERST to detect unstable Grade IIB syndesmotic injuries and correlate these to intraoperative arthroscopic findings.

Supplementary materials

This is linked to the online version of the paper at <https://doi.org/10.1530/EOR-22-0037>.

ICMJE Conflict of Interest Statement

The authors declare that there is no conflict of interest that could be perceived as prejudicing the impartiality of the research reported.

Funding Statement

The study was supported by an AO-research grant granted to S F B.

Author contribution statement

F T S collected the data, helped in conducting the analysis, and helped to write the draft and the paper. V H collected the data and helped to write the paper. B M H assisted in the study design as well as data analysis and interpretation. W B helped to conceive and design the analysis, assisted in data analysis and interpretation. H P helped in designing the study idea and methodology, helped in the data selection and analysis process, and assisted in

the composition of the paper. S F B had the primary study idea, designed the analysis methodology, and wrote the final manuscript. All authors approved the final version of the manuscript.

References

1. Gerber JP, Williams GN, Scoville CR, Arciero RA & Taylor DC. Persistent disability associated with ankle sprains: a prospective examination of an athletic population. *Foot and Ankle International* 1998 **19** 653–660. (<https://doi.org/10.1177/107110079801901002>)
2. Hopkinson WJ, St Pierre P, Ryan JB & Wheeler JH. Syndesmosis sprains of the ankle. *Foot and Ankle* 1990 **10** 325–330. (<https://doi.org/10.1177/107110079001000607>)
3. Mulcahey MK, Bernhardson AS, Murphy CP, Chang A, Zajac T, Sanchez G, Sanchez A, Whalen JM, Price MD, Clanton TO, et al. The epidemiology of ankle injuries identified at the National Football League combine, 2009–2015. *Orthopaedic Journal of Sports Medicine* 2018 **6** 2325967118786227. (<https://doi.org/10.1177/2325967118786227>)
4. Court-Brown CM, McBurnie J & Wilson G. Adult ankle fractures – an increasing problem? *Acta Orthopaedica Scandinavica* 1998 **69** 43–47. (<https://doi.org/10.3109/17453679809002355>)
5. Williams BT, Ahrberg AB, Goldsmith MT, Campbell KJ, Shirley L, Wijdicks CA, LaPrade RF & Clanton TO. Ankle syndesmosis: a qualitative and quantitative anatomic analysis. *American Journal of Sports Medicine* 2015 **43** 88–97. (<https://doi.org/10.1177/0363546514554911>)
6. Hintermann BG & Golanó P. The anatomy and function of the deltoid ligament. *Techniques in Foot and Ankle Surgery* 2014 **13** 67–72. (<https://doi.org/10.1097/BTF.0000000000000044>)
7. Calder JD, Bamford R, Petrie A & McCollum GA. Stable versus unstable grade II high ankle sprains: a prospective study predicting the need for surgical stabilization and time to return to sports. *Arthroscopy* 2016 **32** 634–642. (<https://doi.org/10.1016/j.arthro.2015.10.003>)
8. van Dijk CN, Longo UG, Loppini M, Florio P, Maltese L, Ciuffreda M & Denaro V. Classification and diagnosis of acute isolated syndesmotic injuries: ESSKA-AFAS consensus and guidelines. *Knee Surgery, Sports Traumatology, Arthroscopy* 2016 **24** 1200–1216. (<https://doi.org/10.1007/s00167-015-3942-8>)
9. Randell M, Marsland D, Ballard E, Forster B & Lutz M. MRI for high ankle sprains with an unstable syndesmosis: posterior malleolus bone oedema is common and time to scan matters. *Knee Surgery, Sports Traumatology, Arthroscopy* 2019 **27** 2890–2897. (<https://doi.org/10.1007/s00167-019-05581-5>)
10. Miller JR, Dunn KW, Ciliberti Jr LJ, Eldridge SW & Reed LD. Diagnostic value of early magnetic resonance imaging after acute lateral ankle injury. *Journal of Foot and Ankle Surgery* 2017 **56** 1143–1146. (<https://doi.org/10.1053/j.jfas.2017.05.011>)
11. Hagemeyer NC, Elghazy MA, Waryasz G, Guss D, DiGiovanni CW & Kerkhoffs GMMJ. Arthroscopic coronal plane syndesmotic instability has been over-diagnosed. *Knee Surgery, Sports Traumatology, Arthroscopy* 2021 **29** 310–323. (<https://doi.org/10.1007/s00167-020-06067-5>)
12. Expert Panel on Musculoskeletal Imaging, Smith SE, Chang EY, Ha AS, Bartolotta RJ, Bucknor M, Chandra T, Chen KC, Gorbachova T, Khurana B, et al. ACR appropriateness criteria(R) acute trauma to the ankle. *Journal of the American College of Radiology* 2020 **17** S355–S366. (<https://doi.org/10.1016/j.jacr.2020.09.014>)
13. Nortunen S, Lepojarvi S, Savola O, Niinimäki J, Ohtonen P, Flinkkila T, Lantto I, Kortekangas T & Pakarinen H. Stability assessment of the ankle mortise in supination-external rotation-type ankle fractures: lack of additional diagnostic value of

- MRI. *Journal of Bone and Joint Surgery: American Volume* 2014 **96** 1855–1862. (<https://doi.org/10.2106/JBJS.M.01533>)
- 14. Krahenbuhl N, Weinberg MW, Davidson NP, Mills MK, Hintermann B, Saltzman CL & Barg A.** Imaging in syndesmotic injury: a systematic literature review. *Skeletal Radiology* 2018 **47** 631–648. (<https://doi.org/10.1007/s00256-017-2823-2>)
- 15. Page MJ, McKenzie JE, Bossuyt PM, Boutron I, Hoffmann TC, Mulrow CD, Shamseer L, Tetzlaff JM, Akl EA, Brennan SE, et al.** The PRISMA 2020 statement: an updated guideline for reporting systematic reviews. *BMJ* 2021 **372** n71. (<https://doi.org/10.1136/bmj.n71>)
- 16.** System for Information on Grey Literature in Europe. (available at: <http://www.opengrey.eu>). Accessed 9 November 2021.
- 17. Cumpston M, Li T, Page MJ, Chandler J, Welch VA, Higgins JP & Thomas J.** Updated guidance for trusted systematic reviews: a new edition of the Cochrane Handbook for Systematic Reviews of Interventions. *Cochrane Database of Systematic Reviews* 2019 **10** ED000142. (<https://doi.org/10.1002/14651858.ED000142>)
- 18. Wright JG, Swiontkowski MF & Heckman JD.** Introducing levels of evidence to the journal. *Journal of Bone and Joint Surgery: American Volume* 2003 **85** 1–3. (<https://doi.org/10.2106/00004623-200301000-00001>)
- 19. Whiting PF, Rutjes AW, Westwood ME, Mallett S, Deeks JJ, Reitsma JB, Leeflang MM, Sterne JA, Bossuyt PM & QUADAS-2 Group.** QUADAS-2: a revised tool for the quality assessment of diagnostic accuracy studies. *Annals of Internal Medicine* 2011 **155** 529–536. (<https://doi.org/10.7326/0003-4819-155-8-201110180-00009>)
- 20. Wilke J, Krause F, Niederer D, Engeroff T, Nurnberger F, Vogt L & Banzer W.** Appraising the methodological quality of cadaveric studies: validation of the QUACS scale. *Journal of Anatomy* 2015 **226** 440–446. (<https://doi.org/10.1111/joa.12292>)
- 21. Higgins J & Green S.** *Cochrane Handbook for Systematic Reviews of Interventions Version 5.1.0 [updated March 2011]*. The Cochrane Collaboration, 2011. (available at: www.handbook.cochrane.org)
- 22. Gosselin-Papadopoulos N, Hebert-Davies J, Laflamme GY, Menard J, Leduc S & Nault ML.** A new and more sensitive view for the detection of syndesmotic instability. *Journal of Orthopaedic Trauma* 2019 **33** 455–459. (<https://doi.org/10.1097/BOT.0000000000001495>)
- 23. Gosselin-Papadopoulos N, Hebert-Davies J, Laflamme GY, Menard J, Leduc S, Rouleau DM & Nault ML.** Direct visualization of the syndesmosis for evaluation of syndesmotic disruption: a cadaveric study. *OTA International* 2018 **1** e006. (<https://doi.org/10.1097/OI9.0000000000000006>)
- 24. Beumer A, Valstar ER, Garling EH, van Leeuwen WJ, Sikma W, Niesing R, Ranstam J & Swierstra BA.** External rotation stress imaging in syndesmotic injuries of the ankle: comparison of lateral radiography and radiostereometry in a cadaveric model. *Acta Orthopaedica Scandinavica* 2003 **74** 201–205. (<https://doi.org/10.1080/00016470310013969>)
- 25. Feller R, Borenstein T, Fantry AJ, Kellum RB, Machan JT, Nickisch F & Blankenhorn B.** Arthroscopic quantification of syndesmotic instability in a cadaveric model. *Arthroscopy* 2017 **33** 436–444. (<https://doi.org/10.1016/j.arthro.2016.11.008>)
- 26. Femino JE, Vaseanon T, Phisitkul P, Tochigi Y, Anderson DD & Amendola A.** Varus external rotation stress test for radiographic detection of deep deltoid ligament disruption with and without syndesmotic disruption: a cadaveric study. *Foot and Ankle International* 2013 **34** 251–260. (<https://doi.org/10.1177/1071100712465848>)
- 27. Jiang KN, Schulz BM, Tsui YL, Gardner TR & Greisberg JK.** Comparison of radiographic stress tests for syndesmotic instability of supination-external rotation ankle fractures: a cadaveric study. *Journal of Orthopaedic Trauma* 2014 **28** e123–e127. (<https://doi.org/10.1097/BOT.000000000000010>)
- 28. LaMothe JM, Baxter JR, Karnovsky SC, Murphy CI, Gilbert S & Drakos MC.** Syndesmotic injury assessment with lateral imaging during stress testing in a cadaveric model. *Foot and Ankle International* 2018 **39** 479–484. (<https://doi.org/10.1177/1071100717745660>)
- 29. Stoffel K, Wysocki D, Baddour E, Nicholls R & Yates P.** Comparison of two intraoperative assessment methods for injuries to the ankle syndesmosis. A cadaveric study. *Journal of Bone and Joint Surgery: American Volume* 2009 **91** 2646–2652. (<https://doi.org/10.2106/JBJS.G.01537>)
- 30. Xenos JS, Hopkinson WJ, Mulligan ME, Olson EJ & Popovic NA.** The tibiofibular syndesmosis. Evaluation of the ligamentous structures, methods of fixation, and radiographic assessment. *Journal of Bone and Joint Surgery: American Volume* 1995 **77** 847–856. (<https://doi.org/10.2106/00004623-199506000-00005>)
- 31. DHooghe P, Bouhida S, Whiteley R, Rosenbaum A, Khelaifi K & Kaux J.** Stable versus unstable grade 2 high ankle sprains in athletes: a noninvasive tool to predict the need for surgical fixation. *Clinical Research on Foot and Ankle* 2018 **6** 252. (<https://doi.org/10.4172/2329-910X.1000252>)
- 32. Lloyd J, Elsayed S, Hariharan K & Tanaka H.** Revisiting the concept of talar shift in ankle fractures. *Foot and Ankle International* 2006 **27** 793–796. (<https://doi.org/10.1177/107110070602701006>)
- 33. Ramsey PL & Hamilton W.** Changes in tibiotalar area of contact caused by lateral talar shift. *Journal of Bone and Joint Surgery: American Volume* 1976 **58** 356–357. (<https://doi.org/10.2106/00004623-197658030-00010>)
- 34. Gibson PD, Ippolito JA, Hwang JS, Didesch J, Koury KL, Reilly MC, Adams M & Sirkin M.** Physiologic widening of the medial clear space: what's normal? *Journal of Clinical Orthopaedics and Trauma* 2019 **10** (Supplement 1) S62–S64. (<https://doi.org/10.1016/j.jcot.2019.04.016>)
- 35. Baumfeld D, Baumfeld T, Cangussu J, Macedo B, Silva TAA, Raduan F & Nery C.** Does foot position and location of measurement influence ankle medial clear space? *Foot and Ankle Specialist* 2018 **11** 32–36. (<https://doi.org/10.1177/1938640017699918>)
- 36. Murphy JM, Kadakia AR & Irwin TA.** Variability in radiographic medial clear space measurement of the normal weight-bearing ankle. *Foot and Ankle International* 2012 **33** 956–963. (<https://doi.org/10.3113/FAI.2012.0956>)
- 37. Krahenbuhl N, Akkaya M, Dodd AE, Hintermann B, Dutilh G, Lenz AL, Barg A & International Weight Bearing CT Society.** Impact of the rotational position of the hindfoot on measurements assessing the integrity of the distal tibio-fibular syndesmosis. *Foot and Ankle Surgery* 2020 **26** 810–817. (<https://doi.org/10.1016/j.fas.2019.10.010>)
- 38. Pneumaticos SG, Noble PC, Chatziioannou SN & Trevino SG.** The effects of rotation on radiographic evaluation of the tibiofibular syndesmosis. *Foot and Ankle International* 2002 **23** 107–111. (<https://doi.org/10.1177/107110070202300205>)