



Reinsertion of Distal Brachial Biceps Tendon Rupture through Single Incision Using Anchors*

Reinserção da ruptura distal do bíceps braquial mediante incisão única com uso de âncoras

Carlos Augusto de Mattos¹  Danilo Maia¹ Rodolfo Castro¹ Maurício Etchebehere² 

¹ Department of Orthopedics, Pontifícia Universidade Católica de Campinas, Campinas, São Paulo, Brazil

² Department of Orthopedics, Universidade Estadual de Campinas, Campinas, SP, Brazil

Address for correspondence Carlos Augusto de Mattos, Avenida Jânio da Silva Quadros, 52, Bairro Jardim Chapadão, Campinas, São Paulo, SP, 13070-098, Brazil (e-mail: doutormattos@yahoo.com.br).

Rev Bras Ortop 2020;55(2):191–197.

Abstract

Objective To evaluate 15 patients with ruptured distal biceps tendon submitted to reinsertion via a single, anterior and transverse approach using two anchors. They were submitted to a rehabilitation protocol and, within six months, to an evaluation of the range of motion and strength intensity during flexion and supination of the operated elbow.

Methods The data were collected prospectively, and were analyzed through the Mann-Whitney test and the mixed-model test to evaluate the force between the operated and non-operated elbows.

Results A total of 80% of the patients were men, 60% were injured on the dominant side, 46% were manual workers, and 73% led sedentary lifestyles. The use of anabolic steroids was reported by two patients. After the treatment, the patients recovered supination strength by 98% and flexion by 94%. According to the Disabilities of the Arm, Shoulder and Hand (DASH) questionnaire, 73% of the patients presented the score expected of a normal population.

Conclusion The single, anterior and transverse approach associated with tendon repair using anchors was esthetically satisfactory, with good strength recovery during flexion and supination, and no occurrence of heterotopic ossification.

Keywords

- ▶ biceps
- ▶ elbow/surgery
- ▶ elbow/injuries
- ▶ heterotopic ossification

Resumo

Objetivo Avaliar 15 pacientes com ruptura do tendão distal do bíceps submetidos a reinserção por meio de via única, anterior e transversa no antebraço com o uso de duas âncoras. Os pacientes foram submetidos a um protocolo de reabilitação e, ao término de seis meses, efetuou-se avaliação do arco de movimento do cotovelo operado e da intensidade de força durante a flexão e a supinação.

Métodos Os dados foram coletados de maneira prospectiva, e foram analisados pelo teste de Mann-Whitney e pelo teste de modelos mistos para avaliar a força entre os cotovelos operado e não operado.

* Study performed at Hospital Puc-Campinas, Campinas, SP, Brazil.

Palavras-chave

- ▶ bíceps
- ▶ cotovelo/cirurgia
- ▶ cotovelo/lesões
- ▶ ossificação heterotópica

Resultados Um total de 80% dos pacientes eram homens, 60% sofreram lesão do lado dominante, 46% eram trabalhadores braçais, e 73% não praticavam atividades físicas regularmente. O uso de anabolizante foi relatado por dois pacientes. Após o tratamento, os pacientes recuperaram 98% da força de supinação, e 94% da de flexão. De acordo com questionário de Disfunções do Braço, Ombro e Mão (Disabilities of the Arm, Shoulder and Hand, DASH), 73% dos pacientes encontram-se dentro do esperado para uma população normal.

Conclusão A via única, anterior e transversa associada ao reparo do tendão com o uso de âncoras apresentou-se esteticamente satisfatória, com boa recuperação da força durante a flexão e a supinação, não ocorrendo casos de ossificação heterotópica ou complicações graves.

Introduction

The biceps brachii presents a distal bone attachment at the bicipital tuberosity of the radius that is the most frequent site for ruptures. Rupture of the distal biceps brachii tendon (DBBT) mainly affects the dominant limb of men in the fifth and sixth decades of life, usually during eccentric contraction of elbow flexion at 90 degrees. The degeneration of both the tendon and its insertion may contribute to this type of injury, as well as the use of anabolic steroids.¹⁻⁷

Active elbow movement resumes after the acute phase of the injury. However, DBBT rupture may result in an up to 30% of loss of flexion strength; loss of supination strength may be even more severe, reaching 40%. Biomechanically, the biceps is considered the primary supinator of the forearm and a secondary elbow flexor.⁷⁻¹¹

As such, surgical repair with anatomical reinsertion of the DBBT in the radial tuberosity is indicated for athletes, active patients with high demand, and those who do not accept permanent functional deficits or esthetic deformity.¹¹⁻¹⁴

There are several surgical techniques for the repair of DBBT rupture; the first of them is through a single anterior incision across the elbow. Other techniques were introduced later, such as the double anterior incision and double mini incision, including an anterior and a posterolateral incision. The literature reports radial artery injury, median nerve injury, posterior interosseous nerve injury and proximal radioulnar synostosis as complications resulting from these techniques.^{2,4,6,8,12-17} In-depth knowledge of local anatomy minimizes postoperative complications. As a result, the transverse anterior approach at the radial tuberosity region is more anatomical and respects regional force lines; in addition, it does not cross the anterior elbow crease, avoiding cicatricial retractions. Another advantage is that it does not cross the interosseous membrane, decreasing the occurrence of synostosis or loss of forearm supination.

The present study aims to perform a functional postoperative evaluation of the surgical reinsertion of the DBBT in acute injuries through a single transverse anterior approach at the bicipital radius tuberosity region, comparing it with other techniques already described.

Materials and Methods

The present is a prospective study, approved by the ethics committee (CAAE 23700313.4.0000.5481), and conducted with authorization on the part of all patients, who signed an informed consent form. From 2014 to 2017, 15 consecutive patients, 12 men and 3 women, with a mean age of 44 years (range: 26 to 65 years) with total rupture of DBBT confirmed by history, physical examination and two imaging tests (radiographs of the elbow in anteroposterior and lateral views, and magnetic resonance imaging [MRI]) performed at the same imaging service and using the same MRI equipment, were consecutively operated on. The patients were cared for at the main researcher's outpatient clinical facility. The subjects were included in the protocol and operated at the same hospital, by the same researcher. All patients had the right arm as the dominant limb, and the dominant side was affected in nine patients. Two patients reported the regular use of anabolic steroids.

The following inclusion criteria were defined: age over 18 years, complete injury of the DBBT by non-traumatic effort and acute (less than four weeks), and unilateral injury. Patients with lesions for more than four weeks, partial biceps injuries, previous upper limb injuries or fractures (both ipsilateral or contralateral), and those who did not agree with the surgical treatment or refused to sign the informed consent form were excluded.

Surgical Technique

The patients were submitted to general anesthesia with brachial plexus block; the upper limb was positioned at approximately 90 degrees of abduction. A pneumatic tourniquet (average pressure, 250 mm Hg) was placed on the upper arm, with the forearm and elbow extended and in full supination.

The skin was incised 3 cm distally and parallel to the elbow crease, transversely to the forearm axis, with ~4 cm in length. The intermuscular plane was found between the medial portion of the brachioradialis muscle and laterally to the pronator teres. These muscles were separated with Langenbeck retractors to prevent nerve compression

(especially of the posterior interosseous nerve) against the radius bone. The radial artery is dorsal to the brachioradialis muscle. The lateral cutaneous nerve of the forearm is lateral to the easily identified cephalic vein.

With the forearm in complete supination, the bicipital tuberosity of the radius was observed; in some cases, the distal biceps stump could also be observed. The anatomical attachment of the biceps was opened and decorticated ulnarly to the bicipital tuberosity, preserving its anatomy.

Through the same incision, the stump of the lesion was identified proximally, and the distal repair with absorbable, synthetic, multifilament number 2 suture was performed.

With the tendon and bone bed prepared, 2 titanium anchors with 4 mm of diameter, loaded with high-strength double strands, were introduced into the open bone region, about 0.5 cm apart to prevent additional fractures.

The suture started at the most distal anchor, transfixing the most distal region of the tendon stump and bringing it closer to the most distal part of the prepared bed, using a technique that prevents the slippage of the thread into the tendon (self-locking suture). For the tenodesis, the forearm was flexed at about 30 degrees to decrease suture tension. Next, simple sutures were performed to promote the greatest possible contact between the tendon and the opened bone.

The patients were instructed to keep the arm in an anatomical position, with the elbow flexed at 90 degrees in a sling, from the first to the fourth postoperative weeks. Then, they were referred for rehabilitation therapy.

Anteroposterior and lateral elbow radiographs were taken in the immediate postoperative period to control anchor placement, and they were repeated at one month and six months after surgery for the detection of heterotopic ossification (► **Figure 1A** and **1B**).

The postoperative functional assessment was performed at six months, by two physicians other than the surgeon. The tests included muscle strength measurements using a digital isometric dynamometer (Lafayette Manual Muscle Testing System 01165, Lafayette Instrument, Lafayette, IN, US)¹⁸⁻²⁰ and a specific scale (the Disabilities of the Arm, Shoulder and Hand [DASH] questionnaire),²¹ in addition to the evaluation of the injured and non-injured elbow range of motion (RoM) in flexion, extension, supination and pronation using a goniometer.

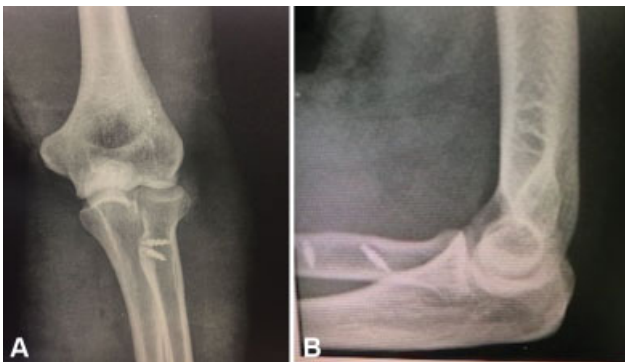


Fig. 1 Case 7, 40-year-old male patient. Postoperative radiography. (A) Anteroposterior view; (B) lateral view.

All patients were assessed for biceps brachii muscle strength with an isometric digital dynamometer¹⁸⁻²⁰ (Lafayette Instrument), which measured the maximum flexion strength with the elbow at 90 degrees of flexion and the maximum supination strength with the forearm in neutral position. To avoid bias, a reference bar was used, and all analyses were performed by the same examiner (► **Figures 2** and **3**). Four measurements in flexion and supination were performed at the injured and non-injured elbows. The measurements were performed at one-minute intervals (► **Figures 4** and **5**). The first measurement of each test was discarded, as it served as training for the patient. The other measurements were used for statistical calculations using mean values.

The postoperative functional outcomes were assessed with the DASH questionnaire,²¹ in which scores close to “0” indicate lower limitations, and, therefore, better technical and surgical results, while “100” indicates greater limitations, that is, worse results.

Postoperative complications were investigated and recorded.

Age, DASH score, complications, passive RoM, and flexion and supination strengths were analyzed descriptively with



Fig. 2 Accessory bar for the dynamometer.



Fig. 3 Digital dynamometer.

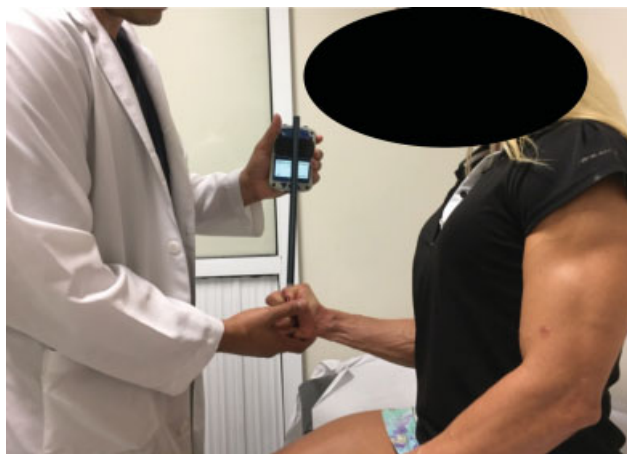

Fig. 4 Case 13, 35-year-old female patient. Supination strength test.

the Numbers (Apple Inc., Cupertino, CA, US) software. The Mann-Whitney test was used to compare the RoM in the operated and non-operated elbows, and a mixed-models test was used to compare the strength in the operated and non-operated elbows. Values of $p < 0.005$ were considered statistically significant.

Results

The average strength measured in flexed elbows was of 20.65 kgf in operated limbs, and of 22.02 kgf in non-operated limbs ($p = 0.904$); in supination, the average strength was of 2.59 kgf in operated elbows, and of 2.64 kgf in non-operated

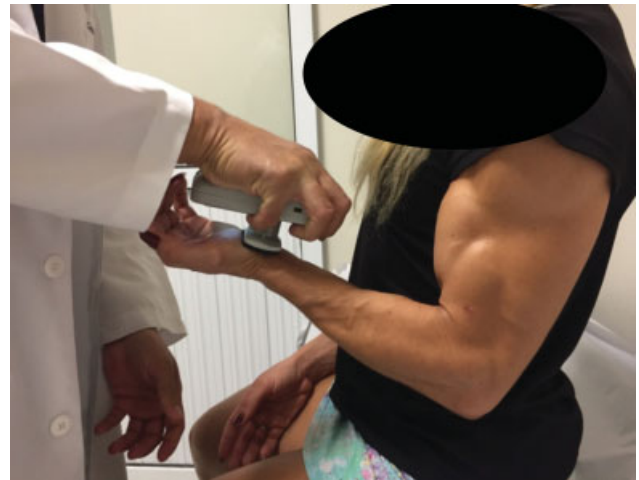

Fig. 5 Case 13, 35-year-old female patient. Flexion strength test.

elbows ($p = 0.668$). There was no significant difference between the strengths in operated and non-operated limbs.

The average active RoM in flexion was of 134.67 degrees for operated elbows, and of 136 degrees for non-operated elbows, while the average supination was of 69.47 degrees on the operated elbows and of 79.33 degrees on the non-operated elbows. These values were compared with the Mann-Whitney test, which showed no statistically significant difference ($p > 0.05$) between the operated and non-operated elbows either in flexion or supination, with respective p -values of 0.345 and 0.114 (→ **Table 1**).

Regarding dominance, there were no significant differences between the average strength and angulation in the operated and non-operated elbows during exercises regardless of whether the affected arm was dominant or not (→ **Table 2**).

The complications included a case of anchor loosening after tendon healing, detected at the six-month postoperative radiograph, which did not interfere with the surgical outcome.

One patient presented radial neurapraxia of the “high” type, that is, transient total radial nerve paralysis, with spontaneous resolution after three months.

Discussion

Our case series is consistent with worldwide findings, in which DBBT rupture is more common in the dominant limb of men between the fourth and fifth decades of life.^{3,6}

The literature describes several surgical techniques for the treatment of DBBT injury; the first of them is performed

Table 1 Comparison of range of motion in operated and non-operated elbows

Range of motion	Operated	Non-operated	p -value
Flexion	134.67	136	0.345
Supination	69.47	79.33	0.114

Table 2 Comparison of strength (average value) and range of motion (RoM) in dominant and non-dominant limbs

		Dominant limb	Non-dominant limb	p-value
Dominant injured arm n = 9	Supination	2.51	2.41	0.86
	Flexion	20.28	20.67	0.93
	RoM in Flexion	134.44	136.67	0.37
	RoM in Supination	63.33	78.89	0.20
	RoM in Pronation	72.22	75.00	1.00
Non-dominant injured arm n = 6	Supination	2.7	2.99	0.62
	Flexion	21.21	24.06	0.57
	RoM in Flexion	135	135.00	1.00
	RoM in Supination	78.67	80.00	0.37
	RoM in Pronation	75.00	73.67	1.00

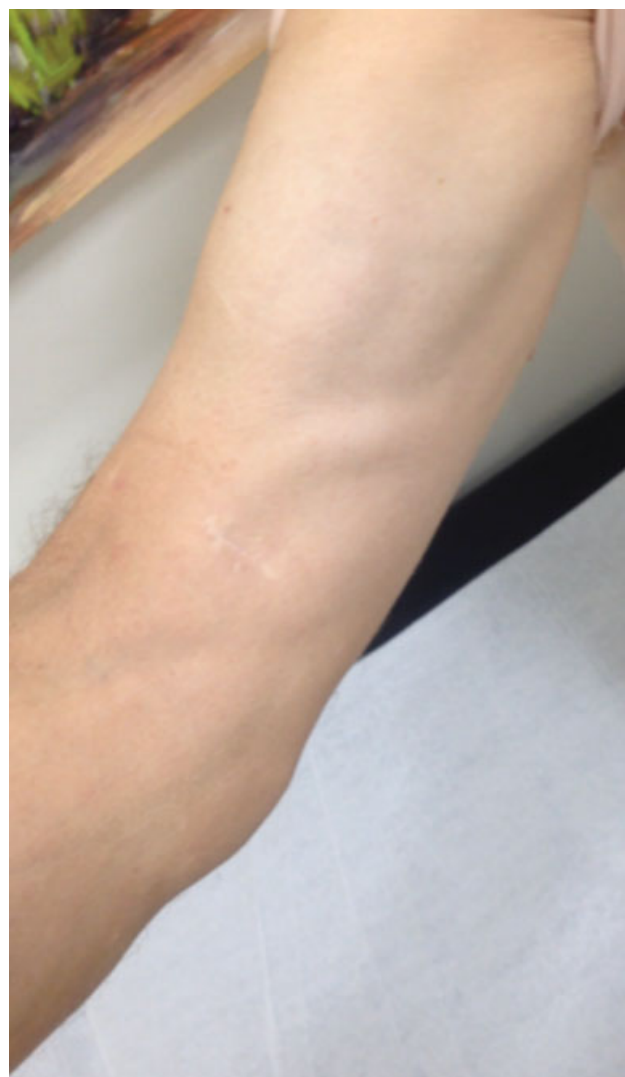through a single anterior incision across the elbow. Other more recent techniques have been described and widely used, such as double anterior incision and double mini incision. So far, there is no consensus in the literature about the superiority of any of these techniques in published clinical studies. All techniques have complications, including radial artery injury, posterior interosseous nerve injury, heterotopic ossification, or proximal radioulnar synostosis.^{2,4,6,8,12-17}

We chose to use a 4-cm forearm single anterior approach over the anterior radius tuberosity because it minimizes the dissection of soft tissue during the repair, as it does not cross syndesmosis, and provides direct access to the radial attachment site of the DBBT, enabling a more anatomical ulnar reinsertion and sparing the tuberosity.^{8,15,22,23} In addition, this technique provides good esthetic results after healing (► **Figure 6**).

Schmidt et al,⁹ in an anatomical and biomechanical study, showed that sparing the radial bicipital tuberosity has a cam effect on supination strength; the anatomical site of distal reattachment of the biceps brachii is ulnar to such tuberosity. In cadavers, the anatomical reattachment had the same biomechanical results as the intact tendon regarding supination; the worst results were obtained when reattachment was radial to the tuberosity, which is deemed non-anatomical. In this situation, compared to the anatomical reattachment, there is a 15% biomechanical strength deficit in supination with the forearm in neutral position, which increases to a 40% deficit when forearm is tested at 45 degrees of supination.¹⁰

Our patients were evaluated six months after surgery, and all participants answered the DASH questionnaire.²¹ Although the mean DASH score of 18.66 (3.3-76.6) was higher than the one reported in other studies^{6,11,14,22,23} (2.88-7.9), most patients (73%) scored as expected for a normal population.

The mean RoM of the operated elbows compared to that of the non-operated elbows showed no significant difference in flexion-extension or pronation-supination. The mean elbow flexion was of 134 degrees, which is similar to that of other studies; in addition, the average values for pronation and supination were of 73 and 69 degrees respectively, which are also close to those reported in the literature, with pronation ranging from 75 to 82 degrees, and supination ranging from

**Fig. 6** Case 8, 59-year-old male patient. Late postoperative aspect.

62 to 88 degrees.^{6,11,14,22-24} An angular deficit of up to 10 degrees for supination in relation to the contralateral limb does not compromise daily living activities for most patients, and other studies with similar techniques found an average deficit of 3 to 6.4 degrees.^{2,4,6,8-14,22-24}

According to the literature, surgical reinsertion can restore muscle function and flexion and supination strengths to values similar to those observed on non-operated limbs. Stoll and Huang² reported that the conservative treatment resulted in losses of 21% to 55% in supination strength, 79% in supination endurance, 10% to 40% in flexion strength, and 30% in flexion endurance.

Numerous implants and techniques have been used for biceps brachii tenodesis in different biomechanical assays, most commonly including metallic buttons, interference screws, anchors and transverse sutures, all exceeding the force required for DBBT rupture, which is of 204 N.¹ According to a biomechanical study by Mazzocca et al,¹ in decreasing order of pullout force (measured in N), there are the metal buttons (440 N), anchors (381 N), transosseous tunnels (310N), and interference screws (232 N). However, implants that traverse the radius, such as metal buttons, interference screw guidewires and transosseous sutures, can damage neurovascular structures as they travel through the bone. In addition, clinical studies comparing anchors with other implants have shown good outcomes with the use of anchors.^{3,8,13,15,22,24} In Brazil, anchors have been widely used in other procedures, such shoulder surgeries, as they are provided by the Brazilian Unified Health System (Sistema Único de Saúde, SUS, in Portuguese), in addition to interference screws. On the other hand, metallic buttons are not on the official list of implants offered by the SUS (Management System for the Table of Procedures, Drugs and Orthotics, Prosthetics and Special Materials, Sistema de Gerenciamento da Tabela de Procedimentos, Medicamentos e Órteses, Próteses e Materiais Especiais, SIGTAP, in Portuguese).²⁵ In October 2018, according to the SIGTAP, an interference screw was priced at BRL 486.29 and an anchor costed 197.66; therefore, anchors were the cheapest implant available at the Brazilian public health system. Despite lower costs, transosseous sutures require greater exposure and, as previously described, go through the bone, which is a drawback related to an increased risk of neurological injuries. Therefore, we decided to use anchors with tenodesis in anatomical position after scarification of an ulnar bed in the radial tuberosity, similar to the techniques of rotator cuff or proximal biceps tenodesis with anchors.

An isometric digital dynamometer was used due to its practicality and feasibility as an outpatient strength measurement instrument.¹⁸⁻²⁰ Our patients did not present significant strength differences between limbs. On average, supination and flexion strengths were restored in 98% and 94% respectively. These outcomes were considered satisfactory, since a systematic review published by Chavan et al²³ reported that a good functional outcome is the restoration of at least 80% of flexion and supination strengths, with a maximum of 30 degrees reduction in any elbow RoM (flexion, extension, supination or pronation). Regarding the recovery of the operated limb strength, the results were similar to those reported in other studies with different techniques, ranging from 80% to 95% for elbow supination, and from 90% to 95% for elbow flexion.^{2,6,8,12-14,23}

The postoperative development of heterotopic ossification was not observed in any of our patients, even though the group did not adopt a routine use of non-hormonal anti-inflammatory drugs, as this prophylaxis may increase the risk of gastrointestinal bleeding. One case of anchor release occurred during the recovery process, but it did not negatively affect objective tests results, representing a 6.6% complication rate, similar to that of studies published in the literature.^{4,8,12-15,23} Despite the careful handling of the retractors and the frequent release of radial soft tissue tension during the surgical procedure, one patient presented radial neurapraxia, with characteristics of high radial nerve motor deficit, that is, proximal to the surgical site; this injury was associated with the use of the tourniquet, and its total spontaneous resolution occurred in three months. This was not considered a direct complication of the surgical technique.

In summary, when using the anterior single approach for the anatomical repair of DBBT with anchors, a minimally-invasive and inexpensive procedure, the patients evolved well, with high satisfaction indexes and minimal loss of RoM in some cases. Thus, we have shown that this is a safe and effective technique for this type of injury.

Conclusions

The anterior single transverse forearm approach to the anatomical repair of DBBT with two anchors showed good clinical outcomes and a low complication rate. This is a technique with functional outcomes similar to those described for other methods and with minimal esthetic alteration.

Conflict of Interests

The authors have no conflict of interests to declare.

References

- Mazzocca AD, Cohen M, Berkson E, et al. The anatomy of the bicipital tuberosity and distal biceps tendon. *J Shoulder Elbow Surg* 2007;16(01):122-127
- Stoll LE, Huang JI. Surgical Treatment of Distal Biceps Ruptures. *Orthop Clin North Am* 2016;47(01):189-205
- Schmidt CC, Savoie FH 3rd, Steinmann SP, et al. Distal biceps tendon history, updates, and controversies: from the closed American Shoulder and Elbow Surgeons meeting-2015. *J Shoulder Elbow Surg* 2016;25(10):1717-1730
- Guglielmino C, Massimino P, Ioppolo F, Castorina S, Musumeci G, Di Giunta A. Single and dual incision technique for acute distal biceps rupture: clinical and functional outcomes. *Muscles Ligaments Tendons J* 2016;6(04):453-460
- Haverstock J, Athwal GS, Grewal R. Distal biceps injuries. *Hand Clin* 2015;31(04):631-640
- Giacalone F, Dutto E, Ferrero M, Bertolini M, Sard A, Pontini I. Treatment of distal biceps tendon rupture: why, when, how? Analysis of literature and our experience. *Musculoskelet Surg* 2015;99(01, Suppl 1):S67-S73
- An KN, Hui FC, Morrey BF, Linscheid RL, Chao EY. Muscles across the elbow joint: a biomechanical analysis. *J Biomech* 1981;14(10):659-669
- Dunphy TR, Hudson J, Batech M, Acevedo DC, Mirzayan R. Surgical Treatment of Distal Biceps Tendon Ruptures: An Analysis of Complications in 784 Surgical Repairs. *Am J Sports Med* 2017; 45(13):3020-3029

- 9 Schmidt CC, Brown BT, Williams BG, et al. The importance of preserving the radial tuberosity during distal biceps repair. *J Bone Joint Surg Am* 2015;97(24):2014–2023
- 10 Prud'homme-Foster M, Louati H, Pollock JW, Papp S. Proper placement of the distal biceps tendon during repair improves supination strength—a biomechanical analysis. *J Shoulder Elbow Surg* 2015;24(04):527–532
- 11 Schmidt CC, Brown BT, Sawardeker PJ, DeGravelle M Jr, Miller MC. Factors affecting supination strength after a distal biceps rupture. *J Shoulder Elbow Surg* 2014;23(01):68–75
- 12 Witkowski J, Królikowska A, Czamara A, Reichert P. Retrospective evaluation of surgical anatomical repair of distal biceps brachii tendon rupture using suture anchor fixation. *Med Sci Monit* 2017; 23:4961–4972
- 13 Waterman BR, Navarro-Figueroa L, Owens BD. Primary repair of traumatic distal biceps ruptures in a military population: clinical outcomes of single- versus 2-incision technique. *Arthroscopy* 2017; 33(09):1672–1678
- 14 Suda AJ, Prajitno J, Grützner PA, Tinelli M. Good isometric and isokinetic power restoration after distal biceps tendon repair with anchors. *Arch Orthop Trauma Surg* 2017;137(07):939–944
- 15 Maciel RA, Costa PS, Figueiredo EA, Belangero PS, Pochini AC, Ejnisman B. Acute distal biceps ruptures: single incision repair by use of suture anchors. *Rev Bras Ortop* 2017;52(02):148–153
- 16 Boyd HB, Anderson LD. A method for reinsertion of the distal biceps brachii tendon. *J Bone Joint Surg Am* 1961;43:1041–1043
- 17 Hartman MW, Merten SM, Steinmann SP. Mini-open 2-incision technique for repair of distal biceps tendon ruptures. *J Shoulder Elbow Surg* 2007;16(05):616–620
- 18 Karnofel H, Wilkinson K, Lentell G. Reliability of isokinetic muscle testing at the ankle. *J Orthop Sports Phys Ther* 1989;11(04): 150–154
- 19 Schwartz S, Cohen ME, Herbison GJ, Shah A. Relationship between two measures of upper extremity strength: manual muscle test compared to hand-held myometry. *Arch Phys Med Rehabil* 1992; 73(11):1063–1068
- 20 Reed RL, Den Hartog R, Yochum K, Pearlmutter L, Ruttinger AC, Mooradian AD. A comparison of hand-held isometric strength measurement with isokinetic muscle strength measurement in the elderly. *J Am Geriatr Soc* 1993;41(01):53–56
- 21 Orfale AG, Araújo PM, Ferraz MB, Natour J. Translation into Brazilian Portuguese, cultural adaptation and evaluation of the reliability of the Disabilities of the Arm, Shoulder and Hand Questionnaire. *Braz J Med Biol Res* 2005;38(02):293–302
- 22 Shields E, Olsen JR, Williams RB, Rouse L, Maloney M, Voloshin I. Distal biceps brachii tendon repairs: a single-incision technique using a cortical button with interference screw versus a double-incision technique using suture fixation through bone tunnels. *Am J Sports Med* 2015;43(05):1072–1076
- 23 Chavan PR, Duquin TR, Bisson LJ. Repair of the ruptured distal biceps tendon: a systematic review. *Am J Sports Med* 2008;36 (08):1618–1624
- 24 Sutton KM, Dodds SD, Ahmad CS, Sethi PM. Surgical treatment of distal biceps rupture. *J Am Acad Orthop Surg* 2010;18(03):139–148
- 25 Brasil. Ministério da Saúde;2013SIGTAP-Sistema de Gerenciamento da Tabela de Procedimentos, Medicamentos e OPM do SUS [acesso em 2018 out 14]. Disponível em: <http://sigtap.datasus.gov.br/tabela-unificada/app/seg/inicio.jsp>