

The unstable hip in children with cerebral palsy: does an acetabuloplasty add midterm stability?

Matthias W. Axt¹
Danielle L. Wadley¹

Abstract

Purpose This study addresses whether an additional pelvic procedure is superior to a varus derotation osteotomy femur (VDRO) alone in unstable hips in children with cerebral palsy (CP).

Methods All patients had unstable hips utilising the Melbourne Cerebral Palsy Hip Classification System (MCPHCS). We compared one group that underwent VDRO alone with one that had a combination of VDRO and Dega osteotomy (VDRO+). Measurements were taken before surgery, postoperatively, two years after surgery and at latest follow-up. Generalised estimating equations were used to account for known and unknown correlations between hips from bilateral cases.

Results In total, 74 hips in 57 children fulfilled the inclusion criteria. There was no outcome difference between Gross Motor Function Classification System levels III, IV and V. Age at time of operation ranged from three to 16 years (mean 9.8 years). Mean follow-up was 49.1 months. In the VDRO group (28 hips) migration percentage (MP) changed from 61% preoperative to a final value of 35.7%. In the VDRO+ group (46 hips) the MP changed from 64.4% to 19.3%. At final follow-up 15 hips (54%) were stable in the VDRO group, 37 hips (83%) in the VDRO+ group. The odds ratio (OR) of hip stability at final follow-up was 3.5-times higher in the VDRO+ group *versus* the VDRO group (OR = 3.9; 95% confidence interval = 1.5 to 9.7; $p = 0.004$).

Conclusion Reconstruction of unstable hips via VDRO + Dega in children with CP provides a higher likelihood of long-term stability than an isolated VDRO.

Level of Evidence Level III, retrospective comparative study

Cite this article: Axt MW, Wadley DL. The unstable hip in children with cerebral palsy: does an acetabuloplasty add midterm stability? *J Child Orthop* 2021;15:564-570. DOI: 10.1302/1863-2548.15.210154

¹ Orthopaedic Department at The Children's Hospital at Westmead, Westmead NSW, Sydney, Australia

Correspondence should be sent to Dr Matthias Axt, MD, Orthopaedic Department at The Children's Hospital at Westmead, Corner Hawkesbury Road and Hainsworth Street, Locked Bag 4001, Westmead NSW 2145, Sydney, Australia.
E-mail: matthias.axt@health.nsw.gov.au

Keywords: cerebral palsy; hip displacement; hip instability; hip reconstructive surgery; VDRO femur plus Dega pelvis

Introduction

Spastic hip displacement affects approximately 35% of children with severe cerebral palsy (CP).^{1,2} The risk of hip displacement is directly related to gross motor function as categorised by the Gross Motor Function Classification System (GMFCS),³ and affects most children with GMFCS levels IV (70%) and V (90%), and fewer with GMFCS level III (40%).² Subluxated hips with a Reimers' migration percentage (MP)⁴ between 30% and 60% have a 25% risk to further subluxate and hips with an MP of > 60% are very likely to dislocate regardless of the age of the patient.⁵

These children require hip stabilisation surgery to prevent advanced hip subluxation or dislocation, which would lead to sitting and resting difficulties as well as pain.

Controversy persists within the orthopaedic community as to the extent that reconstructive hip surgery is necessary. Some surgeons perform a varus derotation osteotomy (VDRO) of the femur, but do not address the acetabulum, which is almost always dysplastic, or use a 'sequential approach'.⁶ Increased procedure time, additional blood loss and thus potentially increased morbidity have also been arguments against additional pelvic procedures.⁷

This retrospective comparative study aims to determine whether a VDRO plus pelvic osteotomy is justified over a VDRO alone to stabilise and maintain stability of the unstable hip in children with CP.

Materials and methods

The study was conducted at our tertiary centre, The Children's Hospital at Westmead, Sydney, Australia, from medical records and radiographs. Approval had been obtained from the hospital's Human Research Ethics Committee. All personal data were de-identified for the purpose of the study. For the study conduct and the preparation of the manuscript no funding has been received. There is no conflict of interest to declare.

The children underwent surgery between 1st June 2005 and 14th April 2011. The minimum observation period following surgery was two years.

Only children with unilateral or bilateral unstable hips at the time of hip reconstruction surgery were included

in this study. Hip instability was defined as grade IV and higher in the Melbourne Cerebral Palsy Hip Classification System (MCPHCS),⁸ which delineates an unstable hip, liable to progressive displacement and symptomatic deterioration with time, having an MP > 30%, a broken Shenton's line by > 5 mm and variable head or acetabular deformity.

Children who had previous bony surgery to the hips were excluded from the study, however, children who had previous or simultaneous anterior/medial hip release were included.

Surgery was performed by two senior surgeons. The extent of the operation (VDRO alone or VDRO/Dega combined) was determined by the surgeon's preference and influenced by the child's health: three children had no Dega osteotomy to allow early weight-bearing, in eight children co-morbidities precluded a pelvic osteotomy in the same session and four children had a Dega osteotomy on only one (the worse) side for the same reason as mentioned above. For the remaining six children the surgeon decided against a Dega osteotomy to limit surgical time and blood loss. The goals of surgery were long-term hip stability for ease of care, comfortable positioning in the wheelchair and bed and freedom from pain.

For the VDRO in children with GMFCS IV and V both surgeons aimed for a neck-shaft-angle of 110° to 115° and 0° to 10° of femoral antetorsion.

Before or concomitant to bony hip surgery children had bilateral hip adductor release and anterior hip release. Hip adductors were released consecutively until a minimum of 45° hip abduction was achieved in hip flexion and a minimum of 30° abduction in hip extension: adductor longus followed by gracilis, adductor brevis and adductor magnus. Children who were able to walk (GMFCS III) had a psoas muscle recession at or over the pelvic brim, children with GMFCS IV/V had an iliopsoas tendon release at the lesser trochanter.

If a hip was subluxated or dislocated and concentric relocation could not be achieved in a closed fashion, open hip reduction was performed.

Radiographs of the pelvis were taken prior to hip reconstruction, directly thereafter, two years after surgery and at the latest follow-up. The pelvic views were performed in an anteroposterior fashion with the patient lying supine, legs in neutral abduction and neutral hip rotation, i.e. patellae facing the ceiling. Parents may have assisted to obtain the standard position. Since children with CP frequently have hip flexion contractures leading to an anterior pelvic tilt, they were positioned with their hips and knees flexed to 30° on a foam block. This position promotes correct measurements of the pelvic indices and maintains hips in neutral rotation and symmetrical/neutral abduction.

We used the following quantifiable radiographical indices: Reimers' MP delineates the percentage of the width

of the femoral head lateral to Perkin's line (a perpendicular line to Hilgenreiner's line passing through the lateral edge of the acetabulum). MP is considered the most reliable measurement to quantify femoral head migration in children with CP.^{2,4,5} For this study a value > 30% was considered pathological.

Since the concavity of the acetabulum develops in response to the presence of the spherical femoral head as a precondition of concentric hip development,⁹ we measured acetabular dysplasia using Hilgenreiner's Acetabular Index (AI)¹⁰ and Wiberg's Centre Edge Angle (CEA).¹¹

AI as a measure to evaluate acetabular dysplasia has been generally accepted.¹² It describes the angle between Hilgenreiner's line and a line connecting the lateral edge of the acetabulum and the most medial point of the ilium adjacent to the tri-radiate cartilage (norm: age three years = ~ 15°, at 15 years < 10°).¹³ Considering the age range of the study group (three to 16 years), 15° was chosen as a cut-off.

CEA is used extensively in the Anglo-American and Scandinavian literature to evaluate therapeutic results.¹⁴ CEA is the angle between a vertical line on Hilgenreiner's line, running through the centre of the femoral head, and a line connecting the centre of the femoral head with the lateral edge of the acetabulum (norm: four to 13 years > 20°, > 14 years > 25°).^{11,15} The centre of the femoral head is determined by using the circle tool in the Siemens imaging software Syngo (Syngo.via, Siemens Healthcare GmbH, Erlangen, Germany) of the femoral head. Considering the age range of the study group, values < 20° were considered pathological.

Measurements were performed by the authors. The junior co-author (DLW) had been trained to measure radiological indices used in this paper by the senior author (MWA). The senior author has many years of experience in measuring radiological indices of the pelvis in children and was co-author of an inter-rater reliability study for Reimers' MP.¹⁶

Measurements were taken before and after hip reconstructive surgery, two years thereafter and at the last radiograph within the observation period. Radiographs were viewed through the hospital's Picture Archiving and Communication System (PACS, Siemens Healthcare GmbH, Erlangen, Germany) and measurements performed via the Siemens Syngo digital tool set. The centre of the femoral head was determined through the circle tool.

The surgeon's volume of hip surgery has been described as a predictor for a successful outcome.¹⁷ Both surgeons involved performed approximately 25 hip reconstructions per year (one of the surgeons also at another institution). The senior author of this study (MWA) performed most of the Dega osteotomies, between ten and 25 per year in combination with a VDRO. The other surgeon did ten or more VDROs per year.

Table 1 Demographic data related to type of hip surgery

Procedure	Patients, n	Hips, n	Sex, male	Sex, female	Mean age, yrs (sd)	GMFCS III, hips	GMFCS IV, hips	GMFCS V, hips	Mean follow-up, mths (sd)
VDRO	21	28	10	7	10.5 (2.1)	5	4	12	
VDRO +	39	46	20	20	9.5 (3.5)	3	11	25	49.1 (19.9)

GMFCS, Gross Motor Function Classification System; VDRO, varus derotation osteotomy femur; VDRO +, varus derotation osteotomy femur plus Dega osteotomy pelvis

Statistics

All statistical analyses were performed using SAS Version 9.3 and 9.4 (SAS Inc., Cary, NC, USA). Categorical variables were summarised with frequencies and percentages, continuous variables were summarised by median and inter-quartile range or mean and SD.

To account for correlations between hips in bilateral cases and repeated observations of the same subject over time, generalised estimating equations (GEE) were used to assess the effects of clinical and patient factors on the outcomes of MP, CEA and AI being stable and/or within normal range, assuming a binominal distribution for the outcomes and an exchangeable correlation structure. GEE was also used to account for differences in patients' GMFCS.

Fraction of a year and months is depicted in decimals.

Results

During the observation period (2005 to 2013) 60 children/77 hips fulfilled MCPHCS grade IV and V hip instability prior to surgery.⁸ In addition, hip stability indices like MP, AI and CEA were collected. Three hips (three children) were removed later from the study: one hip had a severe anterior subluxation, which could not be classified correctly in an anteroposterior pelvic radiograph, one hip had been treated with VDRO and a modified Salter osteotomy. One patient did not meet the two-year observation period.

In total, 74 hips in 57 children (27 female, 30 male) fulfilled the inclusion criteria. In all, 14 children underwent bilateral hip reconstruction in the same session. Three children, who underwent unilateral hip reconstruction initially, subsequently had contralateral hip surgery later, due to either initial contralateral hip stability at the time of primary procedure or poor health precluding bilateral surgery under a single anaesthetic.

Seven children were GMFCS level III, 13 were GMFCS level IV and 37 were GMFCS level V. There was no statistically relevant outcome difference between GMFCS levels. Excluding patients with GMFCS level III did not influence outcome measures.

Children were divided into two groups: group 1 consisted of children who had a VDRO only (28 hips) and group 2 represented children who had a VDRO combined with an ipsilateral Dega osteotomy (VDRO+), 46 hips. In the VDRO group, 12 children were GMFCS level V, four

Table 2 Mean radiological results: comparison between varus derotation osteotomy femur (VDRO) and VDRO plus Dega osteotomy pelvis (VDRO+) groups

Procedure	Hips, n	MP, % (sd)	AI, ° (sd)	CEA, ° (sd)
VDRO				
Preoperative	28	61.0 (26.2)	28.0 (7.9)	- 5.6 (27.3)
Postoperative	28	30.3 (14.2)	28.0 (7.6)	10.5 (13.6)
Two-yr follow-up	28	34.4 (17.3)	22.6 (7.5)	11.2 (22.6)
Final follow-up	19	35.7 (23.3)	21.6 (7.9)	10.1 (24.9)
VDRO +				
Preoperative	46	64.8 (18.5)	30.5 (6.2)	- 16.3 (22.6)
Postoperative	46	12.8 (13.2)	19.5 (6.7)	19.6 (7.7)
Two-yr follow-up	46	20.8 (14.4)	17.8 (6.4)	21.0 (10.1)
Final follow-up	34	19.3 (14.0)	16.9 (7.1)	23.4 (10.1)

MP, Reimers' migration percentage; AI, Hilgenreiner's Acetabular Index; CEA, Wiberg's Centre Edge Angle; VDRO, varus derotation osteotomy femur, VDRO +, varus derotation osteotomy femur plus Dega osteotomy pelvis

were GMFCS level IV and five were GMFCS level III. In the VDRO+ group 25 children were GMFCS level V, 11 were GMFCS level IV and three were GMFCS level III. Age at time of operation ranged from three to 16 years (9.8 years (SD 3.2)). Mean follow-up was 49.1 months (SD 19.9). Demographic data are presented in Table 1.

At final follow-up the VDRO group dropped to 19 hips, the VDRO+ group to 34 hips. The mean final follow-up period (after the minimum of 24 months) was 28 months (SD 18.5). Radiological results for MP, AI and CEA are shown in Table 2.

Considering homogeneity of the VDRO and VDRO+ groups, we only included GMFCS levels III to V. Hips in both groups were MCPHCS grade IV and V and had similar mean MP (VDRO = 61.0% (SD 26.2) versus VDRO+ = 64.8% (SD 18.5)) and mean AI (VDRO = 28.0° (SD 7.9°) versus VDRO+ = 30.5° (SD 6.2°)). Mean CEA was more pathological in the VDRO+ group (-16.3° (SD 22.6°)) compared with the VDRO group (-5.6° (SD 27.3°)) (Table 2).

There was no evidence that characteristics differed between the two groups of surgery: age (p = 0.10), sex (p = 0.23), GMFCS level (p = 0.13), MP (p = 0.56), CEA (p = 0.13) and AI (p = 0.20).

There was no statistically relevant correlation between hips in the same patient (r = -0.046), nor for left versus right hips, nor for unilateral versus bilateral cases. Therefore, outcomes of individual hips are depicted.

With MP being the main indicator for hip stability, at two years postoperatively, 13 hips (46%) were stable in the VDRO group, 36 (78%) were stable in the VDRO+ group. At final follow-up ten hips (53%) were stable in the

VDRO group and 30 hips (88%) were stable in the VDRO+ group.

For AI, at the two-year postoperative interval, four hips (14%) were normal in the VDRO group and 16 (35%) were normal in the VDRO+ group. At final follow-up two hips (11%) were normal in the VDRO group and 15 hips (44%) were normal in the VDRO+ group.

For CEA, at two years postoperatively, eight hips (29%) had normal values in the VDRO group and 23 hips (50%) were normal in the VDRO+ group. At final follow-up five hips (26%) were normal in the VDRO group and 19 hips (56%) were normal in the VDRO+ group.

Figures 1, 2 and 3 show group comparison graphs of the mean radiological results for MP, AI and CEA over time.

The odds ratio (OR), as determined by MP, of being stable at two years postoperative was four-times higher in the VDRO+ group *versus* VDRO alone (OR = 4.2; 95% confidence interval (CI) = 1.8 to 9.9; p = 0.001).

The odds of being stable at final follow-up were 3.5-times higher in the VDRO+ group *versus* the VDRO group (OR = 3.9; 95% CI = 1.5 to 9.7; p = 0.004), (Fig. 4).

In general, differences between groups after surgery were maintained for MP and CEA without significant changes over time (MP: p = 0.4931; AI: p = 0.0091; CEA: p = 0.0569). For AI, changes between groups narrowed (p = 0.0091).

Discussion

To achieve the most meaningful results we examined surgical outcomes in hips of children with CP with defined criteria of instability and the likelihood of further deterioration without surgical intervention.

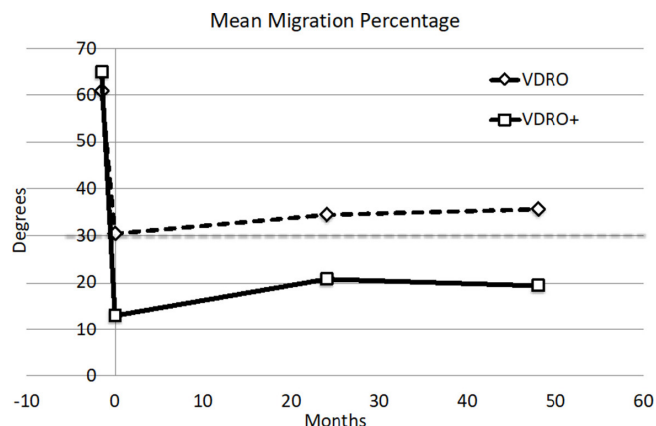


Fig. 1 Mean migration percentage values for varus derotation osteotomy femur (VDRO) and VDRO plus Dega osteotomy pelvis (VDRO+) groups preoperatively, immediately after surgery, two years postoperatively and at final review. In the VDRO+ group the mean MP remains below 30% (values > 30% are considered pathological as depicted by the grey dotted line).

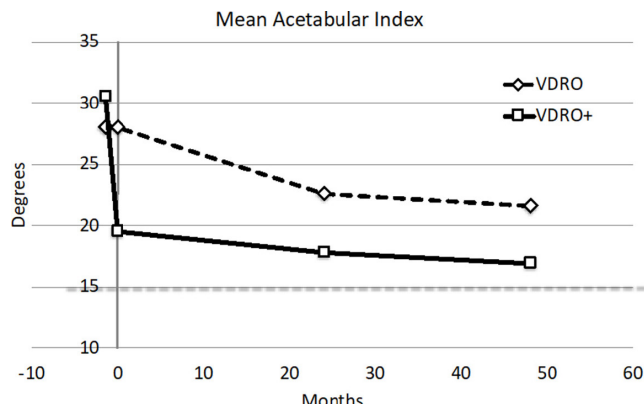


Fig. 2 Mean Acetabular Index values for varus derotation osteotomy femur (VDRO) and VDRO plus Dega osteotomy pelvis (VDRO+) groups preoperatively, immediately after surgery, two years postoperatively and at final review. In both groups the postoperative values are not within normal limits for the age group, defined as < 15°, depicted by the grey dotted line, however, the VDRO+ group comes close to normal values towards the end of the observation period.

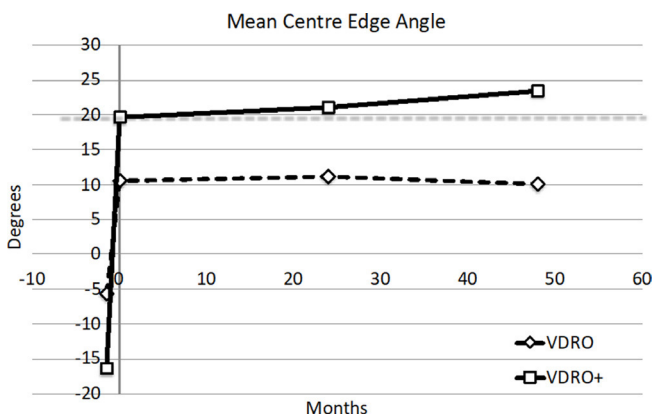


Fig. 3 Mean Centre Edge Angle values for varus derotation osteotomy femur (VDRO) and VDRO plus Dega osteotomy pelvis (VDRO+) groups preoperatively, immediately after surgery, two years postoperatively and at final review. In the VDRO group the postoperative values remain pathological, defined as < 20° for the age group, as depicted by the grey dotted line, whereas in the VDRO+ group values are not within the pathological range following surgery.

The definition of hip instability has been difficult to determine. Reimers' MP, most widely used for hip instability in CP, has often been utilised for lack of femoral head coverage, but not necessarily lateral migration, for which it was designed. Lack of acetabular coverage, which should be defined as acetabular dysplasia, would be better expressed via CEA. Although some authors, like Miller,¹⁸ do not regard the CEA a good measure for 'spastic hip disease', it does support an overall aspect of hip stability and adds valuable information associated with acute changes of the CEA after pelvic osteotomies. Using the circle tool in the Siemens Syngo software helps

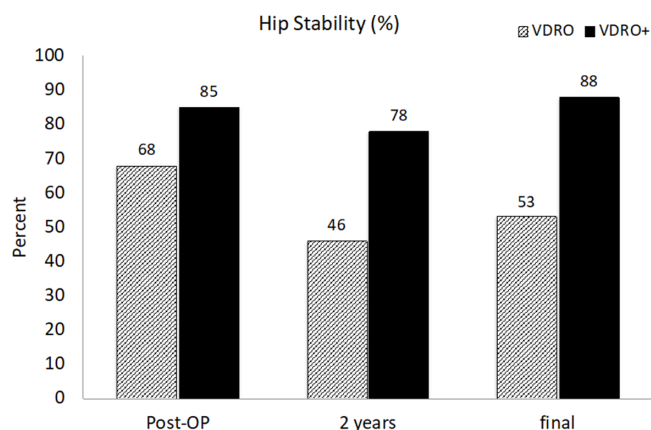


Fig. 4 Hip stability: with MP being the main indicator for hips stability, at two years postoperatively 13 hips (46%) were stable in the varus derotation osteotomy femur (VDR0) group, 36 hips (78%) were stable in the VDR0 plus Dega osteotomy pelvis (VDR0+) group. At final follow-up ten hips (53%) were stable in the VDR0 group whereas 34 hips (88%) were stable in the VDR0+ group.

define the otherwise difficult to determine femoral head centre, as described by Tönnis,¹⁴ one of Miller's points of criticism.⁵ Associated with the CEA is AI, with well-documented development with growth throughout childhood into adulthood.¹³ AI has been labelled a powerful predictor for hip displacement in CP¹⁹ and has been used to describe the natural history of hip development in CP by Terjesen.²⁰

An increase of the AI is typically associated with an increase of the MP, leading to acetabular changes, with the corner blunted and turned upwards, resulting in a type 2 sourcil in most children.²¹ Therefore, we justify the use of all three described indices to complement the appearance of a normal hip.

An MP of > 30% has been largely accepted as a definition of an unstable hip in children with CP and higher values delineate a high risk of disease progression,^{2,4,5,22} although Miller regards the threshold for reconstructive hip surgery at an MP > 40% in his most recent publication.²³ To define hip instability as an indication for hip reconstructive surgery we utilised grade IV and V of the MCPHCS.⁸

The MCPHCS, which includes Reimers' MP, is a categorical scale which was developed to enclose the full spectrum of hip morphology in children with CP. Its relevance was initially limited to patients at or close to skeletal maturity. In their study, Gose et al²⁴ validated the MCPHCS for children aged two to seven years. Therefore, the MCPHCS was the preferred choice for our study.

MP alone may not be an ideal predictor for hip instability. MP has been commonly used, including at our institution, for true lateral migration as well as acetabular dysplasia/a short acetabulum, and it is our observation that true lateral migration has a higher risk of hip displacement progression than acetabular dysplasia alone.

The management goal of stable and pain free hips in children with severe CP, predominantly GMFCS level IV and V, via hip reconstructive surgery, to allow comfortable positioning in the wheelchair and bed, has been widely accepted.^{25,26}

Although soft-tissue surgery alone has been reported to achieve reasonable mid-term hip stability in a heterogeneous population,²⁷ the overall impact of such surgery alone is still not well understood, since the motor type alone, like spasticity, does not seem to predict hip displacement.^{17,25} On the contrary, 80% of 242 children GMFCS level IV and V, had subsequent hip reconstructive surgery after adductor release, reported by Shore et al.¹

To date it still remains unclear whether a pelvic osteotomy is required in all non-ambulatory children with CP.^{28,29} Oh et al²⁹ were unable to recommend an additional pelvic procedure, perhaps due to the lower MP in the femoral osteotomy group.

Shore et al¹⁷ found no difference in the need for revision hip surgery if concomitant pelvic osteotomy was performed at the time of a VDR0 or not. Including all GMFCS levels, their strongest predictor for surgical success was the GMFCS level (the lower the better), age of the patient and the surgeon's experience.

Pelvic procedures in conjunction with a VDR0 may not be considered by some surgeons for this group of children because of complex co-morbidities like epilepsy and respiratory disease. Concomitant pelvic procedures also may increase overall blood loss, raise postoperative complications and prolong recovery.⁷

Huh et al⁶ did not propose a clear recommendation in regards to additional pelvic procedures. They included GMFCS level II, where the focus was less likely in hip reconstruction, but rather in rotational deformities. Starting at a higher MP in the VDR0+ group preoperatively, their final postoperative MPs were similar in both groups (MP > 30%: VDR0 group 33%, VDR0+ group 38%), thus inconclusive for recommendations.

Why can't a satisfactory hip reduction be achieved by a VDR0 only? A VDR0 alone has a small impact on lateral femoral head displacement towards the acetabular rim and, therefore, achieves improvement of the 'true' lateral migration, as well as CEA, by directing mechanical forces within the acetabulum towards its medial wall. In most cases, however, we observe a combination of true lateral migration of the femoral head and a short acetabulum/acetabular dysplasia. Therefore, only the immediate intraoperative anatomical acetabular changes, achieved by a (Dega) pelvic osteotomy, thereby improving MP, AI and CEA in combination, allow satisfactory coverage of the femoral head.

Other authors have supported a combined approach of VDR0 femur and pelvic osteotomy: Song and Carroll,³⁰ whilst reviewing a more heterogeneous group of patients, including diplegia, hemiplegia and quadriplegia, found a higher rate of re-subluxation and re-dislocation in the VDR0 group.

Al-Ghadir et al⁷ found a lower revision surgery rate in the VDRO+ group, however the age in the VDRO group was much lower than in the combined group.

Minaie et al,³¹ in their comprehensive retrospective review about failure rates of hip reconstructive surgery, concluded that concomitant acetabular osteotomies may protect from failure. Conclusions drawn from the study in regards to the low overall failure rate of 13.1% may be regarded with caution, considering the large age range (one to 18 years) at the time of surgery and the inclusion of GMFCS levels I and II, where the focus typically lies on correcting rotational deformities.

Some authors^{31,32} found a relationship between age and recurrent hip instability with higher failure risks at a younger age. Brunner and Baumann³² recommended hip reconstructive surgery after the age of four years and ideally a delay on surgery until the age of eight years to reduce the risk of valgus remodelling of the femur following varising osteotomy. Noonan et al³³, however, found better outcomes in younger children, relating the higher failure rate in older children to their higher hip displacement characteristics and the greater remodelling potential in younger children.

Finally, it is interesting to see that AI (thus acetabular coverage), improved in our VDRO group over time from 28° to 23° within two years after surgery (whilst not reaching a normal value). This may be explained by the maturation and ossification of the acetabular ring apophysis during adolescence.^{34,35}

Conclusion

This study, which uses MCPHCS, grade IV and V, as a definition of an unstable hip in children with CP, provides evidence of more reliable outcomes if a femoral VDRO is combined with a pelvic osteotomy. This surgical combination may have a higher likelihood of achieving longer term hip stability, ideally reducing the risk of revision surgery in this fragile group of patients and is, therefore, recommended for hip grades IV and V MCPHCS.

Received 31 August 2021; accepted after revision 02 November 2021.

COMPLIANCE WITH ETHICAL STANDARDS

FUNDING STATEMENT

No benefits in any form have been received or will be received from a commercial party related directly or indirectly to the subject of this article.

OA LICENCE TEXT

This article is distributed under the terms of the Creative Commons Attribution-Non Commercial 4.0 International (CC BY-NC 4.0) licence (<https://creativecommons.org/licenses/by-nc/4.0/>) which permits non-commercial use, reproduction and distribution of the work without further permission provided the original work is attributed.

ETHICAL STATEMENT

Ethical approval: All procedures performed in studies involving human participants were in accordance with the ethical standards of the institutional and/or national research committee and with the 1964 Helsinki declaration and its later amendments or comparable ethical standards.

Ethics approval was granted for this work by the Sydney Children's Network Human Research Ethics Committee (HREC) on 29 April 2013, Project No. LNR/13/SCHN/101 as a retrospective study without contact to patients, guardians (parents) or other family members.

Informed consent: Informed consent has not been obtained in this retrospective study. It was waived by the institution's HREC. All data were de-identified.

ICMJE CONFLICT OF INTEREST STATEMENT

The authors have no conflicts of interest to declare.

ACKNOWLEDGEMENTS

We would like to acknowledge the following persons for their contributions to the manuscript: Joan Tornquist, Orthopaedic Department at the Children's Hospital at Westmead, for reviewing and proofreading the manuscript; Elizabeth Barnes, statistician at the Kid's Research Institute/Children's Hospital at Westmead, for performing the statistics free of charge.

AUTHOR CONTRIBUTIONS

MWA: Formulated study design, contributed significantly to data acquisition, data analysis, interpretation of data, drafting and critical revision of the manuscript.

DLW: Contributed significantly to data acquisition, data analysis, interpretation of data, drafting and critical revision of the manuscript.

REFERENCES

1. Shore BJ, Yu X, Desai S, et al. Adductor surgery to prevent hip displacement in children with cerebral palsy: the predictive role of the Gross Motor Function Classification System. *J Bone Joint Surg Am* 2012;94-A:326-334.
2. Soo B, Howard JJ, Boyd RN, et al. Hip displacement in cerebral palsy. *J Bone Joint Surg Am* 2006;88-A:121-129.
3. Palisano R, Rosenbaum P, Walter S, Russell D, Wood E, Galuppi B. Development and reliability of a system to classify gross motor function in children with cerebral palsy. *Dev Med Child Neurol* 1997;39:214-223.
4. Reimers J. The stability of the hip in children. A radiological study of the results of muscle surgery in cerebral palsy. *Acta Orthop Scand Suppl* 1980;184:1-100.
5. Miller F, Bagg MR. Age and migration percentage as risk factors for progression in spastic hip disease. *Dev Med Child Neurol* 1995;37:449-455.
6. Huh K, Rethlefsen SA, Wren TAL, Kay RM. Surgical management of hip subluxation and dislocation in children with cerebral palsy: isolated VDRO or combined surgery? *J Pediatr Orthop* 2011;31:858-863.
7. Al-Ghadir M, Masquijo JJ, Guerra LA, Willis B. Combined femoral and pelvic osteotomies versus femoral osteotomy alone in the treatment of hip dysplasia in children with cerebral palsy. *J Pediatr Orthop* 2009;29:779-783.
8. Robin J, Graham HK, Baker R, et al. A classification system for hip disease in cerebral palsy. *Dev Med Child Neurol* 2009;51:183-192.
9. Weinstein SL. Natural history of congenital hip dislocation (CDH) and hip dysplasia. *Clin Orthop Relat Res* 1987;225:62-76.

10. **Hilgenreiner H.** Zur Frühdiagnose und Frühbehandlung der angeborenen Hüftgelenksverrenkung. *Med Klin* 1925;21:1385-1425.
11. **Wiberg G.** Studies on dysplastic acetabula and congenital subluxation of the hip joint with special references to the complication of osteoarthritis. *Acta Chir Scand Suppl* 1939;58:1-135.
12. **Spiegel DA, Flynn JM.** Evaluation and treatment of hip dysplasia in cerebral palsy. *Orthop Clin North Am* 2006;37:185-196, vi.
13. **Tönnis D.** Normal values of the hip joint for the evaluation of X-rays in children and adults. *Clin Orthop Relat Res* 1976;119:39-47.
14. **Tönnis D.** *Congenital dysplasia and dislocation of the hip in children and adults.* Berlin, Heidelberg, New York, London, Paris: Springer, 1987:121.
15. **Werner CML, Ramseier LE, Ruckstuhl T, et al.** Normal values of Wiberg's lateral center-edge angle and Lequesne's acetabular index—a coxometric update. *Skeletal Radiol* 2012;41:1273-1278.
16. **Paget S, Axt M, Waugh M.** Reliability of multidisciplinary rehabilitation team assessment of Reimers' migration percentage for cerebral palsy hip subluxation. *Dev Med Child Neurol* 2012;54(suppl 5):75-93.
17. **Shore BJ, Zurakowski D, Dufreny C, et al.** Proximal femoral varus derotation osteotomy in children with cerebral palsy: the effect of age, gross motor function classification system level, and surgeon volume on surgical success. *J Bone Joint Surg Am* 2015;97-A:2024-2031.
18. **Miller F.** *Cerebral palsy.* New York: Springer-Verlag, 2005:530.
19. **Cooke PH, Cole WG, Carey RPL.** Dislocation of the hip in cerebral palsy. Natural history and predictability. *J Bone Joint Surg Br* 1989;71-B:441-446.
20. **Terjesen T.** The natural history of hip development in cerebral palsy. *Dev Med Child Neurol* 2012;54:951-957.
21. **Flynn JM, Miller F.** Management of hip disorders in patients with cerebral palsy. *J Am Acad Orthop Surg* 2002;10:198-209.
22. **Scrutton D, Baird G, Smeeton N.** Hip dysplasia in bilateral cerebral palsy: incidence and natural history in children aged 18 months to 5 years. *Dev Med Child Neurol* 2001;43:586-600.
23. **Hosseinzadeh P, Baldwin K, Minaie A, Miller F.** Management of hip disorders in patients with cerebral palsy. *JBJS Rev* 2020;8:e0148.
24. **Gose S, Sakai T, Shibata T, et al.** Verification of the Robin and Graham classification system of hip disease in cerebral palsy using three-dimensional computed tomography. *Dev Med Child Neurol* 2011;53:1107-1112.
25. **Shore BJ, Graham HK.** Management of moderate to severe hip displacement in nonambulatory children with cerebral palsy. *JBJS Rev* 2017;5:e4.
26. **Mubarak SJ, Valencia FG, Wenger DR.** One-stage correction of the spastic dislocated hip. Use of pericapsular acetabuloplasty to improve coverage. *J Bone Joint Surg Am* 1992;74-A:1347-1357.
27. **Presedo A, Oh CW, Dabney KW, Miller F.** Soft-tissue releases to treat spastic hip subluxation in children with cerebral palsy. *J Bone Joint Surg Am* 2005;87-A:832-841.
28. **Settecerri JJ, Karol LA.** Effectiveness of femoral varus osteotomy in patients with cerebral palsy. *J Pediatr Orthop* 2000;20:776-780.
29. **Oh CW, Presedo A, Dabney KW, Miller F.** Factors affecting femoral varus osteotomy in cerebral palsy: a long-term result over 10 years. *J Pediatr Orthop B* 2007;16:23-30.
30. **Song HR, Carroll NC.** Femoral varus derotation osteotomy with or without acetabuloplasty for unstable hips in cerebral palsy. *J Pediatr Orthop* 1998;18:62-68.
31. **Minaie A, Gordon JE, Schoenecker P, Hosseinzadeh P.** Failure of hip reconstruction in children with cerebral palsy: what are the risk factors? *J Pediatr Orthop* 2021. (Epub ahead of print).
32. **Brunner R, Baumann JU.** Long-term effects of intertrochanteric varus-derotation osteotomy on femur and acetabulum in spastic cerebral palsy: an 11- to 18-year follow-up study. *J Pediatr Orthop* 1997;17:585-591.
33. **Noonan KJ, Walker TL, Kayes KJ, Feinberg J.** Varus derotation osteotomy for the treatment of hip subluxation and dislocation in cerebral palsy: statistical analysis in 73 hips. *J Pediatr Orthop B* 2001;10:279-286.
34. **Ponseti IV.** Growth and development of the acetabulum in the normal child. Anatomical, histological, and roentgenographic studies. *J Bone Joint Surg Am* 1978;60-A:575-585.
35. **Portinaro NM, Murray DW, Benson MKD.** Microanatomy of the acetabular cavity and its relation to growth. *J Bone Joint Surg Br* 2001;83-B:377-383.