



A Novel Mutation in the *MBTPS2* Gene Resulting in Ichthyosis Follicularis, Atrichia, and Photophobia Syndrome

Jun-Oh Shin^{1,2}, Dongyoung Roh^{1,2}, Kihyuk Shin¹, Woo-Il Kim^{1,2}, Min-Young Yang¹, Won-Ku Lee^{1,2}, Hoon-Soo Kim¹, Byung-Soo Kim¹, Moon-Bum Kim¹, Hyun-Chang Ko^{1,2,3}

¹Department of Dermatology, School of Medicine, Pusan National University, Busan, ²Department of Dermatology, Pusan National University Yangsan Hospital, ³Research Institute for Convergence of Biomedical Science and Technology, Pusan National University Yangsan Hospital, Yangsan, Korea

Received May 7, 2020
Revised June 24, 2020
Accepted July 13, 2020

Corresponding Author

Hyun-Chang Ko
Department of Dermatology, Pusan National University Yangsan Hospital, 20 Geumo-ro, Mulgeum-eup, Yangsan 50612, Korea
Tel: +82-55-360-1678
Fax: +82-55-360-1679
E-mail: hcko@pusan.ac.kr
<https://orcid.org/0000-0002-3459-5474>

Ichthyosis follicularis, atrichia, and photophobia (IFAP) syndrome is a rare genetic disorder caused by mutations in the *MBTPS2* gene. It is characterized by ichthyosis and alopecia from birth. Photophobia may be present in infancy or early childhood. Its mode of inheritance is X-linked recessive; thus, it mostly affects male. The disease severity varies, ranging from mild cases limited to the skin to the severe variant involving multiple extracutaneous features. A 7-year-old boy presented with scanty hair on scalp and eyebrows at birth. On physical examination, scaly patches were observed on the whole body and spiky follicular hyperkeratotic papules were observed on the face and trunk. He also suffered from severe photophobia. Histopathological examination of the scalp showed miniaturized hair follicles without perifollicular fibrosis. Genetic analysis revealed a novel mutation in the *MBTPS2* gene which was a homozygous missense mutation of c.245T>C leading to an amino-acid substitution from phenylalanine to serine (p.Phe82Ser). We diagnosed this patient with IFAP syndrome. To date, 25 pathogenic *MBTPS2* gene mutations have been identified. To our knowledge, c.245T>C is a novel homozygous missense mutation in the *MBTPS2* gene, which has not been reported in Human Gene Mutation Database, ClinVar Database, and Leiden Open Variation Database. Previous reports suggested genotype-phenotype correlations in the *MBTPS2* gene mutations. Supported by a previous notion that genotype correlates with phenotype, this novel mutation can be a predictive factor for the mild form of IFAP syndrome, restricted to the classic symptom triad.

Keywords: Alopecia, Ichthyosis, Missense mutation, Photophobia

INTRODUCTION

Ichthyosis follicularis, atrichia, and photophobia (IFAP) syndrome is a rare X-linked recessive genetic disorder caused by mutations in the membrane-bound transcription factor peptidase, site 2 (*MBTPS2*) gene¹. It is characterized by the triad of ichthyosis, manifesting as thorn-like projections of non-inflammatory follicular hyperkeratosis, total or subtotal atrichia from birth or shortly thereafter, and photophobia of varying degrees². The disease severity varies, ranging from mild cases limited to the skin to the severe BRESHECK

variant involving multiple extracutaneous features (brain anomalies, retardation, ectodermal dysplasia, skeletal deformities, Hirschsprung's disease, ear/eye anomalies, cleft palate/cryptorchidism, and kidney dysplasia/hypoplasia)³. To date, approximately 25 different pathogenic *MBTPS2* mutations have been identified. Here, we report a case of IFAP syndrome resulting from a novel missense *MBTPS2* mutation. We diagnosed this patient with IFAP syndrome.



CASE REPORT

A 7-year-old boy presented with alopecia and persistent ichthyosis from birth. His mother recalled that he congenitally showed scanty scalp hair and eyebrows with generalized dryness and roughness of whole-body skin. The boy was born at 39 weeks by normal vaginal delivery and weighed 2.75 kg at

birth. He visited our dermatology clinic at 17 months of age for the first time. At that time, he showed almost complete absence of scalp hair and eyebrows (Fig. 1A, B). A few hair follicles with short vellus hair were observed on dermoscopic examination (Fig. 1C). At the age of seven, he came back to our clinic because of persistent alopecia and rough skin. He showed total alopecia of scalp and eyebrows (Fig. 1D, E). Hair

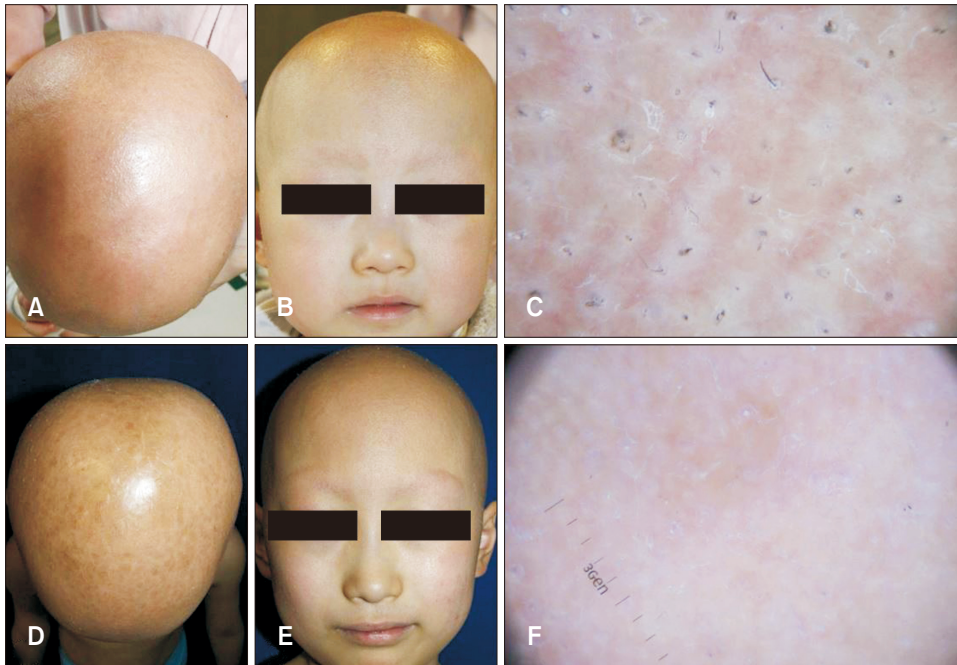


Fig. 1. Complete loss of scalp hair (A) and eyebrows (B) was observed during the first visit (17-month-old). (C) A few hair follicles with short vellus hairs were shown on dermoscopy. At the age of seven, he showed total alopecia of the scalp (D) and eyebrows (E). (F) Hair follicles were almost absent as suggested during dermoscopy.

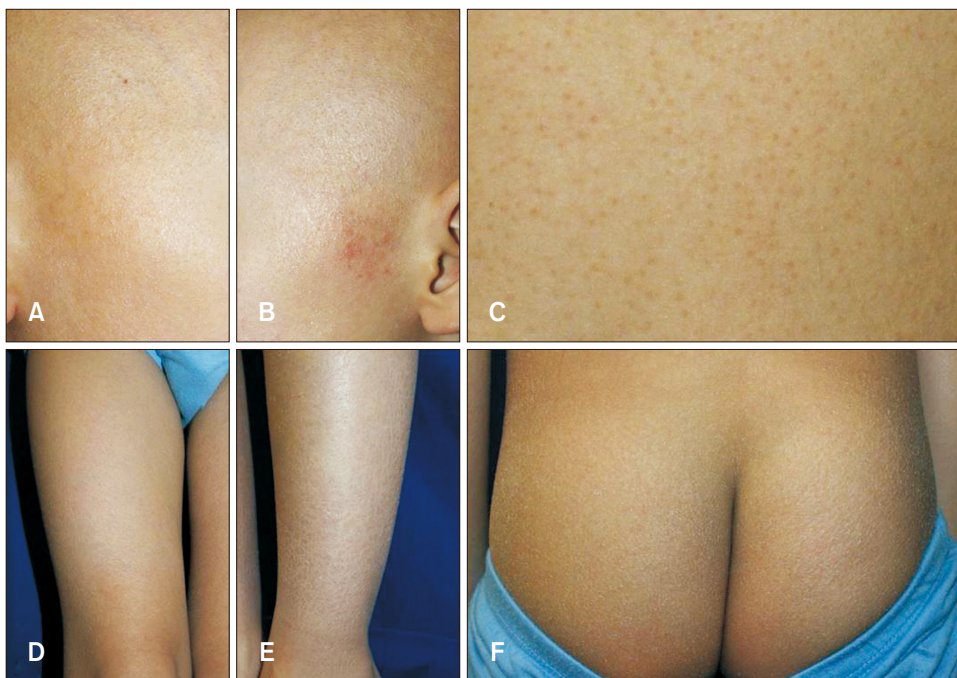


Fig. 2. Spiky follicular hyperkeratotic papules were observed on both cheeks (A, B) and trunk (C). Scaly patches were observed on extremities (D, E) and buttocks (F).

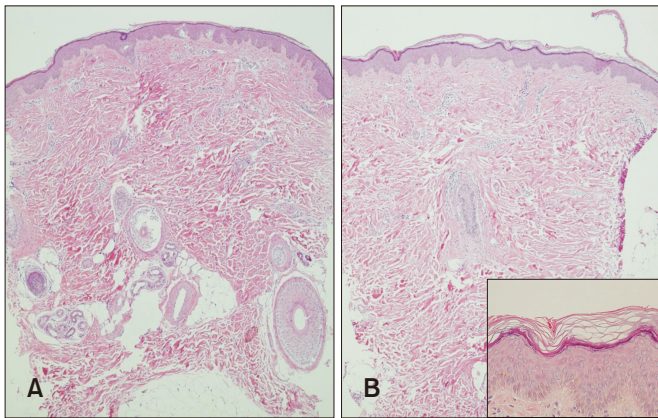


Fig. 3. (A) Miniaturized hair follicles without perifollicular fibrosis were observed on scalp (H&E, ×40). (B) Basket-weave pattern hyperkeratosis was observed on the lower extremity. Inlet: high-power view of epidermis (H&E, ×40; Inlet: H&E, ×400).

follicles were found to be absent on dermoscopy (Fig. 1F). On physical examination, spiky follicular hyperkeratotic papules were observed on the face and trunk (Fig. 2A~C). Generalized xerosis and ichthyotic scaly patches were observed on the entire body (Fig. 2D~F). In addition, he had been using artificial tears for several years due to severe photophobia. We received the patient's consent form about publishing all photographic materials. Skin biopsy was performed from the hairless patch on the scalp and scaly patch on the lower extremity. Histopathological findings showed miniaturized hair follicles without perifollicular fibrosis on the scalp (Fig. 3A) and basket-weave pattern hyperkeratosis on the lower extremity (Fig. 3B). Clinically, the features were suggestive of IFAP syndrome. Notably, the patient's mother was also found to present similar but mild symptoms during her childhood. She had presented partial hairless patches on the scalp and a linear pattern of ichthyotic skin which gradually improved while growing up. Peripheral blood was sampled from the patient and his mother for *MBTPS2* direct sequencing. In both samples, genetic analysis revealed a novel mutation in the *MBTPS2* gene located in Xp22.1 which was a homozygous missense mutation of c.245T>C leading to an amino acid substitution from phenylalanine to serine (p.Phe82Ser) (Fig. 4A, B). This showed X-linked recessive inheritance (Fig. 4C). The diagnosis of IFAP syndrome was validated. Symptomatic therapy including emollients on the ichthyotic skin lesion and topical minoxidil solution on the scalp were prescribed to the patient.

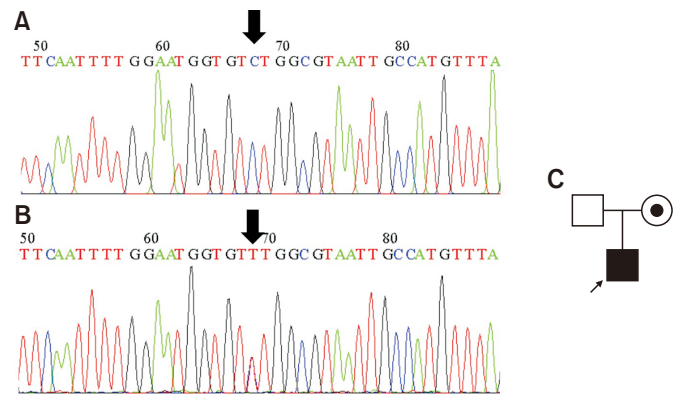


Fig. 4. Diagnostic exome sequencing of the the patient and his mother showed that X-linked recessive inheritance pattern. (A) Hemizygous mutation of c.245T>C detected on the Xp21.1 of the proband. (B) His mother was heterozygous for the same mutation. (C) Pedigree chart of the patient's family. The arrow indicates the proband.

DISCUSSION

IFAP syndrome is an X-linked recessive congenital genetic disorder. It was first recognized as a distinct entity by MacLeod⁴ in 1909 and since then, over 60 cases have been reported worldwide⁵. According to an international consensus for the classification of inherited ichthyosis, IFAP syndrome is classified as a syndromic form of inherited ichthyosis⁶. Thus, the phenotype is observed not only on the skin but also in other organs, which can result into cerebral anomalies, retarded psychomotor development, photophobia, or renal anomalies.

In 2009, mutations in the *MBTPS2* gene located on Xp22.11-p22.13 were reported to cause IFAP syndrome¹. *MBTPS2* contains 11 exons, and it encodes a membrane-embedded zinc metalloprotease, termed site-2 protease (S2P/MBTPS2) with 519 amino acids. It is essential for transcriptional regulation of cholesterol homeostasis and endoplasmic reticulum (ER) stress response. Deficiency in either of these, sterol or ER homeostasis, could disturb differentiation of epidermal structures and lead to the IFAP phenotype¹. *MBTPS2* gene mutations are associated with a variable spectrum of phenotype in genetic diseases. Those were also revealed as the genetic causes for IFAP syndrome with keratosis follicularis spinulosa decalvans (KFSD) syndrome, BRESHECK syndrome, and an X-linked form of Olmsted syndrome². Clinically, KFSD syndrome can be differentiated from IFAP syndrome due to the presence of scarring alopecia because IFAP syndrome shows non-scarring alopecia⁷. However, both syndromes share mul-

tiple overlapping clinical features and are considered to be in the same genetic disorder spectrum. A unifying term, IFAP/KFSD syndrome has been suggested⁸. Currently, 25 pathogenic *MBTPS2* mutations have been identified. To our knowledge, c.245T>C (p.Phe82Ser) is a novel homozygous missense mutation in the *MBTPS2* gene, which has not been reported in Human Gene Mutation Database (HGMD), ClinVar Database, and Leiden Open Variation Database. Polyphen2 (<http://genetics.bwh.harvard.edu/pph2>) predicted it to be ‘probably damaging’ with a score of 1.000, and Mutation Taster (<http://www.mutationtaster.org/>) rated it as ‘disease-causing’.

MBTPS2 protein is composed of several transmembrane domains (TMs), and Bornholdt et al.² identified possible correlations between the locations of the mutations and disease phenotypes. The *MBTPS2* mutation in the TM2 and TM9 domains, near the N-terminal and the C-terminal amino acids, respectively, maintains higher residual catalytic activity that results in a mild phenotype of IFAP/KFSD. In contrast, a mutation in TM6-TM8 domains is associated with a severe phenotype of the IFAP/BRESHECK or the Olmsted syndrome. The mutation c.245T>C (p.Phe82Ser) in our case, located in TM2, led to a mild phenotype of IFAP syndrome with symptoms of only the classic triad (ichthyosis follicularis, atrichia, and photophobia). This is consistent with previous reports on genotype-phenotype correlations, so long-term prognosis of our patient may be favourable. Because of lyonization or clonal skewed X-inactivation, female carriers may have milder phenotype with hairless patches and ichthyosiform skin changes in a linear mosaic pattern following Blaschko’s lines⁹. This explains the milder symptoms in our patient’s mother.

In summary, we found a novel missense mutation c.245T>C (p.Phe82Ser) in the *MBTPS2* gene resulting in the IFAP syndrome. The mutation is located in the TM2 domain, which maintains a high residual catalytic activity resulting in mild classic symptom triad of IFAP phenotype. This case supports the previous research on genotype-phenotype correlation of *MBTPS2* gene mutation.

CONFLICTS OF INTEREST

The authors have nothing to disclose.

FUNDING SOURCE

None.

ORCID

Jun-Oh Shin, <https://orcid.org/0000-0002-3511-4919>
 Dongyoung Roh, <https://orcid.org/0000-0001-7360-8824>
 Kihyuk Shin, <https://orcid.org/0000-0001-8955-9828>
 Woo-Il Kim, <https://orcid.org/0000-0001-7991-2827>
 Min-Young Yang, <https://orcid.org/0000-0001-8994-8401>
 Won-Ku Lee, <https://orcid.org/0000-0002-4938-2455>
 Hoon-Soo Kim, <https://orcid.org/0000-0002-7649-1446>
 Byung-Soo Kim, <https://orcid.org/0000-0003-0054-8570>
 Moon-Bum Kim, <https://orcid.org/0000-0003-4837-0214>
 Hyun-Chang Ko, <https://orcid.org/0000-0002-3459-5474>

REFERENCES

1. Oeffner F, Fischer G, Happel R, König A, Betz RC, Bornholdt D, et al. IFAP syndrome is caused by deficiency in *MBTPS2*, an intramembrane zinc metalloprotease essential for cholesterol homeostasis and ER stress response. *Am J Hum Genet* 2009;84:459-467.
2. Bornholdt D, Atkinson TP, Bouadjar B, Catteau B, Cox H, De Silva D, et al. Genotype-phenotype correlations emerging from the identification of missense mutations in *MBTPS2*. *Hum Mutat* 2013;34:587-594.
3. Naiki M, Mizuno S, Yamada K, Yamada Y, Kimura R, Oshiro M, et al. *MBTPS2* mutation causes BRESEK/BRESHECK syndrome. *Am J Med Genet A* 2012;158A:97-102.
4. MacLeod J. Three cases of ‘ichthyosis follicularis’ associated with baldness. *Br J Dermatol* 1909;21:165-189.
5. Jiang Y, Jin H, Zeng Y. A novel mutation in *MBTPS2* causes ichthyosis follicularis, alopecia, and photophobia syndrome. *Mol Genet Genomic Med* 2019;7:e812.
6. Oji V, Tadini G, Akiyama M, Blanchet Bardon C, Bodemer C, Bourrat E, et al. Revised nomenclature and classification of inherited ichthyoses: results of the First Ichthyosis Consensus Conference in Sorèze 2009. *J Am Acad Dermatol* 2010;63:607-641.
7. Sequeira FF, Jayaseelan E. Keratosis follicularis spinulosa decalvans in a female. *Indian J Dermatol Venereol Leprol* 2011;77:325-327.
8. Aten E, Brasz LC, Bornholdt D, Hooijkaas IB, Porteous ME, Sybert VP, et al. Keratosis follicularis spinulosa decalvans is caused by mutations in *MBTPS2*. *Hum Mutat* 2010;31:1125-1133.
9. König A, Happel R. Linear lesions reflecting lyonization in women heterozygous for IFAP syndrome (ichthyosis follicularis with atrichia and photophobia). *Am J Med Genet* 1999;85:365-368.