

# Use of iris pattern recognition to evaluate ocular torsional changes associated with head tilt

Mohamed Hussein and David Coats

## Abstract

**Purpose:** To describe the use of enhanced iris images and a computer software program to quantify ocular torsional changes associated with head tilt.

**Methods:** Pixel coordinates of the pupil and different iris landmarks were obtained manually using paint program from digital images of the right and left iris of 3 subjects with normal extraocular motility. Photographs of the right eye and of the left eye were taken in the straight-ahead position and at various degrees of right and left head tilt. A computer software program converted the *x*- and *y*-pixel coordinates into angles of rotation after averaging multiple points and determining the degree and the direction of torsion for each eye. The degree of head tilt was mathematically calculated from the digital images. The degree and the direction of ocular torsion were correlated with the degree and the direction of head tilt.

**Results:** The average degree of head tilt was 27.5 degrees (from 8 to 43 degrees). The average intorsion of the lower eye per degree of head tilt was 0.61 degrees (from 0.54 to 0.65 degrees). The average extorsion of the higher eye per degree of head tilt was 0.56 degrees (from 0.43 to 0.60 degrees). The average ocular torsional changes strongly correlated with the degree of head tilt (correlation coefficient=0.92).

**Conclusions:** Computer-assisted iris pattern recognition and analysis of the ocular torsional changes associated with head tilt may provide a useful and objective means of assessing ocular torsion.

**Keywords:** iris pattern, torsion, head tilt, strabismus, photography

Received: 26 October 2017; revised manuscript accepted: 31 August 2018.

## Introduction

Various methods have been suggested for evaluating torsional changes associated with extraocular motility abnormalities and with changes of head posture. These methods included the use of double Maddox rod, synoptophore, Lancaster red-green test, and analysis of the fundus for torsional changes.<sup>1-4</sup> The Maddox rod testing results are subjective and require a cooperative patient who can understand the test. In addition, this test may not demonstrate subjective torsion in a patient with a congenital or early-onset ocular motility disorder.

We previously evaluated torsional changes associated with inferior oblique muscle surgery using iris landmarks.<sup>4</sup> This method showed promise for

using digital imaging and iris pattern recognition to assess and measure torsion in uncooperative patients. In this study, we hypothesized that by comparing digital images of several iris landmarks we could calculate torsional changes associated with head tilt. We believe that this method might be valuable in evaluating pathological torsional changes associated with extraocular muscle abnormalities. In this study, we described the use of iris images and a computer software program to quantify ocular torsional changes associated with head tilt in normal subjects. Our aim was to confirm that the direction and magnitude of torsional changes, as calculated with this method, is consistent with expected physiological torsional changes reported to be associated with head tilt.

*Ther Adv Ophthalmol*

2018, Vol. 10: 1-5

DOI: 10.1177/  
2515841418806492

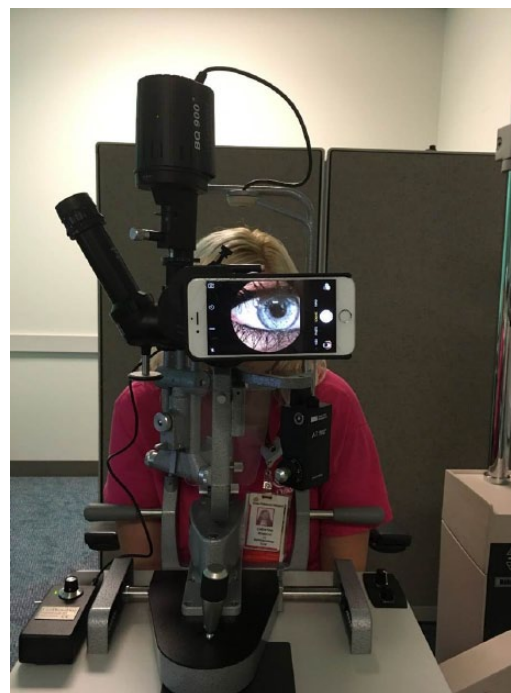© The Author(s), 2018.  
Article reuse guidelines:  
[sagepub.com/journals-  
permissions](http://sagepub.com/journals-permissions)

Correspondence to:  
**Mohamed Hussein**  
Department of  
Ophthalmology, Baylor  
College of Medicine,  
Texas Children's Hospital,  
6701 Fannin Street, Suite  
610.25, Houston, TX 77030,  
USA.  
[mahassei@yahoo.com](mailto:mahassei@yahoo.com)

**David Coats**  
Department of  
Ophthalmology, Baylor  
College of Medicine,  
Texas Children's Hospital,  
Houston, TX, USA.

## Methods

The study was performed with the approval of the Institutional Review Board of Baylor College of Medicine (protocol no. H-34646). Pixel coordinates of the pupil and key iris landmarks were obtained from digital images of the right iris and the left iris of 3 healthy subjects with normal ocular motility examinations. All subjects were orthophoric at distance and near and in all 9 positions of gaze. Double Maddox rod testing was performed and revealed no subjective torsional abnormalities in either eye in all subjects. An iPhone 6s, mounted on the right ocular of a slit lamp, was used to acquire digital images of the anterior segment of both eyes of each subject (Figure 1). Images were obtained with the head erect and in right and left head tilt. Subjects were asked to look at a fixating target at all times while being imaged. A comparison was made between the images taken at the erect head position with images being taken within 5 seconds of the initiation of the head tilt. Figure 2 demonstrates the method used to calculate the degree of head tilt. In summary, the degree of head tilt was determined by calculating the mathematical angle between a perfect vertical line and a line drawn between the inner and outer canthus of the tested eye (Figure 2). Figures 3 and 4 demonstrate the method of calculating ocular torsion. A minimum of 3 distinct iris landmarks were identified for each eye (Figure 2A to C). Each image was copied into a paint program and the  $x$ - and  $y$ -coordinates of each landmark were determined applying the cursor over the pixels corresponding to each landmark. Calculating the degree and direction of torsion based on these coordinates, manually, would have been a complex mathematical task, as this would have entailed using trigonometry to convert the  $x$ - and  $y$ -coordinates into polar coordinates relative to the interpupillary axis. This should have been followed by subtracting the angle obtained in the straight-ahead position from the angle obtained with head tilt to determine the degree and direction of torsion, after averaging multiple points. To facilitate this complex mathematical task, a proprietary computer software program was designed to convert the  $x$ - and  $y$ -pixel coordinates into polar coordinates, average the 3 iris landmarks, and calculate both the degree and the direction of torsion for each eye (Figure 4). The degree and direction of ocular torsion were then correlated with the degree and direction of head tilt.



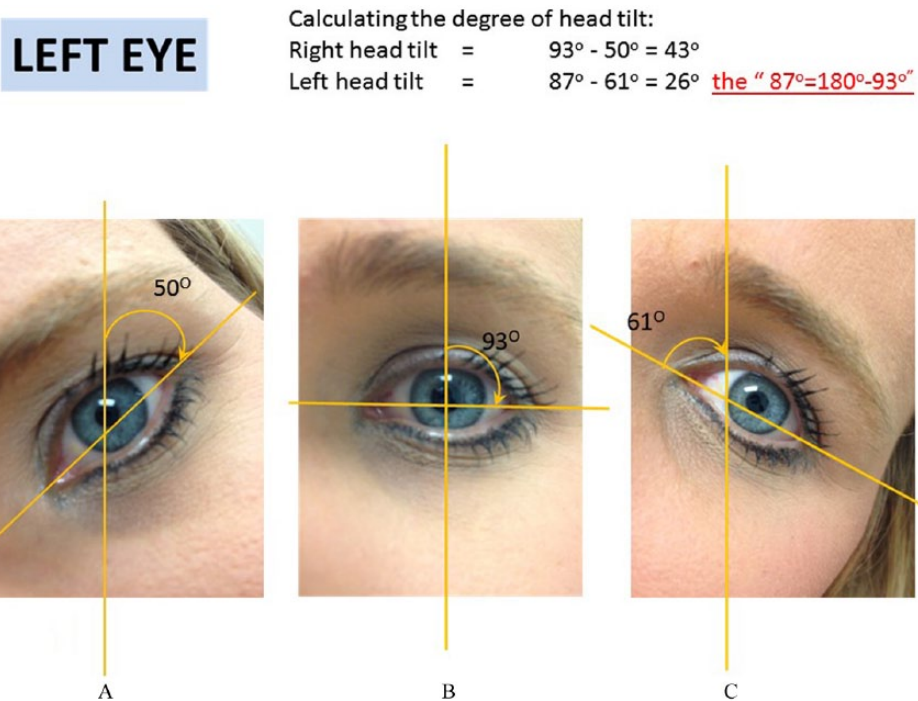
**Figure 1.** Demonstrating the method of photographing the anterior segment of the eye using iPhone 6.

## Results

Intorsion of the lower eye and extorsion of the higher eye were present in all patients and with all degrees of head tilt, as expected. The average degree of head tilt evaluated was 27.5 degrees (from 8 to 43 degrees). The average intorsion of the lower eye per degree of head tilt was 0.61 degrees (from 0.54 to 0.65 degrees). The average extorsion of the higher eye per degree of head tilt was 0.56 degrees (from 0.43 to 0.60 degrees). The average ocular torsion associated with a given head tilt was strongly correlated (correlation coefficient = 0.92; Figure 5).

## Discussion

Current methods for clinically evaluating ocular torsion include double Maddox rod, synoptophore, the Lancaster red-green test, and examination of the ocular fundus.<sup>1-4</sup> Calculating the torsional changes associated with extraocular muscle abnormalities in children and uncooperative patients can be challenging. The use of enhanced iris images has been used before to calculate torsional changes associated with inferior oblique muscle surgery.<sup>4</sup> In this study, we evaluated the use of enhanced iris images and a proprietary computer software



**Figure 2.** Method of calculating the degree of head tilt (calculated mathematically using the digital images).  
 A: right head tilt; B: straight ahead position; C: left head tilt.

program to precisely calculate torsional changes associated with head tilt in 3 healthy adult subjects at various degrees of head tilt based on changes in the position of unique iris landmarks. Our results demonstrated that using this method was consistent with the physiologically known direction of torsion associated with head tilt.

Our results demonstrated intorsion of the lower eye and extorsion of the higher eye in all subjects with any degree of head tilt to the right or left. This is consistent with the well-documented ocular counterrolling,<sup>5-9</sup> suggesting that using iris landmarks can be useful to quantify the ocular tilt response. Our results demonstrated that the degree of ocular torsion associated with a head tilt ranges from 0.45 to 0.63 per degree of head tilt. Our study demonstrated a larger degree of ocular torsion associated with head tilt than has been previously reported.<sup>6-11</sup> The degree of correlation of ocular torsion with the degree of head tilt remains unsettled. Various studies have reported an average ocular torsion ranging from 10% to 27% of the degree of head tilt.<sup>6-11</sup>

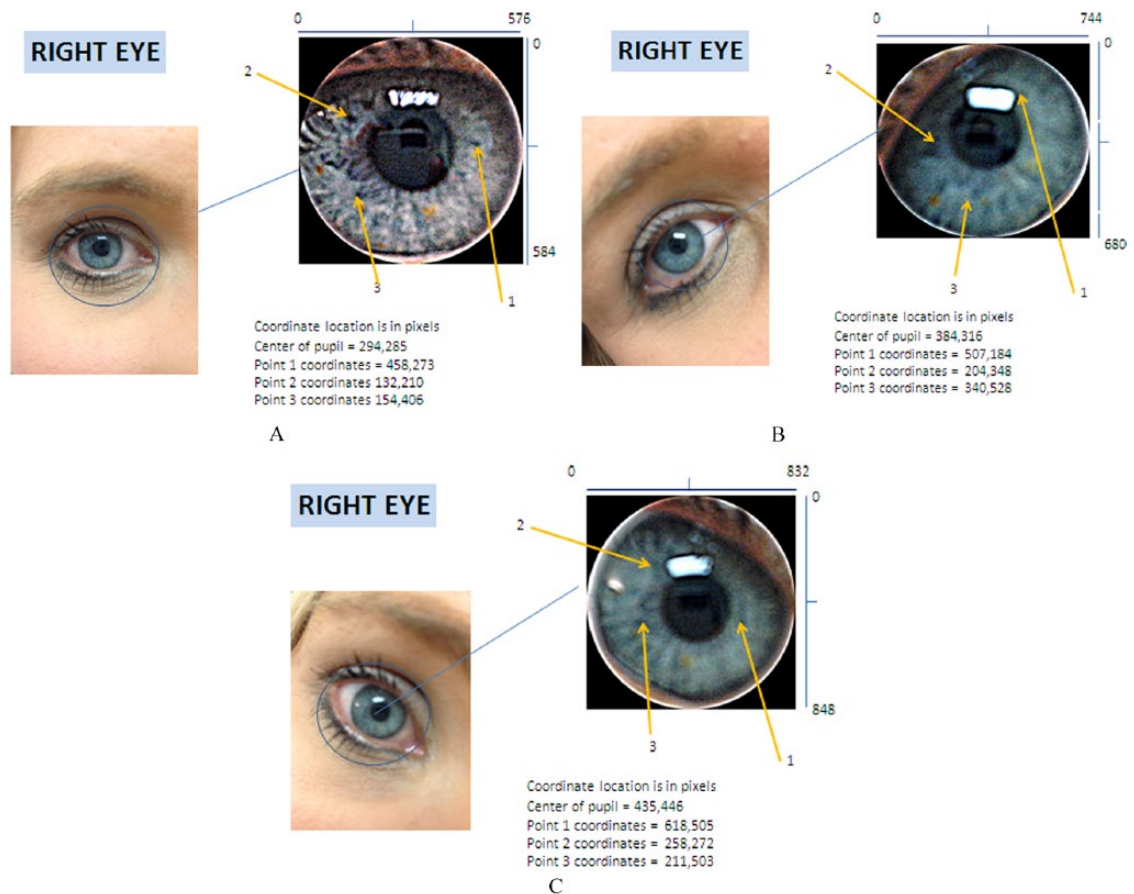
Most published studies, however, evaluated ocular torsion at 3 fixed and predetermined large degrees of head tilt. In our study, by contrast, the

degree of head tilt for each subject was randomly assigned and included both moderate and very small degrees of tilt (the smallest was 8 degrees). Also, our study did not include higher degrees of head tilt, more than 45 degrees, as these were hard to reproduce and maintain and were considered unphysiological. Larger degrees of head tilt, included in the other studies, are thought to lead to lesser degrees of ocular rotation,<sup>7</sup> with expected subsequent less average overall ocular rotation associated with the head tilt.

Although our method measures relative changes of torsional eye position, it has the advantage of potentially being used to determine pathological changes secondary to cyclovertical muscle palsies.

Multiple other studies have used similar hypothesis to determine ocular counterrolling.<sup>12-14</sup> Compared with ours, however, most of these methods, require sophisticated environment that cannot be easily used or reproduced in a simple clinical setting.

One weakness of this study is the small number of healthy subjects tested. The main purpose of this study, however, was to simply test the applicability and reliability of this method to determine the



**Figure 3.** Determining x- and y-coordinates for the right eye (A) in the straight-ahead position, (B) with right head tilt, and (C) with left head tilt.

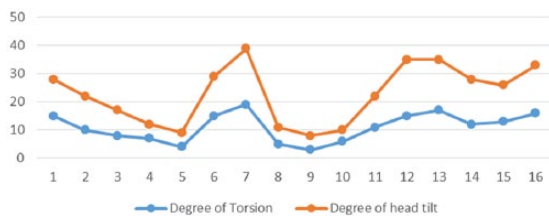
RIGHT EYE				LEFT EYE			
Straight		Head Tilt		Straight		Head Tilt	
X	Y	X	Y	X	Y	X	Y
<b>PUPIL CENTER</b>							
273	147	438	415	282	218	279	309
<b>IRIS MARKINGS</b>							
400	149	626	467	405	259	408	399
127	203	197	426	179	289	123	350
270	274	391	630	280	348	243	466

**Figure 4.** Example of applying the x- and y-coordinates of the various points in the iris into the software program, calculating the degree and direction of torsion. Right eye change mean equals 11.81264, that is, extorsion. Left eye change mean equals 10.77868, that is, intorsion.

physiologically expected direction of torsion associated with head tilt. Further studies with a larger sample size will be needed to look into the possibility of using this method in diagnosing pathological

torsional changes associated with cyclovertical muscle palsy. Another limitation of this study is the inability to compare these results with known reliable objective or subjective methods to





**Figure 5.** Correlation of the degree of head tilt with the degree of torsion.

determine torsional changes associated with head tilt. None of the current methods for measuring torsional changes appears to be reliable or objective enough to consider as a reliable method for comparison. Also, it may be harder to use the iris pattern in extremely dark iris patients.

The use of iris images and our proprietary software program can be used to assess the degree of ocular torsional change associated with head tilt in healthy subjects. We hypothesize that our method may be useful in evaluating pathological torsional changes associated with extraocular muscle abnormalities. In summary, computerized iris pattern recognition and analysis of the ocular torsional changes associated with head tilt is feasible and may provide a useful objective means of assessing ocular torsion.

### Conflict of interest statement

The author(s) declared no potential conflicts of interest with respect to the research, authorship, and/or publication of this article.

### Funding

The author(s) received no financial support for the research, authorship, and/or publication of this article.

### References

- Sharma P, Saxena R, Rao BV and Menon V. Effect of posterior tenectomy of the superior oblique on objective and subjective torsion in cases of superior oblique overaction. *J Pediatr Ophthalmol Strabismus*. 2005;42:284-289.
- Hwang JM and Guyton DL. The Lancaster red-green test before and after occlusion in the evaluation of incomitant strabismus. *J AAPOS*. 1999;3:151-156.
- Kushner BJ. The influence of head tilt on ocular torsion in patients with superior oblique muscle palsy. *J AAPOS*. 2009;13:132-135.
- Felius J, Locke KG, Hussein MA, Stager DR Jr and Stager DR Sr. Photographic assessment of changes in torsional strabismus. *J AAPOS*. 2009;13:593-595.
- Walton WG. Compensatory cyclo-torsion accompanying head tilt. *Am J Optom Arch Am Acad Optom*. 1948;25:525-534.
- Woo SJ, Seo JM and Hwang JM. Clinical characteristics of cyclodeviation. *Eye*. 2005;19:873-878.
- Schworm HD, Ygge J, Pansell T and Lennerstrand G. Assessment of ocular counterroll during head tilt using binocular video oculography. *Invest Ophthalmol Vis Sci*. 2002;43:662-667.
- Collewijn H, Van der Steen J, Ferman L and Jansen TC. Human ocular counterroll: assessment of static and dynamic properties from electromagnetic scleral coil recordings. *Exp Brain Res*. 1985;59:185-196.
- Diamond SG and Markham CH. Ocular counterrolling as an indicator of vestibular otolith function. *Neurology*. 1983;33:1460-1469.
- Kingma H, Stegeman P and Vogels R. Ocular torsion induced by static and dynamic visual stimulation and static whole body roll. *Eur Arch Otorhinolaryngol* 1997;25:161-163.
- Averbuch-Heller L, Rottach KG, Zivotovsky AZ, et al. Torsional eye movements in patients with skew deviation and spasmodic torticollis: responses to static and dynamic head roll. *Neurology*. 1997;48:506-514.
- Bos JE and de Graaf B. Ocular torsion quantification with video images. *IEEE Trans Biomed Eng*. 1994;41:351-357.
- Groen E, Bos JE, Nacken PFM and Graaf B. Determination of ocular torsion by means of automatic pattern recognition. *IEEE Trans Biomed Eng*. 1996;43:471-479.
- Ivins JP, Porrill J and Frisby JP. Deformable model of the human iris for measuring ocular torsion from video images. *IEEE Proc Vis Image Signal Process*. 1998;145:3213-3220.

Visit SAGE journals online  
journals.sagepub.com/  
home/oed

SAGE journals